

## LETTER TO THE EDITOR

# De novo guttate psoriasis following coronavirus disease 2019 vaccination

Dear Editor,

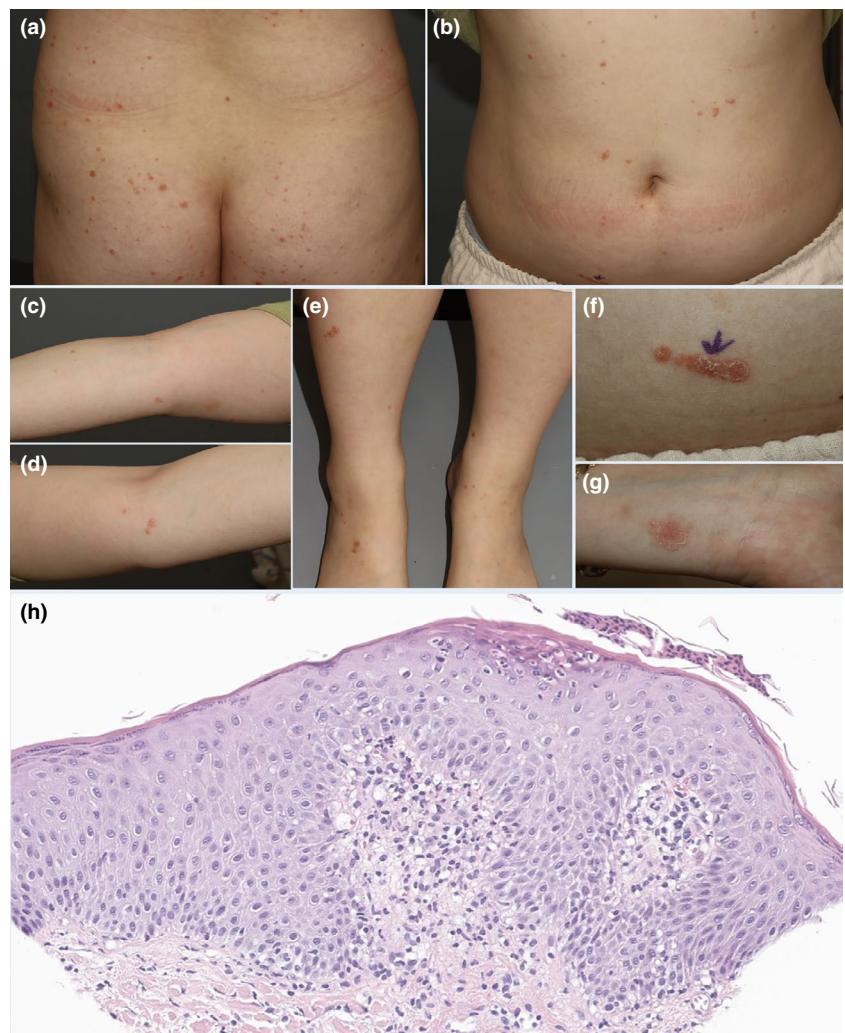
In the era of the coronavirus disease 2019 (COVID-19) pandemic, the importance of vaccination is being increasingly emphasized. With more and more people receiving vaccination, diverse cutaneous reactions are also arising.<sup>1</sup> Here, we report a case of a patient with the first onset of guttate psoriasis after COVID-19 vaccination.

A previously healthy 23-year-old woman presented with erythematous papules and plaques that appeared 2 days after the first dose of COVID-19 vaccine (Pfizer-BioNTech BNT162b2). The lesions had first appeared on the dorsum of her hand and subsequently extended to her arms, legs, and trunk. The patient denied having any

symptom other than the skin lesions. She had no personal or family history of psoriasis and was not on any medication.

Physical examination revealed drop-like scaly erythematous papules and plaques affecting the trunk, the extremities, and the buttock (Figure 1a–g). Histopathology showed moderate acanthosis with rete ridge elongation as well as neutrophilic collection within the stratum corneum, which was compatible with the diagnosis of guttate psoriasis (Figure 1h). Laboratory examinations including blood count, C-reactive protein, erythrocyte sedimentation rate, and antistreptolysin O titer were all within normal limits.

Treatment with topical calcipotriol/betamethasone was initiated. After 2 weeks of follow-up, there was a significant



**FIGURE 1** Clinical and pathological features of the patient. (a–g) Clinical pictures of the patient's buttock, abdomen, arms, legs, and higher magnification of the abdomen and wrist. Drop-like scaly erythematous papules and plaques are scattered over the whole body. (h) Hematoxylin–eosin staining of skin biopsy showing acanthosis with rete ridge elongation and collection of neutrophils within the stratum corneum (original magnification  $\times 200$ )

improvement in the previous lesions. Three weeks after the first dose, the patient received her second dose of vaccine, after which she reported exacerbation of the previous lesions and formation of new lesions.

Guttate psoriasis is a form of psoriasis that typically affects children and young adults. It is often associated with streptococcal infection, although other respiratory virus infection may also trigger onset or flare of psoriasis.<sup>2</sup> COVID-19 is no exception. There has been one case of guttate flare of chronic psoriasis secondary to COVID-19 infection. The proposed mechanism of COVID-19 infection leading to guttate psoriasis is the dysregulation of innate immune response following stimulation of Toll-like receptor by viral RNA, thereby producing pathogenic cytokines such as interleukin-36- $\gamma$  and CXCL8.<sup>3</sup> Lehmann *et al.*<sup>4</sup> reported the first case of de novo guttate psoriasis after Pfizer-BioNTech COVID-19 vaccination in a 79-year-old patient. Lehmann *et al.*<sup>4</sup> conducted immunohistochemical analysis of the patient's skin lesion, which showed strong focal expression of MX1, a surrogate marker of type 1 interferon (IFN). Such a finding may imply that mRNA COVID-19 vaccines activate an immune response in a way similar to COVID-19 virus, via binding to Toll-like receptors and thus producing type 1 IFN and other pro-inflammatory cytokines.<sup>4,5</sup> To susceptible patients, this process can manifest as guttate psoriasis-like lesions.




Our case is the second of de novo guttate psoriasis post-COVID-19 vaccination but with a more acute onset in a previously healthy young adult. The close temporal relationship between vaccination and skin manifestation along with the absence of any triggering factors suggest that COVID-19 vaccination precipitated the development of guttate psoriasis in our case. It is critical that dermatologists stay aware of the COVID-19 vaccine-associated cutaneous manifestations like cases such as this, in order to provide the patients with appropriate guidance and management.

#### ACKNOWLEDGMENTS

None.

#### CONFLICT OF INTEREST

None declared.

Won Ji Song<sup>1</sup>   
 Youngkyoung Lim<sup>1,2</sup>   
 Seong Jin Jo<sup>1,2,3,4</sup> 

<sup>1</sup>Department of Dermatology, Seoul National University Hospital, Seoul, Korea

<sup>2</sup>Skin Cancer/Chemotherapy Skin Care Center, Seoul National University Cancer Hospital, Seoul, Korea

<sup>3</sup>Department of Dermatology, Seoul National University College of Medicine, Seoul, Korea

<sup>4</sup>Institute of Human-Environment Interface Biology, Seoul National University, Seoul, Korea

#### Correspondence

Youngkyoung Lim, Department of Dermatology, Seoul National University Hospital, 101 Daehak-ro, Jongno-gu, Seoul 03080, Korea.  
 Email: ykwh01232@naver.com

#### ORCID

Won Ji Song  <https://orcid.org/0000-0002-2460-7590>

Youngkyoung Lim  <https://orcid.org/0000-0002-6409-2704>

Seong Jin Jo  <https://orcid.org/0000-0002-2501-7672>

#### REFERENCES

1. Sun Q, Fathy R, McMahon DE, Freeman EE. COVID-19 vaccines and the skin: the landscape of cutaneous vaccine reactions worldwide. *Dermatol Clin*. 2021;39:653–73.
2. Sbidian E, Madrange M, Viguier M, Salmona M, Duchatelet S, Hovnanian A, *et al*. Respiratory virus infection triggers acute psoriasis flares across different clinical subtypes and genetic backgrounds. *Br J Dermatol*. 2019;181:1304–6.
3. Gananandan K, Sacks B, Ewing I. Guttate psoriasis secondary to COVID-19. *BMJ Case Rep*. 2020;13:e237367.
4. Lehmann M, Schorno P, Hunger RE, Heidemeyer K, Feldmeyer L, Yawalkar N. New onset of mainly guttate psoriasis after COVID-19 vaccination: a case report. *J Eur Acad Dermatol Venereol*. 2021;35:e752–e755.
5. Teijaro JR, Farber DL. COVID-19 vaccines: modes of immune activation and future challenges. *Nat Rev Immunol*. 2021;21:195–7.