

- diversification via UNC93B and IRAK4. *J Exp Med* 2021; **218**: e20201387.
- 3 Abou-Rahal J, Kurban M, Kibbi AG, Abbas O. Plasmacytoid dendritic cells in alopecia areata: missing link? *J Eur Acad Dermatol Venereol* 2016; **30**: 119–23.
- 4 Teijaro JR, Farber DL. COVID-19 vaccines: modes of immune activation and future challenges. *Nat Rev Immunol* 2021; **21**: 195–7.
- 5 Bertolotti A, Boniface K, Vergier B *et al.* Type I interferon signature in the initiation of the immune response in vitiligo. *Pigment Cell Melanoma Res* 2014; **27**: 398–407.

Abrupt onset of Sweet syndrome, pityriasis rubra pilaris, pityriasis lichenoides et varioliformis acuta and erythema multiforme: unravelling a possible common trigger, the COVID-19 vaccine

doi: 10.1111/ced.14970

Dear Editor,

The development and manufacturing of effective vaccines against COVID-19 has been an epic achievement in record time, and we believe that the vaccine will help

stop the pandemic. As with other medical interventions, vaccines may carry a small risk of adverse reactions (ARs), especially when used on large populations outside the highly controlled setting of Phase 3 clinical trials. We report five cases of different rare and severe cutaneous conditions arising in close connection with COVID-19 vaccination (Table 1).

By April 2021, about 15% of the 849 000 inhabitants of the province of Vicenza (in the Veneto region of north-east Italy) had been vaccinated, with a male : female ratio of 3 : 2. The priority was accorded to older people (> 80 years), healthcare workers and school staff. Overall, 187 adverse events were recorded. Besides the more common reactions reflecting aspecific activation of the immune system such as urticaria and cutaneous rash, we observed four rare acute conditions in five recently vaccinated patients [pityriasis rubra pilaris (PRP) in two patients, and Sweet syndrome (SS), pityriasis lichenoides et varioliformis acuta (PLEVA) and erythema multiforme (EM) in one patient each] (Fig. 1). All these conditions were confirmed histologically (Fig. 2) and appeared within the first 2 weeks following the first dose of the COVID-19 vaccine.

Table 1 Brief summary of the demographic and clinical features of the patients.

Patient	Diagnosis	Sex	Age, years	Type of COVID-19 vaccine	Time lag, days	Comorbidities	Clinical course
1	PRP	F	62	Moderna, first dose (second dose not administered)	5	Metabolic syndrome, T2DM, hypertensive heart disease, hypothyroidism, CKD	Progressive remission with systemic prednisone (1 mg/kg/day for 2 weeks, then tapered) and topical steroids at 1-month follow-up. Hospitalization for COVID-19 infection 4 months after PRP onset
2	PRP	F	82	Pfizer–BioNTech, first dose (second dose not administered)	7	Plaque and nail psoriasis, CLL, T2DM, hypertension, COPD	Clinical improvement achieved with subcutaneous MTX 15 mg/weekly. Residual PP hyperkeratosis and scaly plaques on head and neck at the 4-month follow-up
3	SS	F	69	Oxford–AstraZeneca, first dose (second dose not administered)	12	Overweight, hypertension, dyslipidaemia, iron-deficiency anaemia	Treated with steroid administration (prednisone 1 mg/kg/day for 4 weeks, then slow tapering). At 3-month follow-up, complete healing of the ulcerated plaques with residual hyperpigmentation
4	PLEVA	M	70	Pfizer–BioNTech, second dose	5	Acute lymphocytic leukaemia in complete remission	Treated with topical combination of fusidic acid 2% plus betamethasone cream 0.1%. Complete remission within 10 weeks
5	EM	F	76	Pfizer–BioNTech, first dose (second dose administered)	4	Lung adenocarcinoma (Stage IV), arterial hypertension, T2DM, COPD	Topical prescription of methylprednisolone 0.1% cream twice daily for 10 days. Complete clearance achieved in 10 days. No recurrence with the second vaccine dose

CKD, chronic kidney disease; CLL, chronic lymphocytic leukaemia; COPD, chronic obstructive pulmonary disease; EM, erythema multiforme; PLEVA, pityriasis lichenoides et varioliformis acuta; PP, palmoplantar; PRP, pityriasis rubra pilaris; T2DM, Type 2 diabetes mellitus; MTX, methotrexate; SS, Sweet syndrome.

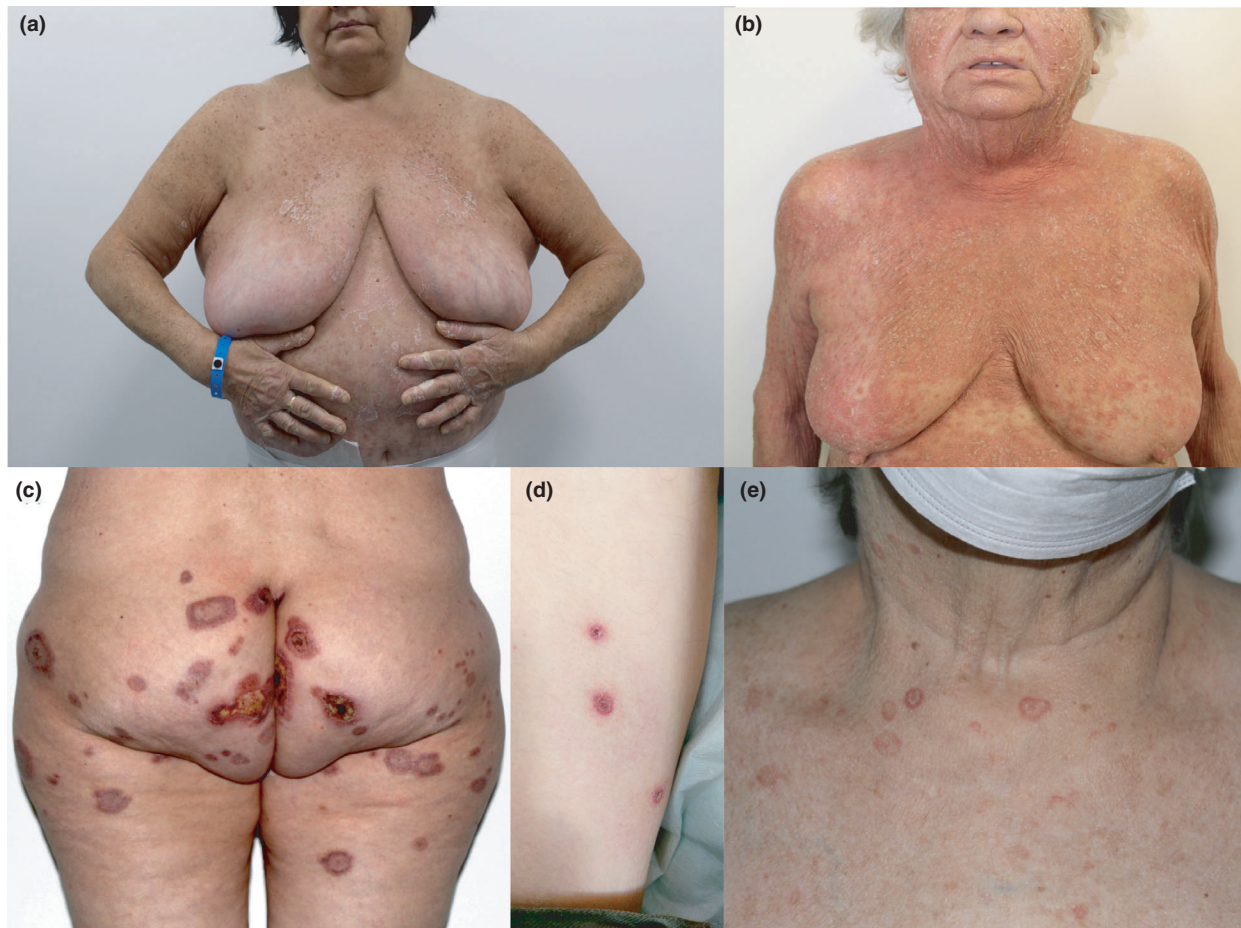

Figure 1 (a–e) Clinical features of the five cases with possible COVID-19 vaccine-related adverse reactions: (a,b) pityriasis rubra pilaris (two patients, both confirmed histologically) manifesting as widespread distributed erythematous patches and concomitant unaffected ‘islands’, resolving with lamellar desquamation; (c) Sweet syndrome, showing evolutive polymorphism of early annular lesions evolving into large, thickened ulcerated plaques; (d) pityriasis lichenoides et varioliformis acuta, manifesting as scattered, nonfolliculocentric, rapidly evolving papules showing erythematous, raised borders and an eroded centre, covered by a haemorrhagic crust; and (e) erythema multiforme, showing noncoalescing target-like lesions mainly distributed on the limbs.

To better characterize the relationship between these possible ARs and vaccine administration, we used the Naranjo Adverse Drug Reaction Probability Scale,¹ obtaining a score for each patient indicating a ‘probable’ causality link (Table 2). All patients had undergone a COVID-19 throat swab test 2 weeks prior to the vaccine, which was negative, and none of them had been infected since the pandemic started. None of the patients had any medical history of previous ARs to drugs or vaccines, or of any dermatological disorders.

A number of cutaneous conditions following COVID-19 immunization have been reported, most of which were mild and self-limiting such as local injection-site reactions, and urticarial and morbilliform eruptions. In addition, some rare reactions have been observed including chilblains, cosmetic filler reactions, flares of herpes zoster

or simplex, pityriasis rosea-like reactions, EM and SS.^{2,3} Our observations confirm the possible association of COVID-19 vaccination with both EM and SS. In addition, this case series expands on the spectrum of possible vaccine ARs to include PRP and PLEVA.

There is a debate about the capacity of COVID-19 vaccines to trigger immune-mediated conditions, either with exacerbation of pre-existing or new onset of immune-mediated disorders. These events may result from upregulated inflammatory immunological pathways or crossreactivity between viral or adjuvant molecules and self-antigens. Other vaccines have been associated with immune-mediated cutaneous ARs, including EM, cutaneous lupus, Gianotti–Crosti syndrome, lichenoid eruption and granuloma annulare,⁴ and also a few cases of SS, PRP and PLEVA.⁵

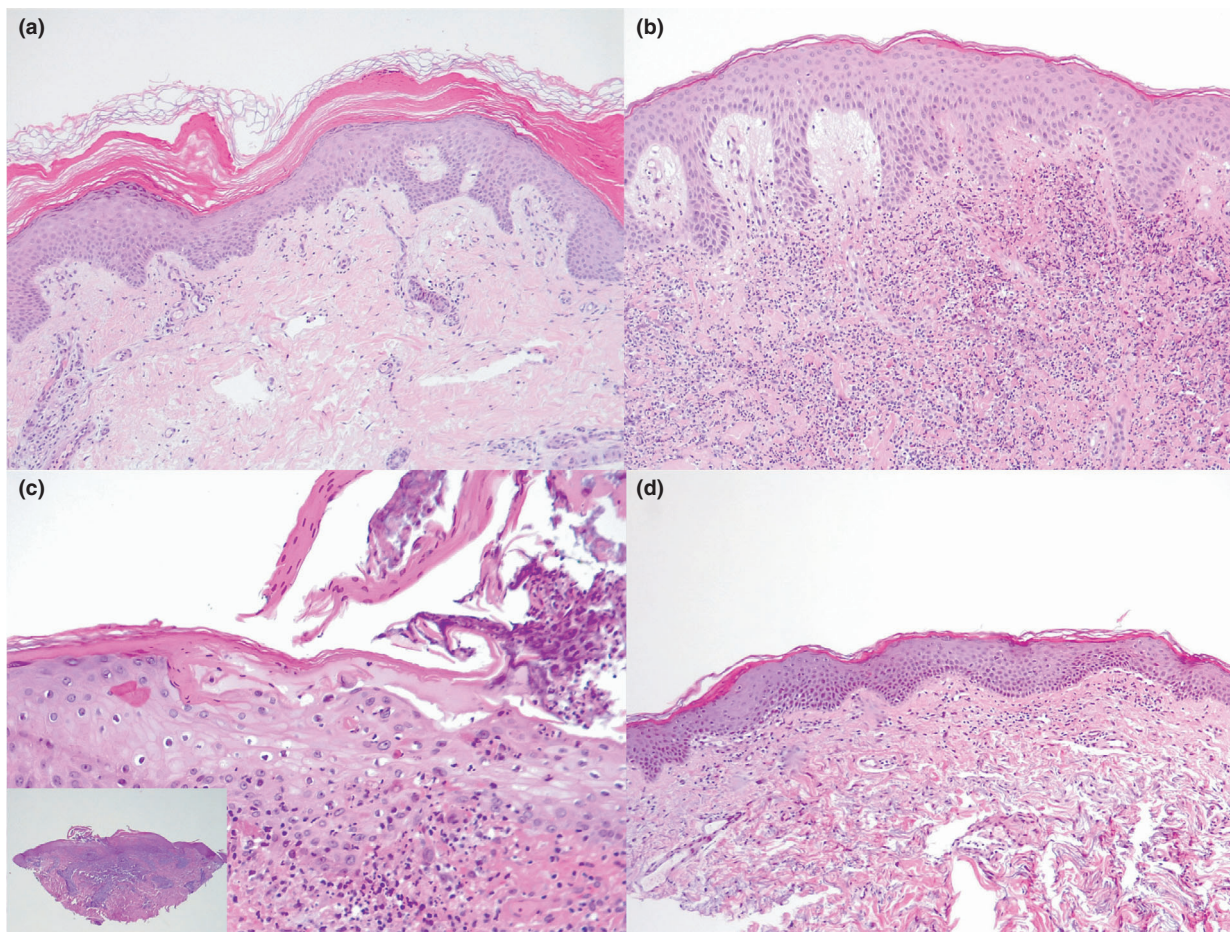


Figure 2 (a–e) Histological analysis of incisional cutaneous biopsy taken from the patients: (a) pityriasis rubra pilaris, showing acanthotic epidermis with fusion and broadening of rete ridges and alternating orthokeratosis and parakeratosis; (b) mildly acanthotic epidermis with subepidermal oedema and intense interstitial neutrophilic infiltrate in a patient with Sweet syndrome; (c) pityriasis lichenoides et varioliformis acuta, showing focal epidermal ulceration, spongiosis, parakeratosis, and interface inflammation within a wedge-shaped dermal inflammatory cell infiltrate; and (d) vacuolar interface dermatitis with a dermal inflammatory lymphohistiocytic infiltrate and a mild epidermal spongiosis in a patient with erythema multiforme. Haematoxylin and eosin, original magnification (a) $\times 200$; (b,c) $\times 50$; (c) $\times 400$, inset $\times 25$.

The causal relationship between mRNA vaccines and cutaneous immunological reactions is still under debate, and we cannot exclude that the events we have reported were purely coincidental. Systemic surveillance and accurate reporting are essential to estimate associations and better qualify the potentially at-risk population, defining effective management strategies.

A. Sechi,^{1,2} E. Pierobon,³ E. Pezzolo,¹ L. Germi,¹ G. Trevisan,¹ D. Zardo,⁴ G. Riva,⁴ S. Mondino⁵ and L. Naldi¹

¹Dermatology Unit, Ospedale San Bortolo, Vicenza, Italy; ²IRCCS University Hospital of Bologna S Orsola-Malpighi Polyclinic Dermatology Division, Department of Experimental, Diagnostic and Specialty Medicine (DIMES), Alma Mater Studiorum University of Bologna, Bologna, Italy; ³Section of Dermatology, Department of Medicine and Surgery, University of Parma, Parma, Italy;

⁴Pathology Unit and ⁵Health and Risk Management, Ospedale San Bortolo, Vicenza, Italy

E-mail: andrea.sechi@hotmail.com

Conflict of interest: the authors declare that they have no conflicts of interest.

AS and EP contributed equally to this work and should be considered joint first authors.

Accepted for publication 7 August 2021

References

- Naranjo CA, Busto U, Sellers EM *et al*. A method for estimating the probability of adverse drug reactions. *Clin Pharmacol Ther* 1981; **30**: 239–45.
- McMahon DE, Amerson E, Rosenbach M *et al*. Cutaneous reactions reported after Moderna and Pfizer COVID-19

Table 2 Naranjo Adverse Drug Reaction Probability Scale¹: the reaction is considered definite if the score is ≥ 9 , probable if 5 to 8, possible if 1 to 4, and doubtful if 0 or less.

Question:	Patient				
	1	2	3	4	5
1 Are there previous conclusive reports on this reaction? Yes: +1; No: 0; Don't know: 0	0	0	+1	0	+1
2 Did the adverse event appear after the suspected drug was administered? Yes: +2; No: -1; Don't know: 0	+2	+2	+2	+2	+2
3 Did the adverse reaction improve when the drug was discontinued, or a specific antagonist was administered? Yes: +1; No: 0; Don't know: 0	+1	+2	+1	+1	+1
4 Did the adverse event reappear when the drug was re-administered? Yes: +2; No: -1; Don't know: 0	0	0	0	0	-1
5 Are there alternative causes that could on their own have caused the reaction? Yes: -1; No: +2; Don't know: 0	+2	+2	+2	+2	+2
6 Did the reaction reappear when a placebo was given? Yes: -1; No: +1; Don't know: 0	0	0	0	0	0
7 Was the drug detected in blood (or other fluids) in concentrations known to be toxic? Yes: +1; No: 0; Don't know: 0	0	0	0	0	0
8 Was the reaction more severe when the dose was increased or less severe when the dose was decreased? Yes: +1; No: 0; Don't know: 0	0	0	0	0	0
9 Did the patient have a similar reaction to the same or similar drugs in any previous exposure? Yes: +1; No: 0; Don't know: 0	0	0	0	0	0
10 Was the adverse event confirmed by any objective evidence? Yes: +1; No: 0; Don't know: 0	+1	+1	+1	+1	+1
Total score	6	7	7	6	6

vaccination: a registry-based study of 414 cases. *J Am Acad Dermatol* 2021; **85**: 46–55.

- Darrigade AS, Théophile H, Sanchez-Pena P *et al*. Sweet syndrome induced by SARS-CoV2 Pfizer-BioNTech mRNA vaccine. *Allergy* 2021; **76**: 3194–6. <https://doi.org/10.1111/all.14981>
- Stone CA Jr, Rukasin CRF, Beachkofsky TM, Phillips EJ. Immune-mediated adverse reactions to vaccines. *Br J Clin Pharmacol* 2019; **85**: 2694–706.
- Gunatheesan S, Ferguson J, Moosa Y. Pityriasis lichenoides et varioliformis acuta: a rare association with the measles, mumps and rubella vaccine. *Australas J Dermatol* 2012; **53**: 76–8.

Validation of the RECap of AtoPic eczema measure of eczema control for use in dermatology clinics

doi: 10.1111/ced.14934

Dear Editor,

The Harmonising Outcome Measures for Eczema (HOME) initiative seeks to standardize outcome measures in trials of eczema treatments.¹ The RECap for AtoPic eczema (RECAP) questionnaire is a seven-item HOME-recommended patient-reported outcome measure of eczema control.² The total score of RECAP is from 0 to 28, with higher scores indicating poorer eczema control. In an

online survey of 382 participants, RECAP was found to have good validity and reliability.³ However, the validity and reliability of questionnaires can vary by both population and setting. We investigated the acceptability and validity of RECAP in a clinic setting in Bristol, England.

The study was approved by Yorkshire and The Humber – South Yorkshire research ethic committee (reference no. 25901) and sponsored by the University of Bristol.

Adults with eczema and parents of children with eczema attending hospital dermatology outpatient clinics and a nurse-led community dermatology clinic were invited to complete a paper-based questionnaire. The questionnaire included RECAP together with Patient Reported Eczema Severity (POEM) and the Patient-Reported Outcomes Measurement Information System (PROMIS) quality of life (QoL) tools, both of which have been shown to have good validity.^{4,5}

To evaluate the construct validity of RECAP, the following hypotheses were prespecified: (i) eczema control worsens with increasing disease severity; (ii) poorer eczema control is associated with worse QoL; and (iii) eczema control worsens with disease 'bother' (How much bother has your eczema been over the past week?: 0, none, 10, maximum). A self-reported improvement/worsening in eczema would equate to a decrease/increase in RECAP score.

Our target sample size was 98, but participant recruitment had to be stopped early because of the COVID-19