




CASE REPORT

Severe autoimmune hemolytic anemia following receipt of SARS-CoV-2 mRNA vaccine

Sanjay R. V. Gadi¹ | Patricia A. R. Brunker² | Hanny Al-Samkari³  | David B. Sykes^{3,4} | Rebecca R. Saff⁵  | Janet Lo⁶ | Pavan Bendapudi^{2,3,7} | David E. Leaf^{8*} | Rebecca Karp Leaf^{3*} 

¹Harvard Medical School, Boston, Massachusetts, USA

²Blood Transfusion Service, Department of Pathology, Massachusetts General Hospital, Boston, Massachusetts, USA

³Division of Hematology and Oncology, Massachusetts General Hospital, Boston, Massachusetts, USA

⁴Center for Regenerative Medicine, Massachusetts General Hospital, Boston, Massachusetts, USA

⁵Division of Rheumatology, Allergy, and Immunology, Massachusetts General Hospital, Boston, Massachusetts, USA

⁶Division of Endocrinology, Massachusetts General Hospital, Boston, Massachusetts, USA

⁷Division of Hemostasis and Thrombosis, Beth Israel Deaconess Medical Center, Boston, Massachusetts, USA

⁸Division of Renal Medicine, Brigham and Women's Hospital, Boston, Massachusetts, USA

Correspondence

Rebecca Karp Leaf, Division of Hematology and Oncology, Massachusetts General Hospital, 55 Fruit Street, Boston, MA 02114, USA.
Email: rkarp-leaf@partners.org

Abstract

Background: Large clinical trials have demonstrated the overall safety of vaccines for severe acute respiratory syndrome coronavirus 2 (SARS-CoV-2). However, reports have emerged of autoimmune phenomena, including vaccine-associated myocarditis, immune thrombocytopenia, and immune thrombotic thrombocytopenia.

Case Presentation: Here we present a novel case of a young woman who developed life-threatening autoimmune hemolytic anemia (AIHA) after her first dose of a SARS-CoV-2 mRNA vaccine. Notably, initial direct antiglobulin testing was negative using standard anti-IgG reagents, which are “blind” to certain immunoglobulin (IgG) isotypes. Further testing using an antiglobulin reagent that detects all IgG isotypes was strongly positive and confirmed the diagnosis of AIHA. The patient required transfusion with 13 units of red blood cells, as well as treatment with corticosteroids, rituximab, mycophenolate mofetil, and immune globulin.

Conclusion: As efforts to administer SARS-CoV-2 vaccines continue globally, clinicians must be aware of potential autoimmune sequelae of these therapies.

KEYWORDS

autoimmune hemolytic anemia, direct antiglobulin test, SARS-CoV-2 mRNA vaccine

Abbreviations: AHG, anti-human globulin; AIHA, autoimmune hemolytic anemia; ANA, anti-nuclear antibodies; CMV, cytomegalovirus; DAT, direct antiglobulin test; EBV, Epstein-Barr virus; HIV, human immunodeficiency virus; IgG, immunoglobulin; IVIG, IV immune globulin; LDH, lactate dehydrogenase; MCV, mean corpuscular volume; MGH, Massachusetts General Hospital; MMF, mycophenolate mofetil; mRNA, messenger RNA; RBCs, red blood cells; RSV, respiratory syncytial virus; SARS-CoV-2, severe acute respiratory syndrome coronavirus 2.

*David E. Leaf and Rebecca Karp Leaf contributed equally to this study.

1 | CASE REPORT

A 41-year-old woman received her first dose of the SARS-CoV-2 mRNA-1273 vaccine in March 2021. Seven days after vaccination, she noted fatigue and dark urine. Twenty days after vaccination, she was admitted to another hospital, where initial laboratory findings were notable for hemoglobin 7.1 g/dl, mean corpuscular volume (MCV) 93 fl, reticulocyte count 15.5%, total bilirubin 3.7 mg/dl, direct bilirubin 0.8 mg/dl, haptoglobin <8 mg/dl, and lactate dehydrogenase (LDH) 746 U/L (additional laboratory values shown in Table 1). Her baseline hemoglobin was 14 g/dl, last assessed 2 years prior. The direct antiglobulin test (DAT) was negative for IgG and C3d, although an eluate prepared from the patient's red blood cells (RBCs) was reactive against all test cells. She was transfused a total of 7 units of RBCs, started on prednisone (oral, 1 mg/kg/day), and discharged home with a hemoglobin of 7.3 g/dl.

The patient continued to feel unwell, and 2 days after discharge from the other hospital (35 days after vaccination), she presented to Massachusetts General Hospital (MGH) with persistent fatigue and dyspnea on exertion. She had a history of central retinal vein occlusion and hypertension. Medications included aspirin (oral, 81 mg/day) and metoprolol succinate (oral, 100 mg/day); she remained on prednisone (oral, 1 mg/kg/day), initiated at the other hospital. The patient worked as an attorney and lived with her husband and three children. She had no personal or family history of autoimmune disease.

On admission to MGH, the patient was in mild distress. Vital signs were notable for temperature 96.9F, blood pressure 133/78 mm Hg, heart rate 79 beats/min, respiratory rate 18 breaths/min, and oxygen saturation 98% on room air. Laboratory values revealed hemoglobin 7.3 g/dl, MCV 109 fl, reticulocyte count >30%, total bilirubin 3.9 mg/dl, direct bilirubin 0.6 mg/dl, haptoglobin <10 mg/dl, and LDH 3095 U/L (additional laboratory values shown in Table 1). A peripheral blood film revealed numerous spherocytes, reticulocytes, and nucleated RBCs. Testing for HIV, HBV, EBV, CMV, tick-borne illnesses, influenza, and RSV was negative. ANA was weakly positive at 1:80. Serum immunofixation and serum-free light chains were within normal limits, and flow cytometry did not reveal a monoclonal B cell or T cell population.

Repeat DAT at MGH was again negative using routine polyspecific, IgG and C3 reagents in tube testing (Gamma-clone, Immucor, Norcross, GA). The plasma antibody screen was also negative (MTS gel cards, Ortho Clinical Diagnostics, Pamanó Beach, FL). Despite the negative DAT, antibody was eluted from the patient's

RBCs that demonstrated strong (3+) panreactivity when tested in the MTS gel system. A subsequent DAT performed using MTS gel cards—rather than Gamma-clone—was positive (2+) for IgG. Further testing demonstrated the presence of a cold autoantibody that was reactive (3+) at 37 degrees.

Prednisone (oral, 1 mg/kg per day) was continued upon admission to MGH. On hospital day 2, the patient received rituximab infusion (1000 mg). On hospital day 5, mycophenolate mofetil (MMF, oral, 1000 mg twice daily) was added (Figure 1). She received IV immune globulin (IVIG, 1 g/kg) on hospital days 7 and 8, as well as a second infusion of rituximab (1000 mg) on hospital day 11.

On day 8 of admission to MGH, the patient's LDH began to fall, and her hemoglobin stabilized at 8 g/dl after receiving an additional 6 units of RBCs (Figure 1). She was discharged home from MGH on hospital day 14 (49 days after receiving the vaccine). She was given two additional weekly doses of rituximab (1000 mg) as an outpatient, and corticosteroids and MMF were tapered. At an office visit 4 weeks after discharge from MGH and 11 weeks after receipt of the vaccine, her hemoglobin was 10.9 g/dl (no RBC transfusion in the preceding 3 weeks) and LDH was 317 U/L. A second dose of the vaccine was deferred. Testing for antibodies to the SARS-CoV-2 virus, performed 11 weeks after receipt of a single dose of the vaccine, was negative.

Autoimmune hemolytic anemia (AIHA) is a rare disorder characterized by the production of autoantibodies against RBC antigens, leading to hemolysis. AIHA can either be primary or occur secondary to rheumatologic conditions, lymphoproliferative disorders, infection, or medications.¹ In the present case, there was a strong clinical suspicion that the SARS-CoV-2 mRNA vaccine was the inciting event for the AIHA based on the chronology of events, the atypical autoantibody profile, and the absence of other causes.²⁻⁵

Diagnosis of AIHA is typically made based on clinical presentation, with a DAT confirming the presence of autoantibody on patient RBCs. False-negative DATs may occur if a patient makes an uncommon immunoglobulin isotype that is not recognized by the anti-human globulin (AHG) reagent used.⁶ In our case, the patient's initial DAT was negative when tested with Gamma-clone (Immucor) anti-IgG reagent, which does not recognize IgG4 or some types of IgG3, but positive when a reagent that detects all IgG isotypes (MTS gel system, Ortho) was used during the elution studies. These unusual findings suggest that the warm (IgG) autoantibody consisted of an atypical subtype of either IgG4 or IgG3. Workup also revealed the presence of a cold autoantibody with a thermal amplitude of 37°C, indicating that our patient may have

TABLE 1 Laboratory data

	Reference range, adult	Upon presentation to initial hospital ^a	Day of admission to MGH ^b	4 weeks after discharge from MGH ^c
Hematology				
Hemoglobin (g/dl)	12.0–16.0	7.1	7.3	10.9
Hematocrit (%)	36.0–46.0	19.5	21.9	31.6
Mean corpuscular volume (fl)	80–100	93	109	103.9
RBC distribution width (%)	11.5–14.5	20.7	31.5	15.9
White blood cell count (per/ μ l)	4500–13,000	15,000	19,000	8860
Platelets (per/ μ l)	150,000–400,000	204,000	142,000	238,000
Hemolysis Labs				
Reticulocyte (%)	0.7–2.5	15.5	>30.0	12.4
Total Bilirubin (mg/dl)	0.0–1.0	3.7	3.9	0.9
Direct Bilirubin (mg/dl)	0.0–0.4	0.8	0.6	-
Haptoglobin (mg/dl)	>10	<8	<10	<10
Lactate dehydrogenase (U/L)	100–210	746	3095	317
Alanine aminotransferase (U/L)	7–33	50	139	41
Aspartate aminotransferase (U/L)	9–32	40	181	23
Chemistry				
Sodium (mmol/L)	135–145	137	137	139
Potassium (mmol/L)	3.4–5.0	4.0	4.1	4.1
Chloride (mmol/L)	98–108	105	100	103
Bicarbonate (mmol/L)	23–32	26	24	26
BUN (mg/dl)	8–25	18	26	15
Creatinine (mg/dl)	0.60–1.50	0.70	0.77	0.62
Glucose (mg/dl)	70–110	95	150	147
Calcium (mg/dl)	8.5–10.5	9.0	9.0	8.5
Total protein (g/dl)	6.0–8.3	7.6	7.5	6.8
Albumin (g/dl)	3.3–5.0	4.0	4.5	4.1
Alkaline phosphatase (IU/L)	30–100	70	78	63

Note: Reference ranges are those used at Massachusetts General Hospital (MGH).

^a20 days after vaccination.

^b35 days after vaccination.

^c77 days after vaccination.

developed a mixed warm/cold AIHA, which comprise approximately 8% of cases of AIHA.⁷ It is difficult to discern the precise contribution of the cold autoantibody to this patient's illness given that the DAT did not detect complement; this could suggest a clinically irrelevant cold autoantibody or one that is potent and resulted in brisk hemolysis and a false-negative DAT.

There have been cases of AIHA reported following vaccination to other pathogens.⁸ Vaccines activate both the humoral and cell-mediated arms of the adaptive immune system by production of effector and memory cells. The mechanism underpinning vaccine-induced autoimmunity is not clear, but it may be due to

molecular mimicry and the development of auto-reactive T cells in a susceptible host.⁹

The cornerstone of treatment for AIHA is immunosuppression, with corticosteroids serving as first-line therapy in warm and mixed AIHA.¹ Second-line therapy for AIHA includes rituximab, a monoclonal antibody directed at CD20. In a meta-analysis of 409 patients with AIHA refractory to corticosteroids, the overall response rate to rituximab was 73%.¹⁰ Third-line agents include azathioprine, cyclosporine, cyclophosphamide, and MMF. IVIG may be used in combination with other treatments, especially in cases of severe hemolysis. Splenectomy remains an option as well, with an approximately

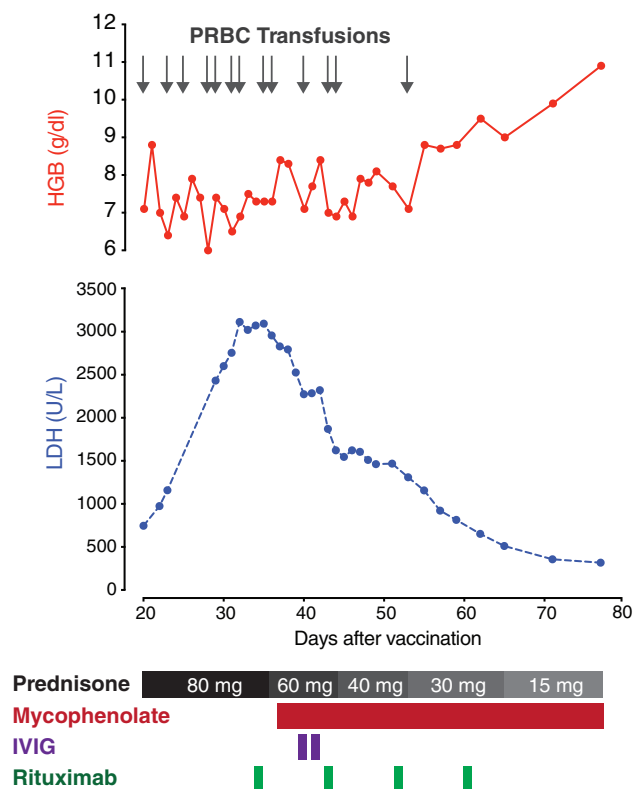


FIGURE 1 Hemoglobin and LDH trends, and response to treatment. The X-axis represents the number of days following receipt of the first dose of the SARS-CoV-2 mRNA-1273 vaccine. The Y-axes represent hemoglobin (above) and LDH concentrations (below). Gray arrows represent RBC transfusions. Black and gray rectangles indicate the prednisone taper. MMF, IVIG, and rituximab are depicted in red, purple, and green, respectively. IVIG, intravenous immune globulin; LDH, lactate dehydrogenase; MMF, mycophenolate mofetil; pRBCs, red blood cells [Color figure can be viewed at wileyonlinelibrary.com]

80% response rate, with 20%–50% of patients achieving sustained response.¹ Clinical trials are ongoing evaluating the safety and efficacy of novel treatments for AIHA, including the Syk inhibitor fostamatinib (clinicaltrials.gov NCT04138927), Bruton tyrosine kinase inhibitor ibrutinib (NCT04398459), and neonatal Fc receptors (NCT04119050).

Our patient developed a robust AIHA 1 week after receiving her first dose of the SARS-CoV-2 mRNA vaccine. Although causation cannot be proven, the temporal relationship in the absence of an alternative cause argues in favor of de novo vaccine-induced AIHA.

ACKNOWLEDGMENTS

The authors would like to thank Drs. Walter Dzik and Mandakolathur Murali for their help in the laboratory evaluation of this patient.

CONFLICT OF INTEREST

The authors have disclosed no conflicts of interest.

INFORMED CONSENT

The patient provided written consent for publication of this case.


DISCLOSURES

H. Al-Samkari declares the following universal disclosures: Research funding to institution (Agius, Dova, Amgen); Consultancy (Agius, Dova, Argenx, Rigel, Sobi, Novartis, Moderna). J. Lo has served as a consultant for Viiv Healthcare and Gilead Sciences. All other authors have no relevant conflicts of interest to disclose.

ORCID

Hanny Al-Samkari  <https://orcid.org/0000-0001-6175-1383>

Rebecca R. Saff  <https://orcid.org/0000-0002-4143-0985>

Rebecca Karp Leaf  <https://orcid.org/0000-0002-9978-8779>

REFERENCES

- Barcellini W, Fattizzo B. How I treat warm autoimmune hemolytic anemia. *Blood*. 2021;137(10):1283–94. <https://doi.org/10.1182/blood.2019003808>
- Advisory Committee on Immunization Practices (ACIP) COVID-19 VaST Work Group Technical Report – May 17, 2021. 2021.
- Lee EJ, Cines DB, Gernsheimer T, Kessler C, Michel M, Tarantino MD, et al. Thrombocytopenia following Pfizer and Moderna SARS-CoV-2 vaccination. *Am J Hematol*. 2021;96(5):534–7. <https://doi.org/10.1002/ajh.26132>
- Schultz NH, Sorvoll IH, Michelsen AE, Munthe LA, Lund-Johansen F, Ahlen MT, et al. Thrombosis and thrombocytopenia after ChAdOx1 nCoV-19 vaccination. *N Engl J Med*. 2021;384:2124–30. <https://doi.org/10.1056/NEJMoa2104882>
- Greinacher A, Thiele T, Warkentin TE, Weisser K, Kyrle PA, Eichinger S. Thrombotic thrombocytopenia after ChAdOx1 nCov-19 vaccination. *N Engl J Med*. 2021;384:2092–101. <https://doi.org/10.1056/NEJMoa2104840>
- Howie HL, Delaney M, Wang X, Er LS, Vidarsson G, Stegmann TC, et al. Serological blind spots for variants of human IgG3 and IgG4 by a commonly used anti-immunoglobulin reagent. *Transfusion*. 2016;56(12):2953–62. <https://doi.org/10.1111/trf.13812>
- Barcellini W, Fattizzo B, Zaninoni A, Radice T, Nichele I, Di Bona E, et al. Clinical heterogeneity and predictors of outcome in primary autoimmune hemolytic anemia: a GIMEMA study of 308 patients. *Blood*. 2014;124(19):2930–6. <https://doi.org/10.1182/blood-2014-06-583021>
- Seltsam A, Shukry-Schulz S, Salama A. Vaccination-associated immune hemolytic anemia in two children. *Transfusion*. 2000;40(8):907–9. <https://doi.org/10.1046/j.1537-2995.2000.40080907.x>

9. Segal Y, Shoenfeld Y. Vaccine-induced autoimmunity: the role of molecular mimicry and immune crossreaction. *Cell Mol Immunol.* 2018;15(6):586–94. <https://doi.org/10.1038/cmi.2017.151>
10. Reynaud Q, Durieu I, Dutertre M, Ledochowski S, Durupt S, Michallet A-S, et al. Efficacy and safety of rituximab in autoimmune hemolytic anemia: a meta-analysis of 21 studies. *Autoimmun Rev.* 2015;14(4):304–13. <https://doi.org/10.1016/j.autrev.2014.11.014>

How to cite this article: Gadi SRV, Brunker PAR, Al-Samkari H, Sykes DB, Saff RR, Lo J, et al. Severe autoimmune hemolytic anemia following receipt of SARS-CoV-2 mRNA vaccine. *Transfusion.* 2021;61:3267–71. <https://doi.org/10.1111/trf.16672>