

LETTERS TO THE EDITOR

Post-Covid cutaneous small-vessel vasculitis with features of Koebnerization

To The Editor,

COVID-19 has been associated with a wide gamut of cutaneous manifestations, some of which are found to develop during the course of the disease, and some of them become clinically apparent, following recovery. Vasculitic lesions have been reported to develop in patients with COVID-19 infection. We hereby report an unusual case of cutaneous small-vessel vasculitis (CSVV), along with features of Koebnerization.

A 30-year-old male presented with a 2-day history of asymptomatic rashes on his legs. He was tested positive for COVID-19 two weeks back and remained in home isolation. There was no history of fever, cough, joint pain or other systemic symptoms. The only symptom he had was loss of smell. He tested negative on the 14th day and noticed the rashes a day later. The only medications he took were multivitamins. The patient had no other comorbidities and was not on any other medications. Past history was unremarkable.

Physical examination revealed non-blanchable erythematous papules and plaques over his thighs and legs (Figure 1a). The lesions over the legs were present in a linear arrangement (Figure 1b), consistent with the appearance of Koebner phenomenon (KP). Systemic examination was unremarkable. Routine blood tests and

urine workup revealed no abnormalities. He was prescribed a topical corticosteroid and an oral antihistamine. Biopsy from the lesions followed by histopathological examination showed features of perivascular neutrophilic infiltrate and fibrinoid degeneration (Figure 1c). A diagnosis of cutaneous small-vessel vasculitis was done, and the patient was prescribed topical corticosteroids.

The purpuric “vasculitic” pattern of skin lesions with histological findings of leukocytoclastic vasculitis has been described in COVID-19 cases along with other patterns of cutaneous manifestations.¹⁻³ The underlying mechanism is thought to be direct endothelial injury by the pathogen or by the dysregulated host immune response in response to COVID-19.⁴ The Koebner's phenomenon is rare in vasculitis. The underlying mechanism of KP in CSVV is poorly understood. One of them is that immune complexes aggregate in vessels due to local inflammation in response to scratching or local trauma, leading to recurring lesions.⁵ Besides, it has been hypothesized that elevated levels of tryptase following a trauma may be responsible. Few authors also believe that microcirculatory stasis leading to prolonged pressure, mast cell activation due to scratching could be possible reasons behind KP in vasculitis. In our case, the patient had an underlying COVID-19 infection, which could be responsible for this

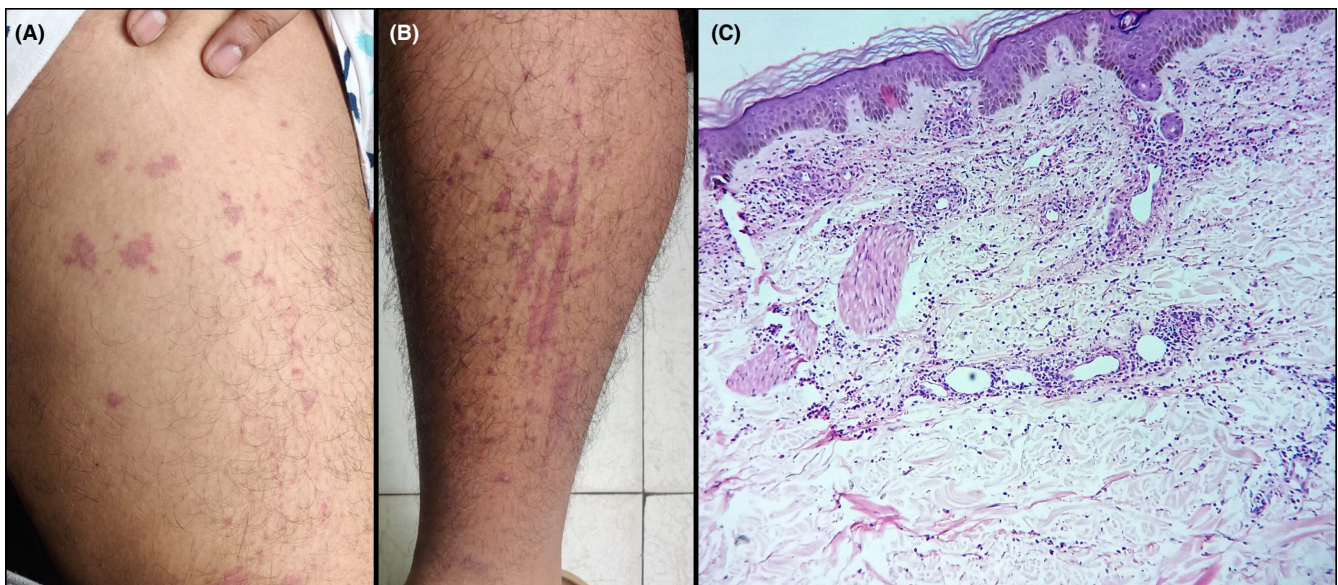


FIGURE 1 A, Non-blanchable erythematous papules and plaques. B, Note the presence of Koebnerization. C, Photomicrograph showing perivascular neutrophilic infiltrate and fibrinoid degeneration (Hematoxylin and Eosin, 100X)

unusual presentation. Further research is warranted to establish the role of COVID-19 behind the causation (if any).^{6,7,8,9}

Our case of post-Covid cutaneous small-vessel vasculitis with features of Koebnerization highlights the fact that COVID-19 may be associated with cutaneous manifestations even after recovery.

DISCLAIMER

"We confirm that the manuscript has been read and approved by all the authors that the requirements for authorship as stated earlier in this document have been met and that each author believes that the manuscript represents honest work"

KEYWORDS

Koebnerization, post-Covid, vasculitis

CONFLICT OF INTEREST

None.

AUTHOR'S CONTRIBUTION


All the authors have contributed equally to the manuscript.

ETHICS STATEMENT

Ethics Committee approval obtained.

DATA AVAILABILITY STATEMENT

The data that support the findings of this study are available from the corresponding author upon reasonable request.

Farhat Fatima MD¹
Piyush Kumar MD²
Shouvik Ghosh MD³
Anupam Das MD³ 

¹Department of Dermatology, Medical College and Hospital, Kolkata, India

²Department of Dermatology, Katihar Medical College, Bihar, India

³Department of Dermatology, KPC Medical College and Hospital, Kolkata, India

Correspondence

Anupam Das, Department of Dermatology, KPC Medical College and Hospital, Kolkata, West Bengal, India.
Email: anupamdasdr@gmail.com

ORCID

Anupam Das  <https://orcid.org/0000-0003-0841-9597>

REFERENCES

1. Caputo V, Schroeder J, Rongioletti F. A generalized purpuric eruption with histopathologic features of leucocytoclastic vasculitis in a patient severely ill with COVID-19. *J Eur Acad Dermatol Venereol.* 2020;34:e579-e581.
2. Negri S, Guadagno A, Greco M, Parodi A, Burlando M. An unusual case of bullous haemorrhagic vasculitis in a COVID-19 patient. *J Eur Acad Dermatol Venereol.* 2020;34:e675-e676.
3. García-Gil MF, Monte Serrano J, García García M, Barra Borao V, Matovelle Ochoa C, Ramirez-Lluch M, et al. Acral purpuric lesions associated with coagulation disorders. *Int J Dermatol.* during the COVID-19 pandemic. 2020;59:1151-1152.
4. Panda M, Dash S, Behera B, Sil A. Dermatological manifestations associated with COVID-19 infection. *Indian J Dermatol.* 2021;66:237-245.
5. De D, Dogra S, Kanwar AJ. Isomorphic response of Koebner in a patient with cutaneous small vessel vasculitis. *J Eur Acad Dermatol Venereol.* 2008;22:1125-1126.
6. Kassam F, Nurmohamed S, Haber RM. Koebner phenomenon in leukocytoclastic vasculitis: A case report and an updated review of the literature. *SAGE Open Med Case Rep.* 2019;7:2050313X1985035.
7. Sharma S, Chandrasekaran V, Krishnamurthy S, et al. Koebner's phenomenon in childhood Henoch-Schonlein purpura: a report of two cases. *Pediatr Dermatol.* 2016;33:e249-e251.
8. Nayak SU, Shenoi SD, Pai BS, et al. Henoch-Schonlein purpura: yet another disease manifesting the Koebner phenomenon. *Indian J Dermatol Venereol Leprol.* 2013;79:135.

How to cite this article: Fatima F, Kumar P, Ghosh S, Das A. Post-Covid cutaneous small-vessel vasculitis with features of Koebnerization. *J Cosmet Dermatol.* 2022;21:2307-2308. <https://doi.org/10.1111/jocd.14443>