

Early Experience of High-dose Intravenous *Mycobacterium w* in Critically Ill Patients of COVID-19

Parth Sudhendu Patel¹, Sudhendu Patel², Vidhi Shah³, Varsha Aswani⁴, Mahendra Narwaria⁵

ABSTRACT

Background: Immune dysregulation is one of the main reasons for mortality and morbidity in coronavirus disease 2019 (COVID-19). *Mycobacterium w* (Mw) is recently approved for gram-negative sepsis. Moreover, it is also found effective in COVID-19 patients in previous studies. The traditional route of administration for Mw is intradermal, which has a limitation of administering 0.1 mL per injection and local injection site reaction. Intravenous (IV) administration of Mw has not been explored in COVID-19. We report the retrospective analysis of six critically ill COVID-19 patients who received Mw (IV).

Patients and methods: At baseline, all patients in this case series required O₂ supplementation, and their inflammatory biomarkers were elevated. All patients received 0.6 mL Mw (high-dose) in normal saline along with the standard-of-care treatment.

Results: After Mw administration, gradual improvement in O₂ requirement was observed and patients were discharged from the hospital with no mortality. A reduction in mean C-reactive protein (CRP) (51.48–18.52 mg/dL), interleukin-6 (IL-6) (260.22–14.47 pg/mL), and FiO₂ (81.67–43.33) was also observed. No side effects were observed with the use of Mw by IV route.

Conclusion: Use of 0.6 mL Mw by IV route in this case series was associated with decreased O₂ supplementation without any side effects in critically ill patients of COVID-19.

Keywords: COVID-19, Immune dysregulation, Immunomodulator, *Mycobacterium w*.

Indian Journal of Critical Care Medicine (2021); 10.5005/jp-journals-10071-23963

INTRODUCTION

Coronavirus disease 2019 (COVID-19) pneumonia is associated with significant mortality and morbidity particularly in critically ill patients requiring O₂ supplementation.¹ Morbidity and mortality associated with sepsis (bacterial as well as viral, including COVID-19) is due to infection-induced immune dysregulation (impaired immune homeostasis) rather than infection per se.^{2,3} Establishment of immune homeostasis is one of the suggested approaches to reduce the morbidity and mortality associated with COVID-19, especially in critically ill patients.⁴

Mycobacterium w (Mw) is an immunomodulator approved for the treatment of gram-negative sepsis,⁵ which helps in reestablishing immune homeostasis. It also reduces the mortality associated with gram-negative sepsis.⁶ The efficacy of Mw in gram-negative sepsis is proportionate to the administered dose of Mw. The recommended dose of Mw for gram-negative sepsis is 0.3 mL daily for 3 days. And 0.3 mL of Mw needs to be administered as three intradermal injections of 0.1 mL each, as intradermal route has a limitation of dose per site of 0.1 mL. Like Bacille Calmette-Guerin, intradermal Mw is also associated with local site reaction. Immune dysregulation seen in gram-negative sepsis and COVID-19 is identical.⁷ The use of intradermal Mw in the management of COVID-19 is also associated with improved outcomes.^{8–10}

Intravenous (IV) administration of mycobacterial immunomodulator is associated with better immune response in lung parenchyma compared to intradermal administration.¹¹ Administration of Mw by the IV route is also described to be safe and effective.¹² IV route of administration of Mw offers (i) ease of administration as it can be given through the secured ongoing IV line, (ii) ability to give desired additional amount as a single injection, and (iii) delivery of the drug to the lungs. Intradermal

¹Department of Critical Care, Bombay Hospital, Institute of Medical Sciences, Ahmedabad, Gujarat, India

^{2–3}Department of Medicine, Sterling Hospital, Ahmedabad, Gujarat, India

⁴Department of Surgery, VS Hospital, Ahmedabad, Gujarat, India

⁵Department of Surgery, Asian Bariatrics Hospital, Ahmedabad, Gujarat, India

Corresponding Author: Parth Sudhendu Patel, Department of Critical Care, Bombay Hospital, Institute of Medical Sciences, Ahmedabad, Gujarat, India, Phone: +91-079-26854876, e-mail: parthtonypatel@gmail.com

How to cite this article: Patel PS, Patel S, Shah V, Aswani V, Narwaria M. Early Experience of High-dose Intravenous *Mycobacterium w* in Critically Ill Patients of COVID-19. *Indian J Crit Care Med* 2021;25(9):1066–1068.

Source of support: Nil

Conflict of interest: None

administration needs additional training/skill that is not required for IV administration in the intensive care unit setting. The highest dose administered so far by intradermal route is 0.3 mL/day compared to a dose as high as 5.0 mL/day by IV route.^{12,13} IV administration of Mw in the management of gram-negative sepsis or COVID-19 is not known. In this case series, we present retrospective analysis of the administration of 0.6 mL/day of Mw by IV route in the critically ill patients of COVID-19.

CASE DESCRIPTION

This case series describes the clinical course of six critically ill patients (three male and three female) treated with IV Mw. All

Table 1: Baseline characteristics

Patients	1	2	3	4	5	6
Age/sex	85/F	49/F	54/M	24/M	53/F	73/M
Ct value	26	32	24	15	25	20
Comorbidities	Diabetes mellitus, hypertension	Morbid obesity	Splenic vein thrombosis	—	Diabetes mellitus	CABG
O ₂ requirement	NIV	NIV	NIV	NC	NRBM	NIV
Symptoms	Fever, breathlessness, dyspnea					

Ct, cycle threshold; NIV, noninvasive ventilation; NC, nasal cannula; NRBM, non-rebreathing mask; CABG, coronary artery bypass grafting

Table 2: Changes following IV Mw for 3 days along with standard treatment

Patients	1		2		3		4		5		6	
	Pre	Post	Pre	Post	Pre	Post	Pre	Post	Pre	Post	Pre	Post
O ₂ (Fi)	95	75	100	70	70	55	75	RA	80	RA	70	60
Mode of O ₂ supplement	NIV	NIV	NIV	HFNC	NIV	NRBM	NC	RA	NRBM	RA	NIV	NRBM
CRP	28	51	73	7	78	9	45.78	7.8	14.1	13.3	70	23
IL6	941	19	10.8	NA	16.2	5.6	11.7	NA	36	23	47.7	10.3

NIV, noninvasive ventilation; HFNC, high-flow nasal cannula; NC, nasal cannula; NRBM, non-rebreathing mask; RA, room air

the patients had COVID-19, confirmed by reverse transcriptase-polymerase chain reaction (RT-PCR) test, and were receiving supplemental O₂. All but one patient had associated comorbidities like diabetes mellitus, hypertension, obesity, history of CABG, and splenic vein thrombosis (Table 1). Baseline mean C-reactive protein (CRP) was 51.48 mg/dL. Supplemental O₂ was provided by noninvasive mechanical ventilation to four and via non-rebreathing mask or nasal cannula to the others. All patients received inj remdesivir, methylprednisolone, and antibiotics (doxycycline or azithromycin) as per institutional protocol along with Mw (Sepsivac, Cadila Pharmaceuticals, Ahmedabad, India). Mw was administered as 0.6 mL of Mw per day diluted with 100 mL of normal saline and was administered for three consecutive days through IV line secured for the administration of medications within 1 to 2 hours of administration of glucocorticoids.

Mw was well-tolerated in all patients, and no adverse event was seen. All the patients improved and were discharged from the hospital. Following the administration of Mw for 3 days, there was an improvement in FiO₂ (Fig. 1) in all and a reduction in O₂ requirement in all but one patient. Reduction in supplemental O₂ requirement device (graded as per the increasing requirement of O₂ supplementation device; patient on room air being grade 0 and requirement of mechanical ventilation being grade 5) was associated with a decrease in CRP (Table 2; Fig. 2). The patient with no change in supplemental O₂ requirement had an increase in CRP. Interleukin-6 (IL-6) reduction was seen in all patients. The mean change in CRP, IL-6, and FiO₂ was from 51.48 to 18.52 mg/dL ($p = 0.079$), 260.22 to 14.47 pg/mL ($p = 0.355$), 81.67 to 43.33 ($p = 0.029$), respectively, on day 4 after the administration of Mw for three consecutive days.

DISCUSSION

Spike—S protein-induced upregulation of endosomal TLRs—is responsible for immune dysregulation seen in COVID-19. Mw

is known to induce TLR2 (Th1 response) while downregulating upregulated endosomal TLRs to reestablish immune homeostasis, thereby improving outcomes in the management of Gram-negative sepsis.^{6,9,14} Mw is also known to improve CD4 count in immunocompromised individuals with lower CD4 count.¹⁵ Conventional route of administration of Mw is the intradermal route. In this study, the IV route of administration allowed ease of administration as well as higher dose (0.6 mL/day instead of 0.3 mL/day). This was found to be safe. It was also associated with improvement in lung function as indicated by a change in FiO₂ and mode of O₂ supplementation.

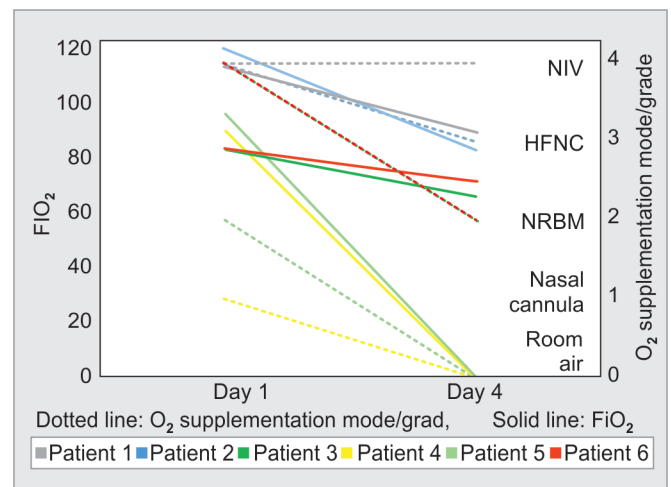


Fig. 1: Changes in O₂ requirement status after the administration of Mw 0.6 mL for three consecutive days. Grade 0—room air (RA); grade 1—nasal cannula (NC); grade 2—non-rebreathing mask ventilation (NRBM); grade 3—high-flow nasal cannula (HFNC); grade 4—noninvasive ventilation (NIV); grade 5—mechanical ventilation

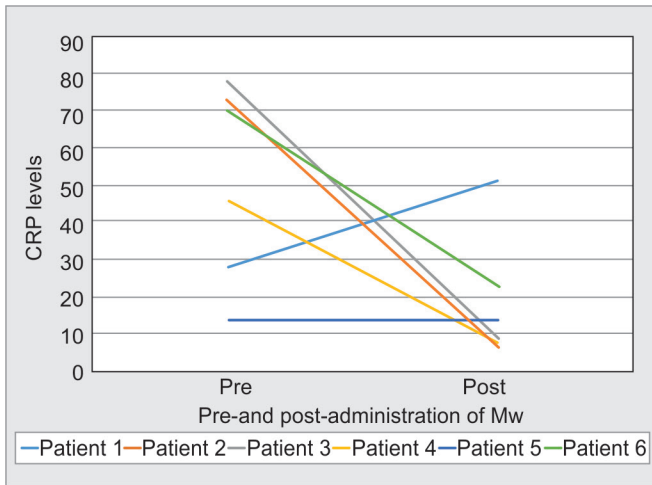


Fig. 2: Change in CRP after the administration of Mw

The observed improvement in O₂ requirement in patients could be attributed to the improvement in the pulmonary pathology. This was also evident by a decrease in the mode of O₂ supplementation.

Safety of addition of 0.6 mL of Mw to standard of treatment observed in this case series is in accordance with previous reports.^{12,13} It also paves way for evaluating Mw via the IV route in a larger study.

ORCID

Parth Sudhendu Patel <https://orcid.org/0000-0002-0061-5721>

Varsha Aswani <https://orcid.org/0000-0002-8495-0227>

Mahendra Narwaria <https://orcid.org/0000-0002-0611-1567>

REFERENCES

1. Al-Rifai RH, Acuna J, Al Hossany FI, Aden B, Al Memari SA, Al Mazrouei SK, et al. Epidemiological characterization of symptomatic and asymptomatic COVID-19 cases and positivity in subsequent RT-PCR tests in the United Arab Emirates. medRxiv 2020.09.23.20200030. DOI: 10.1101/2020.09.23.20200030.

2. Ren C, Yao RQ, Ren D, Li Y, Feng YW, Yao YM. Comparison of clinical laboratory tests between bacterial sepsis and SARS-CoV-2-associated viral sepsis. Mil Med Res 2020;7(1):36. DOI: 10.1186/s40779-020-00267-3.
3. Yazdanpanah F, Hamblin MR, Rezaei N. The immune system and COVID-19: friend or foe? Life Sci 2020;256:117900. DOI: 10.1016/j.lfs.2020.117900.
4. Yang L, Liu S, Liu J, Zhang Z, Wan X, Huang B, et al. COVID-19: immunopathogenesis and Immunotherapeutics. Signal Transduct Target Ther 2020;5(1):128. DOI: 10.1038/s41392-020-00243-2.
5. Sepsivac [package insert]. Ahmedabad, India: Cadila Pharmaceuticals Limited; 2019.
6. Sehgal IS, Basumatary NM, Dhoooria S, Choudhuri R, Shah C, Agarwal R, et al. A randomized trial of *Mycobacterium w* in severe presumed gram-negative sepsis. Chest 2021;S0012-3692(21)00680-2. DOI: 10.1016/j.chest.2021.03.062.
7. López-Collazo E, Avendaño-Ortiz J, Martín-Quirós A, Aguirre LA. Immune response and COVID-19: a mirror image of sepsis. Int J Biol Sci 2020;16(14):2479-2489. DOI: 10.7150/ijbs.48400.
8. Sehgal IS, Bhalla A, Puri GD, Yaddanapudi LN, Singh M, Malhotra P, et al. Safety of an immunomodulator *Mycobacterium w* in COVID-19. Lung India 2020;37(3):279-281. DOI: 10.4103/lungindia.lungindia_242_20.
9. Sehgal IS, Guleria R, Singh S, Siddiqui MS, Agarwal R. A randomised trial of *Mycobacterium w* in critically ill patients with COVID-19: ARMY-1. ERJ Open Res 2021;7(2):00059-2021. DOI: 10.1183/23120541.00059-2021.
10. Ingale A, Ingale F, Kunwar B, Ahmed S, Salvi K, Chavan V, et al. Role of *Mycobacterium w* for the treatment of COVID-19: an observational study. J Assoc Physicians India 2021;69(1):19-22. <https://www.japi.org/x2747444/role-of-mycobacterium-w-for-the-treatment-of-covid-19-an-observational-study>
11. Darrah PA, Zeppa JJ, Maiello P, Hackney JA, Wadsworth II MH, Hughes TK, et al. Prevention of tuberculosis in macaques after intravenous BCG immunization. Nature 2020;577:95-102. DOI: 10.1038/s41586-019-1817-8.
12. Pant MC, Verma VP. Intravenous Cadi05: phase I single dose study. J Clin Oncol 2008;26(15_suppl):14019-14019. DOI: 10.1200/jco.2008.26.15_suppl.14019.
13. Sudhalkar A, Khamar A, Khamar B. Outcomes of toll-like receptors' antagonism in steroid-resistant optic neuritis; a pilot study. Graefes Arch Clin Exp Ophthalmol 2012;250(6):871-877. DOI: 10.1007/s00417-011-1896-1.
14. Desai NM, Khamar BM. Immunotherapy for tuberculous pericarditis. N Engl J Med 2014;371(26):2533-2534. DOI: 10.1056/NEJMc1413185.
15. Kharkar R. Immune recovery in HIV with *Mycobacterium w*. J Indian Med Assoc 2002;100(9):578-579. PMID: 12455393.