

## CLINICAL REPORT

# Novel compound heterozygous *STN1* variants are associated with Coats Plus syndrome

Tanvi Acharya<sup>1</sup>  | Helen V. Firth<sup>2</sup> | Shilpa Dugar<sup>3</sup> | Tassos Grammatikopoulos<sup>3</sup> | Luis Seabra<sup>4</sup> | Angharad Walters<sup>5</sup> | Yanick J. Crow<sup>6</sup> | Alasdair P. J. Parker<sup>1</sup>

<sup>1</sup>School of Clinical Medicine, Cambridge University, Cambridge, UK

<sup>2</sup>Department of Clinical Genetics, Addenbrooke's Hospital, Cambridge, UK

<sup>3</sup>Paediatric Liver, GI and Nutrition Centre and Mowat Labs, King's College Hospital NHS Foundation Trust, London, UK

<sup>4</sup>Laboratory of Neurogenetics and Neuroinflammation, Institut Imagine, Paris, France

<sup>5</sup>Cambridgeshire Community Services, Brookfield Hospital, Cambridge, UK

<sup>6</sup>Centre for Genomic and Experimental Medicine, MRC Institute of Genetics and Molecular Medicine, University of Edinburgh, Edinburgh, UK

## Correspondence

Alasdair P. J. Parker, Department of Paediatric Neuroscience, Addenbrooke's Hospital, Cambridge, UK.  
Email: [alasdair.parker@addenbrookes.nhs.uk](mailto:alasdair.parker@addenbrookes.nhs.uk)

## Funding information

Wellcome

## Abstract

**Aim:** Coats plus syndrome (CP) is a rare autosomal recessive disorder, characterised by retinal telangiectasia exudates (Coats disease), leukodystrophy, distinctive intracranial calcification and cysts, as well as extra-neurological features including abnormal vasculature of the gastrointestinal tract, portal hypertension and osteopenia with a tendency to fractures. CP most frequently occurs due to loss-of-function mutations in *CTCI*. The encoded protein CTC1 constitutes part of the CST (CTC1-STN1-TEN1) complex, and three patients have been described with CP due to biallelic mutations in *STN1*. Together with the identification of homozygosity for a specific loss-of-function mutation in *POT1* in a sibling pair, these observations highlight a defect in the maintenance of telomere integrity as the cause of CP, although the precise mechanism leading to the micro-vasculopathy seen at a pathological level remains unclear. Here, we present the investigation of a fourth child who presented to us with retinal exudates, intracranial calcifications and developmental delay, in keeping with a diagnosis of CP, and later went on to develop pancytopenia and gastrointestinal bleeding. Genome sequencing revealed compound heterozygous variants in *STN1* as the likely genetic cause of CP in this present case.

**Methods:** We assessed the phenotype to be CP and undertook targeted sequencing.

**Results:** Whilst sequencing of *CTCI* and *POT1* was normal, we identified novel compound heterozygous variants in *STN1* (previous gene symbol *OBFC1*): one loss-of-function—c.894dup (p.(Asp299Argfs\*58)); and one missense—c.707T>C (p.(Leu236Pro)).

**Conclusion:** Given the clinical phenotype and identified variants we suggest that this is only the fourth patient reported to date with CP due to mutations in *STN1*.

## KEY WORDS

coats plus, leukodystrophy, stn1

[Correction added on June 19, 2021, after first Online publication: The corresponding author affiliation has been modified.]

This is an open access article under the terms of the Creative Commons Attribution-NonCommercial-NoDerivs License, which permits use and distribution in any medium, provided the original work is properly cited, the use is non-commercial and no modifications or adaptations are made.

© 2021 The Authors. *Molecular Genetics & Genomic Medicine* published by Wiley Periodicals LLC.

## 1 | INTRODUCTION

Coats plus (CP) is a pleiotropic disorder affecting the brain, bone and gastrointestinal tract, with retinal telangiectasia and exudates (Coats disease), a neuroradiological triad of cerebral white matter disease (leukoencephalopathy), intracranial calcifications and cysts (LCC) and extra-neurological manifestations such as osteopenia, life-limiting gastro-intestinal bleeding and portal hypertension caused by the development of vascular ectasias in the stomach/small intestine and liver fibrosis (Crow et al., 2004; Kapuria et al., 2019; Tolmie et al., 1988).

CP has an overlapping phenotype with LCC (also known as Labrune syndrome) which is indistinguishable from CP in terms of the associated neuroradiology, but does not include the extra-neurological manifestations of CP (Labrune et al., 1996). Of note, LCC is an apparently genetically homogeneous disorder due to mutations in *SNORD118* (Jenkinson et al., 2016). Some patients with CP display hair and bone marrow failure—resembling the phenotype of other telomeropathies, including dyskeratosis congenita, Hoyeraal–Hreidarsson syndrome and Revesz syndrome (Keller et al., 2012).

CP has been associated with mutations in any of *CTC1* (Anderson et al., 2012; Polvi et al., 2012), *POT1* (Takai et al., 2016) and, in three cases, *STN1* (Simon et al., 2016; Passi et al., 2020). The identification of biallelic mutations in *CTC1* in individuals with CP has focussed attention on the CST (*CTC1-STN1-TEN1*) complex as a cause of human disease. This conserved trimeric complex has three recognised functions; binding the telomeric G-strand, promoting synthesis of the C-strand and inhibiting telomerase-mediated telomere elongation. It is thought that disruption of the CST complex affects telomere length and telomeric C-strand synthesis, leading to elongated 3' overhangs (Stewart et al., 2012). This means that the role of telomeres as nucleoprotein complexes in the protection of chromosome ends from degradation, activation of the DNA damage response and end-to-end fusion are compromised. The principal role of *STN1* is to interact and stimulate the activity of DNA polymerase  $\alpha$ -primase, the only enzyme known to initiate DNA replication in eukaryotic cells (Stewart et al., 2012). Functional studies have shown that stable knockdown of *STN1* increases the incidence of anaphase bridges and multi-telomeric signals, indicating genomic and telomeric instability (Goulian et al., 1990).

## 2 | CASE STUDY

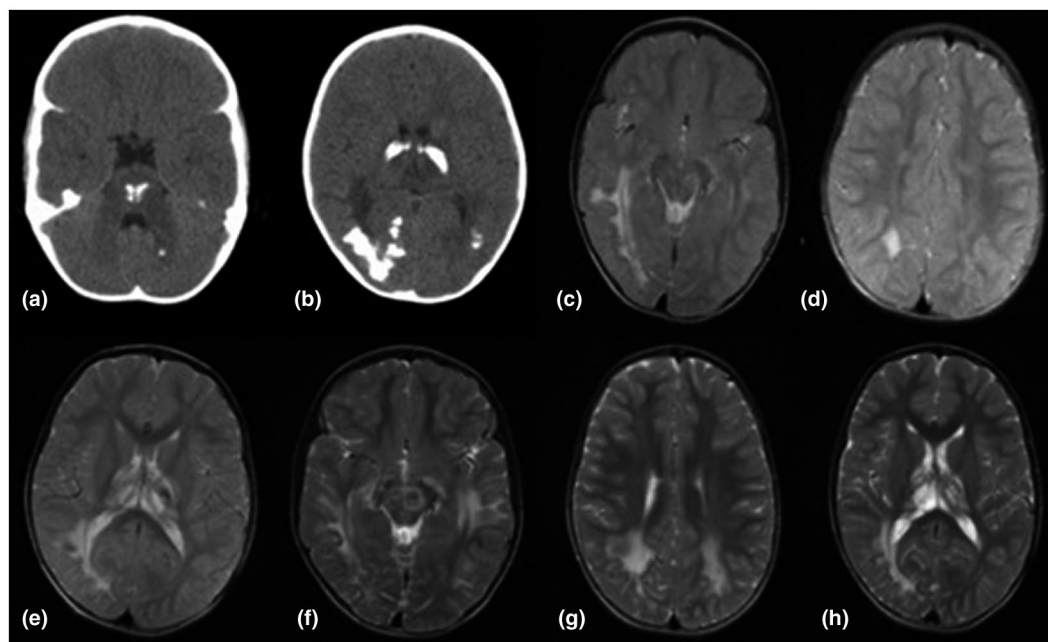
The proband was a 9-year-old Caucasian male. Concerns first arose due to intrauterine growth restriction on a 20-week scan and at 27 weeks gestation his mother underwent

an emergency Caesarean section because of oligohydramnios. He was born weighing 600 g, required ventilation for 2 weeks and remained hospitalised for 3 months thereafter, during which time he was naso-gastrically and subsequently percutaneous endoscopic gastrostomy (PEG) fed. At the age of 30 weeks he was considered to have features of stage 3 retinopathy of prematurity, which was treated with laser therapy in both eyes. He developed conjugated hyperbilirubinaemia, attributed to his prematurity, which cleared after a few weeks. Abdominal ultrasound showed mild hepatomegaly.

His developmental milestones were at the upper end of the normal range, lifting his head at age 3 months and walking with support at 15 months of age after his expected delivery date. He had delayed speech acquisition. Cranial MRI at the age of 3 years revealed asymmetric white matter disease particularly involving the right occipital and parietal lobes, with signal change/swelling in the pons and dense calcifications (Figure 1). These features were in keeping with the radiological triad of both CP and LCC. Other considerations, such as infection and metabolic causes for the patient's symptoms, were excluded.

His height and weight followed the 0.4th centile, with a head circumference 3.5SD below the mean. At age of 5 years he suffered a vitreous haemorrhage in the left eye requiring vitrectomy. At 6 years of age abdominal ultrasound revealed hepatosplenomegaly with elevated transaminases and no cholestasis. Liver histology showed intact lobular architecture without fibrosis, but small portal tracts lacking biliary structures. Full blood count revealed chronic thrombocytopenia and pancytopenia, with a white blood cell count of 2.1 thousands/ $\mu$ L, red blood cell count of 2.7 thousands/ $\mu$ L, haemoglobin of 9.7 g/dL and platelet count of  $35 \times 10^9$ /L. Furthermore, bone marrow aspirate and trephine revealed hypocellularity, with a reduction in the myeloid lineage.

By this time his neurological status had deteriorated, subsequently affecting his speech and with emerging dystonic posturing of the right leg / arm. Cerebral MRI scan showed progression of areas of focal intensity including the left parietal and occipital lobes, along with volume loss of the thalami and brainstem (Figure 1). He experienced episodes of haematemesis. Aged 8 years, esophago-gastro-duodenoscopy revealed grade 2–3 esophageal varices requiring esophageal band ligation (EBL). He was enrolled onto a secondary prophylaxis programme for his portal hypertension (PHT). Proctoscopy was normal. No telangiectasia-like lesions were identified in the examined GI track. His liver ultrasound and Fibroscan showed evolution of liver disease, with features of liver fibrosis and hypersplenism. The oesophageal varices responded to EBL. Suspected low volume non-variceal GI bleeding was managed with tranexamic acid.



**FIGURE 1** Neuroimaging of patient. CT images of patient aged 3 years demonstrating pontine (a) and cerebral white matter/thalamic (b) calcification. T2-weighted axial MRI images of patient aged 3 years showing focal areas of increased intensity of the thalami with calcification artefact (c) and right>left white matter (c,d,e). T2-weighted axial MRI images of patient aged 6 years showing further development of the focal areas of increased intensity on T2-weighted axial images of the pons with calcification artefact (f) and white matter bilaterally (g,h)

**TABLE 1** Comparison of clinical features of previously documented cases with *STN1* mutation and the present case

Features	Patient 1	Patient 2	Patient 3	Present study
Origin	Palestine	Palestine	Indian	United Kingdom
Gender	Female	Male	Female	Male
Age at presentation	12 years	19 years	15 days	3 years
IUGR/growth retardation	Yes	Yes	Yes	Yes
GI bleed	Yes	Yes	Yes	Yes
Hepatic dysfunction	Yes	Yes	—	Yes
CNS	Dystonia, ataxia	—	Dystonia	Dystonia
Eye	—	Retinal telangiectasia	Retinal lesions	Retinal lesions
Haematological abnormality	Pancytopenia	Pancytopenia	Pancytopenia	Pancytopenia
Outcome	Died at 16 years after GI bleed	Improved on thalidomide treatment	Poorly sustained improvement on hormonal therapy	Died at 9 years due to uncontrollable gastrointestinal bleeding and liver failure

Unfortunately, his haemoglobin continued to drop to 8.8 g/dL and liver ultrasound showed marked increase in ascites with an increase in splenomegaly from 13.8 cm to 22.0 cm. Following a large rectal bleed and intolerance of feeds, he was managed palliatively, and died peacefully at age 9. Liver failure and gastrointestinal bleeding were cited as the main cause of death (Table 1).

### 3 | GENETIC EVALUATION

Given the CP phenotype, Sanger sequencing of *CTCI* was undertaken, but no pathological variants were identified. *POT1* and *SNORD118* were also examined and sequences found to be wild type. In contrast, sequencing of *STN1* (previous gene symbol *OBFC1*) identified two

rare variants; c.707T>C, p.(Leu236Pro) and c.894dup, p.(Asp299Argfs\*58) in exons 7 and 9, respectively (Figure 2) —DECIPHER reference number 283482 (Firth et al., 2009; Figure 3 and 4).

Parental testing confirmed that the variants were biallelic. Of note, the p.(Leu236Pro) is not recorded in more than 250,000 control alleles on gnomAD, whilst the p.(Asp299Argfs\*58) has been observed only once in 251,430

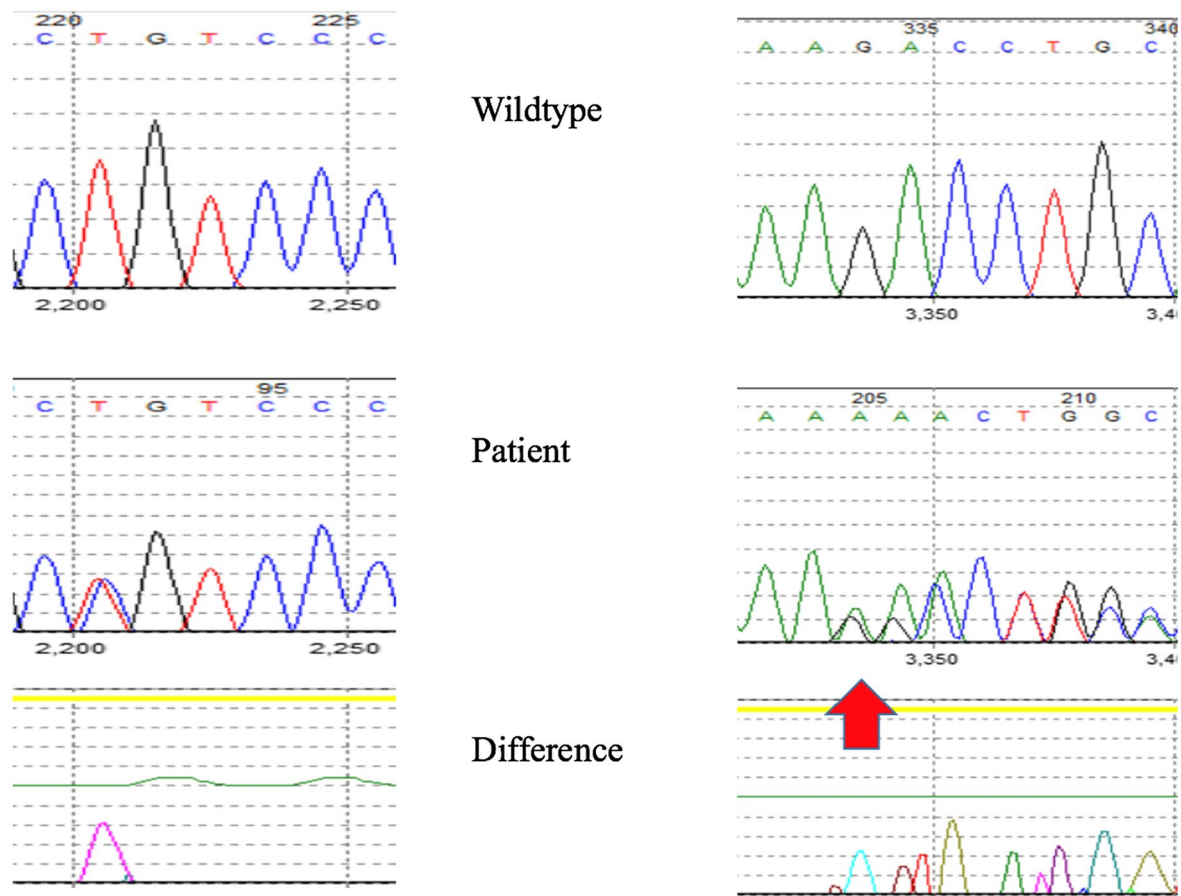


FIGURE 2 Sanger sequencing. c.707T>C variant with amino acid substitution and c.894dup variant with sequence change downstream

STN1: Q9H668 368aa (protein shown matches variant transcript)

Links Settings

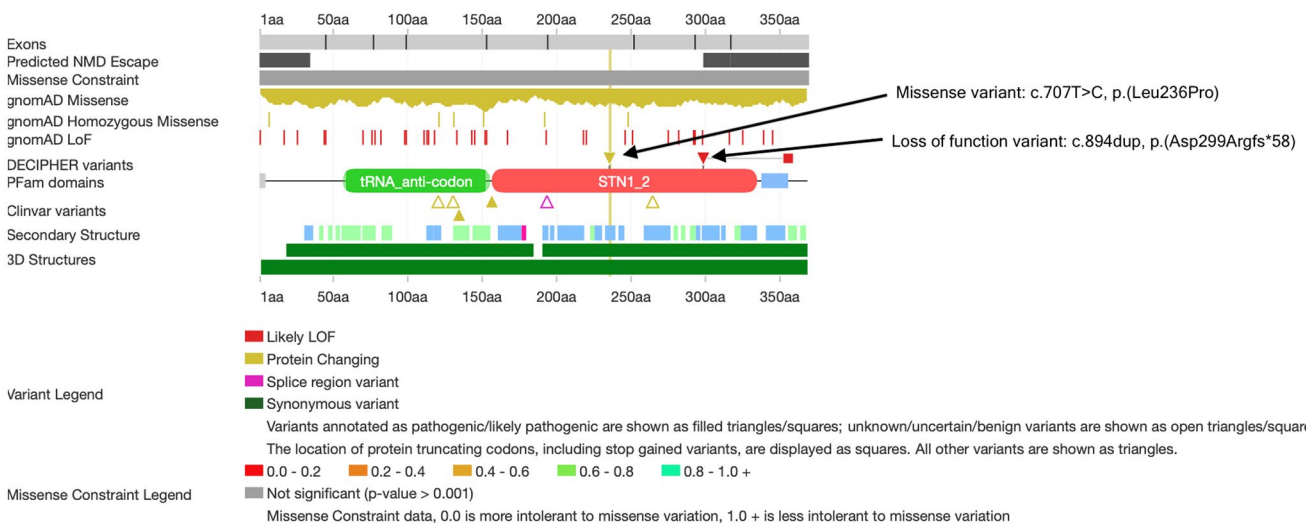
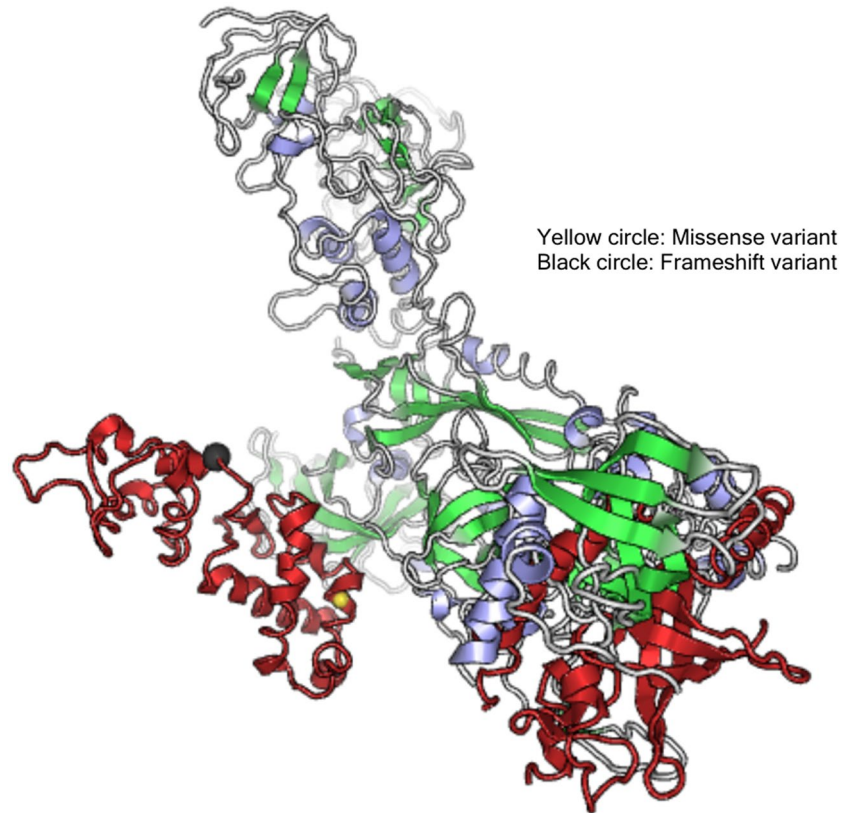


FIGURE 3 Schematic diagram of variants on STN1 protein domain



**FIGURE 4** 3D illustration of mutations on STN1 protein



alleles on the same control database. The c.894dup variant is predicted to create a shift in the reading frame, ending in a premature stop codon 58 positions downstream. The c.707T>C variant alters an amino acid within the C-terminal CST complex STN1 domain and is predicted as damaging by SIFT and Polyphen2.

All genetic investigations were undertaken with consent, and with appropriate ethic permissions (Leeds-west Multicentre Research Ethics Committee: REC reference: 10/H1307/2; IRAS project ID: 62971).

## 4 | DISCUSSION

This boy had a long period prior to accurate molecular diagnosis, during which he developed severe multisystem disease. Coats Plus is a rare, severe, autosomal recessive disorder characterised by a relatively stereotyped set of features: leukodystrophy, calcifications and cysts; retinal telangiectasia/exudates (i.e. Coats disease); and evolving gastrointestinal involvement including hepatic fibrosis, oesophageal varices and hepatosplenomegaly. Bone marrow failure can be present in some cases. GI telangiectasis and osteopenia, two of the key features of CP, were not present in this child, re-emphasising the variability in presentations with mutations in CST components. The major cause of CP is mutations in *CTCI*, with a single family so-far reported harbouring a mutation in *POT1*. Sequencing of

both of these genes was normal in our patient. Despite this, the clinical picture made any diagnosis other than CP highly unlikely. The diagnosis of CP was effectively confirmed with the identification of biallelic rare variants in *STN1*. The only other *STN1*-CP cases reported to date are two unrelated patients, each born to consanguineous Palestinian parents, found to harbour homozygous *STN1* variants; c.404G>C; p.(Arg135Thr), and c.469G>T; p.(Asp157Tyr), in exons 5 and 6 of *STN1*, respectively (Simon et al., 2016); and an Indian child with c.397C>T (p.Arg133\*) and c.985G>C (p.Ala329Pro) in exons 5 and 10, respectively (Passi et al., 2020). Further biological analysis such as telomere length by flow-FISH would be important in supporting our claim.

In summary, we report novel compound heterozygous *STN1* variants associated with Coats Plus, thereby expanding the associated molecular spectrum and emphasising the devastating nature of this multi-system disease.

## ACKNOWLEDGEMENTS

YJC acknowledges a state subsidy managed by the National Research Agency (France) under the 'Investments for the Future' programme bearing the reference ANR-10-IAHU-01. This study makes use of data generated by the DECIPHER community. A full list of centres who contributed to the generation of the data is available from <http://deciphergenomics.org/about/stats> and via email from [contact@deciphergenomics.org](mailto:contact@deciphergenomics.org). Funding for the DECIPHER project was provided by Wellcome.

## CONFLICT OF INTEREST

The authors have declared no conflict of interest.

## AUTHOR CONTRIBUTION

Helen V Firth, Luis Seabra and Yanick Crow conceived and planned the experiments, carried out Sanger Sequencing, analysed data and designed the figures. Alasdair PJ Parker, Shilpa Dugar, Tassos Grammatikopoulos and Angharad Walters were involved in the care of the patient, and provided the clinical details pertaining the patient. Tanvi Acharya took lead in writing the manuscript, with input from all authors.

## DATA AVAILABILITY STATEMENT

The data that support the findings of this study are available from the corresponding author upon reasonable request.

## ORCID

Tanvi Acharya  <https://orcid.org/0000-0003-0330-6585>

## REFERENCES

- Anderson, B. H., Kasher, P. R., Mayer, J., Szykiewicz, M., Jenkinson, E. M., Bhaskar, S. S., Urquhart, J. E., Daly, S. B., Dickerson, J. E., O'Sullivan, J., Leibundgut, E. O., Muter, J., Abdel-Salem, G. M. H., Babul-Hirji, R., Baxter, P., Berger, A., Bonafé, L., Brunstom-Hernandez, J. E., Buckard, J. A., ... Crow, Y. J. (2012). Mutations in CTC1, encoding conserved telomere maintenance component 1, cause Coats plus. *Nature Genetics*, *44*, 338–342.
- Crow, Y. J., McMenamin, J., Haenggeli, C. A., Hadley, D. M., Tirupathi, S., Treacy, E. P., Zuberi, S. M., Browne, B. H., Tolmie, J. L., & Stephenson, J. B. P. (2004). Coats' plus: A progressive familial syndrome of bilateral coats' disease, characteristic cerebral calcification, leukoencephalopathy, slow pre- and post-natal linear growth and defects of bone marrow and integument. *Neuropediatrics*, *35*, 10–19. <https://doi.org/10.1055/s-2003-43552>
- Firth, H. V., Richards, S. M., Bevan, A. P., Clayton, S., Corpas, M., Rajan, D., Van Vooren, S., Moreau, Y., Pettett, R. M., & Carter, N. P. (2009). DECIPHER: Database of chromosomal imbalance and phenotype in humans using ensembl resources. *American Journal of Human Genetics*, *84*, 524–533. <https://doi.org/10.1016/j.ajhg.2009.03.010>
- Goulian, M., Heard, C. J., & Grimm, S. L. (1990). Purification and properties of an accessory protein for DNA polymerase alpha/primase. *Journal of Biological Chemistry*, *265*, 13221–13230. [https://doi.org/10.1016/S0021-9258\(19\)38288-2](https://doi.org/10.1016/S0021-9258(19)38288-2)
- Jenkinson, E. M., Rodero, M. P., Kasher, P. R., Ugenti, C., Oojageer, A., Goosey, L. C., Rose, Y., Kershaw, C. J., Urquhart, J. E., Williams, S. G., Bhaskar, S. S., O'Sullivan, J., Baerlocher, G. M., Haubitz, M., Aubert, G., Barañano, K. W., Barnicoat, A. J., Battini, R., Berger, A., ... Crow, Y. J. (2016). Mutations in SNORD118 cause the cerebral microangiopathy leukoencephalopathy with calcifications and cysts. *Nature Genetics*, *48*, 1185–1192. <https://doi.org/10.1038/ng.3661>
- Kapuria, D., Ben-Yakov, G., Ortolano, R., Cho, M. H., Kalchiem-Dekel, O. R., Takyar, V., Lingala, S., Gara, N., Tana, M., Kim, Y. J., Kleiner, D. E., Young, N. S., Townsley, D. M., Koh, C., & Heller, T. (2019). The spectrum of hepatic involvement in patients with telomere disease. *Hepatology*, *69*, 2579–2585. <https://doi.org/10.1002/hep.30578>
- Keller, R. B., Gagne, K. E., Usmani, G. N., Asdourian, G. K., Williams, D. A., Hofmann, I., & Agarwal, S. (2012). CTC1 Mutations in a patient with dyskeratosis congenita. *Pediatric Blood & Cancer*, *59*, 311–314.
- Labrune, P., Lacroix, C., Goutières, F., de Laveaucoupet, J., Chevalier, P., Zerah, M., Husson, B., & Landrieu, P. (1996). Extensive brain calcifications, leukodystrophy, and formation of parenchymal cysts: a new progressive disorder due to diffuse cerebral microangiopathy. *Neurology*, *46*, 1297–1301. <https://doi.org/10.1212/WNL.46.5.1297>
- Passi, G. R., Shamim, U., Rathore, S., Joshi, A., Mathur, A., Parveen, S., Sharma, P., Crow, Y. J., & Faruq, M. (2020). An Indian child with Coats plus syndrome due to mutations in *STN1*. *American Journal of Medical Genetics*, *182*, 2139–2144.
- Polvi, A., Linnankivi, T., Kivelä, T., Herva, R., Keating, J. P., Mäkitie, O., Pareyson, D., Vainionpää, L., Lahtinen, J., Hovatta, I., Pihko, H., & Lehesjoki, A.-E. (2012). Mutations in CTC1, encoding the CTS telomere maintenance complex component 1, cause cerebroretinal microangiopathy with calcifications and cysts. *American Journal of Human Genetics*, *90*, 540–549. <https://doi.org/10.1016/j.ajhg.2012.02.002>
- Simon, A. J., Lev, A., Zhang, Y., Weiss, B., Rylova, A., Eyal, E., Kol, N., Barel, O., Cesarkas, K., Soudack, M., Greenberg-Kushnir, N., Rhodes, M., Wiest, D. L., Schiby, G., Barshack, I., Katz, S., Pras, E., Poran, H., Reznik-Wolf, H., ... Somech, R. (2016). Mutations in *STN1* cause Coats plus syndrome and are associated with genomic and telomere defects. *The Journal of Experimental Medicine*, *213*, 1429–1440. <https://doi.org/10.1084/jem.20151618>
- Stewart, J. A., Wang, F., Chaiken, M. F., Kasbek, C., Chastain, P. D., Wright, W. E., & Price, C. M. (2012). Human CST promotes telomere duplex replication and general replication restart after fork stalling. *EMBO Journal*, *31*, 3537–3549. <https://doi.org/10.1038/emboj.2012.215>
- Takai, H., Jenkinson, E., Kabir, S., Babul-Hirji, R., Najm-Tehrani, N., Chitayat, D. A., Crow, Y. J., & de Lange, T. (2016). A POT1 mutation implicates defective telomere end fill-in and telomere truncations in Coats plus. *Genes & Development*, *30*, 812–826. <https://doi.org/10.1101/gad.276873.115>
- Tolmie, J. L., Browne, B. H., McGettrick, P. M., & Stephenson, J. B. P. (1988). A familial syndrome with coats' reaction retinal angiomas, hair and nail defects and intracranial calcification. *Eye*, *2*(3), 297–303. <https://doi.org/10.1038/eye.1988.56>

**How to cite this article:** Acharya T, Firth HV, Dugar S, et al. Novel compound heterozygous *STN1* variants are associated with Coats Plus syndrome. *Mol Genet Genomic Med*. 2021;9:e1708. <https://doi.org/10.1002/mgg3.1708>