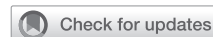

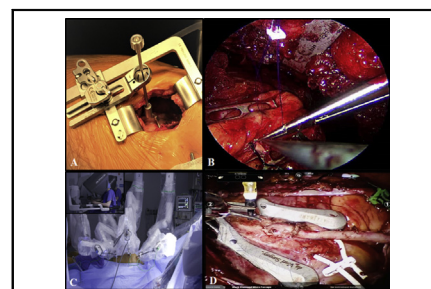
Minimally invasive coronary artery surgery: Robotic and nonrobotic minimally invasive direct coronary artery bypass techniques



Mateo Marin-Cuartas, MD,^a Michel Pompeu Sá, MD, MSc, PhD,^{b,c} Gianluca Torregrossa, MD, MEBCTS,^{b,c} and Piroze M. Davierwala, MD^{d,e}

Video clip is available online.

Continuous progress in percutaneous coronary intervention (PCI) has inspired surgeons to reduce the invasiveness of surgical revascularization techniques, resulting in the development of minimally invasive cardiac surgery (MICS) procedures, which have widely expanded over the past couple of decades.¹⁻⁴ The main goals of MICS are to avert any form of sternotomy, reduce postoperative blood product transfusion, shorten ventilation times, reduce intensive care and hospital stays, diminish postoperative pain, and accelerate return to normal activities.⁵ In the field of coronary artery bypass graft (CABG) surgery, minimally invasive direct coronary artery bypass (MIDCAB) grafting involving the use of the left internal thoracic artery (LITA) to graft the left anterior descending artery (LAD) through a left anterior small thoracotomy has become an attractive alternative approach to sternotomy for surgical revascularization for proximal LAD disease. MIDCAB is currently the most widely performed MICS procedure to graft the LAD and is being routinely performed with excellent outcomes in centers of excellence with expertise in such operations during the past 25 years.^{2,6,7} Moreover, this has prompted the emergence of more sophisticated



Nonrobotic (A and B) and robotic (C and D) minimally invasive direct CABG surgery.

CENTRAL MESSAGE

MIDCAB is a safe and efficacious technique of surgical revascularization for almost every patient with proximal left anterior descending disease with excellent outcomes and less surgical trauma.

technologies such as totally endoscopic and robotic MIDCAB procedures to further reduce the invasiveness, increase safety in LITA take down, and enhance the possibility to harvest the right ITA (RITA) as well. The following expert opinion offers an overview of the techniques, results, and benefits and drawbacks of robotic and nonrobotic approaches to MIDCAB procedures.

NONROBOTIC MIDCAB

Patient Selection

This technique can be used in most patients who need isolated surgical revascularization of the LAD. During the late 1990s, more than 200 MIDCAB procedures were performed at Leipzig Heart Center.² However, the number reduced significantly over the next few years, corresponding to the remarkable surge in the number of PCIs performed in Germany, particularly with the use of drug-eluting stents.⁸ But for the past 15 years, it has stabilized at approximately 10% of the total number of CABG

From the ^aUniversity Department of Cardiac Surgery, Leipzig Heart Center, Leipzig, Germany; ^bDepartment of Cardiac Surgery, Lankenau Heart Institute, Wynnewood, Pa; ^cDepartment of Cardiac Surgery Research, Lankenau Institute for Medical Research, Wynnewood, Pa; ^dDivision of Cardiovascular Surgery, Peter Munk Cardiac Centre, Toronto General Hospital, University Health Network, Toronto, Ontario, Canada; and ^eDepartment of Surgery, University of Toronto, Toronto, Ontario, Canada.

Received for publication Aug 20, 2021; accepted for publication Oct 8, 2021; available ahead of print Oct 13, 2021.

Address for reprints: Piroze M. Davierwala, MD, Division of Cardiovascular Surgery, Peter Munk Cardiac Centre, Toronto General Hospital, University Health Network, 200 Elizabeth st, Toronto, Ontario, Canada (E-mail: pirarm@hotmail.com).

JTCVS Techniques 2021;10:170-7

2666-2507

Copyright © 2021 The Author(s). Published by Elsevier Inc. on behalf of The American Association for Thoracic Surgery. This is an open access article under the CC BY-NC-ND license (<http://creativecommons.org/licenses/by-nc-nd/4.0/>).
<https://doi.org/10.1016/j.jtc.2021.10.008>

surgeries performed every year. There are a few absolute and relative contraindications mentioned in Table 1. The selection criteria may be expanded after overcoming the learning curve, which may be different for individual surgeons. The preoperative assessment is the same as for any patient undergoing CABG. A pulmonary function test would be useful in patients with chronic obstructive pulmonary disease, particularly due to the use of single-lung ventilation during the procedure. A computed tomography scan of the chest is not routinely required but may be performed during the surgeon's initial experience.

Surgical Technique

Our publication reporting the 20-year Leipzig experience in MIDCAB procedures provides a more detailed description of the surgical technique (Video 1).⁶ Single-lung ventilation facilitated by either a bronchus blocker or a double-lumen endotracheal tube is used. The operation is performed through a 5 cm left anterior thoracotomy (fourth or fifth intercostal spaces) located one-third medial and two-thirds lateral to the midclavicular line. The entire length of the LITA is harvested using Thoralift (Autosuture; US Surgical Corp, Norwalk, Conn) or the MIDAccess retractor (Delacroix-Chevalier; Paris, France), which elevates the upper two-thirds and depressed the lower one-third of the left thorax, using long-shafted instruments and electrocautery blade (Figure 1, A). The lower third of the LITA is harvested with a standard rib spreader, which enables better visualization of the distal LITA segment. The LITA is transected at its distal end following heparinization. The pericardium is then opened for about 4 cm over the anticipated anastomotic site on the LAD. It is extremely important to confirm that the vessel in view is the LAD by corroborating the actual coronary anatomy with that in the angiographic film. After stabilization with a reusable mechanical pressure stabilizer (Figure 1, B), the LAD is proximally snared, and an end-to-side anastomosis facilitated by a mister-blower is performed between the LITA and the LAD with 7-0 or 8-0 polypropylene preferably with the use of a shunt (Figure 1, C). Intraoperative flow measurement of the LITA is performed after completion of the anastomosis.⁹ The distal segment of the LITA and the anastomosis are covered with pericardial fat. A left-sided pleural drain is placed, and the left lung is carefully reinflated under direct vision to avoid sudden traction or tension on the LITA. The thoracotomy wound is closed in layers in standard fashion after administration of an intercostal block with a local anesthetic (Figure 1, D).

Outcomes

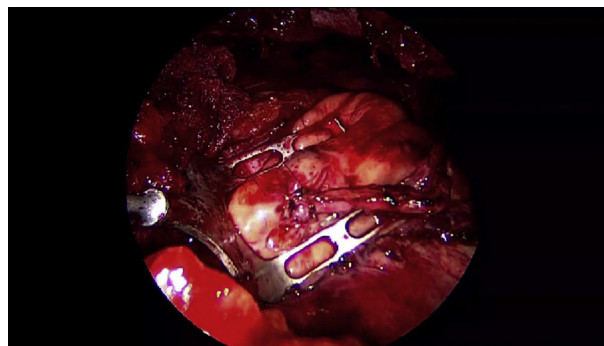
Both surgical and interventional procedures have been given a Class IA recommendation¹⁰ for treating patients with isolated proximal LAD lesions due to comparable

TABLE 1. Contraindications for minimally invasive direct coronary artery bypass (MIDCAB)

Absolute	
Highly stenotic or occluded left subclavian artery	
Severe COPD that precludes single-lung ventilation	
Emergency procedures	
Iatrogenic dissection or occlusion of the LAD following diagnostic or therapeutic interventions	
Hemodynamic instability following an acute coronary syndrome	
Relative	
Severe obesity	
Severe chest deformities	
Complex coronary anatomy	
Intramyocardial LAD	
Calcified LAD requiring endarterectomy	
Small vessel (<1.5 mm)	

COPD, Chronic obstructive pulmonary disease; LAD, left anterior descending.

clinical outcomes reported by several studies.¹¹⁻¹⁵ The 2 small randomized controlled trials comparing MIDCAB to PCI with bare-metal and drug-eluting stents, respectively, did not show any differences in the primary composite outcome between the revascularization strategies; however, MIDCAB patients had a significantly lower rate of target vessel revascularization than PCI with bare-metal stent (11% vs 34%) and drug-eluting stent (1.5% vs 20%) at 10 and 7 years following the procedure, respectively. However, most randomized studies in the literature report follow-up periods to a maximum of 5 years or are too small to make any meaningful inferences. Therefore, observational studies with extended long-term follow-up periods of 15 to 20 years or longer set a benchmark for future studies and trials investigating various revascularization therapies, at least for patients with isolated proximal LAD disease. A recent study involving 2667 patients at Leipzig Heart Center, which is among the pioneering institutions for MIDCAB procedures since the 1990s,^{2,16,17} reported in-hospital



VIDEO 1. Surgical technique of minimally invasive direct coronary artery bypass surgery. Video available at: [https://www.jtcvs.org/article/S2666-2507\(21\)00697-0/fulltext](https://www.jtcvs.org/article/S2666-2507(21)00697-0/fulltext).

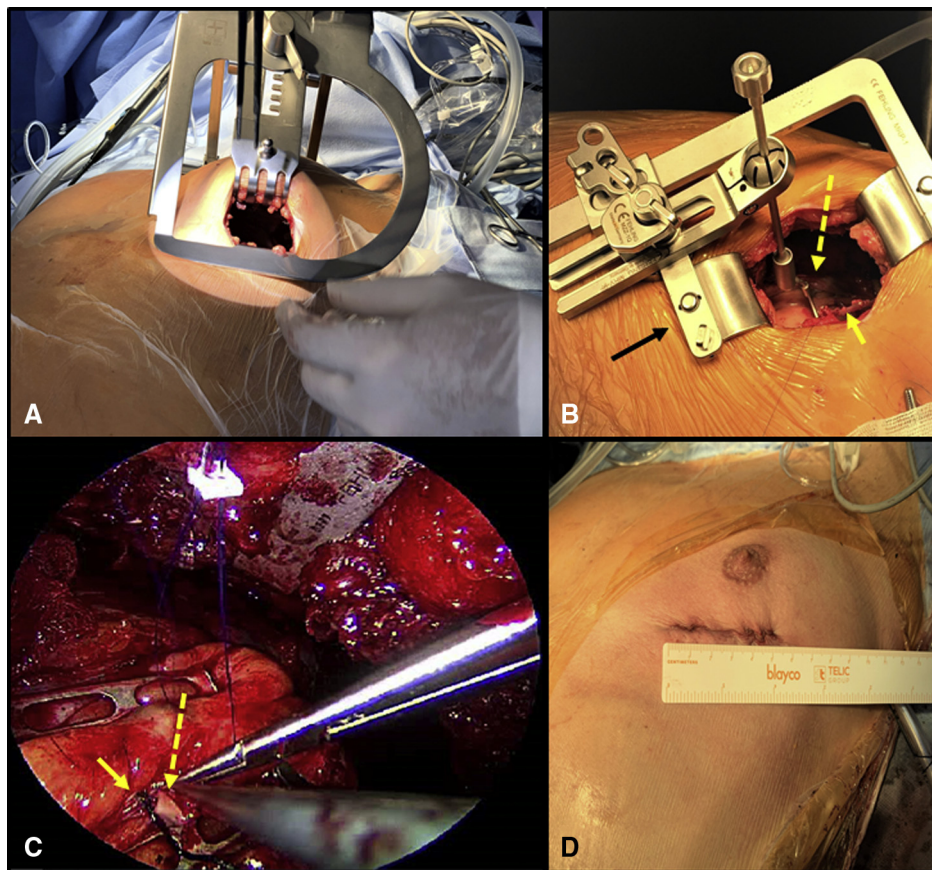


FIGURE 1. A, This picture shows the retractor used for left internal thoracic artery harvest (LITA), which elevates the upper two-thirds and depresses the lower one-third of the left thorax. B, Stabilization of the left anterior descending artery (LAD) with a mechanical pressure stabilizer (*yellow hatched arrow*) mounted on a rib spreader (*black arrow*). The yellow arrow shows the LITA. C, The end-to-side anastomosis being performed between the LITA (*yellow hatched arrow*) and the LAD with a shunt placed in the LAD (*yellow arrow*). D, Closed thoracotomy incision measures 5 cm.

mortality <1%, which remained constant over the 22-year period of the study despite worsening baseline characteristics of patients over time.⁶ The overall 10-, 15-, and 20-year survival estimates were 77.7%, 66.1%, and 55.6%, respectively, which are comparable to those reported by the Harefield group (10- and 15-year survival: 76.2% and 67.5%).¹⁸ An Italian group from Brescia similarly reported excellent 10- and 15-year survival rates (84.3% and 79.8%) in patients undergoing MIDCAB surgery.¹⁹ Moreover, in the Leipzig study, the estimated survival of patients who underwent MIDCAB was comparable to the life expectancy of age- and gender-matched German population,⁶ an observation that was similar to patients undergoing isolated CABG in a Norwegian study.²⁰ Even amongst the elderly population (>80 years), MIDCAB is associated with an acceptable 5- and 10-year survival (63% to 66% and 42%, respectively).^{6,21} However, it is important to note that learning curve, experience of the team, and case volumes do influence outcomes following these procedures.²² Left ventricular dysfunction^{6,23,24} and presence of diabetes mellitus,^{6,25-29} as expected, influence long-term outcomes

following MIDCAB operations. Nevertheless, female gender has not been found to affect survival rates following MIDCAB.^{6,30,31} MIDCAB has also been found to be associated with acceptable outcomes in patients who have a prohibitively high risk for conventional CABG surgery. Hoffmann and colleagues³² reported mortality that was 2-fold lower than that predicted by the log European System for Cardiac Operative Risk Evaluation score. Complete revascularization as scheduled was achieved in 82.1% of patients who underwent MIDCAB as the first procedure. The 1-, 3-, and 5-year survival was 77%, 62%, and 48%, respectively.

ROBOTIC MIDCAB

Robotic MIDCAB has been proposed as an alternative to conventional CABG and MIDCAB for the management of LAD disease, and recently extended its indication by harvesting the RITA and deploying it to the best left coronary target. At the Lankenau Heart Institute, robotic MIDCAB as a stand-alone procedure or as part of hybrid revascularization accounts for 60% of the total annual volume of

CABG (grossly 300+ cases per year), which has remained stable for the past 5 years.

Patient Selection


Although patient selection and preoperative workup of the patients is similar to that required for MIDCAB operations, using a robotic platform enhances the possibility of serving obese patients by allowing a more precise visualization of the proximal LITA during its harvest.

Surgical Technique

It involves 2 different techniques: robot-assisted CABG (RA-CABG) and totally endoscopic CABG (TE-CABG). Whereas the former includes the robotic takedown of the LITA and its direct anastomosis to the LAD coronary artery with a small anterior thoracotomy (3-4 cm) (Video 2), the latter requires no thoracotomy, generally being performed using only 5 ports (8-12 mm) in the left chest. Both in RA-CABG as well as in TE-CABG surgery start with the introduction of 3 ports in the midclavicular/anterior axillary line, in second, fourth, and sixth intercostal space (Figure 2, A). A camera and 2 lateral arms with surgical instruments are introduced and the surgeon sits on the robotic console while a tableside assistant exchanges the robotic surgical instruments (Figure 2, A, inset). The 3-dimensional view offered by the robotic platform enhances the visualization of the LITA, lowering the risk of vessel injury and enables the surgeon to harvest a longer LITA graft by means of skeletonization (Figure 2, B). If a second ITA is required, the surgeon can open the right pleura crossing the mediastinum and accessing the RITA from the left side of the chest. In RA-CABG, after conduit is harvested, a small thoracotomy (3-4 cm) is performed in the fourth intercostal space along the mid clavicular line (Figure 2, C). Through the mini thoracotomy the surgeon can perform an off-pump LITA-to-LAD anastomosis using a suction stabilizer (Octopus Nuvo Tissue Stabilizer; Medtronic, Minneapolis, Minn) to complete the anastomosis. In TE-CABG, after conduit harvest, the surgeon scrubs and goes back to the operating table and adds 2 more ports: a subcostal one medial to the xiphoid process to introduce the robotic stabilizer (da Vinci Robotic Stabilizer; Intuitive, Sunnyvale, Calif) and a working port in the second intercostal space (Figure 2, D). Thereafter, the surgeon returns to the surgical console and completes the LITA to LAD anastomosis using the robotic surgical instruments and a 7-0 Pronova suture (Johnson & Johnson Medical, Franklin Lakes, NJ) (Figure 2, D, inset) or a Flex A distal anastomotic device (Cardica, Redwood City, Calif).

Outcomes

Initially developed to perform LITA-to-LAD anastomoses with cardiopulmonary bypass on an arrested heart, TE-CABG presented itself as an even-less-invasive option than RA-CABG. Initially, 2 important case series



VIDEO 2. Surgical technique of robot-assisted minimally invasive direct coronary artery bypass surgery. Video available at: [https://www.jtcvs.org/article/S2666-2507\(21\)00697-0/fulltext](https://www.jtcvs.org/article/S2666-2507(21)00697-0/fulltext).

demonstrated its safety and reproducibility.^{33,34} Later on, significant technological improvements in the da Vinci robotic system enabled surgeons to perform off-pump multi-arterial TE-CABG.³⁵ The value of TE-CABG versus RA-CABG is not limited to the presence or absence of an incision required to perform the surgery but rather to the possibility of expanding the procedure to multivessel grafting by facilitating RITA harvest and performing multiple anastomoses.³⁶

It is well known that a learning curve is part and parcel of implementing or developing an innovative surgical technique and robotic cardiac surgery is no exception to this rule. Recently, Van den Eynde and colleagues³⁷ carried out a retrospective analysis of the first 300 RA-CABG procedures performed at a single center in Europe. The authors observed a substantial improvement in procedural safety following 50 operations. A recent analysis by Patrick and colleagues³⁸ involving 1195 patients from the Society of Thoracic Surgeons Registry undergoing RA-MIDCAB by 114 surgeons between 2014 and 2019 revealed that stable clinical outcomes can be achieved after the 10th procedure and case sequences >10 were associated with reduced rates of access conversion (odds ratio, 0.27; 95% CI, 0.09-0.84) and improved procedural success (odds ratio, 1.96; 95% CI, 1.00-3.84). These results suggest that surgeons can safely add robotic CABG to their armamentarium of revascularization techniques by quickly reducing complication rates. Similar to the MIDCAB experiences, studies from centers that have teams highly experienced and specialized in robotic cardiac surgery have demonstrated the safety and efficacy of RA-CABG and TE-CABG. Giamb Bruno and colleagues³⁹ published their 18-year experience involving 605 patients who underwent RA-CABG and postprocedural selective graft patency assessment using cardiac catheterization. The death rate was 0.3%. The patency rate of LITA-to-LAD anastomoses was 97.4%. The rates of surgical re-exploration for bleeding and transfusion were 1.8% and 9.2%, respectively. Halkos and

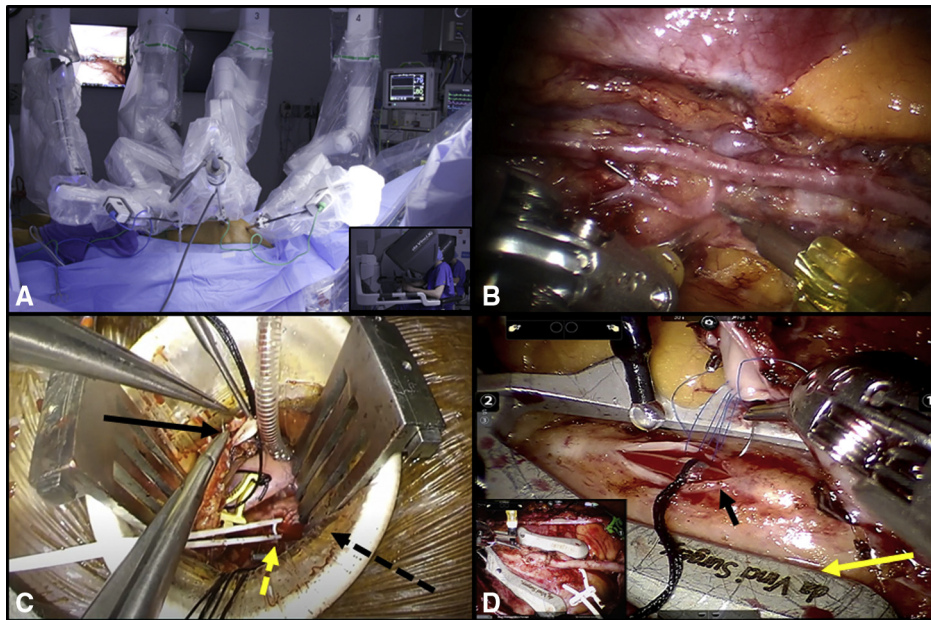


FIGURE 2. A, This picture shows the 3 ports in the second, fourth, and sixth intercostal spaces with the robotic arms inserted into the ports. The inset shows the surgeon working at the console. B, The 3-dimensional view offered by the robotic platform enhances the visualization of the left internal thoracic artery (LITA) that is skeletonized. C, In robot-assisted coronary artery bypass grafting (CABG), a small thoracotomy (3–4 cm) is performed in the fourth intercostal space along the midclavicular line (*black hatched arrow*). Black arrow shows the LITA and the *yellow arrow* shows the left anterior descending artery (LAD) that is proximally snared with a silastic loop while the surgeon performs an off-pump LITA-to-LAD anastomosis using a suction stabilizer. D, LITA to LAD anastomosis (*black arrow*) performed off-pump using the robotic surgical instruments and a 7-0 polypropylene suture facilitated by a robotic stabilizer (*yellow arrow*) inserted into the thorax through an additional port in totally endoscopic-CABG. The inset shows a completed anastomosis.

colleagues⁴⁰ published their series with 307 consecutive RA-CABG procedures performed at a single US institution by 2 surgeons. Thirty-day mortality was 1.3%. The LITA patency was 95% in 199 patients who underwent postoperative angiography before discharge. Balkhy and colleagues³⁶ retrospectively reviewed graft patency in all 121 TE-CABG patients over a 5-year period by means of a follow-up angiogram (84 patients as part of planned hybrid procedures and 37 patients unplanned for clinical indications). The authors evaluated 204 grafts (130 LITA and 74 RITA) and observed an overall graft patency of 95.6% (LITA = 96%; RITA = 93%). LITA-to-LAD graft patency was 97%.

Because robotic TE-CABG is technically more challenging than RA-CABG, it would be prudent to compare their results. Kofler and colleagues⁴¹ compared both techniques in respect to perioperative and midterm results and reported no perioperative deaths in both groups besides similar rates of perioperative myocardial infarction and stroke. Moreover, they found no difference in midterm survival and freedom from major adverse cardiac and cerebrovascular events. RA-MIDCAB procedures have also been shown to have acceptable outcomes in patients with high SYNTAX scores. Lin and colleagues⁴² reported lower in-hospital and long-term mortality following RA-MIDCAB compared with conventional CABG, with similar rates of

target lesion or target vessel revascularization, myocardial infarction, and stroke. Long-term mortality was related to age, lower left ventricular ejection fraction, and chronic kidney disease, but not to the residual SYNTAX score, or completeness of revascularization.

Benefits and Drawbacks

Being a sternal-sparing approach, the main benefit of MIDCAB over sternotomy is the elimination of superficial and deep sternal wound infections and mediastinitis while preserving the long-term benefit of LITA use for revascularizing the LAD, which is the main advantage of CABG over PCI.^{19,43-45} MIDCAB offers an excellent alternative to PCI for successful revascularization of patients with complex diffuse LAD disease, ectatic but severely stenotic LAD, severe coronary calcification, complex bifurcation lesions, tortuous LAD course, and in-stent stenosis without negatively influencing clinical outcomes.⁴⁶ Moreover, MIDCAB is performed without the use of cardiopulmonary bypass, thereby further reducing the invasiveness of the procedure and resulting complications such as perioperative stroke due to avoidance of aortic manipulation.⁴⁷ Lastly, the cosmetic benefit of the procedure cannot be understated from the patient's point of view.

Among the drawbacks of MIDCAB procedures is that if cardiopulmonary bypass is required in the rare case,

TABLE 2. Advantages and disadvantages of robotic and nonrobotic minimally invasive direct coronary artery bypass (MIDCAB)

Nonrobotic MIDCAB	Robotic MIDCAB
Involves a 5-6 cm thoracotomy	Involves a 3-4 cm thoracotomy or ports only— <i>Cosmesis may be better</i>
Rib spreading, especially during ITA harvest— <i>Pain may be more</i>	Minimal; no rib spreading
LITA harvest: Distal segment may be more difficult to take down	LITA harvest: Better visualization of the entire length of the LITA
View of the LAD: Adequate, if pericardium opened up to apex	View of the LAD: Limited, if using robot-assisted MIDCAB
LITA-LAD anastomosis: <ul style="list-style-type: none"> • Most commonly performed at the level of the incision • No facilitatory gadgets required 	LITA-LAD anastomosis: <ul style="list-style-type: none"> • Most commonly performed at the level of the incision if guided by the camera • Facilitated by U-clips or distal anastomotic connectors, technically challenging in TE-CABG when hand-sewn.
Learning curve: Not as steep	Learning curve: Steep
Costs: Similar to conventional surgery	Costs: Higher due to disposables and initial cost of the robot itself
Additional aspects: <ul style="list-style-type: none"> • Very quick and efficient • Entirely dependent on the sewing skill of the surgeon • Can be discomforting for the surgeon • Difficult to teach due to restricted vision 	Additional aspects: <ul style="list-style-type: none"> • Time consuming • Filtration of tremors • Comfortable for the surgeon • Better teaching capabilities due to visualization on a console

ITA, Internal thoracic artery; LITA, left internal thoracic artery; LAD, left anterior descending; TE-CABG, totally endoscopic coronary artery bypass grafting.

peripheral cannulation is the only option available to avoid a sternotomy, which could be difficult to impossible in patients with severe peripheral vascular disease. Another drawback of this technique is that it is a challenge to perform these operations in patients with morbid obesity who, in reality, would benefit the most from avoiding a sternotomy. A robotic MIDCAB procedure may be possible in such patients. This obviously raises the question concerning advantages and disadvantages of both techniques, which have been presented in Table 2.

Future Perspectives

The long-term benefits of CABG have been largely associated with the durability of the LITA graft to the LAD.⁴³ The conventional sternotomy approach being considerably invasive for single-vessel CABG, particularly in the era of PCI with drug-eluting stents, there is an impetus around the globe to reduce the invasiveness of CABG surgery. The 2 techniques described above provide just that! However, such operations are being performed only in niche centers by select surgeons who have developed interest in taking this field forward. We therefore believe that such centers with expertise in minimally invasive CABG should be at the forefront in developing training programs in MICS to make these procedures widely adopted. There is a paucity of evidence comparing the long-term outcomes of PCI and MIDCAB, especially in special high-risk populations of patients with diabetes mellitus, obesity, and chronic kidney and lung diseases. Hence, future clinical trials are required that could shed more light on the benefits of this procedure. We also believe that focusing on advancements in robotic

systems for MIDCAB that reduce the technical difficulty and cost will increase the adoption of robotic technology at least for MIDCAB surgery. It would also provide an opportunity to establish advanced hybrid programs involving robotic MIDCAB and PCI of the non-LAD vessels. Optimal functioning of such programs would require determination of patient selection criteria for such procedures, which would necessitate further clinical trials.

CONCLUSIONS

Robotic and nonrobotic approaches to MIDCAB procedures are safe, feasible, and efficacious, which is particularly true for institutions and surgeons that have developed expertise in the respective type of operations. The learning curve is a reality, being much steeper for robotic than for nonrobotic MIDCAB procedures. Stepwise learning is probably the mantra for successful and safe learning and implementation of MIDCAB.

Conflict of Interest Statement

The authors reported no conflicts of interest.

The *Journal* policy requires editors and reviewers to disclose conflicts of interest and to decline handling or reviewing manuscripts for which they may have a conflict of interest. The editors and reviewers of this article have no conflicts of interest.

References

1. Davierwala PM, Seeburger J, Pfannmueller B, Garbade J, Misfeld M, Borger MA, et al. Minimally invasive mitral valve surgery: "The Leipzig experience." *Ann Cardiothorac Surg*. 2013;2:744-50.

2. Diegeler A, Spyrtantis N, Matin M, Falk V, Hambrecht R, Autschbach R, et al. The revival of surgical treatment for isolated proximal high grade LAD lesions by minimally invasive coronary artery bypass grafting. *Eur J Cardiothorac Surg.* 2000;17:501-4.
3. Chang C, Raza S, Altarabsheh SE, Delozier S, Sharma UM, Zia A, et al. Minimally invasive approaches to surgical aortic valve replacement: a meta-analysis. *Ann Thorac Surg.* 2018;106:1881-9.
4. Davierwala PM, Verevkin A, Sgouropoulou S, Hasheminejad E, von Aspern K, et al. Minimally invasive coronary bypass surgery with bilateral internal thoracic arteries: early outcomes and angiographic patency. *J Thorac Cardiovasc Surg.* 2021;162:1109-19.e4.
5. Marin Cuartas M, Javadikasgari H, Pfanmueller B, Seeburger J, Gillinov AM, Suri RM, et al. Mitral valve repair: robotic and other minimally invasive approaches. *Prog Cardiovasc Dis.* 2017;60:394-404.
6. Davierwala PM, Verevkin A, Bergien L, von Aspern K, Deo SV, et al. Twenty-year outcomes of minimally invasive direct coronary artery bypass surgery: the Leipzig experience. *J Thorac Cardiovasc Surg.* February 6, 2021; <https://doi.org/10.1016/j.jtcvs.2020.12.149> [Epub ahead of print].
7. Calafiore AM, DiGiammarco G, Teodori G, Gallina S, Maddestra N, Paloscia L, et al. Midterm results after minimally invasive coronary surgery (LAST operation). *J Thorac Cardiovasc Surg.* 1998;115:763-71.
8. Ohlmeier C, Czwikla J, Enders D, Mikolajczyk R, Blindt R, Horenkamp-Sonnatag D, et al. Percutaneous coronary interventions: use between 2004 and 2012 in Germany [Article in German]. *Bundesgesundheitsblatt Gesundheitsforschung Gesundheitschutz.* 2016;59:783-8.
9. Marin-Cuartas M, Davierwala PM. Intraoperative graft flow assessment for myocardial surgical revascularization. *Vessel Plus.* 2021;5:32.
10. Neumann FJ, Sousa-Uva M, Ahlsson A, Alfonso F, Banning AP, ESC Scientific Document Group. 2018 ESC/EACTS guidelines on myocardial revascularization. *Eur Heart J.* 2019;40:87-165.
11. Blazek S, Rossbach C, Borger MA, Fuernau G, Desch S, Eitel I, et al. Comparison of sirolimus-eluting stenting with minimally invasive bypass surgery for stenosis of the left anterior descending coronary artery: 7-year follow-up of a randomized trial. *JACC Cardiovasc Interv.* 2015;8:30-8.
12. Blazek S, Holzhey D, Jungert C, Borger MA, Fuernau G, Desch S, et al. Comparison of bare-metal stenting with minimally invasive bypass surgery for stenosis of the left anterior descending coronary artery: 10-year follow-up of a randomized trial. *JACC Cardiovasc Interv.* 2013;6:20-6.
13. Hannan EL, Zhong Y, Walford G, Holmes DR Jr, Venditti FJ, Berger PB, et al. Coronary artery bypass graft surgery versus drug-eluting stents for patients with isolated proximal left anterior descending disease. *J Am Coll Cardiol.* 2014;64:2717-26.
14. Deppe AC, Liakopoulos OJ, Kuhn EW, Slottosch I, Scherner M, Choi YH, et al. Minimally invasive direct coronary bypass grafting versus percutaneous coronary intervention for single-vessel disease: a meta-analysis of 2885 patients. *Eur J Cardiothorac Surg.* 2015;47:397-406.
15. Wang XW, Qu C, Huang C, Xiang XY, Lu ZQ. Minimally invasive direct coronary bypass compared with percutaneous coronary intervention for left anterior descending artery disease: a meta-analysis. *J Cardiothorac Surg.* 2016;11:125.
16. Holzhey DM, Jacobs S, Mochalski M, Walther T, Thiele H, Mohr FW, et al. Seven-year follow-up after minimally invasive direct coronary artery bypass: experience with more than 1300 patients. *Ann Thorac Surg.* 2007;83:108-14.
17. Holzhey DM, Cornely JP, Rastan AJ, Davierwala P, Mohr FW. Review of a 13-year single-center experience with minimally invasive direct coronary artery bypass as the primary surgical treatment of coronary artery disease. *Heart Surg Forum.* 2012;15:E61-8.
18. Raja SG, Garg S, Rochon M, Daley S, DeRobertis F, Bahrami T. Short-term clinical outcomes and long-term survival of minimally invasive direct coronary artery bypass grafting. *Ann Cardiothorac Surg.* 2018;7:621-7.
19. Repossini A, Di Bacco L, Nicolli F, Passaretti B, Stara A, Jonida B, et al. Minimally invasive coronary artery bypass: twenty-year experience. *J Thorac Cardiovasc Surg.* 2019;158:127-38.
20. Enger TB, Pleym H, Stenseth R, Greiff G, Videm WA, Videm V. Reduced long-term relative survival in females and younger adults undergoing cardiac surgery: a prospective cohort study. *PLoS One.* 2016;11:e0163754.
21. Hoffmann G, Friedrich C, Barrabas M, Petzina R, Haneya A, Panholzer B, et al. Short- and long-term follow-up after minimally invasive direct coronary artery bypass in octogenarians. *Interact Cardiovasc Thorac Surg.* 2016;23:377-82.
22. Holzhey DM, Jacobs S, Walther T, Mochalski M, Mohr F, Falk V. Cumulative sum failure analysis for eight surgeons performing minimally invasive direct coronary artery bypass. *J Thorac Cardiovasc Surg.* 2007;134:663-9.
23. Pompilio G, Alamanni F, Tartara PM, Antona C, Porqueddu M, Veglia F, et al. Determinants of late outcome after minimally invasive direct coronary artery bypass. *J Cardiovasc Surg (Torino).* 2007;48:207-14.
24. Marin-Cuartas M, Deo SV, Ramirez P, Verevkin A, Leontyev S, Borger MA, et al. Off-pump coronary artery bypass grafting is safe and effective in patients with severe left ventricular dysfunction. *Eur J Cardiothorac Surg.* August 15, 2021; <https://doi.org/10.1093/ejcts/ezab371> [Epub ahead of print].
25. Lichtenberg A, Klima U, Paeschke H, Pichlmaier M, Ringes-Lichtenberg S, Walles T, et al. Impact of diabetes on outcome following isolated minimally invasive bypass grafting of the left anterior descending artery. *Ann Thorac Surg.* 2004;78:129-34.
26. Hlatky MA, Boothroyd DB, Bravata DM, Boersma E, Booth J, Brooks MM, et al. Coronary artery bypass surgery compared with percutaneous coronary interventions for multivessel disease: a collaborative analysis of individual patient data from ten randomised trials. *Lancet.* 2009;373:1190-7.
27. Onuma Y, Wykrzykowska JJ, Garg S, Vranckx P, Serruys PW, ARTS I and II Investigators. 5-year follow-up of coronary revascularization in diabetic patients with multivessel coronary artery disease: insights from ARTS (Arterial Revascularization Therapy Study)-II and ARTS-I trials. *JACC Cardiovasc Interv.* 2011;4:317-23.
28. Järvinen O, Hokkanen M, Huhtala H. Diabetics have inferior long-term survival and quality of life after CABG. *Int J Angiol.* 2019;28:50-6.
29. Mohammadi S, Dagenais F, Mathieu P, Kingma JG, Doyle D, Lopez S, et al. Long-term impact of diabetes and its comorbidities in patients undergoing isolated primary coronary artery bypass graft surgery. *Circulation.* 2007;116(11 Suppl):1220-5.
30. Friedrich C, Berndt R, Haneya A, Rusch R, Petzina R, Freitag-Wolf S, et al. Sex-specific outcome after minimally invasive direct coronary artery bypass for single-vessel disease. *Interact Cardiovasc Thorac Surg.* 2020;30:380-7.
31. Gofus J, Vobornik M, Sorm Z, Dergel M, Karalko M, Harrer J, et al. Female sex as a risk factor in minimally invasive direct coronary artery bypass grafting. *Scand Cardiovasc J.* 2019;53:141-7.
32. Hoffmann G, Friedrich C, Huenges K, Petzina R, Vogt A-M, Cremer J, et al. Minimally invasive direct coronary artery bypass in high-risk patients with multivessel disease. *Thorac Cardiovasc Surg.* 2021;69:607-13. <https://doi.org/10.1055/s-0041-1723845>
33. Argenziano M, Katz M, Bonatti J, Srivastava S, Murphy D, Poirier R, et al. Results of the prospective multicenter trial of robotically assisted totally endoscopic coronary artery bypass grafting. *Ann Thorac Surg.* 2006;81:1666-75.
34. de Cannière D, Wimmer-Greinecker G, Cichon R, Gulielmos V, Van Praet F, Seshadri-Kreaden U, et al. Feasibility, safety, and efficacy of totally endoscopic coronary artery bypass grafting: multicenter European experience. *J Thorac Cardiovasc Surg.* 2007;134:710-6.
35. Torregrossa G, Amabile A, Williams E, Fonceva A, Hosseinian L, Balkhy HH. Multi-arterial and total-arterial coronary revascularization: past, present, and future perspective. *J Card Surg.* 2020;35:1072-81.
36. Balkhy HH, Nathan S, Arnsdorf SE, Krienbring DJ. Right internal mammary artery use in 140 robotic totally endoscopic coronary bypass cases: toward multi-arterial grafting. *Innovations (Phila).* 2017;12:9-14.
37. Van den Eynde J, Vaesen Bentein H, Decaluwé T, De Praetere H, Werten MC, Sutter FP, et al. Safe implementation of robotic-assisted minimally invasive direct coronary artery bypass: application of learning curves and cumulative sum analysis. *J Thorac Dis.* 2021;13:4260-70.
38. Patrick WL, Iyengar A, Han JJ, Mays JC, Helmers M, Kelly JJ, et al. The learning curve of robotic coronary arterial bypass surgery: a report from the STS database. *J Card Surg.* 2021;36:4178-86. <https://doi.org/10.1111/jocs.15945>
39. Giambruno V, Chu MW, Fox S, Swinamer SA, Rayman R, Markova Z, et al. Robotic-assisted coronary artery bypass surgery: an 18-year single-centre experience. *Int J Med Robot.* 2018;14:e1891.
40. Halkos ME, Liberman HA, Devireddy C, Walker P, Finn AV, Jaber W, et al. Early clinical and angiographic outcomes after robotic-assisted coronary artery bypass surgery. *J Thorac Cardiovasc Surg.* 2014;147:179-85.
41. Kofler M, Stastny L, Reinstadler SJ, Dumfarth J, Kilo J, Friedrich G, et al. Robotic Versus Conventional Coronary Artery Bypass Grafting: Direct Comparison of Long-Term Clinical Outcome. *Innovations (Phila).* 2017;12:239-46.
42. Lin TH, Wang CW, Shen CH, Change K-H, Lai C-H, Liu T-J, et al. Clinical outcomes of multivessel coronary artery disease patients revascularized by robot-assisted vs conventional standard coronary artery bypass graft surgeries in real-world practice. *Medicine (Baltimore).* 2021;100:e23830.

43. Zhang M, Guddeti RR, Matsuzawa Y, Sara JDS, Kwon T-G, Liu Z, et al. Left internal mammary artery versus coronary stents: impact on downstream coronary stenoses and conduit patency. *J Am Heart Assoc.* 2016;5:e003568.
44. Kurlansky PA, Traad EA, Dorman MJ, Galbut DL, Ebra G. Bilateral versus single internal mammary artery grafting in the elderly: long-term survival benefit. *Ann Thorac Surg.* 2015;100:1374-81.
45. Cameron A, Kemp HG Jr, Green GE. Bypass surgery with the internal mammary artery graft: 15 year follow-up. *Circulation.* 1986;74(5 Pt 2):III30-6.
46. Holzhey DM, Jacobs S, Walther T, Mohr FW, Falk V. Is chronic total coronary occlusion a risk factor for long-term outcome after minimally invasive bypass grafting of the left anterior descending artery? *Ann Thorac Surg.* 2010;89:1496-501.
47. Calafiore AM, DiMauro M, Teodori G, Di Giammarco G, Cirmeni S, Contini M, et al. Impact of aortic manipulation on incidence of cerebrovascular accidents after surgical myocardial revascularization. *Ann Thorac Surg.* 2002;73:1387-93.

Key Words: CABG, MIDCAB, robotic, off-pump