

Acute appendicitis complicated by mesenteric vein thrombosis: A case report

Fan Yang, Xiao-Chao Guo, Xiao-Long Rao, Lie Sun, Ling Xu

ORCID number: Fan Yang 0000-0002-9629-074X; Xiao-Chao Guo 0000-0001-7602-5368; Xiao-Long Rao 0000-0002-9277-7524; Lie Sun 0000-0002-3554-9904; Ling Xu 0000-0002-9236-3014.

Author contributions: Yang F drafted the initial manuscript, revised the final manuscript as submitted, and collected clinical data; Guo XC provided the image data and the description of them; Rao XL contributed to the image finding; Xu L was involved in revising and polishing the text; and Sun L took responsibility for the paper as a whole and help collect the patient's data.

Informed consent statement: We have obtained the oral consent of the patient and her family before submitting the manuscript. The case report does not involve the patient's private information and we can provide informed consent when necessary.

Conflict-of-interest statement: The authors have no conflict of interest to declare.

CARE Checklist (2016) statement: We have filled out the CARE Checklist (2016) and uploaded the completed file at the first time we submitted the manuscript.

Country/Territory of origin: China

Fan Yang, Lie Sun, Department of General Surgery, Peking University First Hospital, Beijing 100034, Beijing Province, China

Xiao-Chao Guo, Department of Radiology, Peking University First Hospital, Beijing 100034, Beijing Province, China

Xiao-Long Rao, Endoscopy Center, Peking University First Hospital, Beijing 100034, Beijing Province, China

Ling Xu, Breast Disease Center, Peking University First Hospital, Beijing 100034, Beijing Province, China

Corresponding author: Lie Sun, MD, Associate Chief Physician, Surgeon, Department of General and Visceral Surgery, University of Ulm, Albert-Einstein-Allee 23, 89081 Ulm, Germany, Baden 89081 Ulm, Germany. sunliemd@126.com

Abstract

BACKGROUND

Acute appendicitis with mesenteric vein thrombosis (MVT) is an uncommon condition and usually lacks specific clinical manifestations, which leads to a high rate of misdiagnosis or delayed diagnosis, especially when it is accompanied by other abdominal diseases. Prompt and accurate recognition is vital for treatment and prognosis.

CASE SUMMARY

A 37-year-old woman had a history of acute metastatic right lower abdominal pain, nausea, and fever. A contrast-enhanced computed tomography (CT) scan showed a filling defect in the mesenteric vessels. The patient was diagnosed with acute appendicitis complicated by MVT and was treated with anticoagulation and intravenous antibiotics. The follow-up CT scan showed full resolution of the thrombosis and inflammation.

CONCLUSION

Clinical awareness is essential for recognizing MVT, especially when it is accompanied by other common acute abdominal diseases, such as acute appendicitis. Contrast-enhanced CT is helpful for the diagnosis of MVT and is recommended for patients with acute abdominal diseases.

Key Words: Mesenteric vein thrombosis; Ischemic bowel disease; Acute abdominal

Specialty type: Medicine, research and experimental

Provenance and peer review:

Unsolicited article; Externally peer reviewed.

Peer-review model: Single blind

Peer-review report's scientific quality classification

Grade A (Excellent): 0

Grade B (Very good): B

Grade C (Good): C

Grade D (Fair): 0

Grade E (Poor): 0

Open-Access: This article is an open-access article that was selected by an in-house editor and fully peer-reviewed by external reviewers. It is distributed in accordance with the Creative Commons Attribution NonCommercial (CC BY-NC 4.0) license, which permits others to distribute, remix, adapt, build upon this work non-commercially, and license their derivative works on different terms, provided the original work is properly cited and the use is non-commercial. See: <http://creativecommons.org/licenses/by-nc/4.0/>

Received: June 13, 2021

Peer-review started: June 13, 2021

First decision: June 25, 2021

Revised: June 29, 2021

Accepted: November 15, 2021

Article in press: November 15, 2021

Published online: December 26, 2021

P-Reviewer: Surani S, Yoshizawa T

S-Editor: Wang JJ

L-Editor: Wang TQ

P-Editor: Wang JJ



diseases; Contrast-enhanced computed tomography; Acute appendicitis; Case report

©The Author(s) 2021. Published by Baishideng Publishing Group Inc. All rights reserved.

Core Tip: The article presents an uncommon clinical case of mesenteric vein thrombosis (MVT) complicated by acute appendicitis in a patient with no obvious risk factors for thrombosis. The patient was diagnosed correctly at an early stage and finally recovered after receiving anticoagulation and antibiotics. MVT is rare and difficult to recognize when it occurs with other acute abdominal diseases. Contrast-enhanced computed tomography is vital to its diagnosis. Therefore, clinicians should fully consider the possibility of this disease when treating patients with acute abdominal diseases and use appropriate diagnostic tests.

Citation: Yang F, Guo XC, Rao XL, Sun L, Xu L. Acute appendicitis complicated by mesenteric vein thrombosis: A case report. *World J Clin Cases* 2021; 9(36): 11400-11405

URL: <https://www.wjgnet.com/2307-8960/full/v9/i36/11400.htm>

DOI: <https://dx.doi.org/10.12998/wjcc.v9.i36.11400>

INTRODUCTION

Acute appendicitis is common in emergency departments but is rarely accompanied by mesenteric vein thrombosis (MVT). Numerous retrospective studies have revealed that acute MVT accounts for approximately 2%-10% of the total number of acute intestinal ischemia cases. The incidence rate in Europe and the United States is approximately 0.1%. Risk factors usually include tumors, infection, thrombosis history, inflammatory bowel disease, thrombophilia, cirrhosis, *etc.* Pathogenic factors comprise any conditions that may cause vascular endothelial injury, blood flow obstruction, or hypercoagulability[1]. MVT is more frequent in elderly individuals, although it could still happen in the young. The prognosis largely depends on prompt detection and intervention, while delayed diagnosis and treatment may lead to serious consequences, with mortality rates as high as 60%-80%[2]. The outcome of early simple acute appendicitis is good, but the presence of MVT poses an increased likelihood of adverse outcomes, such as intestinal necrosis, septic shock, or short bowel syndrome. MVT lacks specific clinical and laboratory manifestations in the early stage. The application of contrast-enhanced computed tomography (CT) can greatly improve the recognition of MVT and reduce the mortality of this disease[3].

CASE PRESENTATION

Chief complaints

A 37-year-old woman was admitted to the emergency department due to metastatic right lower abdominal pain, fever, and nausea present for 4 d.

History of present illness

The patient developed pain around the belly button 4 d ago, and the pain migrated to the right lower abdominal pain within 1 d with concomitant fever and nausea.

History of past illness

The patient had been treated with levofloxacin for acute gastroenteritis for 3 d prior but still had not improved.

Personal and family history

The patient had no special history.

Physical examination

The patient's vital signs were normal, and the only discovery was tenderness of the right McBurney's point.

Laboratory examinations

The laboratory tests performed on the day that the patient was admitted showed an increased neutrophil count of $13.11 \times 10^9/L$ and a decreased platelet count of $73 \times 10^9/L$; the fibrin-degradation-product and D-dimer levels were slightly higher.

Imaging examinations

A plain CT scan was routinely performed and suggested appendicitis with adjacent peritonitis. The radiologist suspected mesenteric ischemia and consequently scheduled the patient to receive contrast-enhanced CT, from which we noticed that the embolus was probably blocking the ileocolic vein.

Subsequently, the patient underwent another CT scan on the sixth day in the hospital, and the images showed less severe inflammation and exudation than before; however, the thrombus was still present in her ileocolic vein (Figure 1).

One month after discharge from the hospital, the patient received another CT scan (Figure 2), which showed that the inflammation and the embolized ileocolic vein had both resolved.

FINAL DIAGNOSIS

The final diagnosis of the presented case was acute appendicitis complicated by MVT.

TREATMENT

After admission, the patient received antibiotics and low-molecular-weight heparin (LMWH) as well as underwent fasting. Her temperature returned to normal on the second day, and her abdominal pain was relieved. The only complaint was a small amount of reddish-brown broken tissue excreted in her stool. Considering that the CT scan on her sixth day in the hospital showed a better result, she was allowed to gradually return to a regular diet on the seventh day, then placed on oral rivaroxaban instead of LMWH injection and finally discharged from the hospital on the tenth day.

OUTCOME AND FOLLOW-UP

The physician instructed the patient to stop rivaroxaban 3 d after discharge from the hospital and to receive another CT scan 1 mo later (Figure 2); this scan showed that the inflammation and the embolized ileocolic vein had both resolved. In subsequent follow-up to date, the patient has not complained of any other discomfort.

DISCUSSION

We present a female patient with no significant risk factors or history predisposing to thrombosis. She had a good prognosis after anticoagulation therapy due to accurate diagnosis by contrast-enhanced CT. MVT is rare, and its cause is not clear. Although patients may have a variety of possible pathogenic factors or none of the risk factors, approximately 75% of these patients with MVT have identifiable potential etiologic factors[4]. Other similar cases that have been reported suggest that acute appendicitis may induce MVT by causing local blood hypercoagulability, mesenteric phlebitis, or mesenteric perivascular inflammation, among others[5,6]. Since our case did not undergo surgery, we were unable to obtain a pathological diagnosis. However, the CT scan showed that the appendix and mesenteric perivascular inflammation occurred during the onset of the disease. The other CT scan 1 mo after the onset of illness indicated that the involved vein was completely occluded and that collateral circulation was established. Thus, we consider that the angiitis and periphlebitis could both play a major role in our case.

Acute MVT can happen at any age, though it is more common among elderly patients. Nonspecific gastrointestinal symptoms such as abdominal pain and nausea are often the only manifestation, and peritonitis or shock usually suggest advanced illness[7]. Although classic “pain out of proportion to examination” symptoms are typical, MVT does not have specific manifestations. Difficulties in diagnosis at the

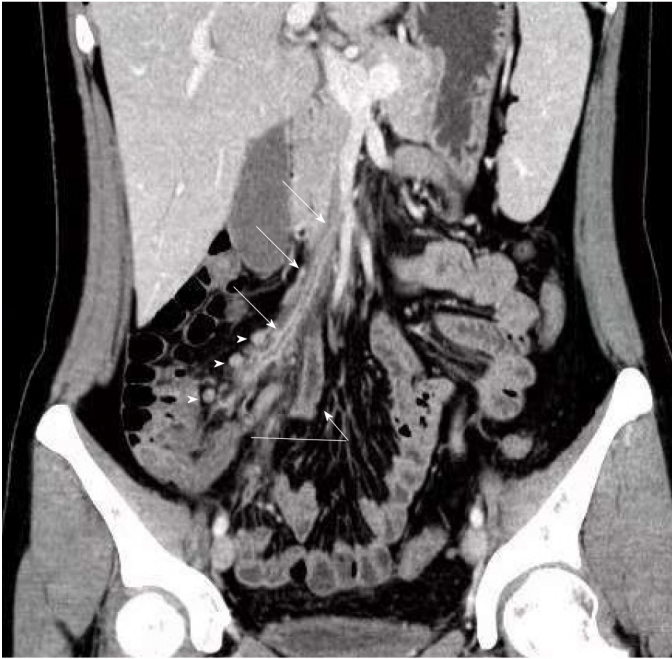


Figure 1 Contrast-enhanced computed tomography coronal reformatted image in the portal vein phase showed a filling defect consistent with a clot in the ileocolic vein (arrow) associated with surrounding inflammation of fat up to the superior mesenteric vein. Substantial appendiceal enlargement with inflammation indicative of acute appendicitis was observed (curve arrow). Moreover, enlarged lymph nodes within the mesentery was seen (arrowhead).

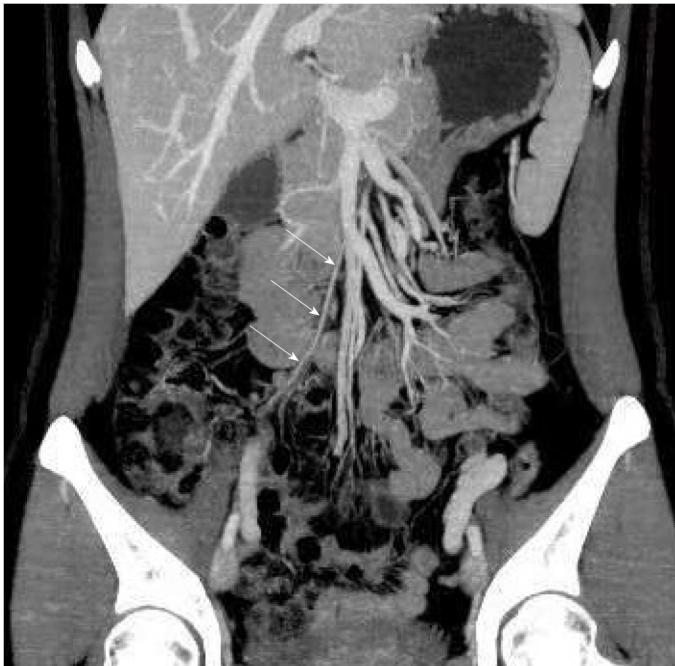

Figure 2 Follow-up computed tomography scan after 1 mo. Coronal reformatted image with maximum intensity projection showed the ileocolic artery (arrow). The site of previous thrombophlebitis in the ileocolic vein had disappeared, which indicated that the vein was completely occluded and that collateral circulation was established.

early stage will lead to delayed treatment and cause severe sequelae, especially in cases of MVT complicated with other acute abdominal diseases. Laboratory tests are usually not helpful for a definitive diagnosis, as the usual finding is an increased white blood cell count, which is not specific. Some patients can exhibit acidosis and increased blood lactic acid, which generally suggests a late stage[7-9]. In recent decades, contrast-enhanced CT has gradually become the preferred test in the diagnosis of ischemic bowel disease. Ischemic bowel disease has been increasingly recognized with

the widespread use of CT technology[2,10]. Other examination tools, such as angiography and magnetic resonance venous imaging, are often too time-consuming or invasive and are rarely used clinically[11]. The specific manifestation of MVT on CT imaging consists of venous filling defects, while nonspecific changes include abnormal or decreased intestinal-wall enhancement, intestinal-wall thickening or gas accumulation, *etc*, which are difficult to identify. However, some studies have shown that if clinicians suspect ischemic bowel disease, imaging can help identify this condition, which may reduce the rate of surgery[12].

Treatment of MVT mainly depends on the disease progression. For early-stage patients (especially those with acute thromboembolism), systemic anticoagulation, including LMWH and oral anticoagulants, is the most basic therapy. If treated promptly, the thrombus can disappear completely. However, interventional therapy and surgery are inescapable options for advanced patients or those with a poor response to conservative treatment[1,2,9,13]. There are no guidelines for the application of antibiotics in ischemic bowel disease. Ischemic bowel diseases such as MVT destroy the integrity of the intestinal mucosal barrier and cause translocation of intestinal flora at an early stage[14]. Therefore, broad-spectrum antibiotics (such as third-generation cephalosporins combined with antianaerobic drugs) are recommended to be administered as soon as possible. For patients with infectious complications such as appendicitis, antibiotics are definitely necessary.

CONCLUSION

MVT is an uncommon but possible complication of acute appendicitis and can lead to severe sequelae. Enhanced-contrast CT scans are essential for avoiding misdiagnosis of suspected MVT patients. Therefore, clinicians must have an awareness of and concern about MVT. Although they have more limitations than plain CT scans, enhanced-contrast CT scans are critical and sometimes inevitable in emergency departments.

REFERENCES

- 1 **Singal AK**, Kamath PS, Tefferi A. Mesenteric venous thrombosis. *Mayo Clin Proc* 2013; **88**: 285-294 [PMID: 23489453 DOI: 10.1016/j.mayocp.2013.01.012]
- 2 **Clair DG**, Beach JM. Mesenteric Ischemia. *N Engl J Med* 2016; **374**: 959-968 [PMID: 26962730 DOI: 10.1056/NEJMra1503884]
- 3 **Copin P**, Zins M, Nuzzo A, Purcell Y, Beranger-Gibert S, Maggiori L, Corcos O, Vilgrain V, Ronot M. Acute mesenteric ischemia: A critical role for the radiologist. *Diagn Interv Imaging* 2018; **99**: 123-134 [PMID: 29433829 DOI: 10.1016/j.diii.2018.01.004]
- 4 **Beckermann J**, Walker A, Grewe B, Appel A, Manz J. Mesenteric venous thrombosis complicating acute appendicitis: A case series. *Int J Surg Case Rep* 2020; **73**: 100-104 [PMID: 32652248 DOI: 10.1016/j.ijscr.2020.06.099]
- 5 **Takehara K**, Miyano S, Machida M, Kitabatake T, Fujisawa M, Kojima K. Superior mesenteric vein thrombosis as a complication of acute appendicitis : report of a case. *Clin J Gastroenterol* 2013; **6**: 269-273 [PMID: 23990849 DOI: 10.1007/s12328-013-0390-1]
- 6 **Chang YS**, Min SY, Joo SH, Lee SH. Septic thrombophlebitis of the porto-mesenteric veins as a complication of acute appendicitis. *World J Gastroenterol* 2008; **14**: 4580-4582 [PMID: 18680244 DOI: 10.3748/wjg.14.4580]
- 7 **Tilsed JV**, Casamassima A, Kurihara H, Mariani D, Martinez I, Pereira J, Ponchiotti L, Shamiyeh A, Al-Ayoubi F, Barco LA, Ceolin M, D'Almeida AJ, Hilario S, Olavarria AL, Ozmen MM, Pinheiro LF, Poeze M, Triantos G, Fuentes FT, Sierra SU, Soreide K, Yanar H. ESTES guidelines: acute mesenteric ischaemia. *Eur J Trauma Emerg Surg* 2016; **42**: 253-270 [PMID: 26820988 DOI: 10.1007/s00068-016-0634-0]
- 8 **Dewitte A**, Biais M, Coquin J, Fleureau C, Cassinotto C, Ouattara A, Janvier G. [Diagnosis and management of acute mesenteric ischemia]. *Ann Fr Anesth Reanim* 2011; **30**: 410-420 [PMID: 21481561 DOI: 10.1016/j.annfar.2011.02.013]
- 9 **Bala M**, Kashuk J, Moore EE, Kluger Y, Biffl W, Gomes CA, Ben-Ishay O, Rubinstein C, Balogh ZJ, Civil I, Coccolini F, Leppaniemi A, Peitzman A, Ansaloni L, Sugrue M, Sartelli M, Di Saverio S, Fraga GP, Catena F. Acute mesenteric ischemia: guidelines of the World Society of Emergency Surgery. *World J Emerg Surg* 2017; **12**: 38 [PMID: 28794797 DOI: 10.1186/s13017-017-0150-5]
- 10 **Kärkkäinen JM**, Acosta S. Acute mesenteric ischemia (part I) - Incidence, etiologies, and how to improve early diagnosis. *Best Pract Res Clin Gastroenterol* 2017; **31**: 15-25 [PMID: 28395784 DOI: 10.1016/j.bpg.2016.10.018]
- 11 **Russell CE**, Wadhwa RK, Piazza G. Mesenteric venous thrombosis. *Circulation* 2015; **131**: 1599-1603 [PMID: 25940967 DOI: 10.1161/CIRCULATIONAHA.114.012871]

- 12 **Lehtimäki TT**, Kärkkäinen JM, Saari P, Manninen H, Paajanen H, Vanninen R. Detecting acute mesenteric ischemia in CT of the acute abdomen is dependent on clinical suspicion: Review of 95 consecutive patients. *Eur J Radiol* 2015; **84**: 2444-2453 [PMID: 26413771 DOI: 10.1016/j.ejrad.2015.09.006]
- 13 **Kärkkäinen JM**, Acosta S. Acute mesenteric ischemia (Part II) - Vascular and endovascular surgical approaches. *Best Pract Res Clin Gastroenterol* 2017; **31**: 27-38 [PMID: 28395785 DOI: 10.1016/j.bpg.2016.11.003]
- 14 **Wong PF**, Gilliam AD, Kumar S, Shenfine J, O'Dair GN, Leaper DJ. Antibiotic regimens for secondary peritonitis of gastrointestinal origin in adults. *Cochrane Database Syst Rev* 2005; CD004539 [PMID: 15846719 DOI: 10.1002/14651858.CD004539.pub2]



Published by **Baishideng Publishing Group Inc**
7041 Koll Center Parkway, Suite 160, Pleasanton, CA 94566, USA

Telephone: +1-925-3991568

E-mail: bpgoffice@wjgnet.com

Help Desk: <https://www.f6publishing.com/helpdesk>

<https://www.wjgnet.com>

