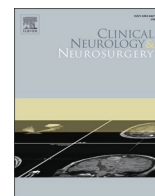




Since January 2020 Elsevier has created a COVID-19 resource centre with free information in English and Mandarin on the novel coronavirus COVID-19. The COVID-19 resource centre is hosted on Elsevier Connect, the company's public news and information website.

Elsevier hereby grants permission to make all its COVID-19-related research that is available on the COVID-19 resource centre - including this research content - immediately available in PubMed Central and other publicly funded repositories, such as the WHO COVID database with rights for unrestricted research re-use and analyses in any form or by any means with acknowledgement of the original source. These permissions are granted for free by Elsevier for as long as the COVID-19 resource centre remains active.



## Case Report

## Neuropsychiatric syndrome with myoclonus after SARS-CoV-2 infection in a paediatric patient

M. Della Corte<sup>a,\*</sup>, C. Delehay<sup>b</sup>, E. Savastano<sup>a</sup>, M.F. De Leva<sup>a</sup>, P. Bernardo<sup>c</sup>, A. Varone<sup>a</sup><sup>a</sup> Department of Neurosciences, Pediatric Neurology, Santobono-Pausilipon Children's Hospital, Via M. Fiore 6, 80129 Naples, Italy<sup>b</sup> Department of Paediatrics, University of Campania "Luigi Vanvitelli", Piazza L. Miraglia, 2, 80138 Naples, Italy<sup>c</sup> Department of Neurosciences, Pediatric Psychiatry and Neurology Santobono-Pausilipon Children's Hospital, Via M. Fiore 6, 80129 Naples, Italy

## ARTICLE INFO

## Keywords:

COVID-19  
Neurological complications  
Myoclonus  
Paediatric

## ABSTRACT

We report the case of a 12-years-old patient who subacutely developed a positive and negative myoclonus of limbs and face, drowsiness and memory deficits after getting infected by SARS-CoV-2. On admission, nasopharyngeal swab for SARS-CoV-2, brain and spinal MRI with and without contrast, EEG, chest X-ray and abdominal ultrasound were negative. CSF physical-chemical examination, culture, PCR testing for SARS-CoV-2 and other pathogens, and oligoclonal IgG bands were negative as well. A full panel blood test, including clotting, autoimmunity and paraneoplastic blood studies, did not show any alteration. The neuropsychological examination showed an impairment in memory, visual-motor coordination, inductive reasoning skills, attention, and concentration. The patient was first treated with clonazepam and then with intravenous methylprednisolone for five days, with poor response. For this reason, he then received a cycle of IVIG, thus reaching a gradual and complete recovery. To date, this is the first case of a COVID-19 associated myoclonus affecting a paediatric patient.

## 1. Introduction

The coronavirus disease (COVID-19), due to SARS-CoV-2, was first identified in December 2019 and, since then, has gradually spread throughout the world. Although COVID-19 is mainly a respiratory disease, up to 73% of patients present with neurological symptoms, including anosmia, hypogeusia/ageusia, cerebrovascular events, encephalopathy, meningoencephalitis, seizures, cerebellar ataxia, polyradiculopathy, myopathy, myelitis, and myoclonus [1]. Myoclonus is an abrupt, involuntary, and brief muscle jerk, which is caused by the sudden contraction of a muscle group (positive myoclonus), or by the sudden discontinuation of the muscle activity (negative myoclonus). Although rare, infections are recognised to be a possible cause of this manifestation [2]. In the context of COVID-19, there are several reported cases of myoclonus in the adult population, occurring either as the consequence of the ongoing infection, or as post-infectious syndrome [1, 3]. However, no cases of COVID-19 related myoclonus have been described in the paediatric population, although there are cases of post-infectious myoclonus in children [4].

We present, as far as we know, the first case of a neuropsychiatric

syndrome including myoclonus in a child with a previous COVID-19 infection.

## 2. Case presentation

We describe the case of a 12-year-old previously healthy boy, who developed a neuropsychiatric syndrome after COVID-19 infection. At the beginning of February 2021, for the occurrence of persistent fatigue the patient presented to the paediatric hospital, where he received the diagnosis of paucisymptomatic COVID-19 through a positive SARS-CoV-2 RT-PCR testing. The boy was therefore hospitalised for 3 days, and during the course of infection he didn't develop fever and respiratory symptoms. However, he exhibited a mild anxiety, memory deficits, dysarthria (slurred and slow speech) and sporadic positive myoclonus involving the axial muscles and limbs, with a left sided predominance. These movements interfered with finalised movements, such as writing. In the light of these symptoms, he underwent a brain CT scan and electroencephalogram (EEG), which didn't show any alteration, and therefore neurologic manifestations were explained as anxiety-related disorders. During his short hospitalisation, he also carried out routine

*Abbreviations:* COVID-19, Coronavirus Disease; CNS, Central Nervous System; CSF, Cerebrospinal fluid; MRI, magnetic resonance imaging; EEG, electroencephalogram; IVIG, Intravenous Immunoglobulin; VC, Verbal Comprehension; PR, Perceptual Reasoning; WM, Working Memory; PS, Processing Speed.

\* Correspondence to: Department of Neurosciences, Pediatric Neurology, Santobono-Pausilipon Children's Hospital, Naples, Italy.

E-mail address: [m.dellacorte@santobonopausilipon.it](mailto:m.dellacorte@santobonopausilipon.it) (M. Della Corte).

<https://doi.org/10.1016/j.clineuro.2022.107121>

Received 24 June 2021; Received in revised form 29 December 2021; Accepted 4 January 2022

Available online 7 January 2022

0303-8467/© 2022 Elsevier B.V. All rights reserved.

blood exams and abdominal ultrasound, which resulted negative.

About a month later, given that the pre-existing symptoms were increasing, he was admitted to the Neurology Division. On admission, nasopharyngeal swab RT-PCR testing for SARS-CoV-2 was negative. Vital signs and physical examination were normal. At the neurological exam, he appeared drowsy. Pupillary reflexes and cranial nerves were normal. Deep tendon reflexes were overly evoked, bilateral foot clonus was present, Babinski sign was bilaterally negative. Segmental strength of the four limbs was preserved. However, the patient presented diffuse involuntary jerky movements, without opsoclonus. Myoclonus occurred both spontaneously and after tactile stimuli, especially on proximal limb muscles (*Video 1*) and on the face. His gait was hindered by his involuntary movements. He complained of severe asthenia, memory issues and difficulty in recognising familiar faces. Brain and spine magnetic resonance imaging (MRI) with and without contrast was unremarkable. Awake and sleep EEG showed a normal electrical brain activity, in the absence of epileptic anomalies during the occurrence of the involuntary movements.

Supplementary material related to this article can be found online at [doi:10.1016/j.clineuro.2022.107121](https://doi.org/10.1016/j.clineuro.2022.107121).

The patient's intellectual function was extensively assessed via clinical observations, psychological interviews, and multiple neuropsychological examinations. Involuntary movements, more prevalent on the left side, were frequently observed over the course of the tests (*Video 2*). He was cooperative and available for the interview, his language comprehension and expression were good, despite attention and concentration were deficient. The patient mostly displayed low mood, apathy, reduced emotional intensity and minimal expressiveness. He also exhibited high insecurity and anxiety, requiring constant reassurance while performing the required tasks and tests. Intellectual ability was measured through WISC-IV test, which showed an inhomogeneous cognitive profile: Verbal Comprehension (VC) Index was 95, Perceptual Reasoning (PR) Index was 56, Working Memory (WM) Index was 70, and Processing Speed (PS) Index was 47, resulting in Full Scale IQ of 58 (extremely low). As shown in [Table 1](#), IQ was affected by a performance drop in PS and PR tests. Higher scores were achieved in Similarities (sc = 9) and Comprehension (sc = 10) subtests, which reflected a good comprehension of social rules and sufficient abilities in the verbal reasoning area. Lower scores were reached in Coding (sc = 1), Matrix Reasoning (sc = 1) and Symbol Search (sc = 1) subtests, thus indicating an impairment in visual-motor coordination, inductive reasoning skills, attention, and concentration. In fact, there was a significant discrepancy between General Ability Index (equal to 73) and Cognitive Proficiency Index (equal to 48), that may be caused by a deficit of executive functions. Non-verbal cognitive abilities were measured through Leiter-3 test, that showed a borderline score for non-verbal memory (sc = 76), and a low score for processing speed (sc = 66). Memory was furtherly assessed via BVN battery, a set of neuropsychological tests validated for Italian children, which showed an impairment of free recall, immediate and delayed memory.

Supplementary material related to this article can be found online at [doi:10.1016/j.clineuro.2022.107121](https://doi.org/10.1016/j.clineuro.2022.107121).

The patient also underwent a full panel of laboratory tests. Complete blood count, electrolytes, glucose, renal and hepatic function tests, inflammatory markers and tox screen were normal. Physical-chemical examination of CSF (Cerebrospinal fluid) was completely normal and

**Table 1**  
WISC-IV scores.

Subscales	Sum of weighted scores	Indexes/IQ
Verbal Comprehension (VC)	27	95
Perceptual Reasoning (PR)	10	56
Working Memory (WM)	10	70
Processing Speed (PS)	2	47
Total (IQ)	49	51

no bacterial exoantigens (N. meningitidis A, N. meningitidis C, N. meningitidis B/E.Coli K1, N. meningitidis Y/W135, H. Influenzae type B, S. pneumoniae and Group B Streptococcus) were detected. Also, Multiplex PCR tests (FilmArray) for virus (SARS-CoV-2, Cytomegalovirus, Enterovirus, Herpes simplex 1–2, Human herpesvirus 6, Human parvovirus) and bacteria (E. Coli K1, H. Influenzae, L. monocytogenes, N. meningitidis, S. agalactiae and S. pneumoniae) were negative. CSF oligoclonal bands were absent, and IgG, IgA, IgM, albumin, and Link index were within normal range.

Serological antibodies and blood RT-PCR (FilmArray) for other infectious diseases (Toxoplasma Gondii, Rubella, Adenovirus, Human Herpes virus 1-2-6, Epstein-Barr virus, Cytomegalovirus, Parvovirus B19, Mycoplasma Pneumoniae, Chlamydia Pneumoniae), anti-streptolysin O test and throat swab for virus and bacteria were negative.

Neuronal Surface Antibodies (NMDAr IgG, anti-LGI, anti-CASPR2, anti-GABA b receptor, anti-GluR1/AMPA1, anti-GluR2/AMPA2) for the screening of potential neurological autoimmune diseases, were negative (analysed at the Neuroimmunology Laboratory of the *IRCCS National Neurological Institute C. Mondino Foundation in Pavia, Italy*).

Furthermore, onconeural antibodies with intracellular and extracellular targets (anti-amphiphysin, anti-CV2/CRMP5, anti-Hu, anti-Ma1, anti-Ma2, anti-recoverin, anti-Ri, anti-Yo, ANNA-1, ANNA-2, ANNA-3, anti-VGKC-related proteins, anti-mGluR1, anti-Tr, anti-Zic4, PCA-1, PCA-2, anti-SOX1, anti-titin, AGNA-1, anti-ganglionic Ach R, anti-GAD65, anti-muscle AchR, anti-VGCC, anti-VGKC, anti-mGluR1, and anti-NMDA, striational antibodies) were negative, thus excluding paraneoplastic neurological syndromes.

Coagulation disorders were also ruled out since first level (PT, aPTT, INR, antithrombin, Clauss fibrinogen, D-dimer), second level (Protein C, Protein S, Activated Protein C Resistance V, homocysteine) and third level clotting tests, including Lupus Anticoagulant DRVVT and Silica Clotting Time tests, Antiphospholipid Antibody syndrome screening tests (anti-cardiolipin IgG and IgM, anti-b2 beta2-glycoprotein IgG and IgM, anti-prothrombin IgG and IgM), the dosage of FVIII, FIX and FXI levels, the determination of DNA FII (20210A > G) and DNA FV (1691G > A) via Real Time PCR and a qualitative in vitro diagnostic genotyping test for the detection of Factor II and Factor V mutations (Xpert HemosIL Factor II & Factor V Assay) were all within normal range.

Chest X-ray, abdominal and testicular ultrasound were normal as well.

For generalised myoclonus, a symptomatic treatment with clonazepam (0,02 mg/kg/day) was introduced, without clinical improvement. Therefore, clonazepam was discontinued and replaced by intravenous methylprednisolone (10 mg/kg/day) for five days, then followed by a prolonged oral prednisone taper. In the light of the poor response, at the end of the intravenous steroid therapy, a cycle of five days of intravenous immunoglobulin (IVIG) was started (0.4 g/kg/day), with a consequent progressive reduction of his involuntary movements (*Video 3*) and an evident improvement of cognitive performances too.

Supplementary material related to this article can be found online at [doi:10.1016/j.clineuro.2022.107121](https://doi.org/10.1016/j.clineuro.2022.107121).

During the two weeks of hospitalisation, several cognitive and psychodiagnostics tests were administered, which revealed a gradual improvement in motor and cognitive functions. However, a generalised anxiety disorder and a mild attentional and memory deficit (BNV battery, Leiter-3 test) were still persistent at the time of hospital discharge.

A further neuropsychological evaluation, made one month after the beginning of the second hospitalisation, showed a full recovery of motor functions and an additional improvement of anxiety symptoms, concentration, attention and memory.

### 3. Discussion

Myoclonus in the context of COVID-19 has been increasingly reported in the adult population since SARS-CoV-2 infection has gradually spread worldwide [3]. Among paediatric patients, no cases of COVID-19

related myoclonus have been reported so far, nevertheless viral infections have been recognised to be rare, but possible, triggers for this neurological symptom [4].

In the present case, a large number of diagnostic procedures have been conducted in order to rule out other causes of myoclonus. Anti-neuronal antibody testing, as well as brain and spinal MRI, EEG, blood, and CSF exams were negative.

As regards to the onset of neurological manifestations, among adult population, the onset of a COVID-19 related myoclonus always occurred after the appearance of the symptoms of infections, with a latency period varying from 7 to 48 days, and with generally unremarkable CSF, MRI and CT findings. Moreover, in these patients, myoclonus is mostly generalised, spontaneous and stimulus induced [3].

However, in the present case, we were not able to reconstruct the precise timeline of symptoms, and therefore the exact time span between the beginning of infection and the onset of neurologic symptoms since we cannot know precisely when the patient has been infected by SARS-CoV-2. Furthermore, the first positive RT-PCR testing was performed for the occurrence of persistent fatigue and, given that the clinical course of COVID-19 in our patient was paucisymptomatic, it is very difficult to clinically determine the beginning of the infection.

In our report, the patient also experienced concomitant cognitive deficits and psychiatric changes, which have been also reported in about the 30% of adults with post-COVID-19 myoclonus [3].

Regarding therapeutic approaches, anti-epileptic drugs are widely used, including levetiracetam, clonazepam, valproic acid, and primidone [3]. Immune-therapy is reserved to post-infectious and immune-mediated myoclonus, and involves the use of intravenous methylprednisolone, IVIG and plasmapheresis [3]. Although we don't have data on paediatric patients, we can affirm that the time needed to reach a full recovery in our patient is consistent with the one reported in the adult population (1–60 days) [3].

The underlying pathogenic pathways involved in post-COVID-19 myoclonus may be different. The direct invasion of the Central Nervous System (CNS) by SARS-CoV-2 is possible, even if just in a few cases the virus has been directly detected in CSF and brain [1]. In the context of a severe form of COVID-19, the massive release of cytokines and metabolic derangements, also play a role in CNS involvement. A severe hypoxia may be the cause of myoclonus too [1,3,5]. Furthermore, it cannot be excluded that a prolonged and paucisymptomatic hypoxia, that is common in this infection, may trigger myoclonus [5]. Finally, as in our and other reports, some cases of myoclonus occur in the apparent absence of a secondary aetiology, and these cases are therefore considered to be immune-mediated and post-infectious disorders. The occurrence of other post-infectious syndromes after COVID-19, such as acute disseminated encephalomyelitis, help to furtherly corroborate the hypothesis that post-COVID-19 myoclonus could recognise an immune-mediated mechanism [1,3,5].

In the present case, we assumed myoclonus to be post-infectious, both for the timing of appearance of this manifestation (consistent with the adult population [3]) and for the lack of evidence of an ongoing infection sustained by SARS-CoV-2. However, given that the temporal association between the two events is not sufficient to establish if this is

a COVID-19 related disorder, we extensively investigated to find other possible causes of myoclonus, without any evidence of other underlying disorders.

Another factor in favour of our hypothesis is that the use of IVIG has proven to be promptly effective, determining a clear clinical improvement right after the end of the five-days cycle. However, it is quite difficult to understand if the patient has partially recovered thanks to IVIG or if his improvement is simply related to the natural course of the disease over time.

We believe that our report is important because it increases knowledge about neurological complications of COVID-19. Although the patient's improvement may have represented the natural course of the disease, it may suggest that IVIG should be considered as a therapeutic approach in other patients with similar post-COVID findings. Moreover, it underlines the possible effectiveness of IVIG as a valid alternative to corticosteroid treatment. However, we recognise that the main limitation in our report is the lack of serological and CSF tests to see what sort of immune response the patient had raised against SARS-CoV-2. Another limitation is the unavailability of polymyography.

#### 4. Conclusions

With this case we want to emphasise that neurological complications related to COVID-19 also occur in paediatric population. Despite post-COVID-19 myoclonus is considered to be a self-limited manifestation in adults, data on paediatric population are still limited. Further studies are needed to better define the neurological and neuropsychiatric complications involving children in the context of COVID-19.

#### Disclosure statement

All the authors declare that they have no known competing financial interests or personal relationships that could have appeared to influence the work reported in this paper.

#### References

- [1] A. Maury, A. Lyoubi, N. Peiffer-Smadja, T. de Broucker, E. Meppiel, Neurological manifestations associated with SARS-CoV-2 and other coronaviruses: a narrative review for clinicians, *Rev. Neurol.* 177 (1–2) (2021) 51–64, <https://doi.org/10.1016/j.neuro.2020.10.001>.
- [2] R. Zutt, M.E. van Egmond, J.W. Elting, P.J. van Laar, O.F. Brouwer, D.A. Sival, H. P. Kremer, T.J. de Koning, M.A. Tijssen, A novel diagnostic approach to patients with myoclonus, *Nat. Rev. Neurol.* 11 (12) (2015) 687–697, <https://doi.org/10.1038/nrneurol.2015.198>.
- [3] J.L. Chan, K.A. Murphy, J.R. Sarna, Myoclonus and cerebellar ataxia associated with COVID-19: a case report and systematic review, *J. Neurol.* (2021) 1–32, <https://doi.org/10.1007/s00415-021-10458-0> (Epub ahead of print. PMID: 33616739; PMCID: PMC7897737).
- [4] V. Delucchi, E. Pavlidis, B. Piccolo, F. Pisani, Febrile and postinfectious myoclonus: case reports and review of the literature, *Neuropediatrics* 46 (1) (2015) 26–32, <https://doi.org/10.1055/s-0034-1395347>.
- [5] P. Anand, A. Zakaria, K. Benameur, C. Ong, M. Putman, S. O'Shea, D. Greer, A. M. Cervantes-Arslanian, Myoclonus in patients with coronavirus disease 2019: a multicenter case series, *Crit. Care Med.* 48 (11) (2020) 1664–1669, <https://doi.org/10.1097/CCM.0000000000004570>.