

Morphology of the Trabecular Meshwork and Schlemm's Canal in Posner-Schlossman Syndrome

Xiaoqin Yan,¹ Mu Li,² Junming Wang,¹ Hong Zhang,¹ Xiongwu Zhou,¹ and Zhiqi Chen¹

¹Department of Ophthalmology, Tongji Hospital, Tongji Medical College, Huazhong University of Science and Technology, Wuhan, China

²Department of Ophthalmology, Union Hospital, Tongji Medical College, Huazhong University of Science and Technology, Wuhan, China

Correspondence: Zhiqi Chen, Postal address: No. 1095, Jiefang Road, Wuhan, Hubei, China; 66czq@163.com.

XY and ML contributed equally to this work.

Received: September 7, 2021

Accepted: December 7, 2021

Published: January 3, 2022

Citation: Yan X, Li M, Wang J, Zhang H, Zhou X, Chen Z. Morphology of the trabecular meshwork and Schlemm's canal in Posner-Schlossman syndrome. *Invest Ophthalmol Vis Sci.* 2022;63(1):1. <https://doi.org/10.1167/iovs.63.1.1>

PURPOSE. The purpose of this study was to investigate trabecular meshwork (TM) and Schlemm's canal (SC) morphology in Posner-Schlossman syndrome (PSS).

METHODS. Forty-five patients with PSS were recruited. TM thickness and length as well as SC area and diameter of both affected and fellow eyes were assessed using swept-source optical coherence tomography.

RESULTS. TM thickness ($108.24 \pm 28.29 \mu\text{m}$ vs. $89.36 \pm 25.82 \mu\text{m}$, $P = 0.014$), SC area ($6010.90 \pm 1287.54 \mu\text{m}^2$ vs. $5445.69 \pm 1368.89 \mu\text{m}^2$, $P = 0.003$), and SC diameter ($239.38 \pm 60.17 \mu\text{m}$ vs. $217.76 \pm 60.79 \mu\text{m}$, $P = 0.010$) were significantly greater in the affected eyes. Furthermore, TM thickness ($113.32 \pm 30.03 \mu\text{m}$ vs. $89.00 \pm 26.99 \mu\text{m}$, $P = 0.046$), SC area ($6216.32 \pm 1267.87 \mu\text{m}^2$ vs. $5476.40 \pm 1390.15 \mu\text{m}^2$, $P = 0.001$), and SC diameter ($246.82 \pm 64.12 \mu\text{m}$ vs. $212.53 \pm 64.29 \mu\text{m}$, $P = 0.001$) were significantly greater in the affected eyes than in the fellow eyes in the ocular hypertension (OHT) subgroup (affected eye with intraocular pressure [IOP] > 21 mm Hg). However, those differences were not noted in the ocular normal tension (ONT) subgroup (affected eye with IOP ≤ 21 mm Hg, all $P > 0.05$).

CONCLUSIONS. TM edema might play a role in the IOP elevation in PSS. The edematous TM could make controlling IOP of the affected eyes difficult. When TM edema is relieved, IOP of the affected eyes can reduce to normal spontaneously or with IOP-lowering medications.

Keywords: Posner-Schlossman syndrome, trabecular meshwork, Schlemm's canal, intraocular pressure, swept-source optical coherence tomography

Posner-Schlossman syndrome (PSS), which was first reported by Posner and Schlossman in 1948, is characterized by recurrent and acute attacks of unilateral, relatively mild, non-granulomatous anterior uveitis. PSS attacks are usually accompanied by significant elevations in intraocular pressure (IOP).^{1,2} The etiology and pathology of PSS remain unclear to date. In recent years, several factors, such as viral infection, autoimmunity, allelic heterogeneity, aqueous cytokine profile, and vascular endothelial dysfunction, have been suggested to contribute to PSS pathogenesis.³⁻⁷

During the acute period of PSS, IOP can increase to 40 mm Hg or higher, with the anterior chamber angle remaining open and the visual field and optic disc appearing normal.¹ PSS is typically self-limited and can be relieved by anti-inflammatory and IOP-lowering medications.⁸ Although a single acute attack usually causes no damage to the optic nerve, repeated attacks might lead to secondary glaucomatous optic nerve changes over 5 to 10 years after the initial onset.^{9,10} To avoid secondary glaucomatous optic nerve injury, IOP control during acute attacks of PSS is important.

A total of 75% to 80% of aqueous humor flows out through the conventional trabecular meshwork (TM)-

Schlemm's canal (SC) pathway.¹¹ Previous studies have indicated that the status of the TM-SC pathway is closely associated with aqueous humor outflow capacity, as well as changes in IOP.^{12,13} A thick and edematous TM (trabeculitis) has been proposed to potentially play a key role in the elevation of IOP during acute attacks of PSS.¹⁴ However, no study to date has reported on the morphological changes in TM in patients with PSS, and there is still no clinical observational evidence supporting the aforementioned hypothesis (trabeculitis leads to the elevation of IOP in patients with PSS). Thus, this study aimed to compare the TM and SC morphology between the affected and fellow eyes in patients with PSS and to investigate whether TM edema is involved in IOP elevation in PSS-affected eyes, using swept-source optical coherence tomography (SS-OCT).

METHODS

This cross-sectional observational study was approved by the ethics committee of Tongji Hospital, Huazhong University of Science and Technology and was in adherence to the tenets of the Declaration of Helsinki. All study subjects provided written informed consent prior to participation in the study.

Subjects

Forty-five patients with PSS were recruited and underwent ophthalmic examinations, including slit-lamp examination, gonioscopy, corneal endothelial microscope, fundus photography, and measurements of axial length (AL; IOL-Master; Carl Zeiss Meditec, Dublin, CA, USA) and IOP. The diagnostic criteria were (1) unilateral and recurrent attack, (2) transient episodes of IOP elevation with blurred vision, (3) mild anterior chamber inflammation and/or hoar and white suet-shaped keratic precipitates (KPs), and (4) open anterior chamber angle without iris synechia.^{8,15} Patients with a history of ocular surgery or systemic diseases (e.g. hypertension and diabetic mellitus) were excluded from the study recruitment.

The patients were further divided into two subgroups based on the IOP of the affected eyes: the ocular hypertension (OHT) subgroup (IOP of affected eye >21 mm Hg) and the ocular normal tension (ONT) subgroup (IOP of affected eye ≤ 21 mm Hg). The OHT subgroup involved patients with PSS whose IOP could not be controlled within the normal range with medications. The ONT subgroup involved patients with PSS whose IOP could be controlled within the normal range with or without medications.

SS-OCT Imaging Acquisition and Processing

Both the affected and fellow eyes of the recruited patients underwent SS-OCT examinations. The participants were instructed to open their eyes wide during the examination. The nasal and temporal limbi were recorded separately after adjusting the fixture to the corresponding areas. The scans were performed three times, and the best quality image was chosen for analysis.

Measurements of TM Thickness and Length, SC Area, and Diameter

A thin, black lucent space represented the SC on SS-OCT images. Optimal image magnification and contrast were subjectively defined to maximize SC visualization. The SC area was manually drawn freehand based on the outlines of the SC.¹³ The SC diameter was measured from the posterior to the anterior SC end point.¹⁶ TM thickness was calculated as the average value of two measurements made at the halfway point and the anterior end point of the SC inner wall. Each TM thickness measurement was performed perpendicular to the TM inner layer, beginning at the SC inner wall.^{13,16,17} TM length was defined as the meridional length from the hyper-reflective point closest to the scleral spur (TM posterior end point) to the hyper-reflective point closest to the Schwalbe line (TM anterior end point¹⁷⁻¹⁹; Fig. 1). All measurements were performed using ImageJ software (National Institutes of Health, Bethesda, MD, USA), and all measurements were masked to the subject information.

Statistical Analysis

Data are presented as the mean ± standard deviation where applicable. Differences between the affected and fellow eyes were compared using paired *t*-tests for continuous variables and using the chi-square test for categorical variables. Parameters, including nasal and temporal measurement results, were compared using general estimate equations (GEEs), which take into account the correlation between

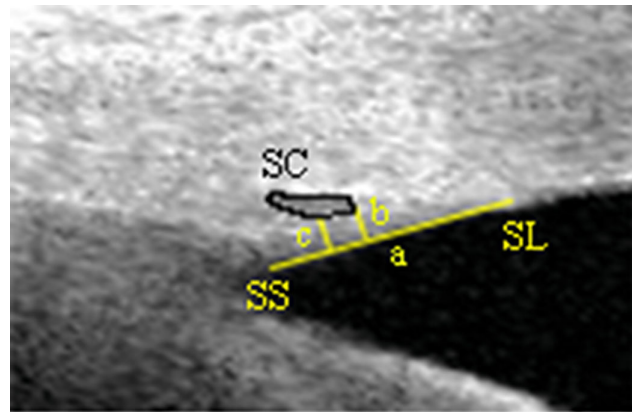


FIGURE 1. Measurements of TM and SC parameters. The yellow line a indicates the measurement of trabecular meshwork length; the yellow lines b and c indicate the measurement of trabecular meshwork thickness; the black curve indicates Schlemm's canal. SS, scleral spur; SL, Schwalbe's line; SC, Schlemm's canal.

the measurements from the nasal and temporal quadrants of one eye. Linear regression was used to determine the associations among TM thickness, SC area, SC diameter, and IOP. Adjusted β coefficients for the associations between the independent and dependent variables were assessed using GEEs. All analyses were conducted using the R software version 3.4.3 (<https://www.r-project.org>). All tests were two-tailed, and statistical significance was defined as a *P* value of < 0.05.

RESULTS

The mean patient age was 36.58 ± 13.05 years. In total, 22 of 45 (48.9%) patients were male patients, whereas 23 of 45 (51.1%) were female patients. There was no significant difference in AL between the affected and fellow eyes (24.05 ± 0.99 mm vs. 24.02 ± 0.95 mm, *P* = 0.420). Meanwhile, the corneal endothelium density (2388 ± 466/mm² vs. 2698 ± 313/mm², *P* < 0.001) was significantly lower and IOP (24.0 ± 12.7 mm Hg vs. 17.2 ± 3.3 mm Hg, *P* = 0.001) was significantly higher in the affected eyes than in the fellow eyes (Table 1).

Comparisons of TM and SC Parameters Between the Affected and Fellow Eyes

TM thickness (108.24 ± 28.29 μm vs. 89.36 ± 25.82 μm, *P* = 0.014), SC area (6010.90 ± 1287.54 μm² vs. 5445.69 ± 1368.89 μm², *P* = 0.003), and SC diameter (239.38 ± 60.17 μm vs. 217.76 ± 60.79 μm, *P* = 0.010) were significantly greater in the affected eyes than in the fellow eyes. Meanwhile, there was no significant difference in TM length

TABLE 1. Subject Characteristics

	Affected Eye	Fellow Eye	<i>P</i> Value
Age, y	36.58 ± 13.05	36.58 ± 13.05	-
Sex, M/F	22/23	22/23	-
Axial length, mm	24.05 ± 0.99	24.02 ± 0.95	0.420
Corneal endothelium density, /mm ²	2388 ± 466	2698 ± 313	<0.001*
Intraocular pressure, mm Hg	24.0 ± 12.7	17.2 ± 3.3	0.001*

* Paired *t*-test.

TABLE 2. Comparisons of TM and SC Parameters Between the Affected and Fellow Eyes

	Affected Eye	Fellow Eye	<i>P</i> Value
TM thickness, μm	108.24 \pm 28.29	89.36 \pm 25.82	0.014*
TM length, μm	710.00 \pm 152.03	683.22 \pm 124.30	0.158
SC area, μm^2	6010.90 \pm 1287.54	5445.69 \pm 1368.89	0.003*
SC diameter, μm	239.38 \pm 60.17	217.76 \pm 60.79	0.010*

* General estimate equations.

TABLE 3. Comparisons of TM and SC Parameters Between the Affected and Fellow Eyes by Subgroup

Ocular Hypertension (OHT) Group (Affected Eye With IOP > 21 mm Hg, n = 21)

	Affected Eye	Fellow Eye	<i>P</i> Value
TM thickness, μm	113.32 \pm 30.03	89.00 \pm 26.99	0.046*
TM length, μm	719.67 \pm 169.39	671.35 \pm 135.39	0.191
SC area, μm^2	6216.32 \pm 1267.87	5476.40 \pm 1390.15	0.001*
SC diameter, μm	246.82 \pm 64.12	212.53 \pm 64.29	0.001*

Ocular normal tension (ONT) group (affected eye with IOP \leq 21 mm Hg, n = 24)

	Affected Eye	Fellow Eye	<i>P</i> Value
TM thickness, μm	104.48 \pm 27.75	89.63 \pm 25.28	0.128
TM length, μm	702.60 \pm 138.71	691.81 \pm 116.36	0.546
SC area, μm^2	5859.07 \pm 1294.61	5423.76 \pm 1370.00	0.124
SC diameter, μm	233.87 \pm 57.17	221.50 \pm 58.66	0.305

* General estimate equations.

between the affected and fellow eyes (710.00 \pm 152.03 μm vs. 683.22 \pm 124.30 μm , $P = 0.158$; Table 2).

Comparisons of TM and SC Parameters Between the Affected and Fellow Eyes by Subgroup

The OHT subgroup showed similar results to those shown in Table 2. TM thickness (113.32 \pm 30.03 μm vs. 89.00 \pm 26.99 μm , $P = 0.046$), SC area (6216.32 \pm 1267.87 μm^2 vs. 5476.40 \pm 1390.15 μm^2 , $P = 0.001$), and SC diameter (246.82 \pm 64.12 μm vs. 212.53 \pm 64.29 μm , $P = 0.001$) were significantly greater in the affected eyes than in the fellow eyes. However, in the ONT subgroup, there were no significant differences in TM thickness (104.48 \pm 27.75 μm vs. 89.63 \pm 25.28 μm , $P = 0.128$), SC area (5859.07 \pm 1294.61 μm^2 vs. 5423.76 \pm 1370.00 μm^2 , $P = 0.124$), and SC diameter (233.87

TABLE 4. Univariate Linear Regression of Associations of TM Thickness, SC area, SC Diameter, and IOP of Affected and Fellow Eyes

	IOP of Affected Eye (mm Hg)	
	β	<i>P</i> value
Affected eye		
TM thickness, μm	0.033	0.466
SC area, μm^2	0.002	0.288
SC diameter, μm	0.028	0.325
Fellow eye		
TM thickness, μm	-0.020	0.288
SC area, μm^2	0.001	0.194
SC diameter, μm	0.001	0.931

β/P values: regression coefficient and P values of the independent variables in general estimate equations. The influence factors as age, sex, and axial length have been adjusted.

\pm 57.17 μm vs. 221.50 \pm 58.66 μm , $P = 0.305$) between the affected and fellow eyes. TM lengths were not significantly different between the affected and fellow eyes in both the OHT and ONT subgroups (both $P > 0.05$; Table 3).

Univariate Linear Regression of Associations of TM Thickness, SC Area, SC Diameter, and IOP of Affected and Fellow Eyes

There were no significant associations among TM thickness, SC area, SC diameter, and IOP in both affected and fellow eyes (all $P > 0.05$; Table 4, Fig. 2).

Univariate Linear Regression of Associations of TM Thickness, SC Area, SC Diameter, and IOP of the Affected Eyes in Each Subgroup

TM thickness of the affected eye was positively associated with IOP ($\beta = 0.066$, $P < 0.001$) in the OHT subgroup, whereas TM thickness of affected eye was negatively associated with IOP ($\beta = -0.011$, $P = 0.005$) in the ONT subgroup. No significant associations among SC area, SC diameter, and IOP of the affected eye were observed in both OHT and ONT subgroups (all $P > 0.05$; Table 5, Fig. 3).

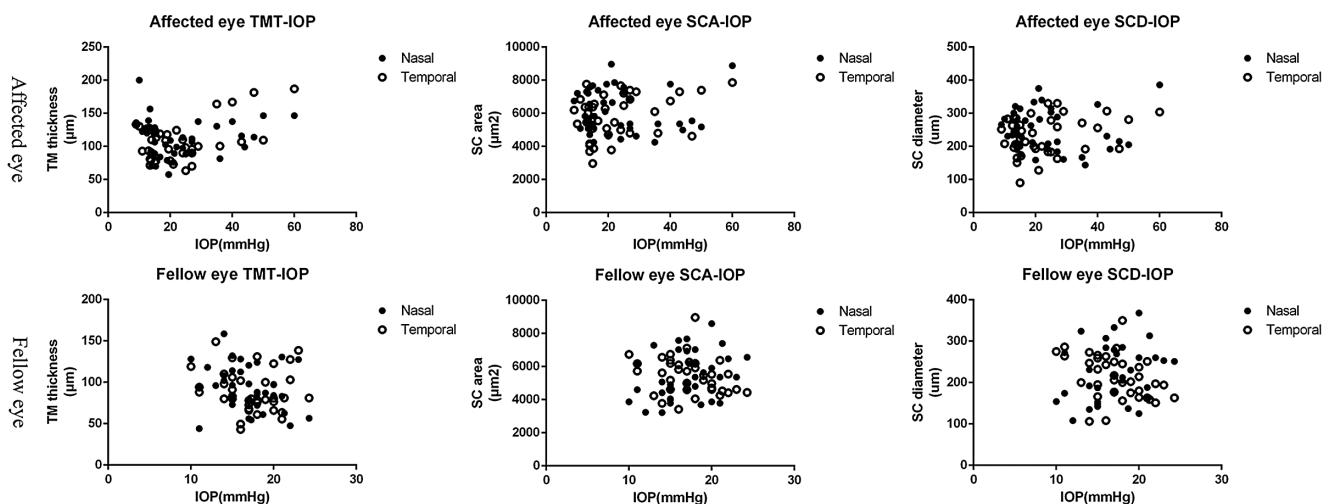
**FIGURE 2.** Associations of TM thickness, SC area, SC diameter, and IOP of affected and fellow eyes. TMT, trabecular meshwork thickness; SCA, Schlemm's canal area; SCD, Schlemm's canal diameter; IOP, intraocular pressure.

TABLE 5. Univariate Linear Regression of Associations of TM Thickness, SC area, SC Diameter, and IOP of Affected Eyes in Each Subgroup

Ocular Hypertension (OHT) Group (Affected Eye With IOP > 21 mm Hg, n = 21)		
IOP of Affected Eye		
Affected eye	β	P value
TM thickness, μm	0.066	<0.001*
SC area, μm^2	0.002	0.311
SC diameter, μm	0.032	0.223
Ocular normal tension (ONT) group (affected eye with IOP \leq 21 mm Hg, n = 24)		
Affected eye	β	P value
TM thickness, μm	-0.011	0.005*
SC area, μm^2	-0.001	0.571
SC diameter, μm	-0.006	0.335

β /P values: regression coefficient and P values of the independent variables in general estimate equations. The influence factors as age, sex, and axial length have been adjusted.

*General estimate equations.

DISCUSSION

Clinical evidence supporting that TM edema leads to the elevation of IOP in patients with PSS is scarce. This study found that TM thickness, SC area, and SC diameter of the affected eyes were significantly greater than those of the fellow eyes in patients with PSS. Further, subgroup analysis showed that TM thickness, SC area, and SC diameter of the affected eyes were significantly greater than those of the fellow eyes in the OHT subgroup. Meanwhile, there were no significant differences in these parameters between the affected eyes and fellow eyes in the ONT subgroup. Moreover, the association between TM thickness and IOP of affected eye in the OHT subgroup was in contrast to that in the ONT subgroup. TM thickness of affected eye was positively associated with IOP in the OHT subgroup, whereas it was negatively associated with IOP in the ONT subgroup.

To our knowledge, this study is the first to report on the morphology of TM and SC in patients with PSS.

Aqueous humor is produced by the ciliary body and mainly flows through the conventional TM-SC pathway.¹¹ The dynamic balance between the production and outflow of aqueous humor maintains the IOP within the normal range. IOP is significantly elevated during a PSS attack.^{1,2} As such, the TM and SC status could also be important factors influencing the changes in IOP in PSS.

PSS is characterized as hypertensive uveitis and can be alleviated by anti-inflammatory and anti-hypertensive medications.^{8,14} Asian PSS has been reported to account for a larger percentage of uveitis than other regions.^{8,20} The clinical manifestations of PSS include anterior chamber inflammation and/or hoar and white suet-shaped KP.^{8,15} The aqueous humor in patients with PSS also contains significantly higher levels of proinflammatory cytokines (e.g. interleukin [IL]-6, IL-8, and tumor necrosis factor- α) than in controls.²¹ Therefore, inflammation may play an important role in PSS.

As a result of anterior inflammation, a thick and edematous TM (trabeculitis) was proposed as a potential reason for the elevated IOP in PSS.¹⁴ An edematous tissue is usually thickened. Our results showed that TM thickness was significantly greater in the affected eyes than in the fellow eyes of patients with PSS, indicating that the affected eyes had TM edema, consistent with the above hypothesis. Moreover, we also found that SC was significantly expanded in the affected eyes as evidenced by the significantly greater SC area and diameter. SC progenitors are first specified in the transcleral veins and then bud off to anastomose.²²⁻²⁴ The SC endothelium originates from vascular cells and retains certain properties of blood vessels.²⁵ In addition, mature SCs are anatomically connected to the intrascleral plexus via collector channels.¹¹ Accordingly, SC is recognized to contain vascular components. Considering that inflammation can induce the expansion of vessels, we hypothesized that the inflammation in PSS can also induce the expansion of SC, leading to a significantly greater SC area and diameter in the affected eyes than in the fellow eyes in patients with PSS.

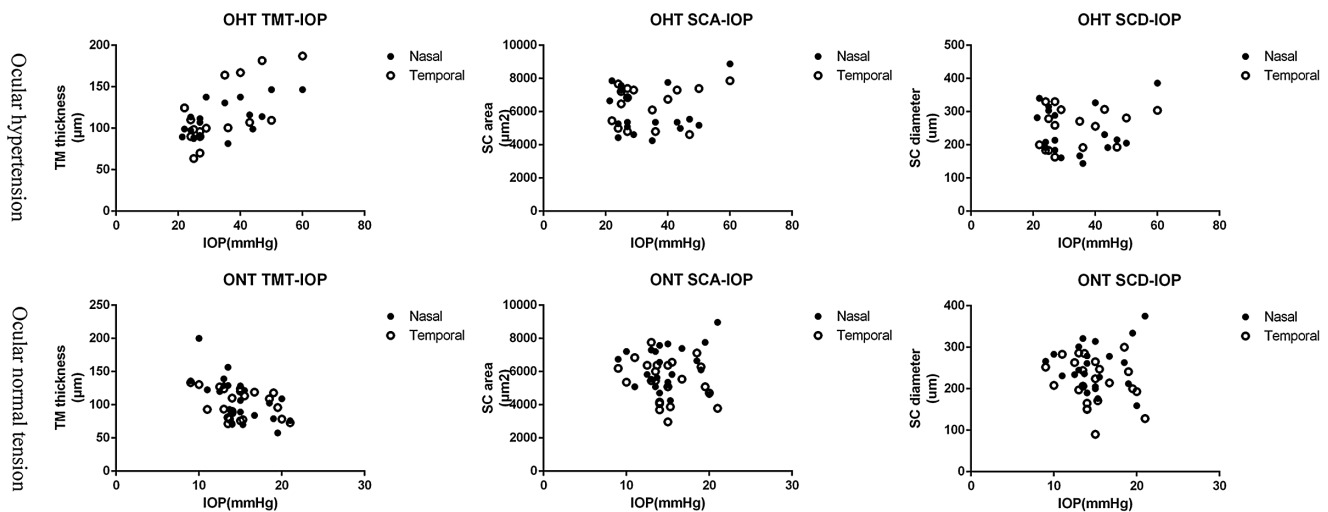


FIGURE 3. Associations of TM thickness, SC area, SC diameter, and IOP of the affected eyes in ocular hypertension and ocular normal tension subgroups. OHT, ocular hypertension; ONT, ocular normal tension; TMT, trabecular meshwork thickness; SCA, Schlemm’s canal area; SCD, Schlemm’s canal diameter; IOP, intraocular pressure.

In the further subgroup analysis, TM thickness, SC area, and SC diameter of the affected eyes were significantly greater than those of the fellow eyes in the OHT subgroup. In contrast, there were no significant differences in these parameters between the affected and fellow eyes in the ONT subgroup. This result indicated that TM and SC were persistently edematous in the OHT subgroup, whereas the edema was relieved in the ONT subgroup. In the OHT subgroup, because persistent TM edema could narrow the trabecular spaces²⁶ and lead to the dysfunction of the TM-SC outflow pathway, IOP could subsequently increase and could be difficult to be controlled within normal range by IOP-lowering medications. In contrast, TM edema was relieved after anti-inflammatory treatment in the ONT subgroup. Thus, IOP of the patients could reduce to normal with or without IOP-lowering medications. These results further indicate that TM edema could be the underlying reason for IOP elevation in patients with PSS.

Correlation analysis in the subgroups revealed that TM thickness of the affected eyes was positively associated with IOP in the OHT subgroup, whereas it was negatively associated with IOP in the ONT subgroup. TM was edematous in the OHT subgroup. A thicker TM indicates more severe TM edema, and TM edema increases aqueous humor outflow resistance and IOP.^{14,26} The more severe the TM edema, the greater the aqueous humor outflow resistance and the higher the IOP. Thus, the positive association between TM thickness and IOP of affected eye in the OHT subgroup could be due to TM edema. In the ONT subgroup, TM edema was relieved, and TM status was approaching to the normal range. Previous studies have indicated that by normal TM, the expansion of TM (increases in TM thickness) could lead to IOP reduction.^{13,17} In addition, normal TM is thicker than glaucomatous TM, which has a much higher IOP.¹⁶ Thus, in the ONT subgroup, TM thickness of affected eye showed negative associations with IOP.

This study has certain limitations. First, this study was a clinical observational study, and only morphological information from SS-OCT images was obtained. TM thickness alone might not be fully representative of the status of TM edema. Thus, further experimental research is needed to gain more information about TM of patients with PSS. Second, most of our study subjects received anti-inflammatory and/or IOP-lowering treatments, and the use of these medications might have a potential influence on the morphology of TM. Thus, a larger study sample size and more detailed stratification analysis are needed in further studies. Third, this was a cross-sectional study, not longitudinal. We did not follow-up with the patients and thus did not observe the dynamic changes in TM morphology throughout the full course of PSS. Fourth, previous studies have indicated that PSS is associated with cytomegalovirus (CMV) infection.^{5,7,27} However, in this study, we did not obtain aqueous humor of patients with PSS to analyze the potential associations between the CMV load of aqueous humor and TM morphology. Fifth, we performed two-dimensional (2D) measurements rather than three-dimensional (3D) measurements of SC in this study. Considering the variability of SC measurements, 2D data could be less accurate and stable than 3D data, leading to the potential measurement variability and error. Thus, in the future studies, 3D data might be more preferable than 2D data for SC dimension measurement. Sixth, in this study, we did not record the presence or absence of trabecular precipitates, which might be a sign of greater inflammation. In the future

studies, we should also take trabecular precipitates into data collection and analysis.

In conclusion, PSS-affected eyes show significantly greater TM thickness, SC area, and SC diameter than does the fellow eyes, indicating an edematous TM in patients with PSS. Persistent TM edema can make medical control of IOP of the affected eye difficult. Thus, TM edema may play a role in IOP elevation in PSS. When TM edema is relieved, IOP of the affected eye could reduce to normal spontaneously or with IOP-lowering medications.

Acknowledgments

Supported by the National Natural Science Foundation of China (Grant Nos. 81800821 and 82000893).

Disclosure: **X. Yan**, None; **M. Li**, None; **J. Wang**, None; **H. Zhang**, None; **X. Zhou**, None; **Z. Chen**, None

References

1. Posner A, Schlossman A. Syndrome of unilateral recurrent attacks of glaucoma with cyclitic symptoms. *Arch Ophthalmol.* 1948;39(4):517–535.
2. Posner A, Schlossman A. Further observations on the syndrome of glaucomatocyclitic crises. *Trans Am Acad Ophthalmol Otolaryngol.* 1953;57(4):531–536.
3. Zhao J, Zhu T, Chen W, et al. Human Leukocyte Antigen-B and -C Loci Associated with Posner-Schlossman Syndrome in a Southern Chinese Population. *PLoS One.* 2015;10(7):e0132179.
4. Shen SC, Ho WJ, Wu SC, et al. Peripheral vascular endothelial dysfunction in glaucomatocyclitic crisis: a preliminary study. *Invest Ophthalmol Vis Sci.* 2010;51(1):272–276.
5. Chee SP, Jap A. Presumed Fuchs heterochromic iridocyclitis and Posner-Schlossman syndrome: comparison of cytomegalovirus-positive and negative eyes. *Am J Ophthalmol.* 2008;146(6):883–889.e1.
6. Li J, Ang M, Cheung CMG, et al. Aqueous cytokine changes associated with Posner-Schlossman syndrome with and without human cytomegalovirus. *PLoS One.* 2012;7(9):e44453.
7. Bloch-Michel E, Dussaix E, Cerqueti P, Patarin D. Possible role of cytomegalovirus infection in the etiology of the Posner-Schlossmann syndrome. *Int Ophthalmol.* 1987;11(2):95–96.
8. Jiang JH, Zhang SD, Dai ML, et al. Posner-Schlossman syndrome in Wenzhou, China: a retrospective review study. *Br J Ophthalmol.* 2017;101(12):1638–1642.
9. Jap A, Sivakumar M, Chee SP. Is Posner Schlossman syndrome benign? *Ophthalmology.* 2001;108(5):913–918.
10. Su CC, Hu FR, Wang TH, et al. Clinical outcomes in cytomegalovirus-positive Posner-Schlossman syndrome patients treated with topical ganciclovir therapy. *Am J Ophthalmol.* 2014;158(5):1024–1031.e2.
11. Grant WM. Clinical measurements of aqueous outflow. *Am J Ophthalmol.* 1951;34(11):1603–1605.
12. Johnstone MA, Grant WG. Pressure-dependent changes in structures of the aqueous outflow system of human and monkey eyes. *Am J Ophthalmol.* 1973;75(3):365–333.
13. Yan X, Li M, Song Y, et al. Influence of Exercise on Intraocular Pressure, Schlemm's Canal, and the Trabecular Meshwork. *Invest Ophthalmol Vis Sci.* 2016;57(11):4733–4739.
14. Megaw R, Agarwal PK. Posner-Schlossman syndrome. *Surv Ophthalmol.* 2017;62(3):277–285.

15. Guo X, Chen D, Luo S, Huang J, Li Y. EDI-OCT choroidal thickness in Posner-Schlossman syndrome. *Int Ophthalmol*. 2020;40(4):877–889.
16. Yan X, Li M, Chen Z, Zhu Y, Song Y, Zhang H. Schlemm's Canal and Trabecular Meshwork in Eyes with Primary Open Angle Glaucoma: A Comparative Study Using High-Frequency Ultrasound Biomicroscopy. *PLoS One*. 2016;11(1):e0145824.
17. Yan X, Li M, Zhang H. Relationship Between Post-Exercise Changes in the Lens and Schlemm's Canal: A Swept-Source Optical Coherence Tomography Study. *Curr Eye Res*. 2018;43(11):1351–1356.
18. Zhao Z, Zhu X, He W, Jiang C, Lu Y. Schlemm's Canal Expansion After Uncomplicated Phacoemulsification Surgery: An Optical Coherence Tomography Study. *Invest Ophthalmol Vis Sci*. 2016;57(15):6507–6512.
19. Fernandez-Vigo JI, De-Pablo-Gómez-de-Liaño L, Fernández-Vigo C, et al. Anterior Chamber Angle and Trabecular Meshwork Measurements Made by Fourier-domain Optical Coherence Tomography in Healthy White Children. *J Glaucoma*. 2017;26(9):810–815.
20. Nakahara H, Kaburake T, Takamoto M, et al. Statistical analyses of Endogenous Uveitis Patients (2007-2009) in central Tokyo area and Comparison with Previous Studies (1963-2006). *Ocul Immunol Inflamm*. 2015;23(4):291–296.
21. Ohira S, Inoue T, Iwao K, Takahashi E, Tanihara H. Factors Influencing Aqueous Proinflammatory Cytokines and Growth Factors in Uveitic Glaucoma. *PLoS One*. 2016;11(1):e0147080.
22. Park DY, Lee J, Park I, et al. Lymphatic regulator PROX1 determines Schlemm's canal integrity and identity. *J Clin Invest*. 2014;124(9):3960–3974.
23. Yang Y, Oliver G. Development of the mammalian lymphatic vasculature. *J Clin Invest*. 2014;124(3):888–897.
24. Dautriche CN, Tian Y, Xie Y, Sharfstein S. A Closer Look at Schlemm's Canal Cell Physiology: Implications for Biomimetics. *J Funct Biomater*. 2015;6(3):963–985.
25. Hamanaka T, Bill A, Ichinohasama R, Ishida T. Aspects of the development of Schlemm's canal. *Exp Eye Res*. 1992;55(3):479–488.
26. Kersey JP, Broadway DC. Corticosteroid-induced glaucoma: a review of the literature. *Eye (Lond)*. 2006;20(4):407–416.
27. Chee SP, Bacsal K, Jap A, Se-Thoe S, Cheng CL, Tan BH. Clinical features of cytomegalovirus anterior uveitis in immunocompetent patients. *Am J Ophthalmol*. 2008;145(5):834–840.