

Detection of Unilateral Axillary Nodal Uptake Both at ^{68}Ga -DOTATOC and ^{18}F -FDG PET/CT After 1 Week From COVID-19 Vaccine

Priscilla Guglielmo, MD, Simona Muccioli, MD, Sara Berti, MD, Alida Sartorello, MD, Fiammetta Pesella, MD, and Michele Gregianin, MD

Abstract: Recently, vaccination against COVID-19 has gained wide diffusion, especially among vulnerable individuals, such as cancer patients. At the same time, patients have been undergoing PET/CT examinations after vaccination in an increasing number, and cases of false-positive axillary nodal uptake have been described, mostly at ^{18}F -FDG PET. Here, we describe the case of both ^{68}Ga -DOTATOC and ^{18}F -FDG axillary nodal uptake in a young woman affected by a metastatic retroperitoneal paraganglioma.

Key Words: nodal uptake, vaccine, DOTA PET/CT, FDG PET/CT

(*Clin Nucl Med* 2022;47: e123–e124)

Received for publication April 18, 2021; revision accepted March 8, 2021.
From the Nuclear Medicine Unit, Veneto Institute of Oncology IOV–IRCCS, Padua, Italy.

Conflicts of interest and sources of funding: none declared.

Authors contribution: P.G., S.M., and S.B. contributed to the data analysis, manuscript writing, and manuscript reviewing. A.S., F.P., and M.G. contributed to the manuscript reviewing.

Correspondence to: Priscilla Guglielmo, MD, Nuclear Medicine Unit, Veneto Institute of Oncology IOV–IRCCS, Padua, Italy. E-mail: priscilla.guglielmo@yahoo.it

Copyright © 2021 Wolters Kluwer Health, Inc. All rights reserved.

ISSN: 0363-9762/22/4702–e123

DOI: 10.1097/RLU.00000000000003918

ACKNOWLEDGMENTS

The authors would like to thank the technicians, the nurses, and all the members of the nuclear medicine unit.

REFERENCES

1. Nawwar AA, Searle J, Hagan I, et al. COVID-19 vaccination induced axillary nodal uptake on ^{18}F -FDG PET/CT. *Eur J Nucl Med Mol Imaging*. 2021;48:2655–2656.
2. Avner M, Orevi M, Caplan N, et al. COVID-19 vaccine as a cause for unilateral lymphadenopathy detected by ^{18}F -FDG PET/CT in a patient affected by melanoma. *Eur J Nucl Med Mol Imaging*. 2021;48:2659–2660.
3. Doss M, Nakhoda SK, Li Y, et al. COVID-19 vaccine-related local FDG uptake. *Clin Nucl Med*. 2021;46:439–441.
4. Ahmed N, Muzaffar S, Binns C, et al. COVID-19 vaccination manifesting as incidental lymph nodal uptake on ^{18}F -FDG PET/CT. *Clin Nucl Med*. 2021;46:435–436.
5. McIntosh LJ, Bankier AA, Vijayaraghavan GR, et al. COVID-19 vaccination-related uptake on FDG PET/CT: an emerging dilemma and suggestions for management. *AJR Am J Roentgenol*. 2021;1–9.
6. Eifer M, Eshet Y. Imaging of COVID-19 vaccination at FDG PET/CT. *Radiology*. 2021;299:E248.
7. Hanneman K, Iwanochko RM, Thavendiranathan P. Evolution of lymphadenopathy at PET/MRI after COVID-19 vaccination [published correction appears in *Radiology*. 2021 Aug;300(2):E338]. *Radiology*. 2021;299:E282.
8. Nawwar AA, Searle J, Singh R, et al. Oxford-AstraZeneca COVID-19 vaccination induced lymphadenopathy on [^{18}F]choline PET/CT—not only an FDG finding. *Eur J Nucl Med Mol Imaging*. 2021;48:2657–2658.
9. Lu Y. DOTATATE-avid bilateral axilla and subpectoral lymphadenopathy induced from COVID-19 mRNA vaccination visualized on PET/CT. *Clin Nucl Med*. 2021. [Online ahead of print]. doi: 10.1097/RLU.00000000000003697.

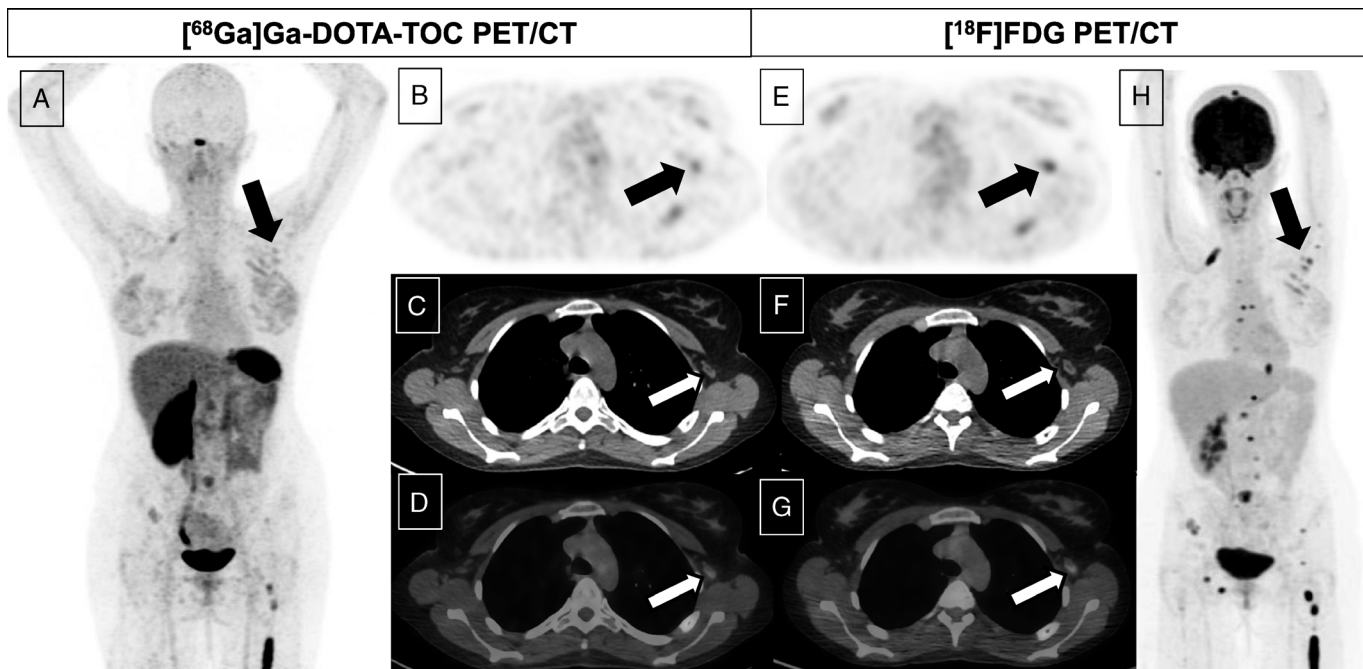


FIGURE 1. We describe the case of a 29-year-old woman with stage IV retroperitoneal paraganglioma and disseminated bone metastases, who underwent both ⁶⁸Ga-DOTATOC and ¹⁸F-FDG PET/CT during her follow-up. After the injection of 101 MBq of ⁶⁸Ga-DOTATOC, the PET/CT examination revealed a stable disease in the already known numerous bone and pulmonary metastases; furthermore, a mild uptake was demonstrated in some small left axillary nodes (white and black arrows; **A**, MIP; **B**, axial PET image; **C**, CT image; **D**, fused PET/CT image). The day after, she underwent ¹⁸F-FDG PET/CT confirming bone and lung lesions and a mild uptake (SUV_{max} 3.80) in the left axillary region, corresponding to the small nodes with fatty hilus previously observed (white and black arrows; **E**, axial PET image; **F**, CT image; **G**, fused PET/CT image; **H**, MIP). A fade uptake was also detected within the subcutaneous soft tissues superficial to the left deltoid muscle. The patient presented a history of receiving the Pfizer-BioNTech COVID-19 vaccine in the left deltoid muscle 6 and 7 days before the ⁶⁸Ga-DOTATOC and the ¹⁸F-FDG PET/CT, respectively. Tracer injection was via the right (contralateral) antecubital fossa in both examinations, hence not a potential cause. Clinical correlation and its morphological aspect supported the nodal uptake to be reactive, ascribed to the recent vaccination. Similar findings were described after COVID-19 vaccinations (both Pfizer-BioNTech and AZ) on ¹⁸F-FDG PET/CT¹⁻⁷ and, recently, also on ¹⁸F-choline PET/CT examination.⁸ To the best of our knowledge, this is the first case of a COVID-19 vaccine-related nodal uptake on ⁶⁸Ga-DOTATOC PET/CT, as very recently another case involving ⁶⁸Ga-DOTATATE PET/CT had been reported.⁹ This case highlights another potential pitfall associated with the current COVID-19 pandemic vaccination program, which may result in incorrect image interpretation and inadvertent disease upstaging.