




Since January 2020 Elsevier has created a COVID-19 resource centre with free information in English and Mandarin on the novel coronavirus COVID-19. The COVID-19 resource centre is hosted on Elsevier Connect, the company's public news and information website.

Elsevier hereby grants permission to make all its COVID-19-related research that is available on the COVID-19 resource centre - including this research content - immediately available in PubMed Central and other publicly funded repositories, such as the WHO COVID database with rights for unrestricted research re-use and analyses in any form or by any means with acknowledgement of the original source. These permissions are granted for free by Elsevier for as long as the COVID-19 resource centre remains active.



Revista Española de Anestesiología y Reanimación

www.elsevier.es/redar



ORIGINAL ARTICLE

SARS-CoV-2 infection. Descriptive analysis of a selected case series[☆]

C.L. Errando^{*}, C.S. Romero-García, M.J. Hernández-Cádiz, M.Á. Pallardó-López, J. Puig

Consorcio Hospital General Universitario de Valencia, Valencia, Spain

Received 7 January 2021; accepted 12 March 2021

Available online 11 January 2022

KEYWORDS

Coronavirus;
COVID-19;
Outbreak;
Complications;
ICU

Abstract

Objectives: COVID-19 was declared pandemic by March 2020. Clinical, analytical, and radiological findings have been reported. Detailed different evolution of patients of the same local outbreak has been scarcely reported. We report 6 selected cases of such an evolution.

Clinical cases: The clinical, radiological, analytical evolution of 6 patients is reported. Patients were selected as it were epidemiological close contacts, and showed particular different clinical evolution.

Results: The clinical course at the start of infection (first week) was similar among patients. In relationship with clinical evolution, middle to severe course were related with inflammation markers levels evolution (D-dimer, IL-6, ferritin, lymphocytes count, etc.). Specially lung alterations were observed, but neurological/neuropsychiatric findings are still common. In evolution, 2 patients showed middle symptoms, but the 2 most severely affected died.

Conclusions: It remains to be elucidated the different evolutive pathways and outcomes of COVID-19. In our 6 patients of the same local outbreak, clinical, laboratory and radiological features were different. We discuss some aspects of the pathophysiology of the disease, other than the widely described of the respiratory system.

© 2021 Sociedad Española de Anestesiología, Reanimación y Terapéutica del Dolor. Published by Elsevier España, S.L.U. All rights reserved.

PALABRAS CLAVE

Coronavirus;
COVID-19;
Brote epidémico;
Complicaciones;
UCI

Infección por SARS-CoV-2. Análisis descriptivo de una serie de casos seleccionada

Resumen

Objetivos: La COVID-19 fue declarada pandemia en marzo del 2020. Han sido comunicados los hallazgos clínicos, analíticos y radiológicos. Sin embargo, la diversa evolución de pacientes del mismo brote local lo ha sido escasamente. Comunicamos en este trabajo 6 casos seleccionados de tal evolución.

[☆] Please cite this article as: Errando CL, Romero-García CS, Hernández-Cádiz MJ, Pallardó-López MÁ, Puig J. Infección por SARS-CoV-2. Análisis descriptivo de una serie de casos seleccionada. Rev Esp Anestesiología y Reanimación. 2022;69:34–42.

^{*} Corresponding author.

E-mail address: errando013@gmail.com (C.L. Errando).

Casos clínicos: Se expone la evolución clínica, radiológica y analítica de 6 pacientes. Estos fueron seleccionados ya que fueron epidemiológicamente contactos estrechos y mostraron una evolución clínica particularmente diferente.

Resultados: El curso clínico al inicio de la infección (primera semana) fue similar entre los pacientes. En relación con la evolución clínica, un curso moderado a severo se relacionó evolutivamente con marcadores elevados de inflamación (dímero D, IL-6, ferritina, linfopenia, etc.). Fueron observadas alteraciones pulmonares típicas, pero fueron comunes también hallazgos neurológicos y neuropsiquiátricos. En la evolución 2 pacientes mostraron síntomas moderados, pero los 2 más gravemente afectados murieron.

Conclusiones: Está por elucidar las diferentes vías evolutivas y resultados finales de los pacientes con COVID-19. En nuestros 6 pacientes del mismo brote local, las características clínicas, de laboratorio y radiológicas fueron diferentes. Discutimos aspectos de la fisiopatología de la enfermedad distintos de los ampliamente descritos del sistema respiratorio.

© 2021 Sociedad Española de Anestesiología, Reanimación y Terapéutica del Dolor. Publicado por Elsevier España, S.L.U. Todos los derechos reservados.

Introduction

The World Health Organization declared COVID-19 to be a pandemic on March 11, 2020. Spain continues to be one of the most highly affected countries in the world in terms of total cases, total cases per million inhabitants, deaths and excess deaths. March was the month with the greatest increase in COVID-19 cases, with Intensive Care Units (ICU) and hospital beds at the limit of their capacity. In Spain, as in other countries, patients presented a wide range of clinical symptoms, 14%–30% patients required ICU, and the mortality rate was around 3%–10%¹.

In this series of selected cases, we have attempted to highlight the different aspects of the disease in close contact cases, and emphasize the different evolution of these patients and the widely described respiratory deterioration.

Methods

We present a case series of COVID-19 patients selected from the same local outbreak. The local Ethics Committee waived the need for informed consent.

In all patients, symptoms onset around the third week of March 2020. COVID-19 was clinically suspected and diagnosed by reverse transcriptase-polymerase chain reaction (RT-PCR) for SARS-CoV-2. The demographic and clinical characteristics of the patients, the chronology of the diagnostic process, and the outcomes obtained are shown in [Table 1](#).

Patients 1 and 3, and 2 and 4, respectively, were couples. Patient 6 was a close friend of patient 1, with whom he was in contact in the days prior to the onset of symptoms. The clinical course and the findings of patient 5 are included due to their particular severity and the fact that he attended a party with several other people, some of whom had mild or moderate forms of COVID-19.

Results

[Table 2](#) shows the evolutionary characteristics of the 4 patients admitted to the ICU. [Table 3](#) shows some of the procedures performed and the clinical course in the ICU, and [Table 4](#) shows a short description of the diagnostic imaging procedures performed (which are detailed in [Figs. 1–7](#)).

Patient 1

A 64-year-old man with moderate fever for 7 days before admission, followed by the symptoms summarized in [Table 1](#). He was admitted to the ICU after a diagnosis of COVID-19 with pneumonia and clinical worsening. Intubation and mechanical ventilation began on the second day of admission to the ICU. The specific COVID-19 treatments and local protocols in place at that time are summarized in [Table 5](#) (Appendix, additional material online). The patient was extubated 10 days later following clinical and analytical improvement. He presented episodes of agitation, drowsiness, disorientation to time, place and person, and incoherent speech in the ICU after extubation and in the Pulmonology ward (where he remained in contact and respiratory isolation, accompanied by his wife, who had also been previously diagnosed with SARS-CoV-2, patient 3). A late computed tomography scan showed pulmonary thromboembolism ([Table 4](#)). He was discharged with enoxaparin. The RT-PCR for SARS-CoV-2 was positive before hospital admission and became negative 21 days later.

Patient 2

A 63-year-old man who reported a 5-day history of fever and productive cough. His clinical course is shown in [Table 4](#). After 7 days in the Pulmonology Unit, he required intubation and mechanical ventilation in the ICU. He was extubated 8 days later.

Table 1 Demographic characteristics, symptoms, results of RT-PCR for SARS-CoV-2, and outcome.

	Demographics, history, prior treatment	Symptoms at onset	First symptom until RT-PCR + ^a	First symptom until RT-PCR - ^a	Time from first symptom to hospital/ICU admission ^a	ICU stay ^a	Hospital stay ^a	Final physical/psychological outcome
Patient 1	64 years old, male, 82 kg, 176 cm, high blood pressure, dyslipidaemia, amlodipine, telmisartan, omeprazole	Fever, malaise, muscle aches, headache, diarrhoea, dyspnoea, vomiting, asthenia, dizziness, vertigo	9	30	10/10	11	44	Microthrombi in pulmonary arteries requiring therapeutic doses of LMWH, weight loss, fatigue/severe malaise, PTSD ^b
Patient 2	63 years old, male, 65 kg, 172 cm, high blood pressure, dyslipidaemia, asthma, amlodipine, atorvastatin, prednisone, budesonide, formoterol	Fever, dry cough, asthenia, fatigue, dyspnoea, palpitations, dizziness, vertigo	7	23	9/11	17	30	Weight loss, palpitations, fatigue, insomnia/severe malaise, PTSD ^b
Patient 3	61 years old, female, 65 kg, 158 cm, osteoporosis, vitamin D	Fever, malaise, headache, diarrhoea, nausea, mild dizziness (all of short duration), anosmia, ageusia	5	20	NA	23	NA	Quetiapine No sequelae
Patient 4	57 years old, female, 70 kg, 160 cm, occasional smoker, hypothyroidism, levothyroxine	Fever, anosmia, ageusia	NA	NA	NA	36	NA	No sequelae
Patient 5	63 years old, male, 90 kg, 160 cm, high blood pressure, losartan, atorvastatin	Cough, fever, malaise	10	23	10/10	61	NA	Tracheostomy, bilateral pneumothorax, thoracotomy, death
Patient 6	74 years old, male, high blood pressure., pulmonary embolism, dyslipidaemia, candesartan, hydrochlorothiazide, allopurinol	Cough, fever, dizziness, myalgia	7	NA ^c	7/10	60	NA	Tracheostomy, death

Patients 1 and 3 and patients 2 and 4 were couples, patients 5 and 6 died in the ICU.

LMWH: low molecular weight heparin; NA: not applicable; PTSD: post-traumatic distress syndrome; RT-PCR: reverse transcriptase-polymerase chain reaction.

^a In days.

^b See text for additional explanation.

^c Remained positive until death.

Table 2 Laboratory data from the 4 patients admitted to the ICU. Patients 1 and 2 survived, patients 5 and 6 died in the ICU.

	Patient 1			Patient 2			Patient 5			Patient 6		
Haemoglobin (g/dl)	12.9	9.7	< ^a	15	12.2	=	14.3	6.5	<	12.6	7.6	<
Leukocytes ($\times 10^9/l$)	2.3	20.4	>	6.6	10.2	>	6.2	23.5	>	9.8	14.1	=
Neutrophils ($\times 10^9/l$)	1.9	18	>	4.8	1.8	>	4.3	10.5	>	9.2	13	=
Lymphocytes ($\times 10^9/l$)	0.29	0.52	<	1.3	0.2	<	1.4	0.2	<	1.4	0.1	<
Platelets ($\times 10^9/l$)	128	84	=	129	147	=	212	67	=	209	77	< ^a
Quick Index (%)	–	81	=	93	65	=	73	69	=	90	55	=
INR	–	1.15	=	1.06	–	=	1.22	1.23	=	1	1.46	=
Fibrinogen (mg/dl)	–	354	=	700	147	=	568	734	>	400	93	<
D-dimer (ng/ml)	643	15,331	>	284	912	>	200	8548	>	258	6100	>
Glucose (mg/dl)	117	117	=	117	140	=	186	325	>	148	270	>
NA (mEq/l)	136	145	=	130	140	=	136	149	=	140	162	>
K (mEq/l)	3.7	4	=	4.1	3.8	=	3.3	3.1	<	3.9	5.1	=
Bilirubin (mg/dl)	–	0.67	=	0.49	1	=	0.63	1.11	=	0.59	0.98	=
AST (I/U)	32	28	=	22	150	=	41	2587	> ^b	82	111	> ^a
ALT (I/U)	99	160	> ^a	–	81	=	39	2679	> ^b	100	100	>
GGT (I/U)	–	–	–	–	–	–	231	438	>	67	300	>
Urea (mg/dl)	46	66	=	29	86	=	16	58	> ^a	119	164	=
Creatinine (mg/dl)	1.22	0.86	=	0.94	0.7	=	0.71	1.67	> ^a	1.3	1.37	=
Ferritin ($\mu g/l$)	675	207	–	721	683	>	200	16,775	>	394	2000	>
LDH (I/U)	584	505	>	532	618	> ^a	488	1135	>	737	208	>
Albumin (g/dl)	3.6	3	< ^a	–	3	< ^a	4.2	2	<	2.8	2	<
Lactate (mEq/l)	1	1.1	=	0.8	0.7	=	0.8	2	=	2	2.8	=
Procalcitonin (ng/ml)	0.16	0.11	=	0.54	0.51	=	0	>	> ^b	0.33	1.77	> ^b
HS troponin I (mg/dl)	6.6	9.78	>	7	60	> ^a	20	1251	=	12	121	>
C-reactive protein (mg/l)	2.1	5.1	=	7.4	1.7	> ^a	9	45.2	=	28.3	38	>
Interleukin 6 (ng/ml)	9.8	20.8	>	–	–	–	–	9 ^c	–	–	7 ^c	–

Patients 3 and 4 were not admitted to the hospital and no blood tests or radiology were performed.

The data shown are at admission to the hospital, worst result (nadir) and general trend (if the result was maintained for more than 5 consecutive days). INR: international normalized ratio; Na: sodium; K: potassium; AST: aspartate aminotransferase; ALT: alanine aminotransferase; GGT: gamma-glutamyltranspeptidase; LDH: lactate dehydrogenase; HS troponin I: high sensitivity troponin I.

=: In normal range; >: predominantly higher than the normal range; <: predominantly below the normal range.

^a Means ‘‘moderate’’.

^b Means increase delayed over time (concurrent sepsis usually due to a bacterial coinfection).

^c Isolated determination.

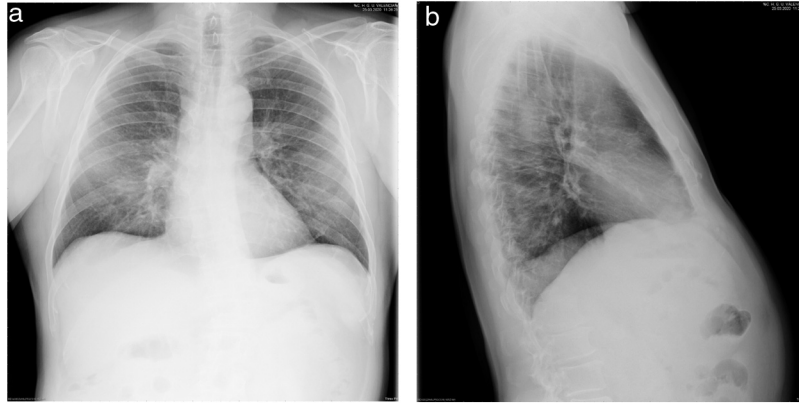


Figure 1 Plain chest X-ray (patient 5). Bilateral interstitial infiltrates (posteroanterior and lateral views).

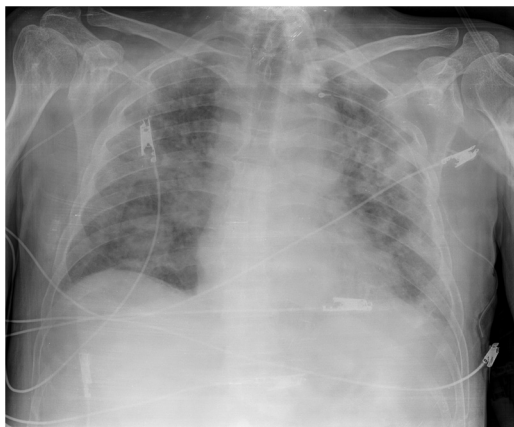


Figure 2 Plain chest X-ray (patient 5). Bilateral pulmonary opacities. Tracheostomy tube. Peripherally inserted central venous catheter.

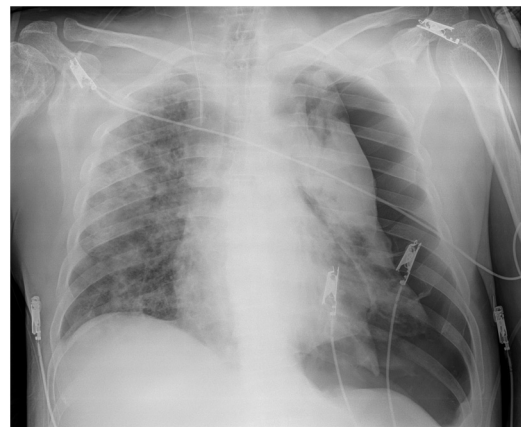

Figure 3 Chest X-ray (patient 5). Opacities in the right lung, massive left pneumothorax (prior to insertion of the drain), catheter in the right internal jugular vein.

He developed agitation, disorientation requiring low-dose propofol infusion, dexmedetomidine and lorazepam infusion, followed by risperidone. In the Pulmonology ward, where he remained in isolation, he presented delirium, confusion, moderate agitation and euphoria, which progressively improved. He was discharged home (where he lived with his wife, patient 4) with quetiapine and ordered to self-isolate for a further 14 days. The RT-PCR for SARS-CoV-2 was positive before hospital admission and became negative 21 days later.

Patients 3 and 4

Before hospitalization, these patients had been living with their respective partners (patients 1 and 2) for at least 7 days while they both had symptoms of COVID-19. Their symptoms were anosmia and dysgeusia/ageusia, lasting more than 10 days. Patient 3 also reported mild fever for 3 days. They quarantined at home for 2 weeks after diagnosis.

Patient 5

Male patient with fever (37.9°C), tachypnoea (40 rpm), cyanosis and SaO₂ 77% breathing room air, blood pressure

140/70 mmHg and heart rate 110 beats per minute. He was diagnosed with bilateral interstitial pneumonia (Fig. 1). After presenting neurological deterioration, he was admitted to the ICU where he was intubated and started on mechanical ventilation.

The treatment was administered according to protocol (Appendix, Table 5, additional material online). An early tracheostomy was performed. His labs showed elevated D-dimer, ferritin, and LDH, which remained elevated (Table 2). Chest radiology showed deterioration (Fig. 2).

Inhaled nitric oxide was started for refractory hypoxaemia. Due to persistence of the inflammatory process, anakinra (IL-1 receptor antagonist) was introduced, but oxygenation did not improve despite this measure, and was followed by *Pseudomonas aeruginosa*, streptococci and fungal coinfections, treated according to antibiogram and local protocol. He eventually developed haemodynamic instability, which was treated with low doses of norepinephrine and dobutamine. Full-dose low-molecular-weight heparin (LMWH) anticoagulation was added, followed by fondaparinux.

He presented the following complications after the fourth week in the ICU: left pneumothorax (Fig. 3), kidney failure, increased markers of myocardial injury (with normal

Table 3 Details of ICU stay.

	Date of admission	PaFi 1	Date intubated	PaFi 2	Prone positioning	PaFi 3	Date extubated	PaFi 4	Date discharge from ICU (discharge from hospital)/death ^a
Patient 1	14/04/20	60	28/03/20	169	0	274	07/04/20	459	22/04/20 (29/04/20)
Patient 2	23/03/20	86	23/03/20	97	4	368	01/04/20	442	08/04/20 (20/04/20)
Patient 5	23/03/20	132	23/03/20	328	9	NA	NA	66 ^b	14/05/20 ^a
Patient 6	14/03/20	79	15/03/20	260	1	NA	NA	56 ^b	18/05/20 ^a

NA: not applicable; PaFi: PaO₂/FiO₂ (1: pre-tracheal intubation; 2: immediate post-tracheal intubation; 3: pre-tracheal extubation; 4: immediate post-tracheal extubation or pre-death); prone positioning: number of times the patient was pronated for ventilation (pronation usually lasted 12–16 h and was indicated when oxygenation did not improve with the usual ventilation manoeuvres, e.g., PaO₂/FiO₂ < 150–200).

^b In case of death, worse PaFi.

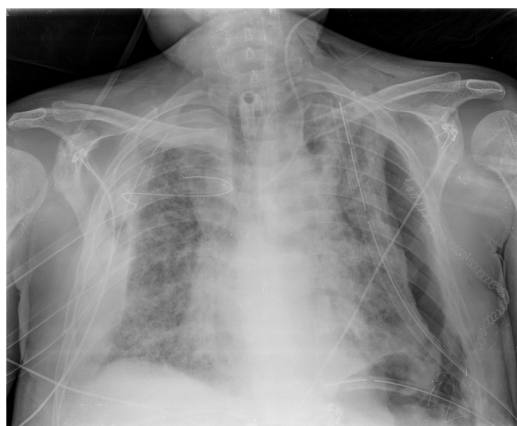


Figure 4 Plain chest X-ray (patient 5). Severe bilateral consolidation, bilateral pneumothorax, mediastinal widening, left jugular vein catheter, thoracic drains (both sides), subcutaneous emphysema, left hemithorax staples (due to thoracotomy, see text for further explanation).

echocardiogram), right pneumothorax (which required thoracotomy for haemothorax, Fig. 4), blood culture positive for *Candida auris*, and liver failure.

In the days before death, ruxolitinib (JAK1 and JAK2 kinase inhibitor) was introduced through a compassionate use programme.

The RT-PCR for SARS-CoV-2 was positive before hospital admission and became negative 25 days later.

Patient 6

A 74-year-old man who was admitted to the emergency room for fever of 39 °C, cough and dizziness. He had attended a meeting with friends who had been diagnosed with SARS-CoV-2 by RT-PCR several days later (including his wife).

SaO₂ was 84% breathing room air, improving to 99% with a mask, but he presented high blood pressure (80/50 mmHg, 65 beats per minute), tachypnoea, and cyanosis. Admission to the ICU and tracheal intubation 6 days later was indicated, and low-dose norepinephrine infusion was started. He was diagnosed with bilateral atypical pneumonia (Fig. 5),

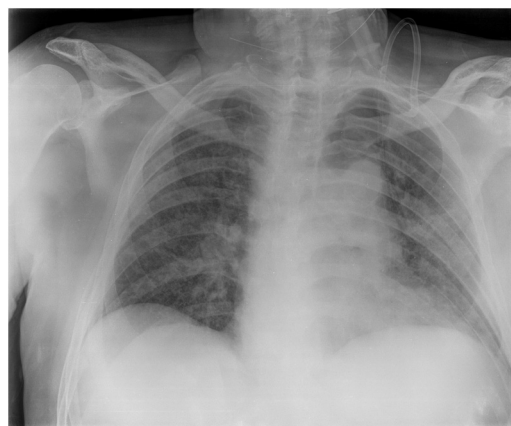


Figure 5 Plain chest X-ray (patient 6). Bilateral reticular pulmonary opacities.

and was treated according to protocol (Appendix, Table 5, additional material online). Prophylactic administration of enoxaparin was followed by therapeutic doses (then switched to fondaparinux) due to abnormal coagulation parameters. A tracheostomy was performed on the 17th day of his stay in the ICU. A computed tomography scan showed bilateral consolidations and pleural effusion (Fig. 6a and b).

In the final days, he presented polyneuropathy, myopathy and kidney failure. Several transthoracic and transoesophageal echocardiograms were performed, but showed no abnormalities. Chest radiology showed deterioration (Fig. 7).

A series of coinfections and colonizations appeared (*Staphylococcus aureus* sensitive to methicillin, *Acinetobacter baumannii*, *Enterobacter cloacae*, *Enterococcus faecium* and *C. auris*) that were treated according to antibiogram.

An attempt at weaning from mechanical ventilation was unsuccessful. Following multiple organ failure, the patient died 44 days after admission to the ICU.

Discussion

In our hospital (Appendix Banex, Tables 6 and 7 additional online material), 1226 patients were diagnosed with SARS-

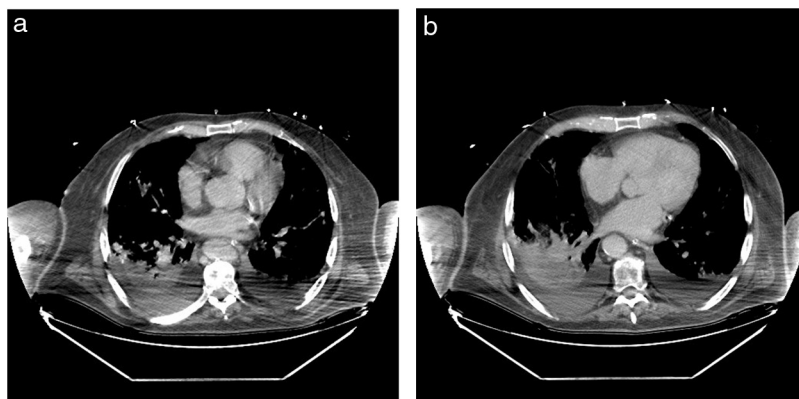


Figure 6 Computed tomography (patient 6). (a) Bilateral pulmonary condensations and some interstitial infiltration. (b) Bilateral pulmonary condensation and pleural effusion, especially in the left hemithorax.

Table 4 Description of ECG and radiological findings in patients admitted to the ICU.

	ECG	Rx 1 (date)	Rx 2 (date)	Other imaging studies
Patient 1	Sinus rhythm, 82 bpm, narrow QRS, QTc 491 ms. No change during ICU stay	Bilateral parenchymal opacities (25/03/20)	Parenchymal opacities in both lungs, bilateral pleural effusion (30/03/20)	CT: pulmonary thromboembolism in the right upper lobe and several segmental arteries, as well as segmental arteries of the left upper lobe; diffuse bilateral ground glass opacifications (16/04/20)
Patient 2	Sinus rhythm, 85 bpm, narrow QRS QT 393 ms. No change during ICU stay	Bilateral opacities (23/03/20)	No opacities (03/04/20)	NA
Patient 5	Sinus rhythm, 90 bpm, narrow QRS QT 500 ms	Interstitial reticular opacifications in the middle lobe (25/03/20)	Laminar atelectasis (17/04/20) Interstitial reticular pattern, bilateral subpleural opacities, discrete interstitial alveolar pattern (10/04/20) Bilateral pneumothorax (not simultaneous) and subcutaneous emphysema (22/04/20)	US: no findings of pulmonary thromboembolism (10/04/20)
Patient 6	Sinus rhythm, 40 bpm, narrow QRS, QTc 357 ms. Developed atrial fibrillation during ICU stay ^a	Interstitial reticular opacification, condensation of the upper lobe of the left lung (14/03/20)	Progressive alveolar condensations, pleural collection in the right hemithorax (haemothorax) (16/05/20) Insertion of chest drains and left thoracotomy	CT: bilateral ground glass opacifications, peripheral opacities in both upper lobes, middle lobe, and lingula. Consolidations in the right lower lobe. Bilateral pleural effusion. No findings of pulmonary thromboembolism (19/04/20)

CT: computed tomography; ECG: electrocardiographic findings; NA: not available; QRS: type of QRS complex; QT and QTc: QT interval duration (normal range 400–440 ms); US: lung examination with ultrasound; X-ray 1: chest X-ray on admission to the ICU; X-ray 2: worse chest X-ray findings (both with date of study).

^a This patient had been previously diagnosed with atrial fibrillation and was being treated with acenocoumarol at admission.

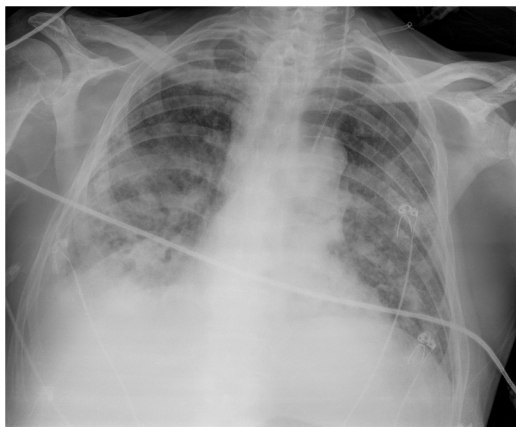


Figure 7 Plain chest X-ray (patient 6). Bilateral pulmonary opacities and consolidations. Right pleural effusion. Catheter in left internal jugular vein.

CoV-2 infection, 371 (30.26%) were hospitalized, and 66 (5.38%, 43 men) were admitted to the ICU. The ICU mortality rate was 44% (29 patients) in this first wave of the pandemic.

In this article, we describe the clinical, laboratory and radiological findings in 6 selected patients diagnosed with COVID-19 in a tertiary public hospital in Valencia, Spain. The patients were admitted during the 2nd and 3rd weeks of the pandemic in Spain.

The reasons for the different clinical course presented by patients infected at the same time or after the index cases are unknown. The mean incubation period before the onset of symptoms is approximately 4–5 days, and almost all symptomatic patients develop symptoms within 11.5 days². Important factors are the viral load, the patient's own characteristics (advanced age, men, genetic factors) and comorbidities (arterial hypertension, diabetes, etc.)³.

In our cases, symptoms were similar in both mild and severe patients, but the latter worsened over the following 5 days. This finding is consistent with other studies⁴.

Reports based on close contacts between confirmed COVID-19 patients in Wuhan⁵ have shown that asymptomatic patients were younger, usually women, with a higher CD4 + T lymphocyte count during recovery, more rapid radiological improvement, and a shorter duration of viral shedding (samples from nasopharyngeal swabs; mean duration [interquartile range], 8 [3–12] days versus 19 [16–24] days; $p = 0.001$) compared to symptomatic cases. These findings suggest that patients with milder infections might have fewer immune system alterations.

It should be noted that the 4 severely affected patients had been treated with antihypertensives, and 3 of them with angiotensin II receptor antagonists or angiotensin converting enzyme inhibitors. Opinions vary on the clinical course of the disease in patients treated with both drugs, and several laboratory parameters have been associated with poorer outcomes, including higher mortality^{4,6}. Interestingly, the patients who developed severe clotting disorders, mainly in the pulmonary circulation (patients 1 and 5), had higher concentrations of D-dimer (Table 2), a finding previously reported elsewhere⁴. Recent evidence has shown that this involved a hypercoagulable state in most patients, and

more than 60% presented clinical evidence of thrombotic events, particularly critically ill patients. This may explain the finding of pulmonary embolism in addition to pulmonary vasculitis and endothelialitis. The pulmonary artery thrombi in patient 1 were diagnosed relatively late (close to hospital discharge) due to persistent hypoxaemia.

We obtained few laboratory determinations of IL-6, but this inflammatory marker also appeared to be increased, and has also been described as an independent marker of in-hospital mortality⁴.

Therefore, D-dimer and IL-6 concentrations at admission appeared to be predictors of mortality. In our patients, both D-dimer and IL-6, in addition to ferritin, increased from the early stages of the disease, and were an expression of the hyperinflammatory syndrome that has been suggested to cause multiorgan involvement in COVID-19.

Lymphopenia is another common finding in COVID-19 patients², and can also be of prognostic value. A recent study reviewed the role of immune system cells in the immunopathogenicity of lung damage and general hyperinflammation⁷.

None of our patients developed important organ deterioration in the first days/weeks, except for pulmonary involvement and signs of generalized inflammation (Table 3). In this regard, ferritin, a marker (or mediator) of inflammation⁸, increased and remained elevated in patients with longer ICU stays (patients 2, 5 and 6) and more severe evolution (patients 5 and 6). Despite increased high sensitivity troponin I levels, serial imaging scans in all patients during their ICU stay showed no evidence of heart disease. We, unlike other authors, only observed a few electrocardiogram changes, such as bradycardia, slight QT or QTc prolongation, and atrial fibrillation in some cases.

The patients that made poorer progress presented several coinfections that were rarely found at the time of presentation. This meant that changes in late laboratory parameters coincided with an increase in lactate, procalcitonin, C-reactive protein, etc. (Table 2), similar to typical acute respiratory distress syndrome aggravated by concurrent coinfections. It has been reported that systemic viral infections are often accompanied or immediately followed by bacterial and fungal infections, and that these can affect outcomes⁶.

In addition to anosmia and dysgeusia, recent studies have reviewed the issue of central nervous system (CNS) involvement⁹. We would draw attention to the neurological alterations consistently observed in these patients. Although this was not specifically defined in the first major studies performed in China, the USA, and Italy, we have observed neurological and psychiatric alterations in our patient since the first cases were admitted to our hospital and the ICU. Patients in the ICU presented confusion, dizziness, drowsiness and appeared disoriented and bradypsychic on admission (with normal to moderately low SaO₂ and normocapnia), and exhibited the same symptoms plus agitation, delirium, euphoria, confusion, etc. when sedation was stopped and they were extubated. The symptoms continued after transfer to the ward¹⁰. CNS involvement could be explained by hypoxia or the side effects of drugs (sedatives, muscle relaxants), but some patients with a short stay in the ICU also presented these symptoms. We could speculate that this is due to various mechanisms of CNS involvement,

because other coronaviruses are also neurotropic and neurological involvement was initially poorly reported despite an incidence of between 36.4%¹¹ and 67%¹². However, it is still unclear whether this is a result of viral invasion or general reaction to inflammation.

Changes in blood–brain barrier (BBB) permeability, theoretically a prerequisite for CNS invasion, are caused by several mechanisms and factors, including advanced age, inflammation and viraemia¹³. We could also hypothesise on the prevalence of a functional alteration caused by changes in the cholinergic anti-inflammatory pathway, without the need for direct viral invasion¹⁴. A potential invasion by SARS-CoV2 of some CNS nuclei could explain, at least in part, the origin of the respiratory failure observed in some COVID-19 patients¹⁵, and could have therapeutic implications. It remains to be seen whether this damage persists over time.

Critical patients were treated according to institutional protocols. However, these were changing day by day (following the recommendations of the Ministry of Health and the local administration), so the timing of the administration of some drugs differed in some patients. For example, anti-inflammatory drugs were started more than 1 week after the onset of symptoms in all cases, depending on the clinical response and laboratory findings, and drugs such as anakinra or sedatives were in short supply. This partly precluded a staged approach (therapeutic window).

This case series has several limitations. The number of cases is low, but our aim is to show the characteristics of selected typical COVID-19 cases. We naturally did not attempt to find a causal relationship; however, the descriptive information might be of interest to the reader because it shows the presentation of most patients during the pandemic.

In conclusion, we present the different evolutionary pathways and outcomes observed in 6 closely-related patients diagnosed with COVID-19. We discuss the typical findings, the clinical, laboratory and radiological characteristics, and the pathophysiology of the disease in addition to the widely described respiratory characteristics.

Conflict of interests

The authors have no conflict of interest to declare.

Appendix A. Supplementary data

Supplementary material related to this article can be found, in the online version, at doi:<https://doi.org/10.1016/j.redare.2021.03.006>.

References

1. Wang D, Hu B, Hu C, Zhu F, Liu X, Zhang J, et al. Clinical characteristics of 138 hospitalized patients with 2019 novel Coronavirus-infected pneumonia in Wuhan, China. *JAMA*. 2020;323:1061–9, <http://dx.doi.org/10.1001/jama.2020.1585>.
2. Huang C, Wang Y, Li X, Ren L, Zhao J, Hu Y, et al. Clinical features of patients infected with 2019 novel coronavirus in Wuhan, China. *Lancet*. 2020;395:497–506, [http://dx.doi.org/10.1016/S0140-6736\(20\)30183-5](http://dx.doi.org/10.1016/S0140-6736(20)30183-5).
3. Grasselli G, Zanella A. Critically ill patients with COVID-19 in New York City. *Lancet*. 2020;395, [http://dx.doi.org/10.1016/S0140-6736\(20\)31190-9](http://dx.doi.org/10.1016/S0140-6736(20)31190-9).
4. Cummings MJ, Baldwin MR, Abrams D, Jacobson SD, Meyer BJ, Balough EM, et al. Epidemiology, clinical course, and outcomes of critically ill adults with COVID-19 in New York City: a prospective cohort study. *Lancet*. 2020;20:363–74, [http://dx.doi.org/10.1016/S0140-6736\(20\)31189-2](http://dx.doi.org/10.1016/S0140-6736(20)31189-2).
5. Yang R, Gui X, Xiong Y. Comparison of clinical characteristics of patients with asymptomatic vs symptomatic Coronavirus disease 2019 in Wuhan, China. *JAMA Netw Open*. 2020;3:e2010182, <http://dx.doi.org/10.1001/jamanetworkopen.2020.10182>.
6. Zhou F, Yu T, Du R, Fan G, Liu Y, Liu Z, et al. Clinical course and risk factors for mortality of adult inpatients with COVID-19 in Wuhan, China: a retrospective cohort study. *Lancet*. 2020;395:1054–62, [http://dx.doi.org/10.1016/S0140-6736\(20\)30566-3](http://dx.doi.org/10.1016/S0140-6736(20)30566-3).
7. Tay MZ, Poh CM, Renia L, MacAry PA, Ng LFP. The trinity of COVID-19: immunity, inflammation and intervention. *Nat Rev Immunol*. 2020;20:363–74, <http://dx.doi.org/10.1038/s41577-020-0311-8>.
8. Rosario C, Zandman-Goddard G, Meyron-Holtz EG, d’Cruz DP, Shoenfeld Y. The hyperferritinemic syndrome: macrophage activation syndrome, Still’s disease, septic shock and catastrophic antiphospholipid syndrome. *BMC Med*. 2013;11:185, <http://dx.doi.org/10.1186/1741-7015-11-185>.
9. Zubair AS, McAlpine LS, Gardin T, Farhadian S, Kuruvilla DE, Spudich S. Neuropathogenesis and neurologic manifestations of the coronaviruses in the age of Coronavirus disease 2019: a review. *JAMA Neurol*. 2020;77:1018–27, <http://dx.doi.org/10.1001/jamaneurol.2020.2065>.
10. Steardo L, Steardo L Jr, Zorec R, Verkhatsky A. Neuroinfection may contribute to pathophysiology and clinical manifestations of COVID-19. *Acta Physiol (Oxf)*. 2020:e13473, <http://dx.doi.org/10.1111/apha.13473>.
11. Mao L, Wang M, Chen S, He Q, Chang J, Hong C, et al. Neurological manifestations of hospitalized patients with COVID-19 in Wuhan, China: a retrospective case series study. *JAMA Neurol*. 2020;77:683–90, <http://dx.doi.org/10.1001/jamaneurol.2020.1127>.
12. Helms J, Kremer S, Merdji H, Clere-Jehl R, Schenck M, Kummerlen C, et al. Neurologic features in severe SARS-CoV-2 infection. *N Engl J Med*. 2020;382:2268–70, <http://dx.doi.org/10.1056/NEJMc2008597>.
13. Abbott NJ. Inflammatory mediators and modulation of blood-brain barrier permeability. *Cell Mol Neurobiol*. 2000;20:131–47, <http://dx.doi.org/10.1023/a:1007074420772>.
14. Cuoco JA, Fennie CN, Cherian GK. The cholinergic anti-inflammatory pathway: a novel paradigm for translational research in neuroimmunology. *J Neurol Neurosci*. 2016;7:86, <http://dx.doi.org/10.21767/2171-6625.100086>.
15. Li YC, Bai WZ, Hashikawa T. The neuroinvasive potential of SARS-CoV2 may play a role in the respiratory failure of COVID-19 patients. *J Med Virol*. 2020, <http://dx.doi.org/10.1002/jmv.25728>.