



Review Article

Corresponding Author

Salman Sharif

<https://orcid.org/0000-0002-3332-1789>

Department of Neurosurgery, Liaquat
National Hospital and Medical College,
Karachi 74800, Pakistan
Email: sharifsalman73@gmail.com

Received: May 4, 2021
Revised: July 12, 2021
Accepted: July 14, 2021



Surgical Techniques for Thoracolumbar Spine Fractures: WFNS Spine Committee Recommendations

Salman Sharif¹, Yousuf Shaikh¹, Onur Yaman², Mehmet Zileli³

¹Department of Neurosurgery, Liaquat National Hospital and Medical College, Karachi, Pakistan

²Department of Neurosurgery, Memorial Bahçelievler Spine Center, Istanbul, Turkey

³Department of Neurosurgery, Ege University Faculty of Medicine, Izmir, Turkey

To formulate the specific guidelines for the recommendation of thoracolumbar fracture regarding surgical techniques and nonfusion surgery. WFNS (World Federation of Neurosurgical Societies) Spine Committee organized 2 consensus meeting. For nonfusion surgery and thoracolumbar fracture, a systematic literature search in PubMed and Google Scholar database was done from 2010 to 2020. The search was further refined by excluding the articles which were duplicate, not in English or were based on animal or cadaveric subjects. After thorough shortlisting, only 50 articles were selected for full review in this consensus meeting. To generate a consensus, the levels of agreement or disagreement on each item were voted independently in a blind fashion through a Likert-type scale from 1 to 5. The consensus was achieved when the sum for disagreement or agreement was $\geq 66\%$. Each consensus point was clearly defined with evidence strength, recommendation grade, and consensus level provided. A magnitude of prospective papers were analyzed to formulate consensus on various surgical techniques that can be employed to address different types of thoracolumbar fractures. Surgical treatment of thoracolumbar fractures can be a better option over the nonoperative approach, especially for those who cannot tolerate months in an orthosis or cast, such as those with multiple extremity injuries, skin lesions, obesity, and so forth. It generally allows early mobilization, less hospital stay, reduced pulmonary complications, and better correction of sagittal balance. Current available literature fails to demonstrate any statistically significant benefit of fusion surgery over nonfusion in thoracolumbar fractures.



This is an Open Access article distributed under the terms of the Creative Commons Attribution Non-Commercial License (<https://creativecommons.org/licenses/by-nc/4.0/>) which permits unrestricted non-commercial use, distribution, and reproduction in any medium, provided the original work is properly cited.

Copyright © 2021 by the Korean Spinal Neurosurgery Society

Keywords: Thoracolumbar fracture, Burst fracture, Spine trauma, Spinal fusion, Nonfusion surgery

INTRODUCTION

Traumatic fractures of the thoracolumbar spine, especially the thoracolumbar junction (T10–L2), are the most common fractures of the spinal column. One of the major contributing factors is the significant biomechanical stress acting on this junction between a mobile lumbar spine and a semirigid thoracic spine. The outcome can be devastating, ranging from complete paraplegia to incomplete weakness, persistent fracture site

pain, and deformity.^{1,2}

Patients with majority of thoracolumbar fractures may require surgical intervention, depending upon the degree of spinal instability. Over the past 75 years, many classification systems have been developed to quantify the degree of spinal instability and neurological compromise accurately, thereby aiding the decision-making process. Denis 3 column model was one of the easiest and most reproducible classifications and became the foundation of further advancement in fracture de-

scriptions.³ This was replaced by a much more complex AOSpine classification introduced by Magerl et al. in 1993.⁴ However, a recent study reported that the AO system (and the Denis) had only moderate reliability and repeatability among spine surgeons.⁵ The AO classification was later modified and was deemed essential for accurate diagnosis through proper assessment of the fracture morphology.^{6,7} Vaccaro et al.⁸ have proposed a novel thoracolumbar injury classification and severity score, which is relatively easy to reproduce and helps demarcate surgical patients from nonsurgical ones. This chapter will discuss the various surgical techniques that could be employed to address unstable thoracolumbar fractures.

MATERIALS AND METHODS

World Federation of Neurosurgical Societies (WFNS) Spine Committee organized 2 consensus meetings to formulate the recommendations for thoracolumbar fracture regarding surgical techniques.

A systematic literature search in PubMed and Google Scholar database was done from 2010 to 2020 with the keywords “thoracolumbar fractures” and “thoracolumbar spine fractures fixation technique.”

Up-to-date information on thoracolumbar fractures was re-

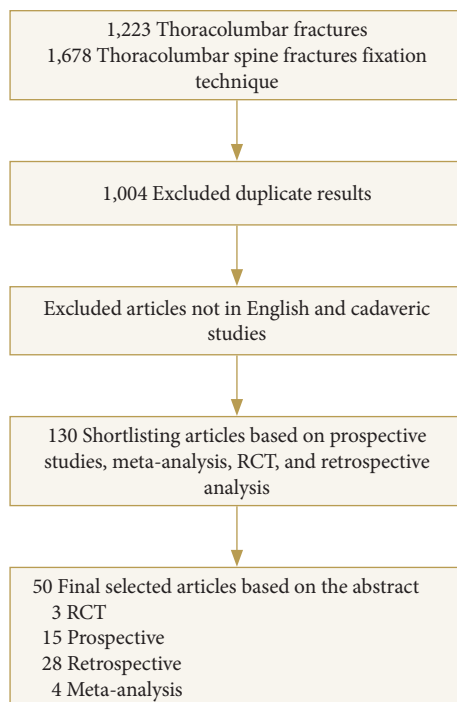


Fig. 1. Flowchart of literature search of thoracolumbar fracture and surgical techniques. RCT, randomized controlled trials.

viewed to reach an agreement in a consensus meeting of the WFNS Spine Committee. The first meeting was conducted in Peshawar in December 2019 with WFNS Spine Committee members’ presence and participation. The second meeting was a virtual meeting via the internet on June 12, 2020.

Both meetings aimed to analyze a preformulated questionnaire through preliminary literature review statements based on the current evidence levels to generate recommendations through a comprehensive voting session.

We utilized the Delphi method to administer the questionnaire to preserve a high degree of validity. To generate a consensus, the levels of agreement or disagreement on each item were voted independently in a blind fashion through a Likert-type scale from 1 to 5. The consensus was achieved when the sum for disagreement or agreement was $\geq 66\%$. Each consensus point was clearly defined with evidence strength, recommendation grade, and consensus level provided.

RESULTS

A systematic literature search in PubMed and Google Scholar database was done from 2010 to 2020 with the keywords “thoracolumbar fractures” and “thoracolumbar spine fractures fixation technique.” The search yielded 1,223 and 1,678 results respectively. Most of the results were duplicated between 2 databases. The search was further refined by excluding the articles which were duplicate, not in English, or were based on animal or cadaveric subjects. The results included case reports, case se-

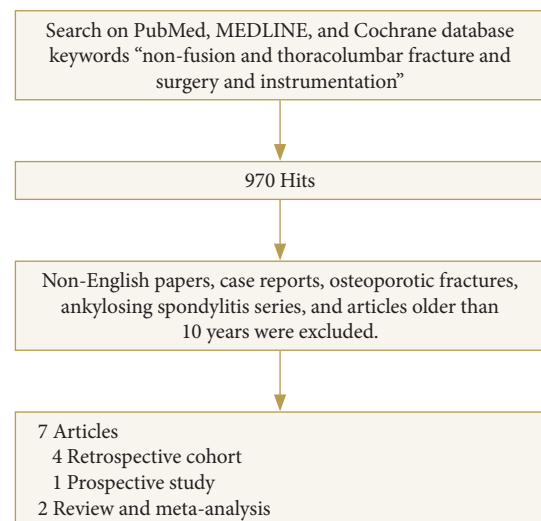


Fig. 2. Flowchart of literature search of thoracolumbar fracture and nonfusion surgery.

ries, prospective and retrospective studies, randomized studies, systematic reviews, and meta-analysis, shortlisting the count to 130. After reading the abstract, only 50 articles were selected for full review in this consensus meeting (Fig. 1).

Another search was performed using keywords “thoracolumbar fracture and nonfusion.” The same criteria were used. There were 566 results in PubMed and MEDLINE. We removed osteoporotic and ankylosing spondylitis fractures, non-English language papers, case reports, and low-quality case series. Seven papers were analyzed for this review. A flowchart of the literature search is shown in (Fig. 2).

DISCUSSION

1. Compression Fractures

Majority of compression fractures are stable and require a short period of bed rest and immobilization.

2. Burst Fractures

Burst fractures are the most common fracture requiring surgical intervention. These can be considered stable if posterior ligaments and facets are intact. Before embarking on a surgical procedure, the major question that needs answering is whether the fracture requires surgical intervention or not. In order to identify surgical indications, multiple classifications systems have been proposed to further characterize these fractures. The Thoracolumbar Injury Classification and Severity Score (TLICS) is the most commonly used score that serves the basis for guiding further treatment plan. Patients with a total score greater than 4 indicate instability and require surgical intervention where as those with a score < 4 are managed conservatively. Relative surgical indications include patients with TLICS score of less than 4 if they have intractable pain not responding to medical management or if the patient wants early mobilization. Similarly, AO classification which is much more extensive also works on a point-based system with surgery indicated for patients with score more than 5.

Main principles of thoracolumbar burst fracture surgery are; neural decompression, improve stability, and correction of kyphosis. Thoracolumbar fractures with 25°–30° kyphosis, progressive neurological deficits, loss of vertebral height more than 50%, and compression of the canal more than 50% should be treated surgically.⁹ Unstable thoracolumbar fractures cause sagittal imbalance due to progressive kyphosis when they have not been treated.^{9,10}

1) Burst fracture: posterior approach and variations

One of the most common and easy procedures to perform is posterior transpedicular screw fixation. It remains the most popular technique today, although not entirely free of complications, including instrumentation failure, pseudarthrosis, infection, and the need for late instrumentation removal.¹¹ One of the dilemmas to overcome in such circumstances is to identify the number of levels that require fusion. For many years thoracolumbar junction fractures have been conventionally treated with long constructs with 4 screws proximal and distal to fracture level. Long-segments posterior fixation imparts greater stability and support with less chances of implant failure but at the cost of sacrificing motion segments. In addition, it is unclear how these constructs of variable length affect adjacent or nearby segments.¹² Long-segment fixations are known to cause increased movement in adjacent disc spaces leading to raised intradiscal pressure. These biomechanical effects are known to hasten disc degeneration process.¹³ To overcome the limitations of long-segment fixation, many authors have put forward a short-segment fixation technique incorporating the pedicle of fractured vertebrae well over a decade ago.¹⁴ Parker et al.¹⁵ explained that a load-sharing score of 6 or less is sufficient to be treated by short-segment pedicle screw fixation. However, Lee et al.¹⁶ reported that in his study of 47 patients, short-segment pedicle screw fixation was ineffective with a load-sharing score of 7 or more. Kim et al.¹⁷ also reported significant differences in the loss of correction angle between long-segment and short-segment posterior fixations, indicating that short-segment posterior instrumentation is insufficient in cases with a load-sharing score of 7 points or above.

However, Altay et al.¹⁸ recommended that short-segment fixation provides adequate fixation with no loss of height or correction loss. Due to the ongoing dilemma and the possibility of implant failure with a large load-sharing score, a newer technique to incorporate fracture segment into the construct was introduced. Park et al.¹⁹ in their study of 45 patients, compared short-segment fixation and intermediate screw with long-segment fixation. A follow-up of 5 years was carried out to assess the degree of correction loss, implant failure, and revision surgery. His results showed that there was no significant difference in outcome between the 2 groups. Hence the use of intermediate screw has been shown to add strength to short-segment fusion. Recent biomechanical studies confide with the results showing the placement of intermediate screw at fracture level increases the stiffness of the construct and protects the anterior column during loading.²⁰ Similar results have been demonstrated

by Chung and Rhym²¹ who reported that easy indirect reduction of fractured vertebrae and improved segmental stability could be achieved by inserting the pedicle screw at the level of the fractured vertebra. Jeong et al.²² compared the clinical and radiological results between short-segment and long-segment pedicle fixation while inserting the pedicle screws at the level of the fractured vertebra in the thoracolumbar burst fracture and obtained similar results. Mahar et al.¹⁴ also reported that segmental fixation with additional screws at the level of the fracture increases constructs stiffness and shields the fractured vertebral body from anterior loads (Fig. 3A, B).

One of the major limitations to all these techniques is the lack of level 1 evidence. All the aforementioned papers and studies are small prospective trials or retrospective analysis. Only a handful of randomized controlled trials have been conducted and that too of a very small sample size. Those worth special mentioning are by Li et al.²³ in 2016 who performed percutaneous pedicle screw fixation in 32 patients with 19 of them having an additional screw in fractured vertebra. His results concluded that an intermediate screw helped in better correction of kyphosis and a stronger construct. The other randomized controlled trial is by Lyu et al.²⁴ in 2016 who compared 3 different techniques, 3-level percutaneous fixation, 2-level

percutaneous fixation, and 3-level open fixation, respectively. His results showed 3-level percutaneous fixation to be the most effective technique in terms of operating time and blood loss. However, the efficacy of either technique was statistically same. (Fig. 4A, B).

With the available recent research, we can safely conclude that short-segment fixation with the incorporation of the fracture segment provides a stable construct even in a setting of high load-sharing score. In circumstances where anatomical boundaries are disrupted and fracture segment cannot be used, a long-segment fixation may be considered.

Recent trials for pedicle screw fixation technique are summarized in Table 1.

2) Burst fracture: use of monoaxial screws and crosslinks

The introduction of polyaxial screws has significantly incre-

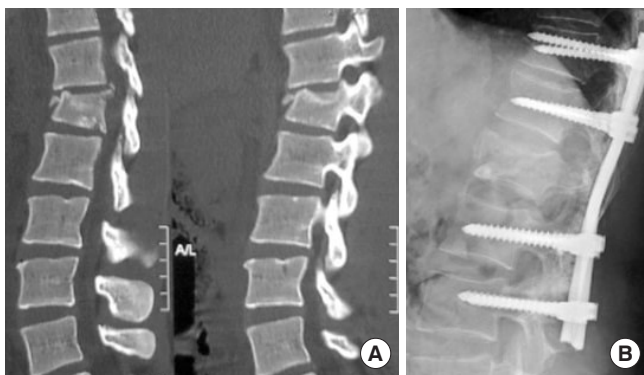


Fig. 3. (A) D12 burst fracture. (B) Traditional long constructs for junctional fractures.

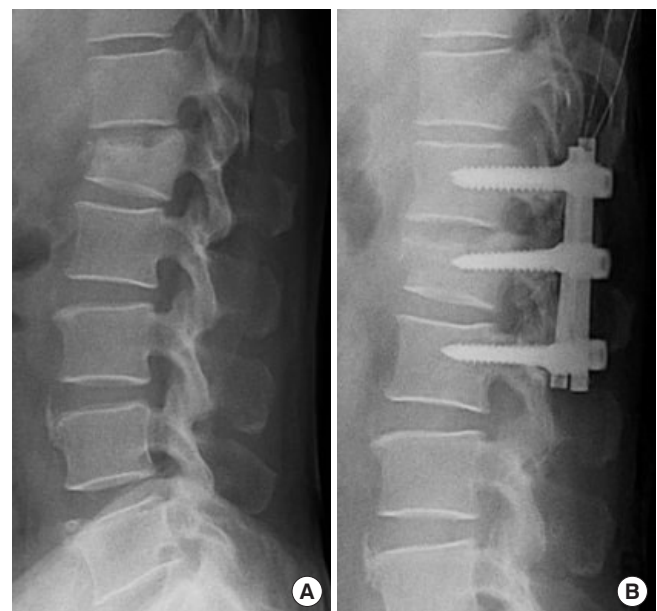


Fig. 4. (A) Burst fracture of thoracolumbar junction. (B) Short-segment fixation with an additional screw in fractured vertebrae.

Table 1. Recent trials for pedicle screw fixation technique

Study	Year of publication	Research type	No. of patients	Comparison made	Results
Park et al. ¹⁹	2016	Retrospective	45	2-Level vs. 3-level fixation	Results are similar
Li et al. ²³	2016	Prospective	32	Short-segment percutaneous screw vs. short segment with screw in fractured vertebrae	Short segment with screw in fractured vertebra is better
Lyu et al. ²⁴	2016	Randomized controlled trials	90	3-Level percutaneous fixation vs 2 level percutaneous fixation vs 3 level Open fixation	3-Level percutaneous fixation is superior to open technique

ased the ease of rod placement, particularly in long constructs. However, monoaxial screws that had initially phased away are now being reinvestigated due to their beneficiary effects in reducing burst fracture segments. Yao et al.²⁵ compared short-segment fixation using both monoaxial and polyaxial screws. He concluded that monoaxial screws at the fracture level have a flick-up effect on the central vertebral body contributing to the restoration of loss height. Similarly, Xue and Zhao²⁶ used monoaxial screws with distraction and compression to reduce collapsed endplate. He concluded that satisfactory fracture reduction and correction of segmental kyphosis could be achieved and maintained with the use of monoaxial pedicle screw fixation, including the fractured vertebra (Figs. 5, 6).

Although not frequently used, the addition of crosslinks, particularly in short-segment fixation, has been biomechanically proven to increase the strength of the construct.²⁷ An experimental study with cadaveric models has shown that crosslinks, when added to short-segment posterior fixation, improve stiffness and decrease motion in axial rotation.²⁸ Despite these studies, there is a lack of level 1 or 2 evidence to suggest the use of crosslinks and its current use is largely dependent on the surgeon's preference.

3) Burst fracture: nonfusion surgery

Unstable thoracolumbar burst fractures need to be treated

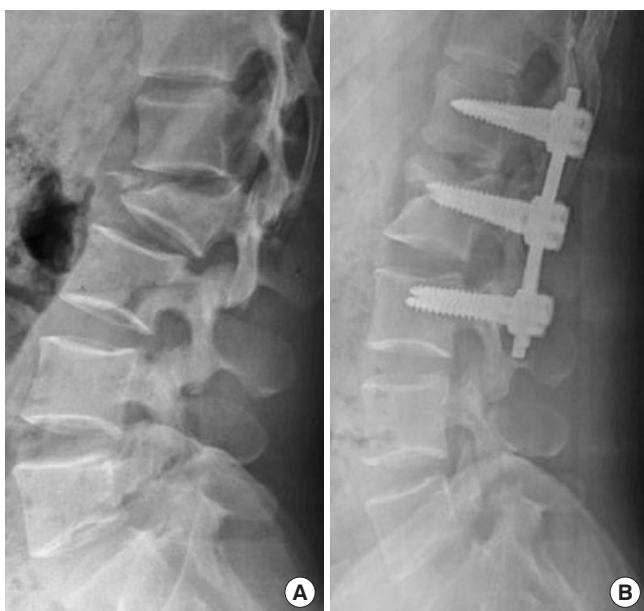


Fig. 5. (A) Burst fracture of junction with significant loss of height and kyphosis. (B) Use of monoaxial screws for distraction and restoration of lost vertebral height.

surgically. However, the ideal surgery is still controversial. Long term of clinical and radiological results of posterior surgeries have been published.^{29,30}

Fusion surgery is an effective method used in the treatment of thoracolumbar fractures. Necessity of fusion surgery is controversial due to complications like pseudoarthrosis and adjacent segment.³¹ Articles on the effectiveness of nonfusion surgeries in thoracolumbar fractures have been published, in the last decade.^{16,32}

Anterior, posterior, and combined surgeries are the treatment options of thoracolumbar fractures. Posterior only surgery has good clinical and radiological results. Instrumentation levels for the treatment of thoracolumbar fractures is also another topic that has been discussed. The main advantage of short-segment instrumentation is the preservation of segmental motion.³³⁻³⁵ Intermediate screws (screw inserted in the fractured vertebra) strengthen the construct and they are more effective in correction of kyphosis.^{34,36}

Recent discussion is whether fusion is necessary for the treat-

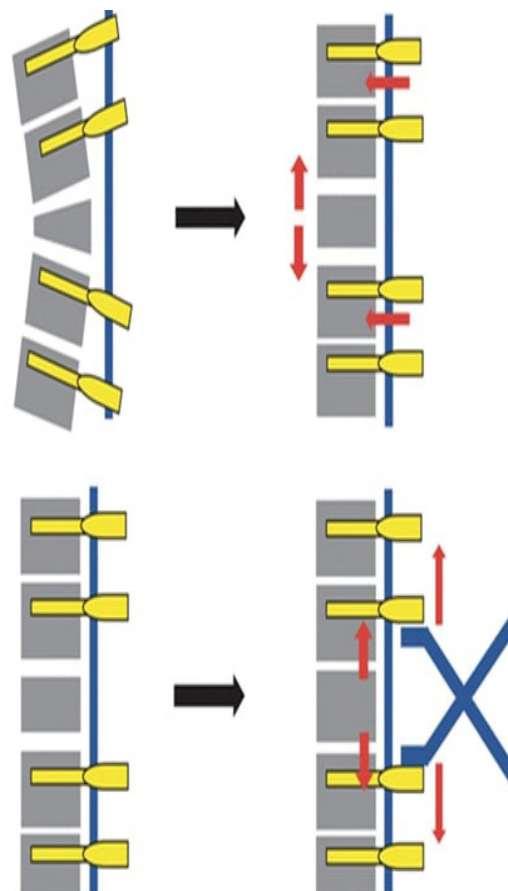


Fig. 6. Distraction/compression method for height restoration using monoaxial screws.

ment of thoracolumbar fractures.^{32,37} Some papers report better radiological correction with fusion surgeries compared to nonfusion surgeries.^{38,39} Other studies suggest that the loss in correction of kyphosis is less in patients who have undergone fusion surgery than nonfusion surgery, but difference is statistically insignificant.⁴⁰

4) *Burst fracture: fusion surgery*

The important advantage of fusion surgery is that the incidence of implant failure reduces when fusion is achieved.¹⁰ Despite this main advantage, fusion surgery decreases the segmental motion. It increases stress forces at the adjacent segment.^{9,15,41,42} Even in patients in which fusion is achieved, kyphosis may increase over time due to the decrease of the height of the disc. Screw breakage may occur due to the increase of kyphosis.⁴³ It has been reported that screw fractures do not make a clinical difference.^{44,45}

Qian et al.⁴⁶ reported that the posterolateral fusion was an effective measure to prevent implant failure in burst fractures, but Sanderson et al.⁴⁵ and Dai et al.⁴⁷ recommended that routine fusion was unnecessary in the operative management of these fractures. Singh et al.⁴⁸ performed a prospective study where 66 patients with thoracolumbar fractures underwent posterior instrumentation with fusion. These patients were followed both clinically and radiologically for up to 12 months. Their results showed that they had less loss of the postoperative correction achieved for all radiological parameters on the final follow-up as compared to the available literature.⁴⁹ Hwang et al.¹⁰ reported that in the patient group who underwent fusion surgery, there were infection, bleeding, pain, and wound healing problems in the iliac donor site. Excessive muscle dissection and bone removal for fusion increase bleeding in fusion surgery.^{31,40} Lan et al. have reported is no difference in postoperative clinical scores in the patient group with fusion and nonfusion surgery.³¹

Studies have shown that nonfusion surgeries have less surgery time and reduce bleeding for the the treatment of thoracolumbar fractures.^{10,31,40} Chou et al.⁴⁴ have reported that thoracolumbar fractures that have been operated with nonfusion short-segment instrumentation have less bleeding, shorter surgical time, fewer bone graft donor site complications, and motion segment preservation. Hwang et al.¹⁰ compared thoracolumbar fractures patients that were treated with short-segment instrumentation with fusion and nonfusion and reported less bleeding and less surgical time in nonfusion surgery group compared to fusion surgery group. They also discussed the advantage of segmental motion preservation and less adjacent segment dis-

ease. Lee et al. showed less bleeding and minimal tissue damage with percutaneous short-segment instrumentation.¹⁶

One of the disadvantages of nonfusion surgery is the need of the implant removal at the end of the first year to prevent implant failure.^{10,37} Kim et al.³² reported that they have removed the screws at the end of an average of 10 months. Sanderson et al.⁴⁵ reported 14% screw fractures who underwent nonfusion short-segment instrumentation. They did not recommend removing the screws. Chou et al.⁴⁴ compared the patients that have been treated with nonfusion instrumentation with and without screw removal. They have reported that there was no functional or radiological difference between the 2 groups.

(1) *Radiological results of nonfusion surgery*

Wang et al.³⁷ stated that the patients in the nonfusion group obtained better radiological results than the fusion group and showed that segmental mobility decreased in the fusion group. Hwang et al.⁵⁰ reported that kyphosis correction was more effective in the fusion group. Chou et al.⁵¹ compared fusion and nonfusion short-segment instrumentation for thoracolumbar fractures. They concluded that there was no significant increase in kyphosis between the 2 groups and suggested that the loss of correction that occurred in the follow-up was due to the decrease in the disc height because of the degeneration of the damaged disc rather than the vertebral height loss.^{37,50} Kim et al.³² published the results of thoracolumbar fractures patients who underwent nonfusion short-segment instrumentation in patients without the disc and facet injury and had no loss of correction.

(2) *Clinical results of nonfusion surgery*

There are many studies that have compared fusion and nonfusion short-segment instrumentation for thoracolumbar fractures. In all of these studies, no clinical or radiological difference was reported between the fusion and nonfusion groups.^{37,40,45,47} Chou et al.⁴⁴ have compared fusion and nonfusion short-segment instrumentation groups and reported that there was no visual analogue scale (VAS) and low back outcome score difference between the 2 groups. Hwang et al. have compared fusion and nonfusion groups and they have reported that there was no clinically and radiologically significant difference in the correction of kyphosis. They also reported that there was loss of correction in the nonfusion group, but there was no clinically significant difference compared to the fusion group.¹⁰

We summarized the 7 papers on nonfusion surgery for thoracolumbar fracture at Table 2.

Table 2. Summary of the reviewed papers on nonfusion surgery

Study	Study design	Evidence level	No. of patients	Main target of the study	Conclusion
Lan et al., ³¹ 2017	Systemic review and meta-analysis	5	445	Comparing fusion and nonfusion for the treatment of thoracolumbar burst fractures	Nonfusion surgery has less blood loss, shorter operation time, better segmental motion and lower donor site pain
Chou et al., ⁴⁴ 2014	Prospective	2	22	Nonfusion surgery for thoracolumbar burst fracture	Regional segmental motion could be preserved without fusion
Hwang et al., ¹⁰ 2012	Retrospective	4	46	Comparison of posterior fixation alone and fixation with fusion	No significant differences in the kyphosis correction and clinical outcomes between the 2 groups
Chou et al., ⁵¹ 2016	Retrospective	4	69	The effect of removal of the implants after fixation of thoracolumbar burst fractures without fusion	The radiological and functional outcomes of both implant removal and retention were similar
Diniz et al., ⁴⁰ 2017	Systemic review and meta-analysis	5	220	Necessarity of fusion for thoracolumbar burst fracture treated with spinal fixation	Arthrodesis did not improve clinical outcomes. Fusion was associated with increased surgical time and higher intraoperative bleeding
Kim et al., ³² 2011	Retrospective	4	23	To evaluate the results of posterior stabilization of thoracolumbar fracture using nonfusion method	Nonfusion method is one of the most effective methods for thoracolumbar fractures, especially in young patients
Lee et al., ¹⁶ 2013	Retrospective	4	59	The effect of percutaneous short-segment instrumentation without fusion for the treatment of thoracolumbar burst fracture	Percutaneous pedicle fixation without bone graft provided earlier pain relief and functional improvement

5) Burst fracture: anterior surgery

The anterior column supports about 80% of the axial load of an intact spine. When the anterior column is substantially injured, the anterior column support is reduced, leaving most of the stress transmitted by the posterior implant and the bony elements. Anterior surgery for such type of burst fractures was introduced in the 1980s when computed tomography (CT) scans demonstrated fracture fragments inside the spinal canal.⁵² Using an anterior transthoracic or transabdominal approach, the surgeon can directly visualize the fracture fragment and remove it completely without any traction on the spinal cord or risk of dural injury. If the defect is significant, it can be bridged with an artificial cage or bone graft to restore the height of the anterior column. Such forms of implants are usually supplemented with lateral body screw placement or posterior transpedicular screws. These techniques are as effective as posterior approaches in neurologically intact patients or even better in terms of restoration of vertebral body height and maintain sagittal balance with comparable outcomes.⁵³ Other studies have shown that degree of neurological recovery is equal to or greater than 80% and significantly correlated with the quality of neural decompression.⁵⁴

The principle of ligamentotaxis is based on the distraction that allows intracanalicular bony fragments to be pushed back into the vertebral body. But this requires the presence of an intact posterior longitudinal ligament. Biomechanically, the anterior approach may seem to be a better option when posterior elements have been injured and the ligamentotaxis cannot be utilized.⁵⁵ An isolated posterior approach is likely to cause iatrogenic injury to the spine or dura in these circumstances. But some surgeons have modified their posterior approach to address these pathologies by combining laminectomy and then unilateral pediclectomy.⁵⁶ As previously mentioned, current anterior approaches are considered as safe as posterior approaches. Kaneda et al.⁵² performed a study on 150 patients with a burst fracture of the thoracolumbar spine with neurological deficits. These patients were subsequently managed with a single-stage anterior spinal decompression, strut grafting, and anterior spinal instrumentation. At an average follow-up of 8 years, radiographs showed successful fusion of the injured spinal segment in 140 patients (93%) with a neurological recovery of 95%. Not many studies have compared anterior with posterior approaches. A meta-analysis by Zhu et al.⁵⁷ compared anterior and posterior surgeries and found no significant differences

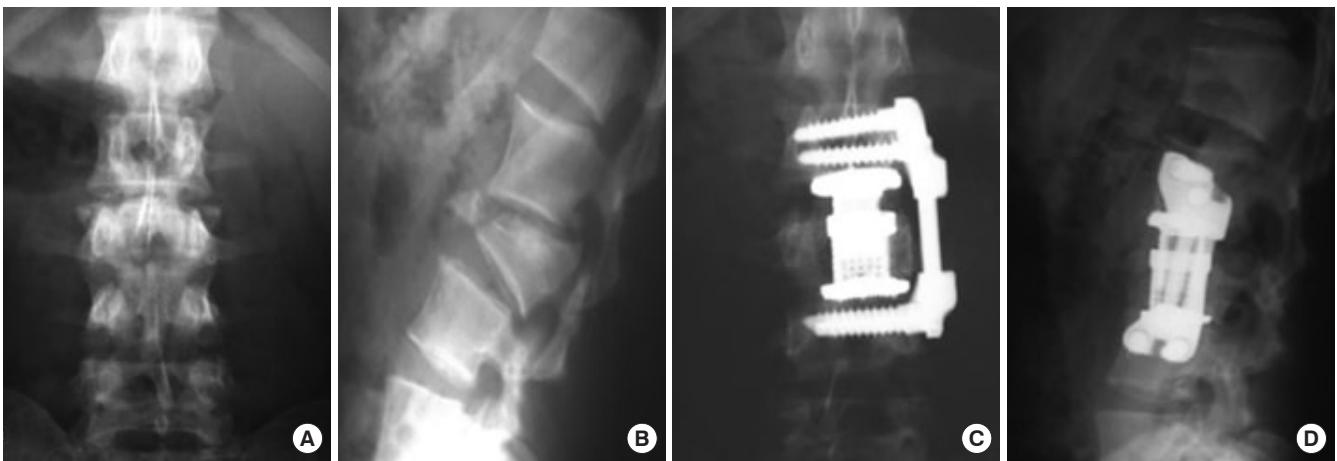


Fig. 7. (A) L1 burst fracture anteroposterior view. (B) L1 burst fracture lateral view. (C) Anterolateral approach with cage placement anteroposterior view. (D) Anterolateral cage placement lateral view.

between the two. However, the anterior approach was associated with more blood loss. Wood compared the 2 approaches in 38 patients and followed them for 2 years. He reported similar patient outcomes between the 2 approaches and that anterior fusion and instrumentation for thoracolumbar burst fractures might present fewer complications³² (Fig. 7A–D).

One of the major drawbacks of the anterior approach is its technical difficulty.⁵⁸ Not many surgeons are comfortable with the anterior approach, which might explain their tendency to shy away from these procedures and improvise on traditional posterior approaches. In addition to this, the procedure may be complicated in obese individuals with the possibility of significant blood loss. These parameters should be borne in mind while planning such operations.⁵⁹

6) Minimally invasive techniques

Conventional open techniques that are being employed to address thoracolumbar fractures are often criticized due to associated blood loss and higher infection rates.⁶⁰ In a systematic review conducted by Verlaan et al.⁶¹ blood loss of up to 1,000 mL has been documented in conventional open procedures with an average infection rate of 0.7% in anterior and 3% in posterior approaches. In addition to these, open procedures are also associated with significant approach-related morbidity. The anterior procedures are associated with significant perioperative pain, shoulder discomfort, and ventilation problems.⁶² Similarly posterior midline approaches lead to extensive retraction and muscle ischemia. These have been known to cause paraspinal muscle scarring, atrophy, and decreased muscle strength.⁶³ The clinical effect of this muscle morbidity can be a

significant postoperative pain and functional impairment in the long term.

In order to overcome these limitations, minimally invasive surgery (MIS) are being employed. Although there are no randomized controlled trials to document the safety and results of MIS techniques, most of the available literature suggests these procedures to be safe and effective.

(1) Anterior endoscopic decompression

For anterior approaches, an endoscope is most commonly used instrument. Endoscopic surgery requires appropriate training and experience. Since most injuries occur at the thoracolumbar junction, knowledge about the attachment and manipulation of the diaphragm is of extreme importance. The procedure is not only surgeon dependent but also requires endoscope-friendly instruments. Anterior endoscopic decompression assisted with posterior stabilization has been used to treat burst fractures⁶⁴ A large trial with 371 patients was conducted by Khoo et al.⁶⁵ in Germany, who did thoracoendoscopic decompression of burst fractures. In 35% of patients, a stand-alone anterior thoracoscopic reconstruction was performed. He reported a steep learning curve with a mean operating time of 300 minutes which was reduced to half after the 50th case. The risk of major complications in his series was 1%.

Similarly, Le Huec et al.⁶⁶ performed video endoscopic decompression and cage placement in 50 patients with thoracic fractures. He achieved good results with better kyphosis correction and neural decompression. Simultaneous anterior and posterior procedures were performed in 20 patients. Although no complications were reported in any of the cases, a long-term

follow-up was lacking. Compared to conventional open techniques, reduced blood loss, perioperative pain, reduced time to mobilization, and hospital stay have been noted.⁶⁷

(2) Percutaneous screw fixation

Percutaneous pedicle screw fixation can be used as a stand-alone procedure or an adjunct to anterior approaches in many circumstances. A systemic review by Phan et al.⁶⁸ in 2017 compared 279 patients undergoing percutaneous pedicle screw fixation with 340 patients who underwent conventional open instrumentation. He concluded that percutaneous pedicle screw fixation was a safe and effective means to treat thoracolumbar fractures. It was associated with reduced blood loss, operating time, and hospital stay. Similarly, Wang et al.⁶⁹ performed percutaneous pedicle screw fixation in 19 patients using the Sextant system and compared them with a conventional open group. After 2 years of follow-up, there were no significant differences in the postoperative sagittal Cobb angle, vertebral body angle, and the improvement of the vertebral body height and the kyphotic deformity correction between the 2 groups. He concluded that percutaneous pedicle screw placement is a good alternative to open procedures with shorter operating time and less blood loss. Another retrospective analysis by the same author compared MIS short-segment fixation with MIS long-segment fixation with screws in fractured vertebrae. Both of these procedures were then compared to the conventional open technique.⁶⁹ This is one of the unique articles that compared these 3 different techniques and found no statistical difference between any of them. However, percutaneous screws with an additional screw at fracture level were superior, with better height restoration and kyphosis correction (Fig. 8A, B).

(3) Cement augmentation

Chen and Lee⁷⁰ were the first individuals to use isolated cement injection to treat thoracolumbar burst fractures. They performed the technique on 6 patients. Although cement leak was seen radiographically in 4 patients, all of them remained asymptomatic. All the patients showed significant pain improvement postoperatively. Similarly, Huwart et al.⁷¹ described cement usage in 62 neurologically intact patients using CT-guided injection. Despite the high accuracy of the CT scan, cement leakage was still observed in 11%. All the patients showed significant improvement in Oswestry Disability Index (ODI) and VAS scores postoperatively. However, no long-term follow-up was available. In contrast to vertebroplasty, kyphoplasty involves an injection of contrast under low pressure within a confined

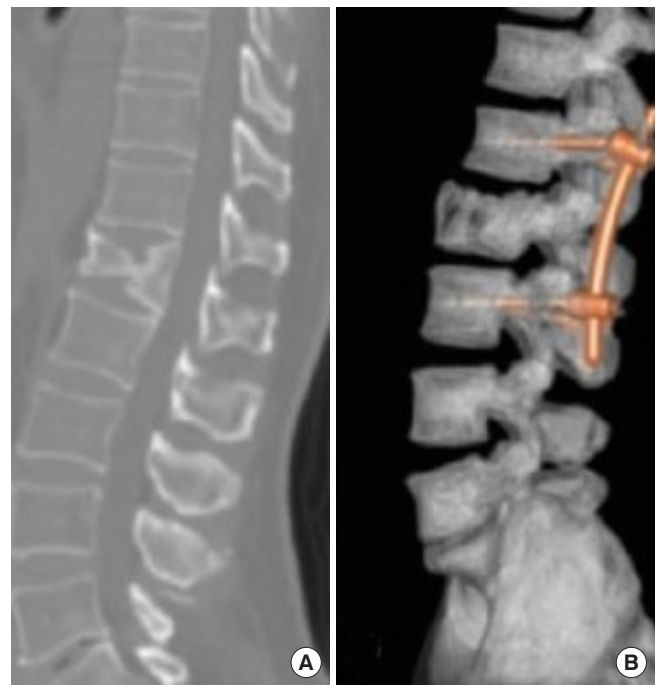

Fig. 8. (A) L1 unstable burst fracture. (B) Minimally Invasive screw placement rod fixation.

created space, theoretically reducing the chances of cement leakage. Hartmann et al.⁷² performed stand-alone kyphoplasty in burst fractures and reported significant post procedure improvement in pain. After 1-year follow-up, an average 6° loss of kyphosis correction was noticed radiologically though these patients remained asymptomatic. Currently, the literature available for stand-alone kyphoplasty and vertebroplasty in thoracolumbar trauma is very limited. Theoretically and based on small studies, kyphoplasty appears to be safer than vertebroplasty. However, despite such claims, isolated use of cement remains controversial in the trauma setting.

The objective of all forms of cement augmentation is to restore vertebral body height and support the anterior column. Cadaveric studies have shown that transpedicular vertebral body augmentation reduces pedicle screw bending moments by 59% in flexion and by 38% in extension, thereby decreasing the stresses on posterior instrumentation.⁷³ While depressed vertebral cortices can be reduced indirectly through ligamentotaxis via traction on the annular fibers, the central portion of the vertebral body remains depressed. Kyphoplasty offers a potential solution to this problem by directly reducing and buttressing the depressed endplate while providing stability to allow bony healing.⁷⁴ Multiple studies have shown benefits of cement augmentation with short-segment pedicle screw fixation.

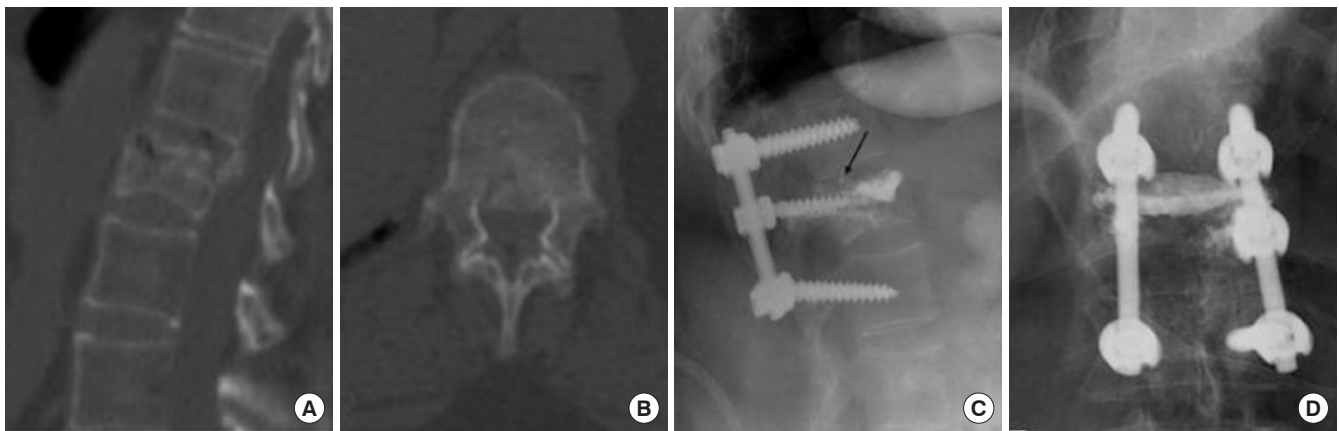


Fig. 9. Cement augmentation and screw placement of the fractured level. (A) D12 burst fracture computed tomography (CT) sagittal film. (B) D12 burst fracture axial CT scan. (C) Screw placement with incorporation of fracture segment and cement augmentation lateral view. (D) Screw placement and cement augmentation anteroposterior view.

Afzal et al.⁷⁵ reported a series of 16 patients with cement injection and short-segment fixation for burst fractures. Cement leakage into the canal was seen in 3 patients, which required immediate removal of cement. All their patients recovered successfully with no additional neurological deficits. Similarly, Verlaan et al.⁷⁶ and Fuentes et al.⁷⁷ showed similar results of cement augmentation and short-segment fixation in a limited number of patients with good kyphosis correction and stability. Cho⁷⁸ was one of the first ones to compare cement augmentation and short-segment fixation with short-segment fixation alone. The author concluded that at a 2-year follow-up, patients with cement augmentation have better kyphosis correction and pain improvement than other groups with no identifiable complications.⁷⁹ Lastly, a prospective randomized trial in patients older than 65 years with burst fractures was randomized into kyphoplasty (controls) and kyphoplasty with short-segment pedicle screw instrumentation. Patients treated with kyphoplasty and spinal instrumentation showed statistically improved VAS and ODI scores at the 2-year follow-up. In addition, the instrumented group exhibited better kyphosis reduction and maintenance of the corrected alignment (Fig. 9A–D).

CONCLUSION

Aforementioned data describe the various techniques that could be used to address thoracolumbar fractures with open posterior decompression and pedicle screw fixation being the most common surgical procedure employed across the world. Other forms of instrumentation are found to be equally effective, but lack of appropriate data and large randomized controlled

trials to back their claims.

The surgical treatment of unstable thoracolumbar fractures is still controversial. There is no difference in functional and radiological outcomes between fusion and nonfusion surgery. Less bleeding and less surgery time are the main advantages of non-fusion surgery.

WFNS SPINE COMMITTEE RECOMMENDATIONS

- For burst fractures, a short-segment posterolateral pedicle screw fixation is sufficient in most cases.
- For burst fractures of thoracolumbar junction, incorporating the fracture level screw is preferred to increase the strength of the construct. If fracture level screw cannot be incorporated, long-segment fixation should be applied.
- When using long-segment screws, there is no evidence that fusion is needed, as there is no difference in outcome with fusion or not.
- For thoracolumbar burst fractures, anterior or posterior approach does not make a difference in clinical outcomes.
- There is inadequate evidence that surgical treatment of burst fractures of the thoracic and lumbar spine may improve clinical outcome compared to nonoperative treatment.
- Minimally invasive techniques may be considered in the treatment of thoracolumbar burst fractures as the evidence suggests equivalent clinical outcomes, compared to open technique.
- Compared to fusion surgery, nonfusion surgery for thoracolumbar burst fractures has advantages of reduced bleed-

ing, surgical time, and donor site complications.

- There is no statistical data suggesting progression of regional kyphosis after nonfusion surgery.

CONFLICT OF INTEREST

The authors have nothing to disclose.

REFERENCES

1. Alpantaki K, Bano A, Pasku D, et al. Thoracolumbar burst fractures: a systematic review of management. *Orthopedics* 2010;33:422-9.
2. Charles YP, Steib JP. Management of thoracolumbar spine fractures with neurologic disorder. *Orthop Traumatol Surg Res* 2015;101(1 Suppl):S31-40.
3. Denis F. The three column spine and its significance in the classification of acute thoracolumbar spinal injuries. *Spine (Phila Pa 1976)* 1983;8:817-31.
4. Magerl F, Aebi M, Gertzbein SD, et al. A comprehensive classification of thoracic and lumbar injuries. *Eur Spine J* 1994;3:184-201.
5. Lopes FAR, Ferreira APRB, Santos RAAD, et al. Intraobserver and interobserver reproducibility of the old and new classifications of thoracolumbar fractures. *Rev Bras Ortop* 2018;53:521-6.
6. Verheyden AP, Spiegl UJ, Ekkerlein H, et al. Treatment of fractures of the thoracolumbar spine: recommendations of the spine section of the German Society for Orthopaedics and Trauma (DGOU). *Global Spine J* 2018;8(2 Suppl):34S-45S.
7. Vaccaro AR, Oner C, Kepler CK, et al. AOSpine thoracolumbar spine injury classification system: fracture description, neurological status, and key modifiers. *Spine (Phila Pa 1976)* 2013;38:2028-37.
8. Vaccaro AR, Zeiller SC, Hulbert RJ, et al. The thoracolumbar injury severity score: a proposed treatment algorithm. *J Spinal Disord Tech* 2005;18:209-15.
9. Cahueque M, Cobar A, Zuñiga C, et al. Management of burst fractures in the thoracolumbar spine. *J Orthop* 2016;13:278-81.
10. Hwang JU, Hur JW, Lee JW, et al. Comparison of posterior fixation alone and supplementation with posterolateral fusion in thoracolumbar burst fractures. *J Korean Neurosurg Soc* 2012;52:346-52.
11. Gautschi OP, Schatlo B, Schaller K, et al. Clinically relevant complications related to pedicle screw placement in thoracolumbar surgery and their management: a literature review of 35,630 pedicle screws. *Neurosurg Focus* 2011;31:E8.
12. Radcliff KE, Kepler CK, Jakoi A, et al. Adjacent segment disease in the lumbar spine following different treatment interventions. *Spine J* 2013;13:1339-49.
13. Kasliwal MK, Shaffrey CI, Lenke LG, et al. Frequency, risk factors, and treatment of distal adjacent segment pathology after long thoracolumbar fusion: a systematic review. *Spine (Phila Pa 1976)* 2012;37(22 Suppl):S165-79.
14. Mahar A, Kim C, Wedemeyer M, et al. Short-segment fixation of lumbar burst fractures using pedicle fixation at the level of the fracture. *Spine (Phila Pa 1976)* 2007;32:1503-7.
15. Parker JW, Lane JR, Karaikovic EE, et al. Successful short-segment instrumentation and fusion for thoracolumbar spine fractures: a consecutive 41/2-year series. *Spine (Phila Pa 1976)* 2000;25:1157-70.
16. Lee JK, Jang JW, Kim TW, et al. Percutaneous short-segment pedicle screw placement without fusion in the treatment of thoracolumbar burst fractures: is it effective?: comparative study with open short-segment pedicle screw fixation with posterolateral fusion. *Acta Neurochir (Wien)* 2013;155:2305-12.
17. Kim CH, Hwang JK, Choi YJ, et al. Treatment of thoracolumbar bursting fractures according to load-sharing classification. *J Korean Fract Soc* 2005;18:69-75.
18. Altay M, Ozkurt B, Aktekin CN, et al. Treatment of unstable thoracolumbar junction burst fractures with short- or long-segment posterior fixation in magerl type a fractures. *Eur Spine J* 2007;16:1145-55.
19. Park SR, Na HY, Kim JM, et al. More than 5-year follow-up results of two-level and three-level posterior fixations of thoracolumbar burst fractures with load-sharing scores of seven and eight points. *Clin Orthop Surg* 2016;8:71-7.
20. Anekstein Y, Brosh T, Mirovsky Y. Intermediate screws in short segment pedicular fixation for thoracic and lumbar fractures: a biomechanical study. *J Spinal Disord Tech* 2007;20:72-7.
21. Chung JY, Rhym IS. Short segment transpedicular Cotrel-Dubousset instrumentation including involved vertebra for fractures of thoracic and lumbar spine. *J Korean Orthop Assoc* 1994;29:940-8.
22. Jeong ST, Cho SH, Song HR, et al. Comparison of short and long-segment fusion in thoracic and lumbar fractures. *J Korean Soc Spine Surg* 1999;6:73-80.
23. Li K, Li Z, Ren X, et al. Effect of the percutaneous pedicle screw fixation at the fractured vertebra on the treatment of

- thoracolumbar fractures. *Int Orthop* 2016;40:1103-10.
24. Lyu J, Chen K, Tang Z, et al. A comparison of three different surgical procedures in the treatment of type A thoracolumbar fractures: a randomized controlled trial. *Int Orthop* 2016; 40:1233-8.
 25. Yao W, Guo R, Lai Q, et al. A comparison of monoaxial and polyaxial pedicle screws in thoracolumbar fracture. Posted 23 Jan, 2020. Available from: <https://www.researchsquare.com/article/rs-12273/v1>
 26. Xue X, Zhao S. Posterior monoaxial screw fixation combined with distraction-compression technology assisted endplate reduction for thoracolumbar burst fractures: a retrospective study. *BMC Musculoskelet Disord* 2020;21:17.
 27. Alizadeh M, Kadir MR, Fadhli MM, et al. The use of X-shaped cross-link in posterior spinal constructs improves stability in thoracolumbar burst fracture: a finite element analysis. *J Orthop Res* 2013;31:1447-54.
 28. Wahba GM, Bhatia N, Bui CN, et al. Biomechanical evaluation of short-segment posterior instrumentation with and without crosslinks in a human cadaveric unstable thoracolumbar burst fracture model. *Spine (Phila Pa 1976)* 2010;35: 278-85.
 29. Jindal N, Sankhala SS, Bachhal V. The role of fusion in the management of burst fractures of the thoracolumbar spine treated by short segment pedicle screw fixation: a prospective randomised trial. *J Bone Joint Surg Br* 2012;94:1101-6.
 30. El Behairy HF, M Abdelaziz A, Saleh AK, et al. Short-segment fixation of thoracolumbar fractures with incorporated screws at the level of fracture. *Orthop Surg* 2020;12:170-6.
 31. Lan T, Chen Y, Hu SY, et al. Is fusion superior to non-fusion for the treatment of thoracolumbar burst fracture? A systematic review and meta-analysis. *J Orthop Sci* 2017;22:828-33.
 32. Kim YM, Kim DS, Choi ES, et al. Nonfusion method in thoracolumbar and lumbar spinal fractures. *Spine (Phila Pa 1976)* 2011;36:170-6.
 33. Aly TA. Short segment versus long segment pedicle screws fixation in management of thoracolumbar burst fractures: meta-analysis. *Asian Spine J* 2017;11:150-60.
 34. Dobran M, Nasi D, Brunozzi D, et al. Treatment of unstable thoracolumbar junction fractures: short-segment pedicle fixation with inclusion of the fracture level versus long-segment instrumentation. *Acta Neurochir (Wien)* 2016;158: 1883-9.
 35. Kapoen C, Liu Y, Bloemers FW, et al. Pedicle screw fixation of thoracolumbar fractures: conventional short segment versus short segment with intermediate screws at the fracture level-a systematic review and meta-analysis. *Eur Spine J* 2020; 29:2491-504.
 36. Formica M, Cavagnaro L, Basso M, et al. Which patients risk segmental kyphosis after short segment thoracolumbar fracture fixation with intermediate screws? *Injury* 2016;47 Suppl 4:S29-34.
 37. Wang ST, Ma HL, Liu CL, et al. Is fusion necessary for surgically treated burst fractures of the thoracolumbar and lumbar spine?: a prospective, randomized study. *Spine (Phila Pa 1976)* 2006;31:2646-52.
 38. Martiniani M, Vanacore F, Meco L, et al. Is posterior fixation alone effective to prevent the late kyphosis after T-L fracture? *Eur Spine J* 2013;22 Suppl 6(Suppl 6):S951-6.
 39. Ye C, Luo Z, Yu X, et al. Comparing the efficacy of short-segment pedicle screw instrumentation with and without intermediate screws for treating unstable thoracolumbar fractures. *Medicine (Baltimore)* 2017;96:e7893.
 40. Diniz JM, Botelho RV. Is fusion necessary for thoracolumbar burst fracture treated with spinal fixation? A systematic review and meta-analysis. *J Neurosurg Spine* 2017;27:584-92.
 41. Cheh G, Bridwell KH, Lenke LG, et al. Adjacent segment disease following lumbar/thoracolumbar fusion with pedicle screw instrumentation: a minimum 5-year follow-up. *Spine (Phila Pa 1976)* 2007;32:2253-7.
 42. Wang XY, Dai LY, Xu HZ, et al. Kyphosis recurrence after posterior short-segment fixation in thoracolumbar burst fractures. *J Neurosurg Spine* 2008;8:246-54.
 43. Butt MF, Farooq M, Mir B, et al. Management of unstable thoracolumbar spinal injuries by posterior short segment spinal fixation. *Int Orthop* 2007;31:259-64.
 44. Chou PH, Ma HL, Wang ST, et al. Fusion may not be a necessary procedure for surgically treated burst fractures of the thoracolumbar and lumbar spines: a follow-up of at least ten years. *J Bone Joint Surg Am* 2014;96:1724-31.
 45. Sanderson PL, Fraser RD, Hall DJ, et al. Short segment fixation of thoracolumbar burst fractures without fusion. *Eur Spine J* 1999;8:495-500.
 46. Qian BP, Qiu Y, Wang B, et al. Effect of posterolateral fusion on thoracolumbar burst fractures. *Chin J Traumatol* 2006; 9:349-55.
 47. Dai LY, Jiang LS, Jiang SD. Posterior short-segment fixation with or without fusion for thoracolumbar burst fractures. a five to seven-year prospective randomized study. *J Bone Joint Surg Am* 2009;91:1033-41.

48. Singh R, Rohilla RK, Kamboj K, et al. Outcome of pedicle screw fixation and monosegmental fusion in patients with fresh thoracolumbar fractures. *Asian Spine J* 2014;8:298-308.
49. Shin TS, Kim HW, Park KS, et al. Short-segment pedicle instrumentation of thoracolumbar burst-compression fractures; short term follow-up results. *J Korean Neurosurg Soc* 2007;42:265-70.
50. Hwang JH, Modi HN, Yang JH, et al. Short segment pedicle screw fixation for unstable T11-L2 fractures: with or without fusion? A three-year follow-up study. *Acta Orthop Belg* 2009;75:822-7.
51. Chou PH, Ma HL, Liu CL, et al. Is removal of the implants needed after fixation of burst fractures of the thoracolumbar and lumbar spine without fusion? a retrospective evaluation of radiological and functional outcomes. *Bone Joint J* 2016; 98-B:109-16.
52. Kaneda K, Abumi K, Fujiya M. Burst fractures with neurologic deficits of the thoracolumbar-lumbar spine. Results of anterior decompression and stabilization with anterior instrumentation. *Spine (Phila Pa 1976)* 1984;9:788-95.
53. Oprel PP, Tuinebreijer WE, Patka P, et al. Combined anterior-posterior surgery versus posterior surgery for thoracolumbar burst fractures: a systematic review of the literature. *Open Orthop J* 2010;4:93-100.
54. Sasso RC, Best NM, Reilly TM, et al. Anterior-only stabilization of three-column thoracolumbar injuries. *J Spinal Disord Tech* 2005;18 Suppl:S7-14.
55. Mohanty SP, Bhat SN, Ishwara-Keerthi C. The effect of posterior instrumentation of the spine on canal dimensions and neurological recovery in thoracolumbar and lumbar burst fractures. *Musculoskelet Surg* 2011;95:101-6.
56. Bradford DS, McBride GG. Surgical management of thoracolumbar spine fractures with incomplete neurologic deficits. *Clin Orthop Relat Res* 1987;(218):201-16.
57. Zhu Q, Shi F, Cai W, et al. Comparison of anterior versus posterior approach in the treatment of thoracolumbar fractures: a systematic review. *Int Surg* 2015;100:1124-33.
58. Dai LY. Principles of management of thoracolumbar fractures. *Orthop Surg* 2012;4:67-70.
59. Lin B, Chen ZW, Guo ZM, et al. Anterior approach versus posterior approach with subtotal corpectomy, decompression, and reconstruction of spine in the treatment of thoracolumbar burst fractures: a prospective randomized controlled study. *J Spinal Disord Tech* 2012;25:309-17.
60. Zhang W, Li H, Zhou Y, et al. Minimally invasive posterior decompression combined with percutaneous pedicle screw fixation for the treatment of thoracolumbar fractures with neurological deficits: a prospective randomized study versus traditional open posterior surgery. *Spine (Phila Pa 1976)* 2016;41 Suppl 19:B23-9.
61. Verlaan JJ, Diekerhof CH, Buskens E, et al. Surgical treatment of traumatic fractures of the thoracic and lumbar spine: a systematic review of the literature on techniques, complications, and outcome. *Spine (Phila Pa 1976)* 2004;29:803-14.
62. De Giacomo T, Francioni F, Diso D, et al. Anterior approach to the thoracic spine. *Interact Cardiovasc Thorac Surg* 2011; 12:692-5.
63. Kim CW. Scientific basis of minimally invasive spine surgery: prevention of multifidus muscle injury during posterior or lumbar surgery. *Spine (Phila Pa 1976)* 2010;35(26 Suppl): S281-6.
64. Assaker R. Minimal access spinal technologies: state-of-the-art, indications, and techniques. *Joint Bone Spine* 2004;71: 459-69.
65. Khoo LT, Beisse R, Potulski M. Thoracoscopic-assisted treatment of thoracic and lumbar fractures: a series of 371 consecutive cases. *Neurosurgery* 2002;51(5 Suppl):S104-17.
66. Le Huec JC, Tournier C, Aunoble S, et al. Video-assisted treatment of thoracolumbar junction fractures using a specific distractor for reduction: prospective study of 50 cases. *Eur Spine J* 2010;19 Suppl 1(Suppl 1):S27-32.
67. Smith WD, Dakwar E, Le TV, et al. Minimally invasive surgery for traumatic spinal pathologies: a mini-open, lateral approach in the thoracic and lumbar spine. *Spine (Phila Pa 1976)* 2010;35(26 Suppl):S338-46.
68. Phan K, Rao PJ, Mobbs RJ. Percutaneous versus open pedicle screw fixation for treatment of thoracolumbar fractures: Systematic review and meta-analysis of comparative studies. *Clin Neurol Neurosurg* 2015;135:85-92.
69. Wang H, Zhou Y, Li C, et al. Comparison of open versus percutaneous pedicle screw fixation using the sextant system in the treatment of traumatic thoracolumbar fractures. *Clin Spine Surg* 2017;30:E239-46.
70. Chen JF, Lee ST. Percutaneous vertebroplasty for treatment of thoracolumbar spine bursting fracture. *Surg Neurol* 2004; 62:494-500.
71. Huwart L, Foti P, Andreani O, et al. Vertebral split fractures: technical feasibility of percutaneous vertebroplasty. *Eur J Radiol* 2014;83:173-8.
72. Hartmann F, Gercek E, Leiner L, et al. Kyphoplasty as an alternative treatment of traumatic thoracolumbar burst fractures Magerl type A3. *Injury* 2012;43:409-15.

73. Mumford J, Weinstein JN, Spratt KF, et al. Thoracolumbar burst fractures. The clinical efficacy and outcome of nonoperative management. *Spine (Phila Pa 1976)* 1993;18:955-70.
74. Verlaan JJ, van Helden WH, Oner FC, et al. Balloon vertebroplasty with calcium phosphate cement augmentation for direct restoration of traumatic thoracolumbar vertebral fractures. *Spine (Phila Pa 1976)* 2002;27:543-8.
75. Afzal S, Akbar S, Dhar SA. Short segment pedicle screw instrumentation and augmentation vertebroplasty in lumbar burst fractures: an experience. *Eur Spine J* 2008;17:336-41.
76. Verlaan JJ, Dhert WJ, Verbout AJ, et al. Balloon vertebroplasty in combination with pedicle screw instrumentation: a novel technique to treat thoracic and lumbar burst fractures. *Spine (Phila Pa 1976)* 2005;30:E73-9.
77. Fuentes S, Blondel B, Metellus P, et al. Percutaneous kyphoplasty and pedicle screw fixation for the management of thoraco-lumbar burst fractures. *Eur Spine J* 2010;19:1281-7.
78. Cho DY, Lee WY, Sheu PC. Treatment of thoracolumbar burst fractures with polymethyl methacrylate vertebroplasty and short-segment pedicle screw fixation. *Neurosurgery* 2003;53:1354-60.
79. Cheng LM, Wang JJ, Zeng ZL, et al. Pedicle screw fixation for traumatic fractures of the thoracic and lumbar spine. *Cochrane Database Syst Rev* 2013;(5):CD009073.