

Autosomal recessive spinocerebellar ataxia type 4 with a *VPS13D* mutation: A case report

Xin Huang, Dong-Sheng Fan

ORCID number: Xin Huang 0000-0002-1764-4537; Dong-Sheng Fan 0000-0002-3965-7718.

Author contributions: Huang X collected all the data, recorded the video, performed the literature review, and wrote the manuscript; Fan DS reviewed and revised the manuscript; all authors issued final approval for the version to be submitted.

Informed consent statement:

Informed written consent was obtained from the patient for publication of this report and any accompanying images.

Conflict-of-interest statement:

There are no conflicts of interest to disclose.

CARE Checklist (2016) statement:

The authors have read the CARE Checklist (2016), and the manuscript was prepared and revised according to the CARE Checklist (2016).

Country/Territory of origin: China

Specialty type: Neurosciences

Provenance and peer review:

Unsolicited article; Externally peer reviewed.

Peer-review model: Single blind

Peer-review report's scientific

Xin Huang, Dong-Sheng Fan, Department of Neurology, Peking University Third Hospital, Beijing 100191, China

Xin Huang, Dong-Sheng Fan, Municipal Key Laboratory of Biomarker and Translational Research in Neurodegenerative Diseases, Beijing 100191, China

Corresponding author: Dong-Sheng Fan, MD, PhD, Director, Professor, Department of Neurology, Peking University Third Hospital, No. 49 Huayuan Bei Road, Haidian District, Beijing 100191, China. dsfan2010@aliyun.com

Abstract

BACKGROUND

Autosomal recessive spinocerebellar ataxia type 4 (SCAR4) is a type of SCA that is a group of hereditary diseases characterized by gait ataxia. The main clinical features of SCAR4 are progressive cerebellar ataxia, pyramidal signs, neuropathy, and macrosaccadic intrusions. To date, many gene dysfunctions have been reported to be associated with SCAR4.

CASE SUMMARY

Here, we report a novel compound heterozygous mutation, c.3288delA (p.Asp1097-ThrfsTer6), in the *VPS13D* gene in a young female Chinese patient. The patient found something wrong with her legs about 10 years ago and presented with the typical characteristics of SCAR4 when she came to the hospital, including ataxia, neuropathy, and positive pyramidal signs. She was then diagnosed with SCAR4 and went home with symptomatic schemes.

CONCLUSION

SCAR4 is a hereditary disease characterized by ataxia, pyramidal signs, neuropathy, and macrosaccadic intrusions. We report a novel compound heterozygous mutation, c.3288delA (p.Asp1097ThrfsTer6), in the *VPS13D* gene, which enriches the gene mutation spectrum and provides additional information about SCAR4.

Key Words: Spinocerebellar ataxia; Recessive; *VPS13D* gene; Compound heterozygous mutation; Case report

©The Author(s) 2022. Published by Baishideng Publishing Group Inc. All rights reserved.

quality classification

Grade A (Excellent): 0
 Grade B (Very good): 0
 Grade C (Good): 0
 Grade D (Fair): 0
 Grade E (Poor): 0

Open-Access: This article is an open-access article that was selected by an in-house editor and fully peer-reviewed by external reviewers. It is distributed in accordance with the Creative Commons Attribution NonCommercial (CC BY-NC 4.0) license, which permits others to distribute, remix, adapt, build upon this work non-commercially, and license their derivative works on different terms, provided the original work is properly cited and the use is non-commercial. See: <http://creativecommons.org/licenses/by-nc/4.0/>

Received: July 10, 2021

Peer-review started: July 10, 2021

First decision: October 22, 2021

Revised: November 3, 2021

Accepted: December 3, 2021

Article in press: December 3, 2021

Published online: January 14, 2022

P-Reviewer: Faruk M

S-Editor: Ma YJ

L-Editor: Wang TQ

P-Editor: Ma YJ



Core Tip: We report a female Chinese patient diagnosed with autosomal recessive spinocerebellar ataxia type 4 (SCAR4) with a compound heterozygous mutation, c.3288delA (p.Asp1097ThrfsTer6), in the *VPS13D* gene. By reviewing the literature, we speculate that the mutation may cause SCAR4 by affecting mitochondrial function. However, there is currently no specific treatment for SCAR4.

Citation: Huang X, Fan DS. Autosomal recessive spinocerebellar ataxia type 4 with a *VPS13D* mutation: A case report. *World J Clin Cases* 2022; 10(2): 703-708

URL: <https://www.wjgnet.com/2307-8960/full/v10/i2/703.htm>

DOI: <https://dx.doi.org/10.12998/wjcc.v10.i2.703>

INTRODUCTION

Spinocerebellar ataxia (SCA) is a group of hereditary diseases characterized by progressive gait ataxia, dysarthria, and oculomotor disorders[1-4], which can be caused by autosomal dominant, autosomal recessive, or X-linked mutations[5]. Autosomal recessive SCA (SCAR) represents the type of SCA caused by autosomal recessive mutations. To date, 13 types of SCAR (named SCAR1-13) have been reported [6], and we focused on SCAR4 in the present study. SCAR4 is characterized by cerebellar ataxia, pyramidal signs, neuropathy, and macrosaccadic intrusions, generally developing in early adulthood[7]. SCAR4 has been reported to be caused by many gene mutations, and mutations in the vacuolar protein sorting-associated protein 13D isoform 1 (*VPS13D*) gene represent the essential component[7]. However, the details of the mechanism have not been explored thoroughly. Here, we report a case of SCAR4 with a novel compound heterozygous mutation in the *VPS13D* gene.

CASE PRESENTATION

Chief complaints

A 33-year-old Chinese woman came to our department for not being able to run for 10 mo.

History of present illness

The patient felt tired when standing up from squatting and walking downstairs 10 years ago, but daily life was not affected at that time. After that, she had increasingly more difficulties in these actions in the following days. Five years ago, she could not walk steadily even on a level road. Ten months ago, she realized that she could not run anymore. No muscle atrophy or fasciculation was found.

History of past illness

The patient had no previous history of neurological disorders, and she did not suffer any significant injuries in these years.

Personal and family history

The patient was born in Beijing and had no remarkable family history. Her parents and sister were clinically healthy (Figure 1).

Physical examination

On physical and neurological examination, the patient had an unsteady walk and an ataxic gait. Other cerebellar signs, such as nystagmus, nose-finger test, and heel-shin slide, were normal. Additionally, she could not stand up when squatting. Her tendon reflexes were hyperactive in the lower limbs. Bilateral Babinski signs, Hoffmann signs, and a Rossolimo sign in the left hand were also observed. There was no problem with muscle strength or sensory examination.

Laboratory examinations

There were increases in the levels of anti-CCP, anti-Ro52, and ANA. However, we

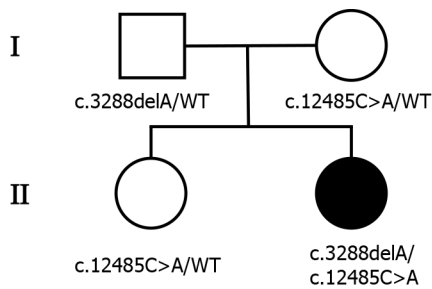


Figure 1 Pedigree of the patient's family. The patient's parents and sister were all healthy. Males and females are represented as squares and circles, respectively. The patient is indicated by black-filled symbols, and unfilled symbols indicate the unaffected individuals. The mutation state is given below.

could not determine what type of immune system disease that the patient had even with the help of physicians in the Department of Rheumatology because she did not have any related symptoms. Cerebrospinal fluid analysis was normal.

Imaging examinations

Electroneuronography showed reduced amplitude of sensory potentials in the right median nerve. Magnetic resonance imaging of the brain (Figure 2) showed no obvious abnormality, and lumbar MRI showed only mild hyperostosis.

Gene sequence analysis

To explore the underlying genetic patterns, we communicated with the patient and obtained informed consent for whole exon sequencing. We collected venous blood samples from the patient and her family at Peking University Third Hospital. We identified a novel compound heterozygous pathogenic mutation, c.3288delA (p.Asp1097ThrfsTer6; RefSeq NM_015378)/c.12485C>A (p.Thr4162Asn; RefSeq NM_015378), in the *VPS13D* gene in this patient. Her father was found to be heterozygous for the c.3288delA frameshift mutation, and her mother was found to be heterozygous for the c.12485C>A missense mutation in the *VPS13D* gene (Figure 3). Her parents reported no symptoms, which suggested that the disease was inherited in an autosomal recessive mode. Although there was also a c.6575C>T (p.Thr2192Ile; RefSeq NM_001376) missense variant in the *DYNC1H1* gene in this patient, but this variant may be clinically irrelevant.

FINAL DIAGNOSIS

The final diagnosis of this patient was SCAR4.

TREATMENT

The treatment of SCA has always been a difficult problem worldwide. However, there have been several clinical trials in recent years. There is no specific treatment for SCA to date. Currently, the treatment for the patient is mainly rehabilitation therapy.

OUTCOME AND FOLLOW-UP

The patient returned to the neurologic clinic regularly. She complained of worsening ataxia last time she returned in July 2021. We plan to continue the follow-up in the following years.

DISCUSSION

The clinical manifestations of SCAR are varied, including slowly progressive gait disorder, hypotonia, excessive clumsiness, *etc.*[8]. Similarly, SCAR mostly occur before the age of 30 years[2-9]. SCAR4, one type of SCAR, mainly presents with cerebellar

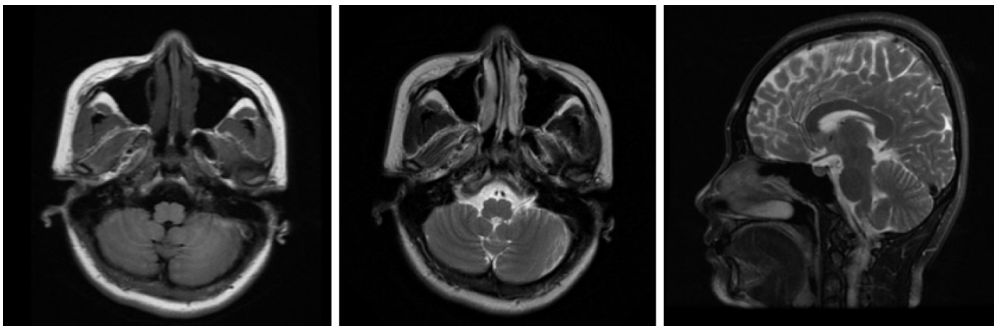


Figure 2 Brain magnetic resonance imaging. The image on the left is the T1-weighted axial image, the image in the middle is the T2-weighted axial image, and the image on the right is the T2-weighted sagittal image. No cerebellar atrophy was observed.

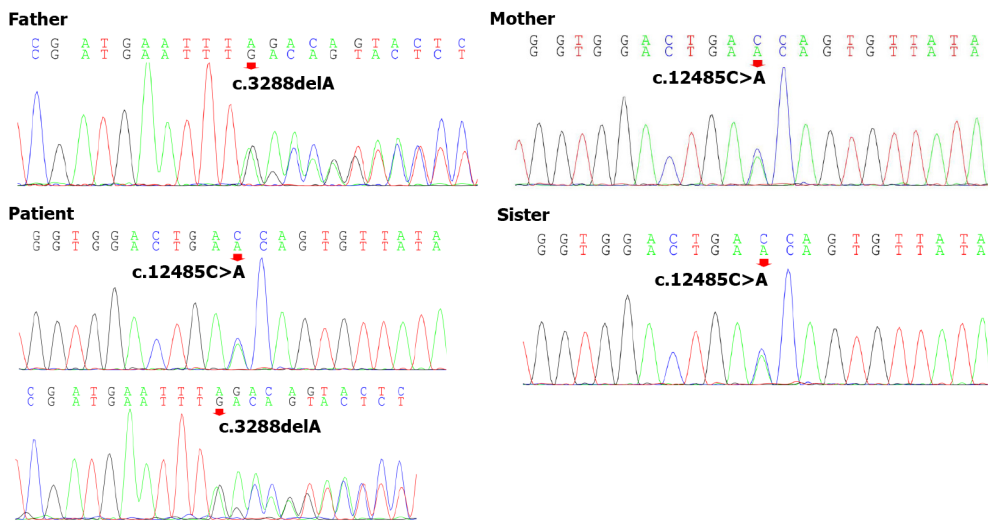


Figure 3 Genomic sequence electropherograms. The patient carried a novel c.3288delA (p.Asp1097ThrfsTer6) frameshift mutation of the *VPS13D* gene, which was not detected in Chinese databases. Only the patient's father was heterozygous for this mutation among her parents and sister, and her mother was heterozygous for c.12485C>A (p.Thr4162Asn). Pedigree analysis suggested that the disease was consistent with autosomal recessive inheritance.

ataxia, neuropathy, pyramidal signs, and macrosaccadic intrusions[7]. The patient's clinical presentation was consistent with the diagnosis of SCAR4. First, the patient developed symptoms early as her symptoms appeared at 22 years old and became evident at 32 years old. The main symptoms were unsteady walking and clumsiness when walking. In addition, the patient felt tired quickly before the unsteady walk. Consistently, the phenomena of pre-ataxia were confirmed by two earlier observational studies, which found other symptoms occurring several years before ataxia[10]. Pyramidal signs, as identified by physical examination, and neuropathy, as observed by electroneuronography, provided evidence consistent with the diagnosis. Because we did not perform electronystagmograms, we could not confirm the saccadic intrusions. Overall, the patient's clinical manifestations were in accordance with SCAR4.

Currently, the diagnosis of SCAR4 relies on genetic testing[11]. SCAR4 is mapped to chromosome 16q22.1, and the *VPS13D* gene has been reported to be closely related to SCAR4[7]. In this case, we found a novel compound heterozygous mutation in the *VPS13D* gene, c.3288delA (p.Asp1097ThrfsTer6; RefSeq NM_015378)/c.12485C>A (p.Thr4162Asn; RefSeq NM_015378). Pedigree analysis suggested that the disease was autosomal recessive inherited. This mutation has not been described in the previous literature. Furthermore, the new mutation is located in a relatively conserved domain, suggesting that the variant may be a pathogenic mutation (Figure 4).

VPS13D (NM_015378.3) consists of 69 exons spanning approximately 281000 nucleotides, and it encodes a 4388 amino acid protein (NP_056193.2)[12,13]. Although large, *VPS13D* is intolerant to variations[14]. Only 27 individuals from 15 families have been identified with *VPS13D* mutations (Figure 5)[7,14-18]. Previous studies have reported that *VPS13D* gene variants could lead to normal growth and development

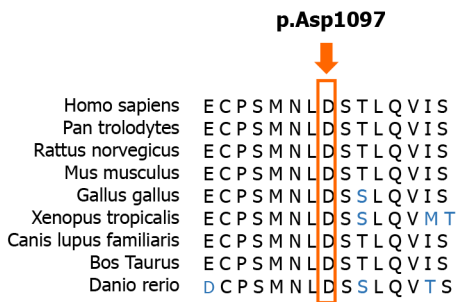


Figure 4 Conservation of amino acids in the context of the frameshift mutation. Amino acid sequence alignments of some of the amino acids affected by the mutation are shown for selected species. The red rectangle highlights the first amino acid affected by the frameshift mutation. This novel mutation is located in a relatively conserved domain.

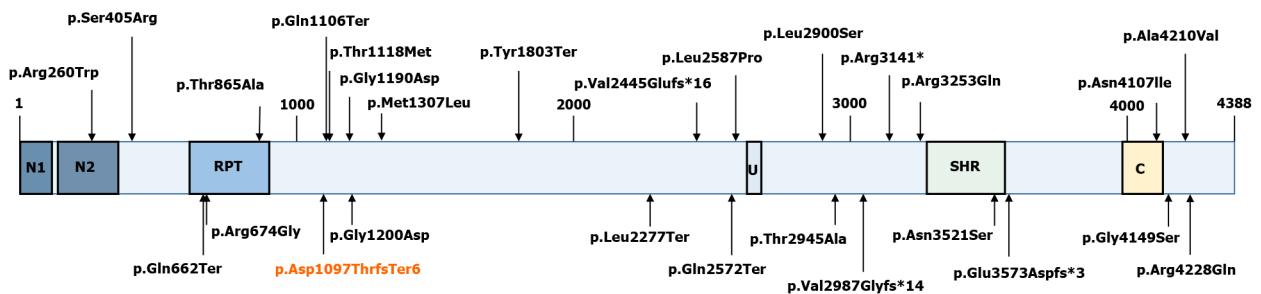


Figure 5 Schematic representation of the VPS13D protein (RefSeq NM_015378). The novel p.Asp1097ThrfsTer6 mutation is marked red. The others are mutations that have since been found in other studies: p.Ser405Arg, p.Thr1118Met, p.Arg3141*, and p.Thr2945Ala (Koh *et al*[13], 2020); p.Gly1190Asp, p.Ala4210Val, p.Met1307Leu, p.Gly4149Ser, p.Asn4107Ile, p.Gln1106Ter, p.Tyr1803Ter, p.Gln662Ter, p.Gln2572Ter, p.Val2987Glyufs*14, and p.Leu2277Ter (Seong *et al*[7], 2018); p.Val2445Gluufs*16, p.Leu2900Ser, p.Asn3521Ser, p.Glu3573Aspfs*3, p.Arg4228Gln, p.Arg3253Gln, p.Leu2900Ser, p.Thr865Ala, p.Arg674Gly, and p.Gly1200Asp (Gauthier *et al*[12], 2018); p.Arg260Trp (McCarthy *et al*[14], 2014); p.Arg674Gly (Shamseldin HE *et al*[16], 2017); and p.Leu2587Pro (Lee JS *et al*[15], 2020). N1: VPS13 1st N-terminal domain (aa 2-115); N2: VPS13 2nd N-terminal domain (aa 137-356); U: Ubiquitin-associated (UBA)-like domain (aa 2627-2679); SHR: VPS13 SHORT ROOT transcription factor-binding domain (aa 3276-3558); C: VPS13 C-terminal domain (aa 3983-4129).

but with cerebellar ataxia, pyramidal signs, and extrapyramidal signs[7-14,19].

VPS13D is an important protein involved in mitochondrial metabolism, including autophagy (mitophagy), fission, and clearance in *Drosophila*[18,19]. *VPS13D* is also essential in human cells. Researchers have observed enlarged mitochondria in human HeLa cells with *VPS13D* knockout[20]. Gauthier *et al*[12] reported that T2 hyperintensities in the basal ganglia and/or white matter could be observed on brain MRI in *VPS13D*-caused movement disorders. Considering that mitochondrial leukodystrophies also show a pattern of diffuse subcortical white matter and bilateral basal ganglia involvement, we suggest that the impact of *VPS13D* mutation on mitochondrial function may be part of the pathophysiological mechanisms of these diseases[14].

CONCLUSION

To date, studies on SCAR4 are insufficient with only a few reported cases. Nonetheless, SCAR4 shows genetic heterogeneity and the pathogenesis and treatment are far from clear at present. It is necessary to collect data on mutations in the *VPS13D* gene and to further explore the correlations between genotype and phenotype. We report a female Chinese patient diagnosed with SCAR4 with a compound heterozygous mutation, c.3288delA (p.Asp1097ThrfsTer6), in the *VPS13D* gene, which enriches the gene mutation spectrum and is valuable information for SCAR4. The physiopathological mechanism of the gene variant requires further investigation.

REFERENCES

- Sullivan R, Yau WY, O'Connor E, Houlden H. Spinocerebellar ataxia: an update. *J Neurol* 2019; 266: 533-544 [PMID: 30284037 DOI: 10.1007/s00415-018-9076-4]

- 2 **Hetzelt KLML**, Kraus C, Kusnik S, Thiel CT, Uebe S, Ekici AB, Trollmann R, Reis A, Zweier C. A case of severe autosomal recessive spinocerebellar ataxia type 18 with a novel nonsense variant in GRID2. *Eur J Med Genet* 2020; **63**: 103998 [PMID: 32622959 DOI: 10.1016/j.ejmg.2020.103998]
- 3 **Schöls L**, Bauer P, Schmidt T, Schulte T, Riess O. Autosomal dominant cerebellar ataxias: clinical features, genetics, and pathogenesis. *Lancet Neurol* 2004; **3**: 291-304 [PMID: 15099544 DOI: 10.1016/S1474-4422(04)00737-9]
- 4 **Klockgether T**, Mariotti C, Paulson HL. Spinocerebellar ataxia. *Nat Rev Dis Primers* 2019; **5**: 24 [PMID: 30975995 DOI: 10.1038/s41572-019-0074-3]
- 5 **Palau F**, Espinós C. Autosomal recessive cerebellar ataxias. *Orphanet J Rare Dis* 2006; **1**: 47 [PMID: 17112370 DOI: 10.1186/1750-1172-1-47]
- 6 **Morino H**, Miyamoto R, Ohnishi S, Maruyama H, Kawakami H. Exome sequencing reveals a novel TTC19 mutation in an autosomal recessive spinocerebellar ataxia patient. *BMC Neurol* 2014; **14**: 5 [PMID: 24397319 DOI: 10.1186/1471-2377-14-5]
- 7 **Seong E**, Insolera R, Dulovic M, Kamsteeg EJ, Trinh J, Brüggemann N, Sandford E, Li S, Ozel AB, Li JZ, Jewett T, Kievit AJA, Münchau A, Shakkottai V, Klein C, Collins CA, Lohmann K, van de Warrenburg BP, Burmeister M. Mutations in VPS13D lead to a new recessive ataxia with spasticity and mitochondrial defects. *Ann Neurol* 2018; **83**: 1075-1088 [PMID: 29604224 DOI: 10.1002/ana.25220]
- 8 **Anheim M**, Tranchant C, Koenig M. The autosomal recessive cerebellar ataxias. *N Engl J Med* 2012; **366**: 636-646 [PMID: 22335741 DOI: 10.1056/NEJMra1006610]
- 9 **Guan RY**, Wu JJ, Ding ZT, Wang J, Sun YM. Clinical and genetic findings in a cohort of Chinese patients with autosomal recessive spinocerebellar ataxia. *Clin Genet* 2020; **97**: 532-535 [PMID: 31743419 DOI: 10.1111/cge.13669]
- 10 **Meijer IA**. VPS13D Movement Disorder. 2019 Feb 21. In: GeneReviews® [Internet]. Seattle (WA): University of Washington, Seattle; 1993-2022 [PMID: 30789691]
- 11 **Velayos-Baeza A**, Vettori A, Copley RR, Dobson-Stone C, Monaco AP. Analysis of the human VPS13 gene family. *Genomics* 2004; **84**: 536-549 [PMID: 15498460 DOI: 10.1016/j.ygeno.2004.04.012]
- 12 **Gauthier J**, Meijer IA, Lessel D, Mencacci NE, Krainc D, Hempel M, Tsiakas K, Prokisch H, Rossignol E, Helm MH, Rodan LH, Karamchandani J, Carecchio M, Lubbe SJ, Telegrafi A, Henderson LB, Lorenzo K, Wallace SE, Glass IA, Hamdan FF, Michaud JL, Rouleau GA, Campeau PM. Recessive mutations in VPS13D cause childhood onset movement disorders. *Ann Neurol* 2018; **83**: 1089-1095 [PMID: 29518281 DOI: 10.1002/ana.25204]
- 13 **Koh K**, Ishiura H, Shimazaki H, Tsutsumiuchi M, Ichinose Y, Nan H, Hamada S, Ohtsuka T, Tsuji S, Takiyama Y. VPS13D-related disorders presenting as a pure and complicated form of hereditary spastic paraplegia. *Mol Genet Genomic Med* 2020; **8**: e1108 [PMID: 31876103 DOI: 10.1002/mgg3.1108]
- 14 **McCarthy SE**, Gillis J, Kramer M, Lihm J, Yoon S, Berstein Y, Mistry M, Pavlidis P, Solomon R, Ghiban E, Antoniou E, Kelleher E, O'Brien C, Donohoe G, Gill M, Morris DW, McCombie WR, Corvin A. De novo mutations in schizophrenia implicate chromatin remodeling and support a genetic overlap with autism and intellectual disability. *Mol Psychiatry* 2014; **19**: 652-658 [PMID: 24776741 DOI: 10.1038/mp.2014.29]
- 15 **Lee JS**, Yoo T, Lee M, Lee Y, Jeon E, Kim SY, Lim BC, Kim KJ, Choi M, Chae JH. Genetic heterogeneity in Leigh syndrome: Highlighting treatable and novel genetic causes. *Clin Genet* 2020; **97**: 586-594 [PMID: 32020600 DOI: 10.1111/cge.13713]
- 16 **Shamseldin HE**, Kurdi W, Almusafri F, Alnemer M, Alkaff A, Babay Z, Alhashem A, Tulbah M, Alsahan N, Khan R, Sallout B, Al Mardawi E, Seidahmed MZ, Meriki N, Alsaber Y, Qari A, Khalifa O, Eyaid W, Rahbeeni Z, Kurdi A, Hashem M, Alshidi T, Al-Obeid E, Abdulwahab F, Ibrahim N, Ewida N, El-Akouri K, Al Mulla M, Ben-Omran T, Pergande M, Cirak S, Al Tala S, Shaheen R, Faqeih E, Alkuraya FS. Molecular autopsy in maternal-fetal medicine. *Genet Med* 2018; **20**: 420-427 [PMID: 28749478 DOI: 10.1038/gim.2017.111]
- 17 **Steel D**, Kurian MA. Recent genetic advances in early-onset dystonia. *Curr Opin Neurol* 2020; **33**: 500-507 [PMID: 32657892 DOI: 10.1097/WCO.0000000000000831]
- 18 **Andersen JN**, Sathyanarayanan S, Di Bacco A, Chi A, Zhang T, Chen AH, Dolinski B, Kraus M, Roberts B, Arthur W, Klinghoffer RA, Gargano D, Li L, Feldman I, Lynch B, Rush J, Hendrickson RC, Blume-Jensen P, Paweletz CP. Pathway-based identification of biomarkers for targeted therapeutics: personalized oncology with PI3K pathway inhibitors. *Sci Transl Med* 2010; **2**: 43ra55 [PMID: 20686178 DOI: 10.1126/scitranslmed.3001065]
- 19 **Fogel BL**. Collaborative science unites researchers and a novel spastic ataxia gene. *Ann Neurol* 2018; **83**: 1072-1074 [PMID: 29908061 DOI: 10.1002/ana.25262]
- 20 **Anding AL**, Wang C, Chang TK, Sliter DA, Powers CM, Hofmann K, Youle RJ, Baehrecke EH. Vps13D Encodes a Ubiquitin-Binding Protein that Is Required for the Regulation of Mitochondrial Size and Clearance. *Curr Biol* 2018; **28**: 287-295.e6 [PMID: 29307555 DOI: 10.1016/j.cub.2017.11.064]



Published by **Baishideng Publishing Group Inc**
7041 Koll Center Parkway, Suite 160, Pleasanton, CA 94566, USA
Telephone: +1-925-3991568
E-mail: bpgoffice@wjgnet.com
Help Desk: <https://www.f6publishing.com/helpdesk>
<https://www.wjgnet.com>

