

Current concepts from diagnosis to management in Gorham–Stout disease: a systematic narrative review of about 350 cases

Andrea Angelini, Nicolò Mosele, Elisa Pagliarini and Pietro Ruggieri

Department of Orthopedics and Orthopedic Oncology, University of Padova, Padova, Italy

Correspondence should be addressed to P Ruggieri

Email
pietro.ruggieri@unipd.it

- Patients with Gorham–Stout disease (GSD) present progressive destruction and resorption of bone.
- Typical bone-related symptoms include swelling, pain and functional impairment in the region involved.
- The three aspects of GSD etiopathology are osteoclasts, angiogenesis/lymphangiogenesis and osteoblast function.
- Multi-targeted pharmacological approach includes innovative options and represent milestones of treatment, sometimes associated with radiotherapy.
- Surgery is mainly used to treat complications: pathologic/impending fractures, spinal instability or deformities and chylothorax.
- In this narrative review, we highlight current standards in diagnosis, clinical management and therapeutic strategies.

Keywords

- ▶ phantom bone disease
- ▶ osteolysis
- ▶ differential diagnosis
- ▶ radiotherapy
- ▶ bone tumors
- ▶ treatment
- ▶ diagnosis
- ▶ symptoms
- ▶ surgery

EFORT Open Reviews
(2021) **7**, 35–48

Search strategy

A systematic search of the literature was done to identify studies reporting on patients treated for Gorham–Stout disease (GSD). English and non-English language literature were searched in Pubmed using the terms ‘GSD’, ‘Gorham–Stout’, ‘progressive osteolysis’, ‘phantom bone disease’, ‘disappearing bone’, ‘lymphangiogenesis’, ‘syndrome’, in different combinations and in ISI Web of Knowledge database. The search was done on literature published in the past 70 years (from 1955 to date), resulting in about 270 articles (mainly case reports) describing over 350 cases (Supplementary Table 1 can be found online, see section on [supplementary materials](#) given at the end of this article). The focus of each reference varied including: series of patients with GSD irrespective of locations, case reports and articles investigating specific aspects from preclinic research, imaging, treatment and outcomes.

Historical overview and epidemiology

First described by Jackson in 1838 (1), in a patient with progressive osteolysis of the humerus, GSD takes its name

from LW Gorham and AP Stout who first correlated the massive bone lysis with hemangiomatosis in their report in 1955 (2). GSD, also called phantom bone disease, is a rare syndrome (around 350 cases reported in the literature are summarized in Supplementary Table 1) (2, 3, 4, 5) characterized by massive osteolysis affecting one or more bones and by the substitution with bone lymphatics. This syndrome is considered as the type IV of osteolysis in the classification of Hardegger (6) (Table 1).

GSD does not seem to have any kind of preference for race, sex (although some authors evidenced a male prevalence (7, 8)) or geographic area; the only noteworthy epidemiologic feature is the age. GSD can be diagnosed at any age, but it exhibits a clear preference for a young patient; it affects patients younger than 40 years of age with an average age at diagnosis of 25 years of age (5, 9, 10, 11, 12, 13, 14). This syndrome can affect every skeletal segment, but it is mostly found in the upper part of the body with a slight predilection for the maxillo-facial bones (5). Other frequently involved bones are vertebrae, ribs and the pelvic girdle. In the majority of the reported cases, the disease affects only one bone segment even if multiple bones involvement has been described (13).

Table 1 Classification of 'idiopathic osteolysis' according to Hardegger.

Type 1	Multicentric osteolysis (+ carpotarsal)	Dominant transmission	Infancy	Pain and edema in hands and feet
Type 2	Multicentric osteolysis (+ carpotarsal)	Recessive transmission	Infancy	Generalized osteoporosis
Type 3	Multicentric osteolysis (+carpo-metacarpal)	Non-hereditary	Infancy	Nephropaty
Type 4 (GSD)	Single center osteolysis	Non-hereditary	Aspecific (usually under 40)	Bone lymphatics
Type 5 (WC)	Monocentric osteolysis (+ carpotarsal)	Recessive autosomal	Infancy	Contractures, generalized osteoporosis and short stature

GSD, Gorham–Stout disease; WC, Winchester syndrome.

GSD is a sporadic disease with no definite pattern of genetic inheritance described since now. No cases with a familiar history have been reported. The only mutation reported today is a heterozygous splicing mutation NM_032638.4 (GATA2): c.379C >A described by Oguz *et al* in 2019 in a patient clinically diagnosed with GSD with a severe case of cardiac tamponade and multiple vertebral lytic lesions (15).

Molecular characteristics

Etiopathogenetic mechanisms in GSD are still unclear and uncertain, nevertheless, several hypotheses have been made since the Gorham and Stout article of 1955 (2). There are three fundamental features in GSD etiopathology, which are the role of osteoclasts, angiogenesis/lymphangiogenesis and osteoblast function. About the role of osteoclasts, these cells have been found by some investigators in osteolytic area's biopsies (9, 16, 17, 18, 19, 20, 21, 22, 23, 24, 25, 26) whereas others have not (2, 27, 28, 29, 30). The reason for this discrepancy is unclear. It may be due to evaluations conducted at different phases of the disease (31). Those who have not found osteoclasts argue that osteolysis may be secondary to lymphangiogenesis (the second main feature in GSD). The improvement in number and activity of the osteoclast has been confirmed by Devlin *et al.* in 1996 (32) and by Hirayama *et al.* in 2001 (22). Both of these studies confirm the fundamental role of humoral factors to promote osteoclastogenesis and the survival of osteoclast besides their activity (22, 32). Interleukin -6 (IL-6), macrophage colony-stimulating factor (M-CSF) and Receptor activator of NF- κ B ligand (RANK-L) seem to play an important role in this pathway. Osteoclastogenesis can also be induced in a RANK-L independent way using a combination of TNF α and IL-1 in presence of M-CSF (33). Colucci *et al.* reported that the onset of GSD is secondary to the production of high level of osteoclastogenic and angiogenic molecules from mesenchymal cells belonging to the monocyte lineage and that there is an increased sensitivity of the monocytic cell to osteoclastogenic factors that may lead those cells to differentiate in osteoclasts (34). The increased production of soluble mediators (such as IL-6 and vascular endothelial growth factor A (VEGF-A)) and their altered loops seem to be necessary but not sufficient for the

pathogenesis of GSD (34). Furthermore, an augmented number of macrophage-like cells have been found in GSD lesions (28, 35), which are thought to be the osteoclast's progenitors capable of producing VEGF-A, VEGF-C and VEGF-D (36) that can stimulate osteoclast differentiation and lymphangiogenesis (37, 38, 39, 40). As mentioned above, mononuclear cells in GSD are stimulated to differentiate into osteoclasts, and these osteoclasts are more active on resorbing bone; therefore, they are more motile as motility is fundamental for their activity (41). All these features in differentiation and activity of osteoclasts seem to be correlated with PTEN pathway as it had already been reported in a patient with Hamartoma Tumor Syndrome and Gorham–Stout Phenomenon a germline heterozygous mutation defensin β 113 belongs to a family of innate host defense peptides with pleiotropic activities (42).

Some studies have been conducted recently on the role of VEGF-C in GSD patients. This growth factor, which promotes lymphangiogenesis in embryos and in adult tissue, has been found in higher levels than normal in transgenic mice expressing VEGF-C under the control of osterix promoter causing a phenotype of osteoporosis and bone lymphatics. It is interesting that increased levels of VEGF-C were found only locally, in the site of the bone loss (43). Another etiopathogenetic hypothesis is that the main part is played by lymphangiogenesis. The mechanism under this theory could be the uncontrolled growth of fluid-filled lymphatic vessel that causes osteolysis by mechanically compressing the bone. The secretion of growth factor by lymphatic endothelial cells may influence the activity of osteoclasts and osteoblasts (13). The fundamental role of lymphangiogenesis in GSD is also evidenced by the presence of lymphatic vascular endothelial hyaluronan marker on endothelial GS patient's cells (44) and confirmed from the elevated levels of circulating platelet-derived growth factor-BB (PDGF-BB), a lymphangiogenic cytokine, in affected patients (45). Some studies have also pointed out that lymphatic endothelial cells (LECs) can stimulate osteoclast formation through the expression of M-CSF without any activity on osteoblasts. LEC-produced M-CSF by the way is not able to stimulate osteoclastogenesis on its own but needs more factors to 'help', such as for example, RANK-L (46). Another hypothesis on the proliferation of lymphatic vessels is that there might be a

decrease in the level of an antilymphangiogenic factor such as soluble vascular endothelial growth factor receptors 2 (sVEGFR2) (47), transforming growth factor- β (TGF- β) (48), interferon- γ (IFN- γ) (49), etc. that could promote the uncontrolled growth of lymphatic vessels in the bones of patients with GSD (13).

Besides IL-6, many other serum biomarkers have been highlighted as potentially useful in the diagnosis of GSD, for example sclerostin, which is a biomarker of defective bone regeneration belonging to the β -catenin/Wnt pathway of signaling; collagen type 1 carboxy terminal telopeptide (ICTP), which is also a marker of bone resorption, and the aforementioned VEGF family. All of these potential markers are usually found in increased levels due to the bone resorption activity of the disease (especially ICTP), as well as VEGF-A which is a marker of angiomatous bone proliferation.

The last crucial feature of GSD is the role of osteoblasts. What has been found up to now about osteoclast's role is that they are lacking in activity in GSD not counterbalancing bone resorption. Among the many factors that can influence osteoblast's activity, the increased levels of sclerostin have been found to regulate mineralization and ALP activity. Sclerostin indeed upregulates RANK-L and downregulates osteoprotegerin (OPG) (50, 51) in osteoblast's lineage cells (41).

Orthopedic manifestations

All possible symptoms and clinical manifestations are summarized in Table 2. Orthopedic clinical features in GSD depend on the bone that has been affected. The ribs, spine, pelvis, skull, clavicle and jaw are the most commonly affected bones, although every bone may be potentially involved. Typical symptoms include swelling, pain and functional impairment in the region involved. Pain can arise spontaneously or be caused by pathologic

fractures that can be either atraumatic or following minor trauma. If the disease affects long bones, it can result in bone deformity and limb shortening. If it affects the lower limbs, walking and weight-bearing may become difficult and often the use of crutches is required. Upper limb involvement is less debilitating as the patient can walk normally, but all the movements are impaired and painful. Hand involvement is rarely reported (24, 52, 53) compared to the other cases of spontaneous osteolysis classified by Hardegger. Some patients may experience a dull pain or generalized weakness that increases over time. Life-threatening complications can arise if the lesion involves vertebrae; neurological complications may be present due to the spinal cord involvement, which can lead to paraplegia or to major neurological deficits (54, 55). Vertebral involvement can be either unifocal or multifocal. All spinal segments can be affected with different symptoms based on the segment involved.

Other symptoms and visceral involvement

Cerebro-spinal fluid (CSF) leakage is another severe complication that may arise if the lesion is located in the cranial bones, especially the skull base, or in the spine, and can be caused by the formation of a fistula. CSF leakage can cause symptoms like headache, vomiting, nausea and cranial hypotension and may require surgical repair (56, 57). Temporal bones and skull base seem to be the most involved cranial bones, apart from the maxilla and mandibula. CSF leak may decrease its pressure causing cerebral hypotension and, in some cases, have led to Chiari I malformation. This malformation can occur in GSD also following occiput deformities or following intracranial hypertension originated from the lymphatic flow in the CSF space following lymphatic anomalies (58, 59, 60, 61, 62, 63). Other complications in temporal or petrous bones may be hearing problems such as hearing loss (64, 65), tinnitus and egophony (66) or there may be sight problem (67). Temporomandibular joint is frequently involved causing face deformities and impairment in mouth opening. In 2019, Chrcanovic *et al.* conducted a study reviewing all the GSD involving face bone (in particular jaws) and he found 89 cases in 86 studies (68).

Chest involvement may lead to pleural effusion and chylothorax (64) if the lymphangiogenic effusion involves the pleural cavity or the thoracic duct. Chylothorax is an abnormal accumulation of chyle in the space between the lungs and chest cavity. Chylothorax has been reported to be the consequence of a duro-pleural fistula in a patient, and obviously, the symptoms were related to the duration and the acuity of the fistula formation (69). Cytological and biochemical examinations are mandatory and have always revealed the presence of exudate with a moderate

Table 2 Clinical manifestations and symptoms of Gorham–Stout disease.

Orthopedic	<ul style="list-style-type: none"> - Pain - Swelling - Pathologic fractures - Absence of bone/soft tissue consistency - Bone deformities, kyphosis
Neurologic	<ul style="list-style-type: none"> - Paraplegia - Cerebrospinal fluid leakage (rhinorrhea, otorrhea, headache, migraine, nausea, vomiting) - Hearing problems
Temporo-mandibular joint	<ul style="list-style-type: none"> - Tinnitus - Egophony - Loose teeth - Facial deformity
Thorax	<ul style="list-style-type: none"> - Pleural or pericardial effusion - Mediastinal mass - Chylothorax - Dyspnea - Respiratory failure
Cutaneous	<ul style="list-style-type: none"> - Lymphangiogenic malformations

predominance of lymphocytes (70). Chylothorax is a quite common severe complication of this disease (25%) (13) and it can cause respiratory failure and consequently, death. Patients affected by chylothorax have been seen to have, generally, a worse outcome since this effusion may be relapsing and it may require frequent thoracentesis. Fatal outcome has been reported around 43.6% in patients with chylothorax, which is significantly more than in patients without it.

Lymphatic malformation affecting the mediastinum may lead to pericardial effusion or to the formation of a mediastinal mass. These findings are often associated with other lymphatic diffuse anomalies such as chylothorax (since the establishment mechanism is the same), lymphatic flow into the pericardial area or involvement of thoracic duct. However, these are rare findings in GSD (less than 10 cases reported in the literature), but they can be life-threatening (56, 71, 72, 73, 74, 75, 76, 77, 78).

Cutaneous malformations are other clinical features observed in GSD. Several authors have mentioned these lesions in their patients, but no one specifically focuses attention on this aspect. Bruch Geharz *et al* in 2007 reported that in only five cases (16, 65, 79, 80, 81) out of the many described at that time were expressly reported cutaneous malformations, hypothesizing a possible role in anticipating diagnostic process. Since then, to the best of our knowledge, eight more cases of skin involvement have been reported in the literature with different manifestation going from verrucous lesions (82) to lymphangiogenic malformation with endothelial proliferation in dermis causing dark plaque, sometimes with cutaneous fistula formation (23).

Another organ often involved in lymphatic anomalies related to GSD is the spleen. In fact, many cases of asymptomatic splenic cyst have been reported in the literature. We did not consider this as a true complication of GSD since it is usually asymptomatic, but it can be taken into account in the diagnostic process (78).

GSD in childhood and adolescence

Gorham–Stout disease, as aforementioned, mainly affects children and young adults, with an average age at the diagnosis of 25 years old. More than half of the cases reported in the Supplementary Table 1 have been diagnosed under the age of 18. In particular, as far as we know from our systematic review, 80 cases have been diagnosed under the age of 10 and 79 more cases have been diagnosed between 11 and 18 years old. Clinical manifestations do not differ from the classical clinical picture. In children, the involvement of growing bones may appear serious, even if young children have more possibility to have a good outcome due to their plasticity (75, 83). Complication rates

are comparable to the older population. In particular, we observed 40 cases of major complications in the first group (0–10 years old) and 38 major complications in the second one (10–18 years old). The most frequent are pleural effusion and chylothorax with 25 cases in the younger group and 29 cases in the older one. Unfortunately, 20 patients had fatal outcome; all of them had developed chylothorax during the course of the disease except for 3 patients. Of those 3 patients, one died of cervical spine compression, one died aged 65 years of severe depression and food refusal (84) and one died of septic shock (85).

Imaging

Radiological findings are essential for diagnosis, even if there are no specific imaging that definitively diagnose GSD, which is partly a diagnosis of exclusion.

Radiographs

Plain X-ray features depend on the stage of the lesion: initially X-rays show subcortical and intramedullary radiolucent foci (Fig. 1), but in a later stage of the disease, the classic pattern of osteolysis without osteosclerosis or periosteal reaction becomes evident and may appear as pathological fractures. Additionally, tubular bones undergo concentric shrinkage with a so-called ‘sucked candy’ appearance. These aspects usually lead to second-level exams such as CT scan or MRI (Fig. 2).

Computed tomography

The findings may be variable, but bone loss and its dissolution are usually observed (Fig. 3). CT scans can also be useful in showing the extent of soft tissue involvement. Vessel-shaped defects at the edge of osteolysis are sometimes observed.

Magnetic resonance images

The lesion appears hypointense in T1-weighted and hyperintense at T2-weighted MRI (86, 87). The osteolytic pattern is also confirmed on second-level examination and, especially if contrast is used, a soft mass substituting the reabsorbed bone with a reticular pattern may be observed. MRI can clearly show the vascular and/or lymphatic vessels within the bone, with contrast enhancement at the region of active osteolysis.

Bone scintigraphy

Bone scintigraphy mostly shows increased uptake in the areas with increased lymphatic and vascular proliferation and a decreased uptake at the osteolytic region of vanished bone. In 2009, Kobayashi *et al* evaluated for the first time the extension and the activity of the GSD using

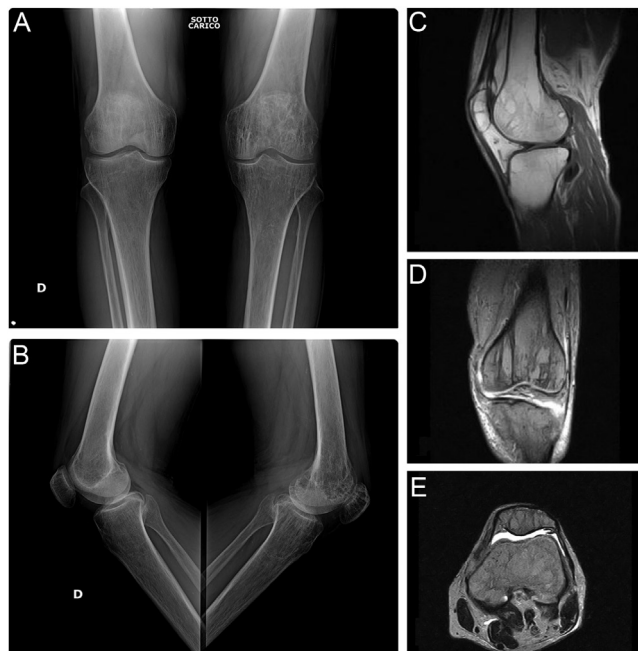


Figure 1
First stage of GSD characterized by ‘patchy’ intramedullary and subcortical lucencies resembling osteoporosis. Typical imaging appearance with (A) frontal and (B) lateral radiograph of both knee and (C) sagittal, (D) coronal and (E) axial MR images.

99 mTc(V)-DMSA scintigraphy (88). Some years later, in 2015, Alves *et al* confirmed the usefulness of total body 99 mTc(V)-DMSA SPECT-CT in evaluating the activity, extension and multifocality of the disease (89).

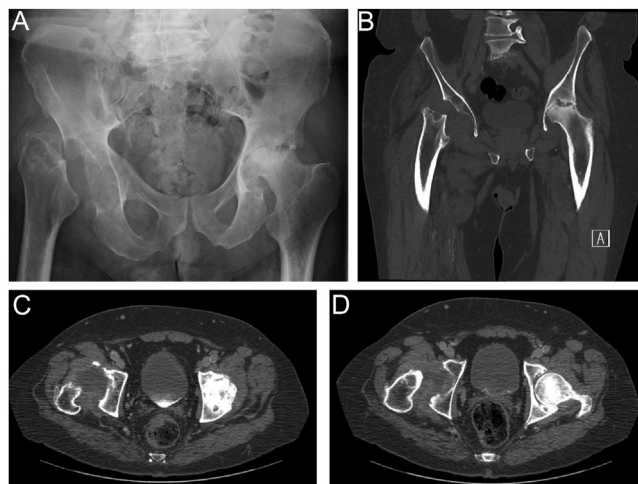


Figure 2
59 years old male with progressive osteolysis of right hip and osteonecrosis of proximal left hip. (A) X-ray, (B) coronal and (C and D) axial CT scan show the final stage of GSD with complete resorption of bone replaced by fibrous tissue.

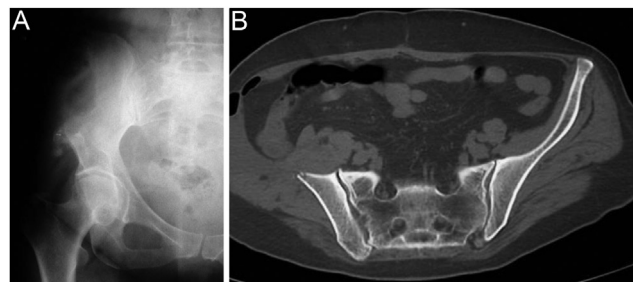


Figure 3
Gorham–Stout disease. (A) Plain radiographs and (B) CT scan of the pelvis show the classic pattern of osteolysis without osteosclerosis or periosteal reaction.

PET/CT

Different types of agents have been used in PET/CT, and specifically, ¹⁸F-NaF has shown higher specificity and sensibility in identifying osteolytic foci when compared to ¹⁸F-FDG. In fact, in GSD, there is no higher metabolic activity and ¹⁸F-NaF is a bone-specific marker reflecting blood flow by being deposited on the surface of the hydroxyapatite matrix-forming fluorapatite (90).

Differential diagnosis

A diagnosis of GSD may be quite difficult and requires the exclusion of all the other potential causes of osteolysis such as cancer, infection, inflammation and hereditary diseases. The main disorders that have been reported in the differential diagnosis are lymphangiomatosis, multiple myeloma, lytic metastasis from an unknown primary tumor, Hajdu–Cheney syndrome, Paget’s disease, rheumatoid arthritis, fibrous dysplasia, Langerhans cell histiocytosis, Winchester syndrome (type V of Hardegger classification), carpal tarsal osteolysis (type I–III of Hardegger classification), idiopathic multicentric osteolysis, multicentric osteolysis with nephropathy and eosinophilic granulomatosis. Blood tests are almost completely negative and are neither helpful for diagnosis nor for follow-up of the disease as there are no specific markers except for alkaline phosphatase (which may be slightly elevated) (14). Heffez *et al* proposed eight criteria that can be used for the diagnosis of GSD: (i) positive biopsy (angiomatous tissue with abnormal lymphatic channels and numerous osteoclasts – Fig. 4); (ii) absence of cellular atypia; (iii) minimal or no osteoblastic response and absence of dystrophic calcifications; (iv) evidence of local progressive bone resorption; (v) non-expansive, non-ulcerative lesion; (vi) absence of visceral involvement; (vii) osteolytic radiographic pattern and (viii) negative hereditary, metabolic, neoplastic, immunologic and infectious etiology (31).

Radiotherapy and medical treatments

Many treatments have been proposed since the first description of this disease. The results of the accurate systematic review of the literature were summarized in a diagnostic and treatment algorithm (Fig. 5).

Radiotherapy and medical treatments play a very important role in the management of the disease, and many pharmacological approaches have been tried during the past years. Moderate doses of radiotherapy have been often administered to treat this disease. Commonly, the total dose of radiation ranges between 30.6 and 45 Gy in 1.8/2 Gy fractions (8, 91, 92, 93, 94, 95, 96, 97, 98, 99, 100, 101, 102, 103). Radiotherapy can be used in association with surgery, pre- or post-operatively, to reduce the size of the lesion, stopping the angiogenesis and consequently the progression of osteolysis. Results are quite convincing: in 1993, Dunbar *et al* reviewed the literature confirming the successful effect of radiation therapy in achieving good clinical results if administered with aforementioned posology (30–40 Gy in 2 Gy

fractions) (91). In 2011, Heyd *et al* published another review (up to 2009) with ten additional cases, confirming local control of the disease in 77.2% of the cases in the literature and in eight out of ten patients in their series (92). To the best of our knowledge, since the last literature review, nearly 22 further patients have been treated with radiation therapy, and in most of the cases, a stop of the angiogenesis has been achieved (8, 93, 94, 95, 96, 97, 98, 99, 100, 101, 102, 103). Concerns about the use of radiotherapy are later adverse effects including secondary malignancy and all the other complications related to its use (104), although only one case of radiation-induced sarcoma has been reported (105).

Another option to treat GSD is the pharmacological approach which can either be monotherapeutic or multi-targeted. Monotherapeutic approach has initially been tried with usually poor results. Therefore, the use of different drugs is preferred with more encouraging results. Many pharmacological approaches have been tried during the past years. Some of them have been used since the first case and are still used nowadays like bisphosphonates, vitamin D, calcium, corticosteroids and interferon α -2b. Other drugs such as octreotide, bevacizumab, propranolol, cyclophosphamide, vincristine, sunitinib, taxol, hydroxychloroquine, acetazolamide, calcitonin and bevacizumab have been used in patients unresponsive to the conventional 'first line treatments', but they did not lead to great results. Recently (2016), sirolimus (also known by the name of rapamicine) has been used with encouraging results and has never been abandoned since then. Sirolimus is an antibiotic belonging to the class of macrolides, which works as an immunosuppressant by inhibiting both cell proliferation and angiogenesis. Its action is to block IL-2 signaling pathway by inhibiting mTOR (mammalian target of rapamicine), a serine/threonine protein kinase that stimulates cell growth and angiogenesis. In 2016, Triana *et al.* reported a large study on the use of sirolimus on various vascular anomalies: Authors observed an overall successful response in 33 out of 41 patients (80.4%) and specifically 6/7 of the patients affected by GSD responded well (106). Since its first use, sirolimus has been used many other times with good results; in some cases, a decrease of more than a half of the size of the lesion has been observed (107, 108, 109, 110, 111).

Since the first report by Lagberg in 1997, another widely used pharmaceuticals are bisphosphonates. These drugs have anti-osteolytic activity inhibiting osteoclast-mediated bone resorption but does not promote the stop of angiogenesis or bone formation. This supports their association with RT or with interferon- α (Ifn- α) to stop angiogenesis, or with calcium or cholecalciferol to promote bone formation. Many different types of bisphosphonates have been used in the treatment of GSD. Zoledronic acid has been widely used by many authors and has been

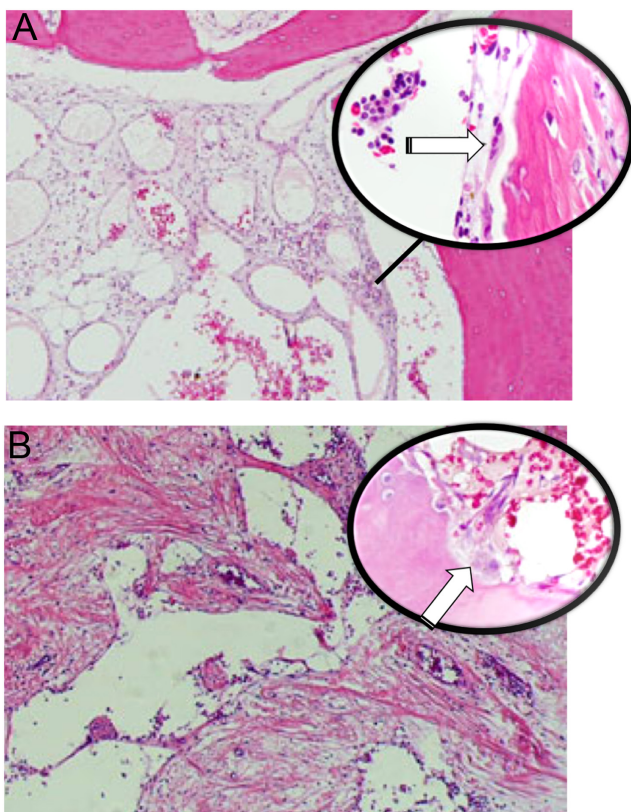


Figure 4
Gorham–Stout disease. (A) Enlarged abnormal lymphatic channels vary in size with numerous osteoclasts (white arrow in higher magnification), (B) dilated vessels with thin walls, loss of cortex and bone trabeculae surrounded by fibrous tissue. Active osteoclasts (white arrow) are present.

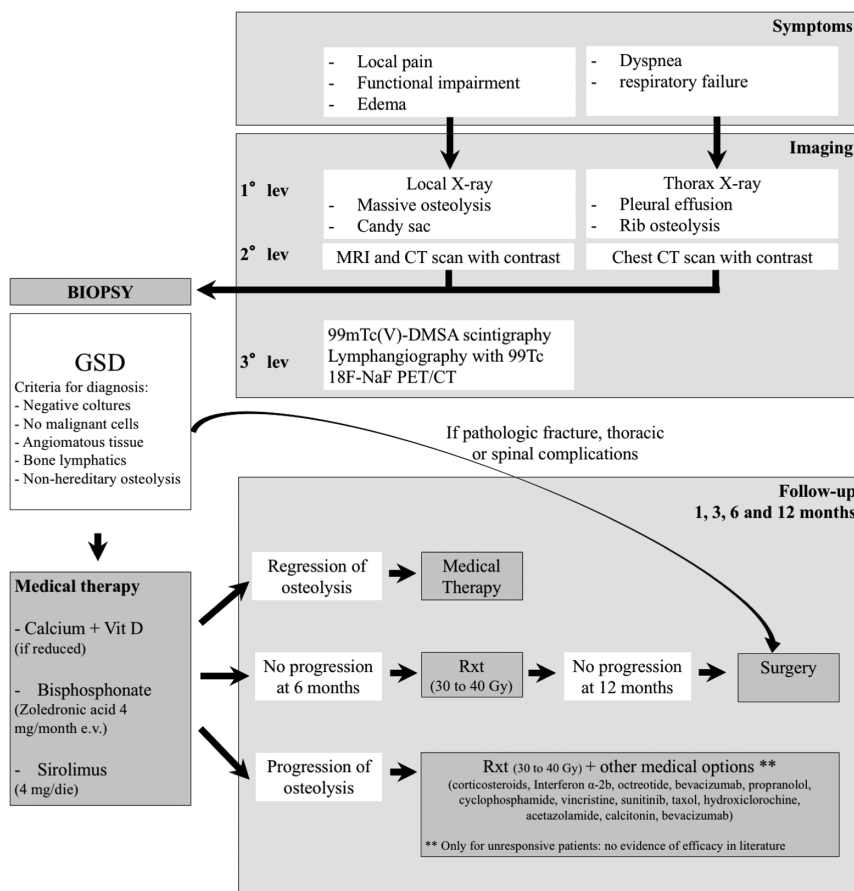


Figure 5
Diagnostic and treatment algorithm for Gorham–Stout disease.

administered intravenously with a dose of 4 mg/month. Clodronate, pamidronate and etidronate have been used as a monotherapy (7, 8, 21, 97, 109, 112, 113, 114, 115, 116), but more often, they have been administered in combination with other therapies such as RT (3, 23, 92, 97, 99, 100), lfn- α (65, 93, 117, 118, 119, 120, 121, 122, 123), calcium and/or Vit D (19, 124, 125, 126, 127). A triple approach using a combination of bisphosphonates with RT and lfn- α has also been reported (95, 98).

Interferon α -2b (lfn-a2b) is another pharmacological approach used in GSD for its anti-angiogenic effect aimed at reducing angiogenesis-cased osteolysis. This drug has been commonly used for different types of leukemia and other tumors such as Kaposi sarcoma or as an adjuvant in melanoma. The first results date back to 1997 (117) when interferon α -2b had been used for the first time to treat GSD in a patient who had previously undergone radiotherapy and simultaneously clodronate therapy. However, it was not clear whether the regression in the symptoms was due to the action of clodronate or lfn-a2b. The first satisfying results attributable to the lfn-a2b therapy are reported in a study in 2005 (128) on a 2 year old patient with multicentric osteolysis previously treated with local injection of ok-432 (lyophilized incubation mixture of group A *Streptococcus pyogenes* of human

origin) and simultaneously treated with steroids pulse therapy, which was reported to be only partially effective. After the administration of lfn-a2b (1.5 MU daily then reduced to 1.5 MU weekly), she had complete remission of the symptoms and almost total disappearance of the lesions. lfn-a2b has been used many other times since then, usually combined with other treatments such as RT (94, 98, 129) or bisphosphonates (65, 93, 117, 118, 119, 120, 121, 122, 123). Rarely, has it been tried as a monotherapeutic approach with lfn-a2b but with variable results. In one case (65), the therapy was stopped and switched with sirolimus due to adverse reactions (fever, mild depression, fatigue); whilst, in another case, it was administered in monotherapy with good results (reduction in the size of the lesion and symptoms relief) (130).

Beta-blocking agent propranolol has been used only in few cases of GSD, with the rationale of downregulating the Raf mitogen-activated protein kinase signaling pathway lowering the expression of VEGF-A (81, 102, 111, 131, 132). However, more evidence has been found on the role of propranolol in lymphangiomatosis and in hemangiomatosis especially in young patients showing good effectiveness in reducing the size of the tumor (19, 110, 111, 112, 113, 114, 115, 116, 117, 118, 119, 120, 121, 122, 123, 124, 125, 126, 127, 128, 129, 130, 131, 132, 133, 134, 135, 136).

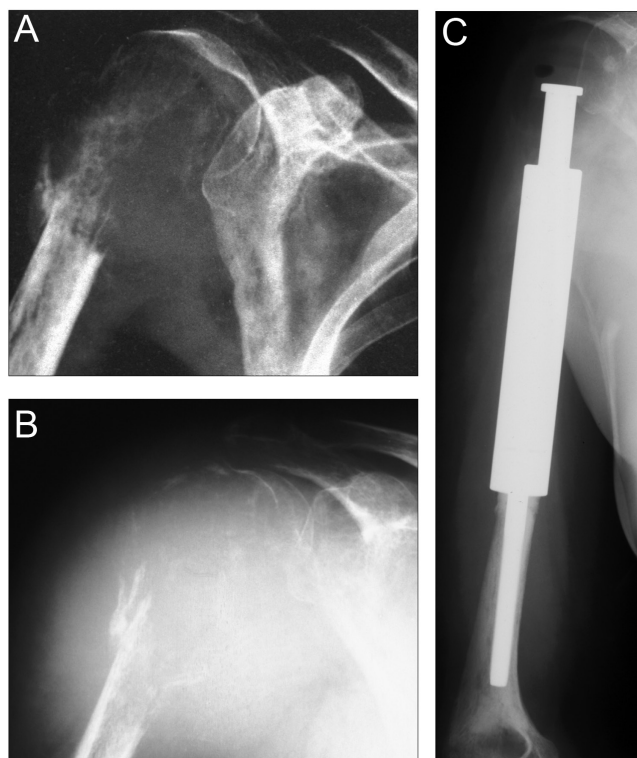


Figure 6

(A) Pathologic fracture of the proximal humerus with extensive osteolysis. A biopsy confirmed the diagnosis of Gorham–Stout disease. (B) Repeated plain x-ray AP view after 3 months reveals progressive resorption of bone despite medical treatment. (C) Resection and reconstruction with conventional modular mega prosthesis have been performed.

Surgical treatment

In GSD, surgery is mainly used to treat complications. The orthopedic surgeon is involved in case of pathological fracture, impending fracture or when the patient complains about impaired function, reduced mobility or hard pain. Surgical treatments have been used to reduce the size of the osseous lesion, to fill the affected area (137) or to completely remove the bone segment (91, 138) with consequent reconstruction with prostheses or bone grafts (3, 26, 93, 124, 139, 140, 141) (Fig. 6). Bone grafts are usually resorbed and vanish in phases of activity of the GSD (142). The longest surviving rate in bone grafts has been achieved using cortical homologous bone graft, which has lasted more than 20 years, according to a case–control study conducted by Turra *et al.* (143). Spinal lesions can also be managed surgically if the lesion leads to spinal instability, deformity or pain. Posterior spinal stabilization with screws and rods associated with decompression, or anterior stabilization with plate and screws to induce vertebral fusion, can be used in the most severe cases of cervical and thoracic deformities (101, 115, 117, 144, 145,

146, 147, 148, 149). The use of vertebroplasty has to be considered when the spine is involved, but the osteolytic lesion does not lead to severe deformity or to major instability (98, 137). In spinal surgery, bone grafts are often used (114, 144, 150).

Surgery also plays a key role in thoracic complications, such as chylothorax or even minor pleural fluid leakage, which have been treated with pleural drainage (119, 149, 151, 152), pleurectomy, pleurodesis (64, 153, 154) and/or thoracic duct ligation or embolization (14, 27, 65, 155). In most of the cases, the best outcome has been obtained by combining these surgical techniques rather than using them in isolation (154, 156).

Conclusions

Gorham–Stout disease is an extremely rare bone disease characterized by progressive osteolysis with lymphatic and vascular proliferation. Diagnosis is challenging; once the GSD is suspected, the patient should be referred to a specialized center in musculoskeletal oncology or rare bone disease. Treatments and care are usually directed toward the specific symptoms and should require a multidisciplinary team approach with a long-term follow-up. Multimodal medical therapy with/without radiotherapy might be helpful in arresting bone lesion progression of GSD. Surgery has a role in stabilizing the disease or in the presence of complications (such as pathologic fracture, chylothorax or spinal complications). Chylothorax during the course of the disease represents the worst prognostic factor for survival.

Supplementary materials

This is linked to the online version of the paper at <https://doi.org/10.1530/EOR-21-0083>.

ICMJE Conflict of Interest Statement

P R reports receiving royalties and consultancy fees for Stryker and Exactech are not related to the research reported here. The other authors have nothing to disclose.

Funding Statement

This work did not receive any specific grant from any funding agency in the public, commercial, or not-for-profit sector.

References

1. Jackson J. A boneless arm. *Boston Medical and Surgical Journal* 1838 **18** 398–399.
2. Gorham LW & Stout AP. Massive osteolysis (acute spontaneous absorption of bone, phantom bone, disappearing bone); its relation to hemangiomas. *Journal of Bone and Joint Surgery: American Volume* 2004 **37-A** 985–1004.
3. Ellati R, Attili A, Haddad H, Al-Hussaini M & Shehadeh A. Novel approach of treating Gorham–Stout disease in the humerus – case report and review of literature. *European Review for Medical and Pharmacological Sciences* 2016 **20** 426–432.

- 4. Ganau M, Prasad V, Ligarotti GKI, Syrmos NC & Ellamushi H.** An overview of the neurosurgical implications, pathophysiology, diagnosis and recent treatment strategies for grade IV idiopathic osteolysis, also known as Gorham–Stout or phantom bone disease. *Hellenic Journal of Nuclear Medicine* 2018 **21** 198–201. (<https://doi.org/10.1967/s002449910905>)
- 5. Nikolaou VS, Chytas D, Korres D & Efstathopoulos N.** Vanishing bone disease (Gorham–Stout syndrome): a review of a rare entity. *World Journal of Orthopedics* 2014 **5** 694–698. (<https://doi.org/10.5312/wjo.v5.i5.694>)
- 6. Hardegger F, Simpson LA & Segmueller G.** The syndrome of idiopathic osteolysis. Classification, review, and case report. *Journal of Bone and Joint Surgery: British Volume* 1985 **67** 88–93. (<https://doi.org/10.1302/0301-620X.67B1.3968152>)
- 7. de Keyser CE, Saltzherr MS, Bos EM & Zillikens MC.** A large skull defect due to Gorham–Stout disease: case report and literature review on pathogenesis, diagnosis, and treatment. *Frontiers in Endocrinology* 2020 **11** 37. (<https://doi.org/10.3389/fendo.2020.00037>)
- 8. Hu P, Yuan XG, Hu XY, Shen FR & Wang JA.** Gorham–Stout syndrome in mainland China: a case series of 67 patients and review of the literature. *Journal of Zhejiang University: Science B* 2013 **14** 729–735. (<https://doi.org/10.1631/jzus.B1200308>)
- 9. Möller G, Priemel M, Amling M, Werner M, Kuhlmeier AS & Delling G.** The Gorham–Stout syndrome (Gorham’s massive osteolysis). A report of six cases with histopathological findings. *Journal of Bone and Joint Surgery: British Volume* 1999 **81** 501–506. (<https://doi.org/10.1302/0301-620X.81B3.9468>)
- 10. Boyer P, Bourgeois P, Boyer O, Catonné Y & Saillant G.** Massive Gorham–Stout syndrome of the pelvis. *Clinical Rheumatology* 2005 **24** 551–555. (<https://doi.org/10.1007/s10067-005-1088-7>)
- 11. Lee S, Finn L, Sze RW, Perkins JA & Sie KC.** Gorham Stout syndrome (disappearing bone disease): two additional case reports and a review of the literature. *Archives of Otolaryngology: Head and Neck Surgery* 2003 **129** 1340–1343. (<https://doi.org/10.1001/archotol.129.12.1340>)
- 12. Mendez AA, Keret D, Robertson W & MacEwen GD.** Massive osteolysis of the femur (Gorham’s disease): a case report and review of the literature. *Journal of Pediatric Orthopedics* 1989 **9** 604–608. (<https://doi.org/10.1097/01241398-198909010-00019>)
- 13. Dellinger MT, Garg N & Olsen BR.** Viewpoints on vessels and vanishing bones in Gorham–Stout disease. *Bone* 2014 **63** 47–52. (<https://doi.org/10.1016/j.bone.2014.02.011>)
- 14. Patel DV.** Gorham’s disease or massive osteolysis. *Clinical Medicine and Research* 2005 **3** 65–74. (<https://doi.org/10.3121/cm.3.2.65>)
- 15. Oguz MM, Oguz B, Dogan V, Aydin B, Eyuboglu TS, Yesil S, Ceylaner S & Senel S.** Cardiac tamponade in Gorham–Stout syndrome associated with GATA2 mutation. *Indian Journal of Pediatrics* 2020 **87** 239–240. (<https://doi.org/10.1007/s12098-019-03174-1>)
- 16. Jones GB, Midgley RL & Smith GS.** Massive osteolysis: disappearing bones. *Journal of Bone and Joint Surgery: British Volume* 1958 **40-B** 494–501. (<https://doi.org/10.1302/0301-620X.40B3.494>)
- 17. Pazzaglia UE, Andriani L, Bonato M & Leutner M.** Pathology of disappearing bone disease: a case report with immunohistochemical study. *International Orthopaedics* 1997 **21** 303–307. (<https://doi.org/10.1007/s002640050173>)
- 18. Bruder E, Perez-Atayde AR, Jundt G, Alomari AI, Rischewski J, Fishman SJ, Mulliken JB & Kozakewich HP.** Vascular lesions of bone in children, adolescents, and young adults. A clinicopathologic reappraisal and application of the ISSVA classification. *Virchows Archiv* 2009 **454** 161–179. (<https://doi.org/10.1007/s00428-008-0709-3>)
- 19. Avelar RL, Martins VB, Antunes AA, de Oliveira Neto PJ & Andrade ES.** Use of zoledronic acid in the treatment of Gorham’s disease. *International Journal of Pediatric Otorhinolaryngology* 2010 **74** 319–322. (<https://doi.org/10.1016/j.ijporl.2009.12.007>)
- 20. Choma ND, Biscotti CV, Bauer TW, Mehta AC & Licata AA.** Gorham’s syndrome: a case report and review of the literature. *American Journal of Medicine* 1987 **83** 1151–1156. ([https://doi.org/10.1016/0002-9343\(87\)90959-4](https://doi.org/10.1016/0002-9343(87)90959-4))
- 21. Hammer F, Kenn W, Wesselmann U, Hofbauer LC, Delling G, Alolio B & Arlt W.** Gorham–Stout disease – stabilization during bisphosphonate treatment. *Journal of Bone and Mineral Research* 2005 **20** 350–353. (<https://doi.org/10.1359/JBMR.041113>)
- 22. Hirayama T, Sabokbar A, Itonaga I, Watt-Smith S & Athanasou NA.** Cellular and humoral mechanisms of osteoclast formation and bone resorption in Gorham–Stout disease. *Journal of Pathology* 2001 **195** 624–630. (<https://doi.org/10.1002/path.989>)
- 23. Lehmann G, Pfeil A, Böttcher J, Kaiser WA, Füller J, Hein G & Wolf G.** Benefit of a 17-year long-term bisphosphonate therapy in a patient with Gorham–Stout syndrome. *Archives of Orthopaedic and Trauma Surgery* 2009 **129** 967–972. (<https://doi.org/10.1007/s00402-008-0742-3>)
- 24. Silva S.** Gorham–Stout disease affecting both hands: stabilisation during bisphosphonate treatment. *Hand* 2011 **6** 85–89. (<https://doi.org/10.1007/s11552-010-9292-6>)
- 25. Spieth ME, Greenspan A, Forrester DM, Ansari AN, Kimura RL & Gleason-Jordan I.** Gorham’s disease of the radius: radiographic, scintigraphic, and MRI findings with pathologic correlation. A case report and review of the literature. *Skeletal Radiology* 1997 **26** 659–663. (<https://doi.org/10.1007/s002560050306>)
- 26. Poirier H.** Massive osteolysis of the humerus treated by resection and prosthetic replacement. *Journal of Bone and Joint Surgery: British Volume* 1968 **50** 158–160.
- 27. Fujii K, Kanno R, Suzuki H, Nakamura N & Gotoh M.** Chylothorax associated with massive osteolysis (Gorham’s syndrome). *Annals of Thoracic Surgery* 2002 **73** 1956–1957. ([https://doi.org/10.1016/s0003-4975\(02\)03413-6](https://doi.org/10.1016/s0003-4975(02)03413-6))
- 28. Heyden G, Kindblom LG & Nielsen JM.** Disappearing bone disease. A clinical and histological study. *Journal of Bone and Joint Surgery: American Volume* 1977 **59** 57–61. (<https://doi.org/10.2106/00004623-197759010-00009>)
- 29. Ross JL, Schinella R & Shenkman L.** Massive osteolysis. An unusual cause of bone destruction. *American Journal of Medicine* 1978 **65** 367–372. ([https://doi.org/10.1016/0002-9343\(78\)90834-3](https://doi.org/10.1016/0002-9343(78)90834-3))
- 30. Tauro B.** Multicentric Gorham’s disease. *Journal of Bone and Joint Surgery: British Volume* 1992 **74** 928–929. (<https://doi.org/10.1302/0301-620X.74B6.1447260>)
- 31. Heffez L, Doku HC, Carter BL & Feeney JE.** Perspectives on massive osteolysis. Report of a case and review of the literature. *Oral Surgery, Oral Medicine, and Oral Pathology* 1983 **55** 331–343. ([https://doi.org/10.1016/0030-4220\(83\)90185-8](https://doi.org/10.1016/0030-4220(83)90185-8))
- 32. Devlin RD, Bone HG 3rd & Roodman GD.** Interleukin-6: a potential mediator of the massive osteolysis in patients with Gorham–Stout disease. *Journal of Clinical Endocrinology and Metabolism* 1996 **81** 1893–1897. (<https://doi.org/10.1210/jcem.81.5.8626854>)
- 33. Kobayashi K, Takahashi N, Jimi E, Udagawa N, Takami M, Kotake S, Nakagawa N, Kinosaki M, Yamaguchi K, Shima N, et al.** Tumor necrosis factor alpha stimulates osteoclast differentiation by a mechanism independent of the ODF/RANKL-RANK interaction. *Journal of Experimental Medicine* 2000 **191** 275–286. (<https://doi.org/10.1084/jem.191.2.275>)
- 34. Colucci S, Tarabozetti G, Primo L, Viale A, Roca C, Valdembrì D, Geuna M, Pagano M, Grano M, Pogrel AM, et al.** Gorham–Stout syndrome: a monocyte-mediated cytokine propelled disease. *Journal of Bone and Mineral Research* 2006 **21** 207–218. (<https://doi.org/10.1359/JBMR.051019>)

- 35. Dickson GR, Hamilton A, Hayes D, Carr KE, Davis R & Mollan RA.** An investigation of vanishing bone disease. *Bone* 1990 **11** 205–210. ([https://doi.org/10.1016/8756-3282\(90\)90215-k](https://doi.org/10.1016/8756-3282(90)90215-k))
- 36. Granata F, Frattini A, Loffredo S, Staiano RI, Petraroli A, Ribatti D, Oslund R, Gelb MH, Lambeau G, Marone G, et al.** Production of vascular endothelial growth factors from human lung macrophages induced by group IIA and group X secreted phospholipases A2. *Journal of Immunology* 2010 **184** 5232–5241. (<https://doi.org/10.4049/jimmunol.0902501>)
- 37. Motokawa M, Tsuka N, Kaku M, Kawata T, Fujita T, Ohtani J, Matsuda Y, Terao A & Tanne K.** Effects of vascular endothelial growth factor-C and -D on osteoclast differentiation and function in human peripheral blood mononuclear cells. *Archives of Oral Biology* 2013 **58** 35–41. (<https://doi.org/10.1016/j.archoralbio.2012.06.010>)
- 38. Niida S, Kaku M, Amano H, Yoshida H, Kataoka H, Nishikawa S, Tanne K, Maeda N, Nishikawa S & Kodama H.** Vascular endothelial growth factor can substitute for macrophage colony-stimulating factor in the support of osteoclastic bone resorption. *Journal of Experimental Medicine* 1999 **190** 293–298. (<https://doi.org/10.1084/jem.190.2.293>)
- 39. Niida S, Kondo T, Hiratsuka S, Hayashi S, Amizuka N, Noda T, Ikeda K & Shibuya M.** VEGF receptor 1 signaling is essential for osteoclast development and bone marrow formation in colony-stimulating factor 1-deficient mice. *PNAS* 2005 **102** 14016–14021. (<https://doi.org/10.1073/pnas.0503544102>)
- 40. Zhang Q, Guo R, Lu Y, Zhao L, Zhou Q, Schwarz EM, Huang J, Chen D, Jin ZG, Boyce BF, et al.** VEGF-C, a lymphatic growth factor, is a RANKL target gene in osteoclasts that enhances osteoclastic bone resorption through an autocrine mechanism. *Journal of Biological Chemistry* 2008 **283** 13491–13499. (<https://doi.org/10.1074/jbc.M708055200>)
- 41. Rossi M, Buonomo PS, Battafarano G, Conforti A, Mariani E, Algeri M, Pelle S, D'Agostini M, Macchiaiolo M, De Vito R, et al.** Dissecting the mechanisms of bone loss in Gorham-Stout disease. *Bone* 2020 **130** 115068. (<https://doi.org/10.1016/j.bone.2019.115068>)
- 42. Hopman SM, Van Rijn RR, Eng C, Bras J, Alders M, van der Horst CM, Hennekam RC & Merks JH.** PTEN hamartoma tumor syndrome and Gorham-Stout phenomenon. *American Journal of Medical Genetics: Part A* 2012 **158A** 1719–1723. (<https://doi.org/10.1002/ajmg.a.35406>)
- 43. Hominick D, Silva A, Khurana N, Liu Y, Dechow PC, Feng JQ, Pytowski B, Rutkowski JM, Alitalo K & Dellinger MT.** VEGF-C promotes the development of lymphatics in bone and bone loss. *eLife* 2018 **7** e34323. (<https://doi.org/10.7554/eLife.34323>)
- 44. Hagendoorn J, Padera TP, Yock TI, Nielsen GP, di Tomaso E, Duda DG, Delaney TF, Gaissert HA, Pearce J, Rosenberg AE, et al.** Platelet-derived growth factor receptor-beta in Gorham's disease. *Nature Clinical Practice: Oncology* 2006 **3** 693–697. (<https://doi.org/10.1038/ncon0660>)
- 45. Radhakrishnan K & Rockson SG.** Gorham's disease: an osseous disease of lymphangiogenesis? *Annals of the New York Academy of Sciences* 2008 **1131** 203–205. (<https://doi.org/10.1196/annals.1413.022>)
- 46. Wang W, Wang H, Zhou X, Li X, Sun W, Dellinger M, Boyce BF & Xing L.** Lymphatic endothelial cells produce M-CSF, causing massive bone loss in mice. *Journal of Bone and Mineral Research* 2017 **32** 939–950. (<https://doi.org/10.1002/jbmr.3077>)
- 47. Albuquerque RJ, Hayashi T, Cho WG, Kleinman ME, Dridi S, Takeda A, Baffi JZ, Yamada K, Kaneko H, Green MG, et al.** Alternatively spliced vascular endothelial growth factor receptor-2 is an essential endogenous inhibitor of lymphatic vessel growth. *Nature Medicine* 2009 **15** 1023–1030. (<https://doi.org/10.1038/nm.2018>)
- 48. Oka M, Iwata C, Suzuki HI, Kiyono K, Morishita Y, Watabe T, Komuro A, Kano MR & Miyazono K.** Inhibition of endogenous TGF-beta signaling enhances lymphangiogenesis. *Blood* 2008 **111** 4571–4579. (<https://doi.org/10.1182/blood-2007-10-120337>)
- 49. Shao X & Liu C.** Influence of IFN-alpha and IFN-gamma on lymphangiogenesis. *Journal of Interferon and Cytokine Research* 2006 **26** 568–574. (<https://doi.org/10.1089/jir.2006.26.568>)
- 50. Wijenayaka AR, Kogawa M, Lim HP, Bonewald LF, Findlay DM & Atkins GJ.** Sclerostin stimulates osteocyte support of osteoclast activity by a RANKL-dependent pathway. *PLoS ONE* 2011 **6** e25900. (<https://doi.org/10.1371/journal.pone.0025900>)
- 51. Xiong L, Jung JU, Wu H, Xia WF, Pan JX, Shen C, Mei L & Xiong WC.** Lrp4 in osteoblasts suppresses bone formation and promotes osteoclastogenesis and bone resorption. *PNAS* 2015 **112** 3487–3492. (<https://doi.org/10.1073/pnas.1419714112>)
- 52. Klein C, Haraux E & Gouron R.** Gorham-Stout disease: hand involvement in an 8-year-old child. *Jurnalul Pediatriei* 2017 **191** 277–277.e1.
- 53. Lehnhardt M, Steinau HU, Homann HH, Steinstraesser L & Druecke D.** Das Gorham-Stout-Syndrom der Hand: Fallbericht eines progressiven Krankheitsverlaufes über 24 Jahre. (Gorham-Stout disease: report of a case affecting the right hand with a follow-up of 24 years). *Handchirurgie, Mikrochirurgie, Plastische Chirurgie* 2004 **36** 249–254. (<https://doi.org/10.1055/s-2004-821048>)
- 54. Halliday DR, Dahlin DC, Pugh DG & Young HH.** Massive osteolysis and angiomatosis. *Radiology* 1964 **82** 637–644. (<https://doi.org/10.1148/82.4.637>)
- 55. Esmailiejah AA, Kamalian N & Abbasian M.** Temporary paraplegia resulting from Gorham's disease involving the third lumbar vertebra and proximal femur: a five-year follow-up and review of the literature. *Archives of Iranian Medicine* 2013 **16** 686–690. (<https://doi.org/0131611/AIM.0016>)
- 56. Tie ML, Poland GA & Rosenow EC 3rd.** Chylothorax in Gorham's syndrome. A common complication of a rare disease. *Chest* 1994 **105** 208–213. (<https://doi.org/10.1378/chest.105.1.208>)
- 57. Hernández-Marqués C, Serrano González A, Cordobés Ortega F, Alvarez-Coca J, Sirvent Cerda S, Carceller Lechón F & Azorín Cuadrillero D.** Gorham-Stout disease and cerebrospinal fluid otorrhea. *Pediatric Neurosurgery* 2011 **47** 299–302. (<https://doi.org/10.1159/000336877>)
- 58. Coulter IC, Khan SA, Flanagan AM & Marks SM.** Chiari I malformation associated with Gorham's disease of the skull base. *Clinical Neurology and Neurosurgery* 2014 **116** 83–86. (<https://doi.org/10.1016/j.clineuro.2013.11.007>)
- 59. Nagashima H, Mizukawa K, Taniguchi M, Yamamoto Y & Kohmura E.** Cerebrospinal fluid leakage and Chiari I malformation with Gorham's disease of the skull base: a case report. *Neurologia i Neurochirurgia Polska* 2017 **51** 427–431. (<https://doi.org/10.1016/j.pjnns.2017.06.007>)
- 60. Yoshimoto S, Takai K, Takahashi K, Yasui T & Taniguchi M.** Intracranial hypotension and hypertension: reversible Chiari I malformation due to dynamic cerebrospinal fluid abnormalities in Gorham-Stout disease. Case report. *Journal of Neurosurgery: Pediatrics* 2018 **22** 508–512. (<https://doi.org/10.3171/2018.5.PEDS1859>)
- 61. Stephens S, Squires L, Campbell R, Davies J & Chaseling R.** Multifocal Gorham-Stout disease associated with Chiari I malformation and recurrent aseptic meningitis: case report and review of literature. *Journal of Clinical Neuroscience* 2020 **72** 486–492. (<https://doi.org/10.1016/j.jocn.2019.12.033>)

- 62. Aouad P, Young NM, Saratsis AM, Reynolds MA & Ryan ME.** Gorham Stout disease of the temporal bone with cerebrospinal fluid leak. *Child's Nervous System* 2021. (<https://doi.org/10.1007/s00381-021-05245-1>)
- 63. Morimoto N, Ogiwara H, Miyazaki O, Kitamura M, Nishina S, Nakazawa A, Maekawa T & Morota N.** Gorham–Stout syndrome affecting the temporal bone with cerebrospinal fluid leakage. *International Journal of Pediatric Otorhinolaryngology* 2013 **77** 1596–1600. (<https://doi.org/10.1016/j.ijporl.2013.06.004>)
- 64. Girn HR, Towns G, Chumas P, Holland P & Chakrabarty A.** Gorham's disease of skull base and cervical spine—confusing picture in a two year old. *Acta Neurochirurgica* 2006 **148** 909–13; discussion 913. (<https://doi.org/10.1007/s00701-005-0806-x>)
- 65. Nozawa A, Ozeki M, Kuze B, Asano T, Matsuoka K & Fukao T.** Gorham–Stout disease of the skull base with hearing loss: dramatic recovery and antiangiogenic therapy. *Pediatric Blood and Cancer* 2016 **63** 931–934. (<https://doi.org/10.1002/xbc.25886>)
- 66. Mowry S & Canalis R.** Gorham–Stout disease of the temporal bone. *Laryngoscope* 2010 **120** 598–600. (<https://doi.org/10.1002/lary.20788>)
- 67. Domínguez Fuentes B, García-Gil D, Jimeno A & García-Lechuz JM.** Síndrome de Gorham–Stout en un paciente con infección por el VIH. (Gorham–Stout syndrome in a patient with HIV infection). *Medicina Clinica* 2008 **131** 36–37. (<https://doi.org/10.1157/13123040>)
- 68. Chrcanovic BR & Gomez RS.** Gorham–Stout disease with involvement of the jaws: a systematic review. *International Journal of Oral and Maxillofacial Surgery* 2019 **48** 1015–1021. (<https://doi.org/10.1016/j.ijom.2019.03.002>)
- 69. Agrawal R, Mohammed I & Reilly PG.** Duropleural fistula as a consequence of Gorham–Stout syndrome: a combination of 2 rare conditions. *Journal of Thoracic and Cardiovascular Surgery* 2006 **131** 1205–1206. (<https://doi.org/10.1016/j.jtcvs.2006.01.023>)
- 70. Momanu A, Caba L, Gorduza NC, Arhire OE, Popa AD, Ianole V & Gorduza EV.** Gorham–Stout disease with multiple bone involvement—challenging diagnosis of a rare disease and literature review. *Medicina* 2021 **57** 681. (<https://doi.org/10.3390/medicina57070681>)
- 71. Mawk JR, Obukhov SK, Nichols WD, Wynne TD, Odell JM & Urman SM.** Successful conservative management of Gorham disease of the skull base and cervical spine. *Child's Nervous System* 1997 **13** 622–625. (<https://doi.org/10.1007/s003810050155>)
- 72. Duffy BM, Manon R, Patel RR & Welsh JS.** A case of Gorham's disease with chylothorax treated curatively with radiation therapy. *Clinical Medicine and Research* 2005 **3** 83–86. (<https://doi.org/10.3121/cmr.3.2.83>)
- 73. Jiang Y, Hou G & Cheng W.** 99mTc-SC lymphoscintigraphy and SPECT/CT findings in a case report of Gorham–Stout disease presenting with chylothorax and bone pain. *Medicine* 2019 **98** e15023. (<https://doi.org/10.1097/MD.00000000000015023>)
- 74. Ricci KW, Hammill AM, Mobberley-Schuman P, Nelson SC, Blatt J, Bender JLG, McCuaig CC, Synakiewicz A, Frieden IJ & Adams DM.** Efficacy of systemic sirolimus in the treatment of generalized lymphatic anomaly and Gorham–Stout disease. *Pediatric Blood and Cancer* 2019 **66** e27614. (<https://doi.org/10.1002/xbc.27614>)
- 75. Ramaroli DA, Cavarzere P, Cheli M, Provenzi M, Barillari M, Rodella G, Gaudino R & Antoniazzi F.** A child with early-onset Gorham–Stout disease complicated by chylothorax: near-complete regression of bone lesions with interferon and bisphosphonate treatment. *Hormone Research in Paediatrics* 2019 **91** 406–410. (<https://doi.org/10.1159/000495364>)
- 76. Davalos EA, Gandhi NM, Barank D & Varma RK.** Gorham–Stout disease presenting with dyspnea and bone pain in a 9-year-old girl. *Radiology Case Reports* 2015 **10** 1110. (<https://doi.org/10.2484/rcr.v10i2.1110>)
- 77. Demir MK, Yapıcıer Ö, Toktaş ZÖ, Yılmaz B, Akakin A & Konya D.** Gorham's disease—vanishing bone of the cervical spine. *Spine Journal* 2016 **16** e19–e21. (<https://doi.org/10.1016/j.spinee.2015.08.045>)
- 78. González Luna A, Nuñez Pizarro JL & Rodríguez Echegaray CI.** Presentación atípica del síndrome de Gorham–Stout: caso clínico. (Atypical presentation of Gorham–Stout syndrome: case report). *Archivos Argentinos de Pediatría* 2015 **113** e153–e156 (Spanish). (<https://doi.org/10.5546/aap.2015.e153>)
- 79. Bruch-Gerharz D, Gerharz CD, Stege H, Krutmann J, Pohl M, Koester R & Ruzicka T.** Cutaneous lymphatic malformations in disappearing bone (Gorham–Stout) disease: a novel clue to the pathogenesis of a rare syndrome. *Journal of the American Academy of Dermatology* 2007 **56** (Supplement) S21–S25. (<https://doi.org/10.1016/j.jaad.2006.01.063>)
- 80. Frost JF & Caplan RM.** Cutaneous hemangiomas and disappearing bones with a review of cutaneovisceral hemangiomatosis. *Archives of Dermatology* 1965 **92** 501–508.
- 81. Fornasier VL.** Hemangiomatosis with massive osteolysis. *Journal of Bone and Joint Surgery: British Volume* 1970 **52B** 444–451.
- 82. Ogawa Y, Shimada S & Kawamura T.** Case of Gorham–Stout disease with multiple verrucous skin lesions. *Journal of Dermatology* 2020 **47** e388–e390. (<https://doi.org/10.1111/1346-8138.15557>)
- 83. Liang Y, Tian R, Wang J, Shan Y, Gao H, Xie C, Li J, Xu M & Gu S.** Gorham–Stout disease successfully treated with sirolimus (rapamycin): a case report and review of the literature. *BMC Musculoskeletal Disorders* 2020 **21** 577. (<https://doi.org/10.1186/s12891-020-03540-7>)
- 84. Bode-Lesniewska B, von Hochstetter A, Exner GU & Hodler J.** Gorham–Stout disease of the shoulder girdle and cervico–thoracic spine: fatal course in a 65-year-old woman. *Skeletal Radiology* 2002 **31** 724–729. (<https://doi.org/10.1007/s00256-002-0568-y>)
- 85. Kery L & Wouters HW.** Massive osteolysis. Report of two cases. *Journal of Bone and Joint Surgery: British Volume* 1970 **52** 452–459.
- 86. Lo CP, Chen CY, Chin SC, Juan CJ, Hsueh CJ & Chen A.** Disappearing calvarium in Gorham disease: MR imaging characteristics with pathologic correlation. *American Journal of Neuroradiology* 2004 **25** 415–418.
- 87. Yoo SY, Hong SH, Chung HW, Choi JA, Kim CJ & Kang HS.** MRI of Gorham's disease: findings in two cases. *Skeletal Radiology* 2002 **31** 301–306. (<https://doi.org/10.1007/s00256-002-0487-y>)
- 88. Kobayashi H, Shigeno C, Sakahara H, Hosono M, Hosono M, Yao ZS, Endo K & Konishi J.** Intraosseous hemangiomatosis: technetium-99m(V)dimercaptosuccinic acid and technetium-99m-hydroxymethylene diphosphonate imaging. *Journal of Nuclear Medicine* 1994 **35** 1482–1484.
- 89. Alves VM, Vieira TS, Amorim NS, Oliveira A, Rodrigues A & Pereira JG.** 99mTc(V)–DMSA SPECT–CT findings in a case of Gorham–Stout disease. *Nuclear Medicine Review: Central and Eastern Europe* 2015 **18** 97–101. (<https://doi.org/10.5603/NMR.2015.0023>)
- 90. Papadakis GZ, Millo C, Bagci U, Blau J & Collins MT.** 18F–NaF and 18F–FDG PET/CT in Gorham–Stout disease. *Clinical Nuclear Medicine* 2016 **41** 884–885. (<https://doi.org/10.1097/RLU.0000000000001369>)
- 91. Dunbar SF, Rosenberg A, Mankin H, Rosenthal D & Suit HD.** Gorham's massive osteolysis: the role of radiation therapy and a review of the literature. *International Journal of Radiation Oncology, Biology, Physics* 1993 **26** 491–497. ([https://doi.org/10.1016/0360-3016\(93\)90968-2](https://doi.org/10.1016/0360-3016(93)90968-2))

- 92. Heyd R, Micke O, Surholt C, Berger B, Martini C, Füller J, Schimpke T, Seegenschmiedt MH & German Cooperative Group on Radiotherapy for Benign Diseases.** Radiation therapy for Gorham–Stout syndrome: results of a national patterns-of-care study and literature review. *International Journal of Radiation Oncology, Biology, Physics* 2011 **81** e179–e185. (<https://doi.org/10.1016/j.ijrobp.2011.01.006>)
- 93. Ruggieri P, Montalti M, Angelini A, Alberghini M & Mercuri M.** Gorham–Stout disease: the experience of the Rizzoli Institute and review of the literature. *Skeletal Radiology* 2011 **40** 1391–1397. (<https://doi.org/10.1007/s00256-010-1051-9>)
- 94. Brodzki N, Länsberg JK, Dictor M, Gyllstedt E, Ewers SB, Larsson MK & Eklund EA.** A novel treatment approach for paediatric Gorham–Stout syndrome with chylothorax. *Acta Paediatrica* 2011 **100** 1448–1453. (<https://doi.org/10.1111/j.1651-2227.2011.02361.x>)
- 95. Leite I, Hernández-Martín A, Colmenero I, López-Gutiérrez JC & Torrelo A.** Invasive lymphatic malformation (gorham–stout) of the pelvis with prominent skin involvement. *Pediatric Dermatology* 2013 **30** 374–378. (<https://doi.org/10.1111/j.1525-1470.2012.01814.x>)
- 96. Ozbayrak M, Yilmaz MH, Kantarci F, Ozer H, Harmanci K, Babacan M & Dervisoglu S.** A case of an idiopathic massive osteolysis with skip lesions. *Korean Journal of Radiology* 2013 **14** 946–950. (<https://doi.org/10.3348/kjr.2013.14.6.946>)
- 97. Liu Y, Zhong DR, Zhou PR, Lv F, Ma DD, Xia WB, Jiang Y, Wang O, Xing XP & Li M.** Gorham–Stout disease: radiological, histological, and clinical features of 12 cases and review of literature. *Clinical Rheumatology* 2016 **35** 813–823. (<https://doi.org/10.1007/s10067-014-2780-2>)
- 98. Carbó E, Riquelme Ó, García A & González JL.** Vertebroplasty in a 10-year-old boy with Gorham–Stout syndrome. *European Spine Journal* 2015 **24** (Supplement 4) S590–S593. (<https://doi.org/10.1007/s00586-015-3764-x>)
- 99. Yerganyan VV, Body JJ, De Saint Aubain N & Gebhart M.** Gorham–Stout disease of the proximal fibula treated with radiotherapy and zoledronic acid. *Journal of Bone Oncology* 2015 **4** 42–46. (<https://doi.org/10.1016/j.jbo.2015.05.001>)
- 100. Tolis K, Triantafyllopoulos IK, Tournis S & Papaioannou NA.** Gorham–Stout disease of the pelvis: seven years follow up with complete radiological evaluation. *Journal of Musculoskeletal and Neuronal Interactions* 2016 **16** 79–82.
- 101. Tateda S, Aizawa T, Hashimoto K, Kanno H, Ohtsu S, Itoi E & Ozawa H.** Successful management of Gorham–Stout disease in the cervical spine by combined conservative and surgical treatments: a case report. *Tohoku Journal of Experimental Medicine* 2017 **241** 249–254. (<https://doi.org/10.1620/tjem.241.249>)
- 102. Koto K, Inui K, Itoi M & Itoh K.** Gorham–Stout disease in the rib and thoracic spine with spinal injury treated with radiotherapy, zoledronic acid, vitamin D, and propranolol: a case report and literature review. *Molecular and Clinical Oncology* 2019 **11** 551–556. (<https://doi.org/10.3892/mco.2019.1934>)
- 103. Tena-Sanabria ME, Jesús-Mejenes LY, Fuentes-Herrera G, Álvarez-Martínez FA, Victorio-García NP & Núñez-Enríquez JC.** A report of two children with Gorham–Stout disease. *BMC Pediatrics* 2019 **19** 206. (<https://doi.org/10.1186/s12887-019-1561-0>)
- 104. Mavrogenis AF, Angelini A, Pala E, Calabro T, Bianchi G, Casadei R & Ruggieri P.** Radiation-induced sarcomas. *Journal of Long-Term Effects of Medical Implants* 2011 **21** 233–240. (<https://doi.org/10.1615/jlongtermeffmedimplants.v21.i3.70>)
- 105. Rodríguez-Vazquez JR, Chandra SR, Albertson ME, Hansen NJ & Johnson CM.** Radiation-induced sarcoma on 18F-FDG PET/CT after treatment of Gorham–Stout disease of the maxilla. *Clinical Nuclear Medicine* 2019 **44** e607–e608. (<https://doi.org/10.1097/RLU.0000000000002761>)
- 106. Triana P, Dore M, Cerezo VN, Cervantes M, Sánchez AV, Ferrero MM, González MD & Lopez-Gutierrez JC.** Sirolimus in the treatment of vascular anomalies. *European Journal of Pediatric Surgery* 2017 **27** 86–90. (<https://doi.org/10.1055/s-0036-1593383>)
- 107. García V, Alonso-Claudio G, Gómez-Hernández MT & Chamorro AJ.** Sirolimus on Gorham–Stout disease. Case report. *Colombia Medica* 2016 **47** 213–216. (<https://doi.org/10.25100/cm.v47i4.2406>)
- 108. Ozeki M, Nozawa A, Yasue S, Endo S, Asada R, Hashimoto H & Fukao T.** The impact of sirolimus therapy on lesion size, clinical symptoms, and quality of life of patients with lymphatic anomalies. *Orphanet Journal of Rare Diseases* 2019 **14** 141. (<https://doi.org/10.1186/s13023-019-1118-1>)
- 109. Mo AZ, Trenor CC 3rd & Hedequist DJ.** Sirolimus therapy as perioperative treatment of Gorham–Stout disease in the thoracic spine: a case report. *JBJS Case Connector* 2018 **8** e70. (<https://doi.org/10.2106/JBJS.CC.17.00287>)
- 110. Schneider KN, Gosheger G & Andreou D.** Gorham–Stout syndrome. *Deutsches Ärzteblatt International* 2019 **116** 507. (<https://doi.org/10.3238/arztebl.2019.0507a>)
- 111. Cho S, Kang SR, Lee BH & Choi S.** Chylous manifestations and management of Gorham–Stout syndrome. *Korean Journal of Thoracic and Cardiovascular Surgery* 2019 **52** 44–46. (<https://doi.org/10.5090/kjtcs.2019.52.1.44>)
- 112. Zheng MW, Yang M, Qiu JX, Nan XP, Huang LY, Zhang WD, Gong L & Huang ZZ.** Gorham–Stout syndrome presenting in a 5-year-old girl with a successful bisphosphonate therapeutic effect. *Experimental and Therapeutic Medicine* 2012 **4** 449–451. (<https://doi.org/10.3892/etm.2012.622>)
- 113. Gem M, Özkul E & Arslan H.** Gorham–Stout’s disease in the metatarsus: a case report. *Acta Orthopaedica et Traumatologica Turcica* 2014 **48** 467–471. (<https://doi.org/10.3944/AOTT.2014.13.0132>)
- 114. Maillot C, Cloche T & Le Huec JC.** Thoracic osteotomy for Gorham–Stout disease of the spine: a case report and literature review. *European Spine Journal* 2018 **27** 2285–2290. (<https://doi.org/10.1007/s00586-014-3613-3>)
- 115. Matsumoto T, Naito M, Hirose J, Nakada I, Morikawa T & Tanaka S.** Gorham–Stout syndrome of the shoulder girdle successfully controlled by antiresorptive agents: a report of 2 cases. *JBJS Case Connector* 2019 **9** e0285. (<https://doi.org/10.2106/JBJS.CC.18.00285>)
- 116. Schneider KN, Masthoff M, Gosheger G, Klingebiel S, Schorn D, Röder J, Vogler T, Wildgruber M & Andreou D.** Gorham–Stout disease: good results of bisphosphonate treatment in 6 of 7 patients. *Acta Orthopaedica* 2020 **91** 209–214. (<https://doi.org/10.1080/17453674.2019.1709716>)
- 117. Hagberg H, Lamberg K & Aström G.** Alpha-2b interferon and oral clodronate for Gorham’s disease. *Lancet* 1997 **350** 1822–1823. ([https://doi.org/10.1016/S0140-6736\(05\)63639-2](https://doi.org/10.1016/S0140-6736(05)63639-2))
- 118. Pflieger A, Schwinger W, Maier A, Tauss J, Popper HH & Zach MS.** Gorham–Stout syndrome in a male adolescent—case report and review of the literature. *Journal of Pediatric Hematology/Oncology* 2006 **28** 231–233. (<https://doi.org/10.1097/01.mph.0000203721.83566.e6>)
- 119. Deveci M, Inan N, Corapçioğlu F & Ekingen G.** Gorham–Stout syndrome with chylothorax in a six-year-old boy. *Indian Journal of Pediatrics* 2011 **78** 737–739. (<https://doi.org/10.1007/s12098-010-0328-2>)

- 120. Kuriyama DK, McElligott SC, Glaser DW & Thompson KS.** Treatment of Gorham–Stout disease with zoledronic acid and interferon- α : a case report and literature review. *Journal of Pediatric Hematology/Oncology* 2010 **32** 579–584. (<https://doi.org/10.1097/MPH.0b013e3181edb464>)
- 121. Shimizu T, Sato K, Yoshida T, Takahashi A, Yanagawa T, Wada N, Sohmiya M, Shirakura K & Watanabe H.** A case report of Gorham–Stout syndrome remission. *Journal of Orthopaedic Science* 2012 **17** 199–204. (<https://doi.org/10.1007/s00776-011-0080-0>)
- 122. Yavaşoğlu İ & Çakiroğlu U.** Diffuse lymphangiomatosis: Gorham–Stout syndrome. *Internal Medicine* 2014 **53** 75–76. (<https://doi.org/10.2169/internalmedicine.53.0987>)
- 123. Cramer SL, Wei S, Merrow AC & Pressey JG.** Gorham–Stout disease successfully treated with sirolimus and zoledronic acid therapy. *Journal of Pediatric Hematology/Oncology* 2016 **38** e129–e132. (<https://doi.org/10.1097/MPH.0000000000000514>)
- 124. Garbers E, Reuther F & Delling G.** Report of a rare case of Gorham–Stout disease of both shoulders: bisphosphonate treatment and shoulder replacement. *Case Reports in Rheumatology* 2011 **2011** 565142. (<https://doi.org/10.1155/2011/565142>)
- 125. Brance ML, Castiglioni A, Cócáro N & Palatnik M.** Two cases of Gorham–Stout disease with good response to zoledronic acid treatment. *Clinical Cases in Mineral and Bone Metabolism* 2017 **14** 250–253. (<https://doi.org/10.11138/ccmbm/2017.14.2.250>)
- 126. Illeez OG, Ozkan K, Ozkan FU, Bostan AB, Akpınar F, Bilgic B & Aktas I.** Zoledronic acid: treatment option for Gorham–Stout disease. *Der Orthopade* 2018 **47** 1032–1035. (<https://doi.org/10.1007/s00132-018-3655-z>)
- 127. Zheng C, Tang F, Min L, Zhou Y, Luo Y, Tu C & Zhang S.** Gorham–Stout disease of the malleolus: a rare case report. *BMC Musculoskeletal Disorders* 2019 **21** 3. (<https://doi.org/10.1186/s12891-019-3027-9>)
- 128. Takahashi A, Ogawa C, Kanazawa T, Watanabe H, Suzuki M, Suzuki N, Tsuchida Y, Morikawa A & Kuwano H.** Remission induced by interferon alfa in a patient with massive osteolysis and extension of lymph–hemangiomatosis: a severe case of Gorham–Stout syndrome. *Journal of Pediatric Surgery* 2005 **40** E47–E50. (<https://doi.org/10.1016/j.jpedsurg.2004.11.015>)
- 129. Kose M, Pekcan S, Dogru D, Akyuz C, Ozelik U, Ozsurekci Y, Gulhan B, Demircin M & Kiper N.** Gorham–Stout syndrome with chylothorax: successful remission by interferon alpha-2b. *Pediatric Pulmonology* 2009 **44** 613–615. (<https://doi.org/10.1002/ppul.20849>)
- 130. Dupond JL, Bermont L, Runge M & de Billy M.** Plasma VEGF determination in disseminated lymphangiomatosis–Gorham–Stout syndrome: a marker of activity? A case report with a 5-year follow-up. *Bone* 2010 **46** 873–876. (<https://doi.org/10.1016/j.bone.2009.11.015>)
- 131. Nir V, Guralnik L, Livnat G, Bar-Yoseph R, Hakim F, Ilivitzki A & Bentur L.** Propranolol as a treatment option in Gorham–Stout syndrome: a case report. *Pediatric Pulmonology* 2014 **49** 417–419. (<https://doi.org/10.1002/ppul.22869>)
- 132. Baud J, Lomri A, Graber D & Bikfalvi A.** The therapeutic response in Gorham's syndrome to the beta-blocking agent propranolol is correlated to VEGF-A, but not to VEGF-C or FLT1 expression. *BMC Research Notes* 2015 **8** 333. (<https://doi.org/10.1186/s13104-015-1259-9>)
- 133. Ozeki M, Fukao T & Kondo N.** Propranolol for intractable diffuse lymphangiomatosis. *New England Journal of Medicine* 2011 **364** 1380–1382. (<https://doi.org/10.1056/NEJMc1013217>)
- 134. Ozeki M, Kanda K, Kawamoto N, Ohnishi H, Fujino A, Hirayama M, Kato Z, Azuma E, Fukao T & Kondo N.** Propranolol as an alternative treatment option for pediatric lymphatic malformation. *Tohoku Journal of Experimental Medicine* 2013 **229** 61–66. (<https://doi.org/10.1620/tjem.229.61>)
- 135. Léauté-Labrèze C, Dumas de la Roque E, Hubiche T, Boralevi F, Thambo JB & Taïeb A.** Propranolol for severe hemangiomas of infancy. *New England Journal of Medicine* 2008 **358** 2649–2651. (<https://doi.org/10.1056/NEJMc0708819>)
- 136. Peridis S, Pilgrim G, Athanasopoulos I & Parpounas K.** A meta-analysis on the effectiveness of propranolol for the treatment of infantile airway haemangiomas. *International Journal of Pediatric Otorhinolaryngology* 2011 **75** 455–460. (<https://doi.org/10.1016/j.ijporl.2011.01.028>)
- 137. Liu SZ, Zhou X, Song A, Wang YP & Liu Y.** A rare case of Gorham–Stout syndrome of femur treated with cement augmentation. *Chinese Medical Journal* 2018 **131** 1628–1629. (<https://doi.org/10.4103/0366-6999.235121>)
- 138. Feigl D, Seidel L & Marmor A.** Gorham's disease of the clavicle with bilateral pleural effusions. *Chest* 1981 **79** 242–244. (<https://doi.org/10.1378/chest.79.2.242>)
- 139. Busilacchi A, Ramazzotti D, Ulisse S & Gigante A.** Gorham–Stout disease as a complication of posterior shoulder capsulorrhaphy. *Journal of Shoulder and Elbow Surgery* 2012 **21** e1–e7. (<https://doi.org/10.1016/j.jse.2012.05.024>)
- 140. Brunner U, Rückl K, Konrads C, Rudert M & Plumhoff P.** Gorham–Stout syndrome of the shoulder. *SICOT-J* 2016 **2** 25. (<https://doi.org/10.1051/sicotj/2016015>)
- 141. Vaishya R, Vaish A, Singh LK & Baweja P.** Management of a pathological fracture in a rare case of Gorham Stout disease of the hip with a mega prosthesis. *Journal of Orthopaedics* 2020 **18** 177–180. (<https://doi.org/10.1016/j.jor.2019.08.003>)
- 142. Woodward HR, Chan DP & Lee J.** Massive osteolysis of the cervical spine: a case report of bone graft failure. *Spine* 1981 **6** 545–549. (<https://doi.org/10.1097/00007632-198111000-00003>)
- 143. Turra S, Gigante C & Scapinelli R.** A 20-year follow-up study of a case of surgically treated massive osteolysis. *Clinical Orthopaedics and Related Research* 1990 **250** 297–302. (<https://doi.org/10.1097/00003086-199001000-00039>)
- 144. Chong Ng L & Sell P.** Gorham disease of the cervical spine—a case report and review of the literature. *Spine* 2003 **28** E355–E358. (<https://doi.org/10.1097/01.BRS.0000084557.38858.85>)
- 145. Schell A, Rhee JM, Allen A, Andras L & Zhou F.** Surgical management of Gorham disease involving the upper cervical spine with occipito–cervical–thoracic fusion: a case report. *Spine Journal* 2016 **16** e467–e472. (<https://doi.org/10.1016/j.spinee.2016.02.020>)
- 146. Jaccard A, Macedo C, Castro G & Guiroy A.** Thoracic spine dislocation in Gorham–Stout syndrome: case report and literature review. *Surgical Neurology International* 2018 **9** 223. (https://doi.org/10.4103/sni.sni_311_18)
- 147. Du CZ, Li S, Xu L, Zhou QS, Zhu ZZ, Sun X & Qiu Y.** Spinal Gorham–Stout syndrome: radiological changes and spinal deformities. *Quantitative Imaging in Medicine and Surgery* 2019 **9** 565–578. (<https://doi.org/10.21037/qims.2019.03.17>)
- 148. Kim JH, Yoon DH, Kim KN, Shin DA, Yi S, Kang J & Ha Y.** Surgical management of Gorham–Stout disease in cervical compression fracture with cervicothoracic fusion: case report and review of literature. *World Neurosurgery* 2019 **129** 277–281. (<https://doi.org/10.1016/j.wneu.2019.05.235>)
- 149. Chang KJ, Yang MH, Li B & Huang H.** Surgical management of Gorham–Stout syndrome involving the cervical spine with bilateral pleural effusion: a case report and

literature review. *Experimental and Therapeutic Medicine* 2020 **19** 3851–3855. (<https://doi.org/10.3892/etm.2020.8627>)

150. Kai B, Ryan A, Munk PL & Dunlop P. Gorham disease of bone: three cases and review of radiological features. *Clinical Radiology* 2006 **61** 1058–1064. (<https://doi.org/10.1016/j.crad.2006.04.014>)

151. Kotaru AC & Rajput AK. Chylothorax from Gorham–Stout disease. *Journal of Bronchology and Interventional Pulmonology* 2018 **25** 340–342. (<https://doi.org/10.1097/LBR.0000000000000506>)

152. Pedicelli G, Mattia P, Zorzoli AA, Sorrone A, De Martino F & Sciotto V. Gorham syndrome. *JAMA* 1984 **252** 1449–1451.

153. Hejgaard N & Olsen PR. Massive Gorham osteolysis of the right hemipelvis complicated by chylothorax: report of a case in a 9-year-old boy successfully

treated by pleurodesis. *Journal of Pediatric Orthopedics* 1987 **7** 96–99. (<https://doi.org/10.1097/01241398-198701000-00020>)

154. Cho SJ & Kim SW. Chemical pleurodesis using *Viscum album* extract in Gorham disease complicated with chylothorax. *Acute and Critical Care* 2018 **33** 105–109. (<https://doi.org/10.4266/acc.2016.00164>)

155. Ferreiro L, Suárez-Antelo J, Rábade C, Abdulkader I, Bermúdez-Naveira A, Fernández-García A & Valdés L. Chylothorax as a debut form of Gorham–Stout disease. *Pulmonology* 2019 **25** 195–197. (<https://doi.org/10.1016/j.pulmoe.2019.01.008>)

156. Wang P, Liao W, Cao G & Jiang Y. A rare case of Gorham–Stout syndrome involving the thoracic spine with progressive bilateral chylothorax: a case report. *BMC Musculoskeletal Disorders* 2019 **20** 154. (<https://doi.org/10.1186/s12891-019-2542-z>)