



Rare sites of breast cancer metastasis: a review

Rosa Di Micco^{1,2}, Letizia Santurro¹, Maria Luisa Gasparri¹, Veronica Zuber¹, Enrico Fiacco¹, Guglielmo Gazzetta¹, Chanel Elisha Smart¹, Alice Valentini¹, Oreste Davide Gentilini¹

¹Breast Surgery Unit, Breast Unit, San Raffaele University Hospital, Milan, Italy; ²Department of Clinical Medicine and Surgery, University of Naples Federico II, Naples, Italy

Contributions: (I) Conception and design: R Di Micco, OD Gentilini; (II) Administrative support: V Zuber, E Fiacco, CE Smart; (III) Provision of study materials or patients: ML Gasparri; (IV) Collection and assembly of data: L Santurro, G Gazzetta; (V) Data analysis and interpretation: R Di Micco; (VI) Manuscript writing: All authors; (VII) Final approval of manuscript: All authors.

Correspondence to: Rosa Di Micco. San Raffaele University Hospital, Via Olgettina 60, 20132 Milan, Italy. Email: dimicco.rosa@hsr.it.

Abstract: Breast cancer (BC) metastasis accounts for the majority of deaths from BC. The rate of metastasis to uncommon sites is on the rise due to the more effective therapy prolonging survival and to the early detection on imaging. The evaluation of patient-reported symptoms is essential in detecting a recurrence as early as possible, which may impact survival. Hence, the knowledge of even the rare sites of BC metastasis is of paramount importance for the clinical interpretation of new symptoms in BC survivors. The term “unusual metastasis” defines a systemic failure with a frequency of $\leq 1\%$ at each site and according to this unusual metastasis involve the central nervous system, secretory/endocrine organs and glands, internal organs and structures, and gynecological organs. The literature search was performed using the electronic database PubMed up to December 2018, with the following key words: {[rare(Title/Abstract)] OR [unusual(Title/Abstract)] OR [unconventional(Title/Abstract)]} AND {[metastases(Title/Abstract)] OR [metastasis(Title/Abstract)]} AND {[breast(Title/Abstract)]} AND {[cancer(Title/Abstract)] OR [tumor(Title/Abstract)] OR [tumour(Title/Abstract)] OR [neoplasm(Title/Abstract)]}. The search was limited to papers in English language. Of the 3,086 papers found, 757 were excluded as reporting animal models, 378 were not in English language, 1 was a duplicate of the same research, 1,414 did not report on BC metastases, 108 were previous review reviews on BC or tumour to tumour metastases; 428 papers were included in this review. Despite the improvements in BC management, most deaths from cancer result from metastases that are resistant to conventional therapies. In general, it is uncommon to find isolated rare metastases, the vast majority of these develops together with metastases in other sites, thus highlighting a worsening systemic disease. However, the early detection of even rare metastases represents the only chance to control the disease and prolong survival while waiting for the development of more effective systemic therapies.

Keywords: Breast cancer (BC); rare metastasis; unusual site; metastatic disease

Submitted Jun 30, 2019. Accepted for publication Jul 12, 2019.

doi: 10.21037/tcr.2019.07.24

View this article at: <http://dx.doi.org/10.21037/tcr.2019.07.24>

Introduction

Breast cancer (BC) metastasis accounts for the majority of deaths from BC. The rate of metastasis even in sites known as uncommon is on the rise. On one side this is due to the more effective therapy which have prolonged the overall survival of BC patients, on the other side due to the development of new imaging techniques and early detection (1). The American

Cancer Society/American Society of Clinical Oncology Breast Cancer Survivorship Care Guideline recommends that primary care clinicians should educate and counsel all women about the signs and symptoms of recurrence, including new lumps, pain in the bone, chest or abdomen, dyspnea and constant headaches (2). There is no evidence that routine laboratory tests or imaging (exception for mammography, when indicated) in asymptomatic patients gives any survival

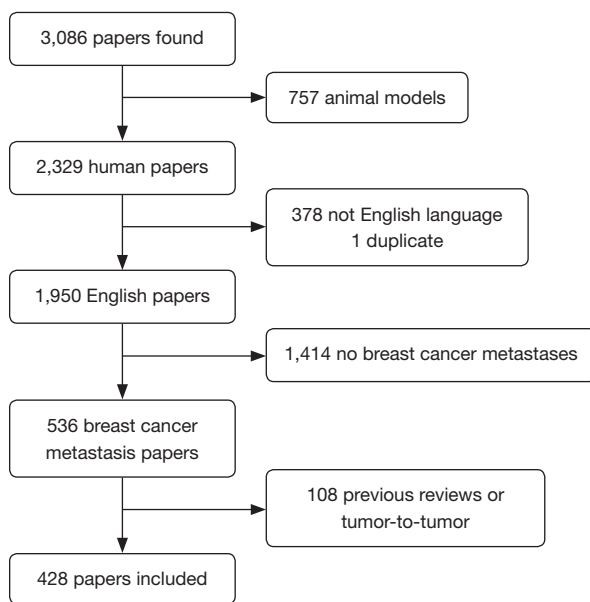


Figure 1 Flow chart of studies included in the review.

advantage, thus advanced imaging should be offered when recurrence is suspected (3,4). The evaluation of patient-reported symptoms is essential in detecting a recurrence as early as possible, which may impact survival (5,6). Hence, the knowledge of even the rare sites of BC metastasis is of paramount importance for the clinical interpretation of new symptoms in BC survivors.

BC can metastasize to several organs, the most frequent metastatic sites include bone, lungs, liver and skin (7). Additionally, more and more sites of BC metastasis have been reported in literature. The definition of “unusual metastasis” is not universally accepted, however it defines a systemic failure with a frequency of $\leq 1\%$ at each site and according to this unusual metastasis involve the central nervous system, secretory/endocrine organs and glands, internal organs and structures, and gynaecological organs.

This review reports on the rare anatomical regions where BC can spread forming metastases.

Methods

The literature search was performed using the electronic database PubMed up to December 2018, with the following key words: $\{[rare(Title/Abstract)] \text{ OR } [unusual(Title/Abstract)] \text{ OR } [unconventional(Title/Abstract)]\} \text{ AND } \{[metastases(Title/Abstract)] \text{ OR } [metastasis(Title/Abstract)]\} \text{ AND } \{[breast(Title/Abstract)]\} \text{ AND } \{[cancer(Title/$

$Abstract)] \text{ OR } [tumor(Title/Abstract)] \text{ OR } [tumour(Title/Abstract)] \text{ OR } [neoplasm(Title/Abstract)]\}$. The search did not include editorials, letters, comments, conference letters, systematic reviews and meta-analyses and it was limited to papers in English language.

All studies on rare sites of metastases from BC were eligible to be included.

All data were extracted in a standard pre-determined format including information on: first author’s name, publication year, number of cases and site of metastases. We considered rare the sites different from nodes, bone, lung, liver and skin.

Results

The flow chart of the study selection was shown in *Figure 1*. Of the 3,086 papers found, 757 were excluded as reporting animal models, 378 were not in English language, 1 was a duplicate of the same research, 1,414 did not report on BC metastases, 108 were previous review on BC or tumour to tumour metastases, 428 papers were included in this review. *Table 1* shows the distribution per sites of all cases of rare metastases reported in literature.

Discussion

In the war against BC, metastasis remains a primary clinical challenge as it is unpredictable in onset and it exponentially increases the clinical impact to the patient. The process of tumour metastasis is still controversial. Starting from Paget’s hypothesis of “seed and soil” (436), numerous studies have partially confirmed his observations and integrated new findings with the idea of a multistage process dependent on both the intrinsic properties of the tumour cells and the host response (437). In 1889 the surgeon Stephen Paget had already raised the question of “What is that decides what organs shall suffer in a case of disseminated cancer?” and contradicted the prevailing theory of Virchow (438) on metastasis originating from the arrest of tumour-cell emboli in the vasculature. Paget’s hypothesis is now widely accepted and enriched by new studies. The current definition of “seed” is a progenitor cell, cancer stem cell, or metastatic cell within the heterogeneous subpopulations forming the primary tumour, and the “soil” is the host factor, stroma, niche or organ microenvironment where selected metastatic cells can live and grow (439,440).

Translating Paget’s theory into clinical practice, findings show that BC preferentially spreads to some organs, whilst

Table 1 Site distribution of rare metastasis cases reported in literature

Anatomical region	Site	Reference	Number	Tot.	
Eye	Orbital soft tissue	Reeves <i>et al.</i> , 2002 (8)	1		
		Asproudis <i>et al.</i> , 2004 (9)	1		
		Eckardt <i>et al.</i> , 2011 (10)	1		
		Mora-Guzmán <i>et al.</i> , 2018 (11)	1		
		Maliepaard <i>et al.</i> , 2017 (12)	2		
		Spraker <i>et al.</i> , 2017 (13)	1		
		Pinto Proença <i>et al.</i> , 2018 (14)	1		
		Gondim <i>et al.</i> , 2017 (15)	5		
		Kim <i>et al.</i> , 2011 (16)	1 (bilateral)		
		Pierson <i>et al.</i> , 2016 (17)	6		
		Raap <i>et al.</i> , 2015 (18)	8		
		Zwicker <i>et al.</i> , 2008 (19)	7		
		Torres <i>et al.</i> , 2007 (20)	2		
		Schick <i>et al.</i> , 2006 (21)	3		
		Dieing <i>et al.</i> , 2004 (22)	2		
		Amemiya <i>et al.</i> , 2002 (23)	20		
		Rossi <i>et al.</i> , 2014 (24)	1	61	
		Intraocular	Bajcsay <i>et al.</i> , 2003 (25)	11	11
		Extraocular muscles	Murthy <i>et al.</i> , 2011 (26)	1	
	Chang <i>et al.</i> , 2017 (27)		1		
	Nifosi <i>et al.</i> , 2018 (28)		1		
	Framarino-Dei-Malatesta <i>et al.</i> , 2019 (29)		1		
	Weiss <i>et al.</i> , 1984 (30)		2		
	Lell <i>et al.</i> , 2004 (31)		1		
	Kouvaris <i>et al.</i> , 2008 (32)		1 (bilateral)		
	Spitzer <i>et al.</i> , 2005 (33)		1		
	Van der Heijden <i>et al.</i> , 1991 (34)		1		
	Glazer <i>et al.</i> , 1991 (35)		1		
	Retina	Pierson <i>et al.</i> , 2016 (17)	6	17	
Correa de Mello <i>et al.</i> , 2017 (36)		1			
Shields <i>et al.</i> , 2014 (37)		2			
Shah <i>et al.</i> , 2017 (38)		1			
Pierson <i>et al.</i> , 2016 (17)		9			
Biswas <i>et al.</i> , 2007 (39)		1 (bilateral)			
Sirimaharaj <i>et al.</i> , 2006 (40)		1			

Table 1 (continued)

Table 1 (continued)

Anatomical region	Site	Reference	Number	Tot.
		Schlaen <i>et al.</i> , 1986 (41)	1	16
	Conjunctiva	Skalicky <i>et al.</i> , 2007 (42)	1	
		Sánchez Orgaz <i>et al.</i> , 2017 (43)	1	
		Radovanović <i>et al.</i> , 2013 (44)	1	
	Eyelid	Kiratli <i>et al.</i> , 1996 (45)	4	7
		Kaur <i>et al.</i> , 2005 (46)	1	
		Martorell-Calatayud <i>et al.</i> , 2010 (47)	1 (bilateral)	
		Goodier <i>et al.</i> , 2010 (48)	1	
		Kuo <i>et al.</i> , 2008 (49)	1	
		Douglas <i>et al.</i> , 2002 (50)	1 (bilateral)	
		Claessens <i>et al.</i> , 2000 (51)	1	
		Rosenblum <i>et al.</i> , 1983 (52)	2	
	Iris and ciliar body	Lawton <i>et al.</i> , 1980 (53)	1	9
		Ozturk <i>et al.</i> , 2007 (54)	1	
		Shields <i>et al.</i> , 1995 (37)	16	
		Mennel <i>et al.</i> , 2001 (55)	2	
		Reddy <i>et al.</i> , 2000 (56)	1	20
	Choroid	Williams <i>et al.</i> , 2000 (57)	1	
		Solav <i>et al.</i> , 2010 (58)	1	
		Arya <i>et al.</i> , 2018 (59)	1	
		Luo <i>et al.</i> , 2018 (60)	1	
		Antosz <i>et al.</i> , 2014 (61)	1	
		Liu <i>et al.</i> , 2012 (62)	1	
		Hood <i>et al.</i> , 2011 (63)	3	
		Oleksy <i>et al.</i> , 2010 (64)	1	
		Kosmas <i>et al.</i> , 2000 (65)	1	
		Kreusel <i>et al.</i> , 1999 (66)	2	
		Chen <i>et al.</i> , 1998 (67)	1	
		Paoli <i>et al.</i> , 1998 (68)	1	
		Gupta <i>et al.</i> , 1991 (69)	1	
		Thatcher <i>et al.</i> , 1975 (70)	42	58
Genital organs	Cervix	Pambuccian <i>et al.</i> , 2000 (71)	1	
		Nair <i>et al.</i> , 2009 (72)	1	
		Proença <i>et al.</i> , 2016 (73)	2	
		Toyoshima <i>et al.</i> , 2015 (74)	1	

Table 1 (continued)

Table 1 (continued)

Anatomical region	Site	Reference	Number	Tot.
		Bogliolo <i>et al.</i> , 2010 (75)	1	
		Mousavi <i>et al.</i> , 2007 (76)	1	
		Green <i>et al.</i> , 2004 (77)	1	
		Pauer <i>et al.</i> , 2003 (78)	1	
		Sinkre <i>et al.</i> , 2000 (79)	1	
		Kesavan <i>et al.</i> , 2000 (80)	1	
		Hepp <i>et al.</i> , 1999 (81)	1	
		Kennebeck <i>et al.</i> , 1998 (82)	2	
		Taxy <i>et al.</i> , 1994 (83)	1	
		Sanuki-Fujimoto <i>et al.</i> , 2008 (84)	4	19
	Endometrium	Kemp <i>et al.</i> , 1997 (85)	1	
		Moey <i>et al.</i> , 2016 (86)	1	
		Çift <i>et al.</i> , 2016 (87)	1	
		Rahmani <i>et al.</i> , 2018 (88)	1	
		Aytekin <i>et al.</i> , 2018 (89)	1	
		Briki <i>et al.</i> , 2018 (90)	2	
		Franco-Màrquez <i>et al.</i> , 2019 (91)	1	
		Ertas <i>et al.</i> , 2012 (92)	1	
		D'souza <i>et al.</i> , 2010 (93)	1	
		Karvouni <i>et al.</i> , 2009 (94)	1	
		Scopa <i>et al.</i> , 2005 (95)	2	
		Chehal <i>et al.</i> , 2002 (96)	1	
		Horn <i>et al.</i> , 2000 (97)	1	16
	Vulva	Gandhi <i>et al.</i> , 2015 (98)	1	
		Engelstaedter <i>et al.</i> , 2011 (99)	1	
		Sheen-Chen <i>et al.</i> , 2004 (100)	1	
		Curtin <i>et al.</i> , 1997 (101)	1	
		Valenzano Menada <i>et al.</i> , 2003 (102)	1	5
	Vagina	Pineda <i>et al.</i> , 1978 (103)	1	
		Bellati <i>et al.</i> , 2012 (104)	1	2
	Ovaries	Pambuccian <i>et al.</i> , 2000 (71)	1	
		Durga <i>et al.</i> , 2018 (105)	1	
		Fujii <i>et al.</i> , 2006 (106)	1	
		Sanuki-Fujimoto <i>et al.</i> , 2008 (84)	6	9
	Clitoris	Julien <i>et al.</i> , 2012 (107)	1	1

Table 1 (continued)

Table 1 (continued)

Anatomical region	Site	Reference	Number	Tot.		
Placenta		Alexander <i>et al.</i> , 2003 (108)	15			
		Froehlich <i>et al.</i> , 2018 (109)	1			
		Eltorky <i>et al.</i> , 1995 (110)	2			
		Sanuki-Fujimoto <i>et al.</i> , 2008 (84)	1	19		
Soft tissue	Skeletal muscle	Liu <i>et al.</i> , 2015 (111)	1			
		Khettab <i>et al.</i> , 2017 (112)	1			
		Almusarhed <i>et al.</i> , 2017 (113)	1			
		Salemis <i>et al.</i> , 2015 (114)	1			
		Khandelwal <i>et al.</i> , 2012 (115)	10			
		Surov <i>et al.</i> , 2010 (116)	2	16		
		Purkayastha <i>et al.</i> , 2016 (117)	1			
	Subcutaneous tissue	Rao <i>et al.</i> , 2015 (118)	1			
		Metere <i>et al.</i> , 2012 (119)	1			
		Plaza <i>et al.</i> , 2008 (120)	13	16		
		Intra-articular	Jaffe <i>et al.</i> , 2016 (121)	1	1	
			Head and neck	Paranasal sinus	Monserez <i>et al.</i> , 2001 (122)	1
		Pignataro <i>et al.</i> , 2001 (123)			1	
Asproudis <i>et al.</i> , 2004 (9)	1					
Fyrmpas <i>et al.</i> , 2008 (124)	1					
Reimann <i>et al.</i> , 2011 (125)	1					
Xiong <i>et al.</i> , 2017 (126)	1					
Walker <i>et al.</i> , 2013 (127)	1					
Marchioni <i>et al.</i> , 2004 (128)	1					
Pitkäranta <i>et al.</i> , 2001 (129)	1					
Austin <i>et al.</i> , 1995 (130)	9					
Gondim <i>et al.</i> , 2017 (15)	2					
Tiwari <i>et al.</i> , 2014 (131)	1					
Namad <i>et al.</i> , 2014 (132)	1					
Imre <i>et al.</i> , 2013 (133)	1					
Atasoy <i>et al.</i> , 2013 (134)	1	24				
Parotid gland	Ando <i>et al.</i> , 2011 (135)	1				
	Agrawal <i>et al.</i> , 2018 (136)	1				
	Cao <i>et al.</i> , 2018 (137)	1				
	Rawet <i>et al.</i> , 2017 (138)	1				
	Sellinger <i>et al.</i> , 2011 (139)	1				

Table 1 (continued)

Table 1 (continued)

Anatomical region	Site	Reference	Number	Tot.
		Dangore-K <i>et al.</i> , 2009 (140)	1	
		Perez-Fidalgo <i>et al.</i> , 2007 (141)	1	
		Zhang <i>et al.</i> , 2003 (142)	1	
		Sanuki-Fujimoto <i>et al.</i> , 2008 (84)	3	11
	Minor Salivary glands	Erra <i>et al.</i> , 2011 (143)	1	
		Cain <i>et al.</i> , 2001 (144)	1	2
	Tongue and lip	Suárez Roa <i>et al.</i> , 2007 (145)	2	
		Owosho <i>et al.</i> , 2016 (146)	1	3
	Tonsils	Bar <i>et al.</i> , 2011 (147)	1	
		Sera <i>et al.</i> , 2017 (148)	1	
		Maruzzo <i>et al.</i> , 2012 (149)	1	
		Barton <i>et al.</i> , 1980 (150)	1	
		Gondim <i>et al.</i> , 2017 (15)	1	5
	Pharynx and parapharyngeal space	Saab <i>et al.</i> , 1987 (151)	1	
		Copson <i>et al.</i> , 2018 (152)	1	
		Murhekar <i>et al.</i> , 2015 (153)	1	
		Raut <i>et al.</i> , 2001 (154)	1	
		Nguyen <i>et al.</i> , 1983 (155)	1	
		Agrawal <i>et al.</i> , 2015 (156)	1	6
	Larynx	Schuler <i>et al.</i> , 2010 (157)	1	
		Wanamaker <i>et al.</i> , 1993 (158)	1	2
	Nasal cavity	Weng <i>et al.</i> , 2014 (159)	1	
		Gondim <i>et al.</i> , 2017 (15)	1	
		Wanamaker <i>et al.</i> , 1993 (158)	1	3
	Ear	Pusiol <i>et al.</i> , 2013 (160)	1	
		Marques <i>et al.</i> , 2002 (161)	1	2
	Glomus	Çelik <i>et al.</i> , 2017 (162)	1	1
	Intravascular carcinomatosis	Takei <i>et al.</i> , 2015 (163)	1	1
	Lacrimal gland	Sanuki-Fujimoto <i>et al.</i> , 2008 (84)	1	1
	Oral cavity	Cooney <i>et al.</i> , 1988 (164)	1	
		Scipio <i>et al.</i> , 2001 (165)	1	
		Malhotra <i>et al.</i> , 2006 (166)	1	
		Eichhorn <i>et al.</i> , 2010 (167)	1	
		Kechagias <i>et al.</i> , 2012 (168)	1	
		Gondim <i>et al.</i> , 2017 (15)	3	

Table 1 (continued)

Table 1 (continued)

Anatomical region	Site	Reference	Number	Tot.
		Friedrich <i>et al.</i> , 2010 (169)	6	
		Rajesh <i>et al.</i> , 1998 (170)	1	15
	Thyroid	Yang <i>et al.</i> , 2014 (171)	1	
		Bourcier <i>et al.</i> , 2018 (172)	1	
		Ghias <i>et al.</i> , 2019 (173)	1	
		Kho <i>et al.</i> , 2018 (174)	1	
		Plonczak <i>et al.</i> , 2017 (175)	1	
		Debnam <i>et al.</i> , 2017 (176)	8	
		Magers <i>et al.</i> , 2016 (177)	1	
		Rossi <i>et al.</i> , 2015 (178)	5	
		HooKim <i>et al.</i> , 2015 (179)	3	
		Kolarević <i>et al.</i> , 2012 (180)	1	
		Calzolari <i>et al.</i> , 2008 (181)	1	
		Saber <i>et al.</i> , 2007 (182)	1	
		Leboeuf <i>et al.</i> , 2006 (183)	1	
		Gong <i>et al.</i> , 2005 (184)	1	
		Lam <i>et al.</i> , 1998 (185)	7	
		Ferrara <i>et al.</i> , 1997 (186)	1	
		Rosen <i>et al.</i> , 1978 (187)	1	39
		Sanuki-Fujimoto <i>et al.</i> , 2008 (84)	3	
	Parathyroid glands	Lee <i>et al.</i> , 2013 (188)	1	
		Watanabe <i>et al.</i> , 1983 (189)	1	2
	Pituitary gland	Ghosn <i>et al.</i> , 1991 <i>et al.</i> , (190)	1	
		Fukunaga <i>et al.</i> , 2014 (191)	1	
		Rozen <i>et al.</i> , 2007 (192)	1	
		Poursadegh Fard <i>et al.</i> , 2011 (193)	1	
		Nose <i>et al.</i> , 2018 (194)	1	
		Castle-Kirsbaum <i>et al.</i> , 2018 (195)	4	
		Kam <i>et al.</i> , 2017 (196)	1	
		Ravnik <i>et al.</i> , 2016 (197)	1	
		Burkhardt <i>et al.</i> , 2016 (198)	6	
		Gormally <i>et al.</i> , 2014 (199)	1	
		Magalhães <i>et al.</i> , 2014 (200)	1	
		Spinelli <i>et al.</i> , 2012 (201)	1	
		Naqi <i>et al.</i> , 2012 (202)	1	

Table 1 (continued)

Table 1 (continued)

Anatomical region	Site	Reference	Number	Tot.
		Dogan <i>et al.</i> , 2008 (203)	1	
		Gołkowski <i>et al.</i> , 2007 (204)	1	
		Kurkjian <i>et al.</i> , 2005 (205)	2	
		Sturm <i>et al.</i> , 2004 (206)	1	
		Ruiz Hernández <i>et al.</i> , 1996 (207)	1	
		Paulus <i>et al.</i> , 1990 (208)	1	
		Yap <i>et al.</i> , 1979 (209)	39	
		Sanuki-Fujimoto <i>et al.</i> , 2008 (84)	2	
		Teears <i>et al.</i> , 1975 (210)	35	104
	Jugular foramen (Villaret syndrome)	Flis <i>et al.</i> , 2015 (211)	1	1
	Cavernous sinus	Khaw <i>et al.</i> , 2012 (212)	1	1
Thoracic organs	Mediastinum	Kim <i>et al.</i> , 2018 (213)	1	
		Rampado <i>et al.</i> , 2007 (214)	25	26
	Thymus	Fukunaga <i>et al.</i> , 2017 (215)	1	
		Fujioka <i>et al.</i> , 2013 (216)	1	
		Park <i>et al.</i> , 2007 (217)	1	3
	Heart	Bhojwani <i>et al.</i> , 2016 (218)	1	
		Sandhu <i>et al.</i> , 2017 (219)	1	
		Bhambhani <i>et al.</i> , 2014 (220)	1	
		Katalinic <i>et al.</i> , 2013 (221)	1	
		Eminowicz <i>et al.</i> , 2011 (222)	1	
		Garg <i>et al.</i> , 2011 (223)	1	
		Kawase <i>et al.</i> , 2009 (224)	1	
		Broom <i>et al.</i> , 2006 (225)	1	
		Lieberman <i>et al.</i> , 1993 (226)	1	
		Labib <i>et al.</i> , 1992 (227)	2	11
Gastrointestinal tract	Esophagus	Wada <i>et al.</i> , 2009 (228)	1	
		Anaya <i>et al.</i> , 2006 (229)	1	
		Koike <i>et al.</i> , 2005 (230)	2	
		McLemore <i>et al.</i> , 2005 (231)	4	
		Sunada <i>et al.</i> , 2005 (232)	1	
		Erman <i>et al.</i> , 2002 (233)	1	
		Simchuk <i>et al.</i> , 2001 (234)	4	
		Varanasi <i>et al.</i> , 1995 (235)	4	
		Herrera <i>et al.</i> , 1992 (236)	1	

Table 1 (continued)

Table 1 (continued)

Anatomical region	Site	Reference	Number	Tot.
		Biller <i>et al.</i> , 1982 (237)	2	
		Sanuki-Fujimoto <i>et al.</i> , 2008 (84)	2	23
	Stomach	Ghosn <i>et al.</i> , 1991 (190)	1	
		Malhotra <i>et al.</i> , 2009 (238)	1	
		Hara <i>et al.</i> , 2010 (239)	1	
		Dòria <i>et al.</i> , 2015 (240)	1	
		Geredeli <i>et al.</i> , 2015 (241)	1	
		Ricciuti <i>et al.</i> , 2016 (242)	1	
		Dos Santos Fernandes <i>et al.</i> , 2016 (243)	4	
		Villa Guzmán <i>et al.</i> , 2017 (244)	1	
		Jmour <i>et al.</i> , 2017 (245)	4	
		Khan <i>et al.</i> , 2017 (246)	1	
		Kliiger <i>et al.</i> , 2017 (247)	1	
		Ulmer <i>et al.</i> , 2018 (248)	1	
		Bushan <i>et al.</i> , 2018 (249)	1	
		Güler <i>et al.</i> , 2019 (250)	1	
		Woo <i>et al.</i> , 2018 (251)	1	
		Kim <i>et al.</i> , 2018 (213)	1	
		Gurzu <i>et al.</i> , 2018 (252)	2	
		Yim <i>et al.</i> , 2017 (253)	1	
		Choi <i>et al.</i> , 2017 (254)	1	
		Mullally <i>et al.</i> , 2017 (255)	1	
		Rodrigues <i>et al.</i> , 2016 (256)	1	
		Zuhair <i>et al.</i> , 2015 (257)	1	
		Rachan Shetty <i>et al.</i> , 2015 (258)	2	
		Wysocka <i>et al.</i> , 2011 (259)	1	
		Critchley <i>et al.</i> , 2011 (260)	1	
		Almubarak <i>et al.</i> , 2011 (261)	35	
		Ghirarduzzi <i>et al.</i> , 2010 (262)	3	
		Yamamoto <i>et al.</i> , 2010 (263)	1	
		Trouillet <i>et al.</i> , 2010 (264)	4	
		Ellis <i>et al.</i> , 2009 (265)	4	
		Ciulla <i>et al.</i> , 2008 (266)	1	
		Jhaveri <i>et al.</i> , 2006 (267)	1	
		Savanis <i>et al.</i> , 2006 (268)	1	

Table 1 (continued)

Table 1 (continued)

Anatomical region	Site	Reference	Number	Tot.
		Whitty <i>et al.</i> , 2005 (269)	1	
		Akcali <i>et al.</i> , 2005 (270)	1	
		Tremblay <i>et al.</i> , 2002 (271)	1	
		Oda <i>et al.</i> , 2001 (272)	61 (autopsy)	
		Pera <i>et al.</i> , 2001 (273)	1	
		Washington <i>et al.</i> , 1995 (274)	20	
		McLemore <i>et al.</i> , 2005 (231)	11	
		Sanuki-Fujimoto <i>et al.</i> , 2008 (84)	6	185
	Duodenum	Houghton <i>et al.</i> , 1987 (275)	1	
		Sarkar <i>et al.</i> , 2002 (276)	1	
		Sato <i>et al.</i> , 2007 (277)	1	
		Jones <i>et al.</i> , 2015 (278)	1	
		Giestas <i>et al.</i> , 2016 (279)	1	
		Lin <i>et al.</i> , 2019 (280)	1	
		Wang <i>et al.</i> , 2018 (281)	1	
		Zhao <i>et al.</i> , 2012 (282)	1	
		Asoglu <i>et al.</i> , 2006 (283)	1	
		Lottini <i>et al.</i> , 2002 (284)	1	
		Titus <i>et al.</i> , 1997 (285)	1	11
	Small bowel	Hernández <i>et al.</i> , 2000 (286)	1	
		Choi <i>et al.</i> , 2011 (287)	1	
		Khan <i>et al.</i> , 2017 (246)	1	
		Liu <i>et al.</i> , 2018 (288)	1	
		Bilen <i>et al.</i> , 2012 (289)	1	
		Cho <i>et al.</i> , 2011 (290)	1	
		Mouawad <i>et al.</i> , 2011 (291)	1	
		Kelly <i>et al.</i> , 2009 (292)	1	
		Oyasiji <i>et al.</i> , 2009 (293)	1	
		Al-Qahatani <i>et al.</i> , 2007 (294)	1	
		McLemore <i>et al.</i> , 2005 (231)	14	24
	Colon-rectum	Wang <i>et al.</i> , 2014 (159)	1	
		Haberstich <i>et al.</i> , 2005 (295)	1	
		Malhotra <i>et al.</i> , 2009 (238)	1	
		Titi <i>et al.</i> , 2010 (296)	1	
		Okido <i>et al.</i> , 2011 (297)	1	

Table 1 (continued)

Table 1 (continued)

Anatomical region	Site	Reference	Number	Tot.
		Saranovic <i>et al.</i> , 2011 (298)	1	
		Mistrangelo <i>et al.</i> , 2011 (299)	1	
		Villa Guzmán <i>et al.</i> , 2016 (244)	1	
		Cherian <i>et al.</i> , 2017 (300)	1	
		Khan <i>et al.</i> , 2017 (246)	1	
		Falco <i>et al.</i> , 2018 (301)	1	
		Blachman-Braun <i>et al.</i> , 2019 (302)	1	
		Samra <i>et al.</i> , 2019 (303)	1	
		Schellenberg <i>et al.</i> , 2018 (304)	1	
		Ruymbeke <i>et al.</i> , 2018 (305)	1	
		Tsujimura <i>et al.</i> , 2017 (306)	1	
		Buka <i>et al.</i> , 2016 (307)	1	
		Rengifo <i>et al.</i> , 2016 (308)	1	
		Mroz <i>et al.</i> , 2015 (309)	1	
		Zhou <i>et al.</i> , 2012 (310)	1	
		Takeuchi <i>et al.</i> , 2012 (311)	1	
		Bochicchio <i>et al.</i> , 2012 (312)	1	
		Gerova <i>et al.</i> , 2012 (313)	1	
		Nikolic <i>et al.</i> , 2012 (314)	1	
		Amin <i>et al.</i> , 2011 (315)	1	
		Razzetta <i>et al.</i> , 2011 (316)	1	
		Critchley <i>et al.</i> , 2011 (260)	1	
		Efthimiadis <i>et al.</i> , 2011 (317)	1	
		Balja <i>et al.</i> , 2010 (318)	1	
		Thèraux <i>et al.</i> , 2009 (319)	1	
		Birla <i>et al.</i> , 2008 (320)	1	
		Uygun <i>et al.</i> , 2006 (321)	1	
		Savanis <i>et al.</i> , 2006 (268)	1	
		Signorelli <i>et al.</i> , 2005 (322)	1	
		McLemore <i>et al.</i> , 2005 (231)	18	
		Law <i>et al.</i> , 2003 (323)	1	
		Dhar <i>et al.</i> , 2003 (324)	1	
		Barnias <i>et al.</i> , 2001 (325)	1	
		Koutsomanis <i>et al.</i> , 2000 (326)	1	
		Flamme <i>et al.</i> , 1994 (327)	1	

Table 1 (continued)

Table 1 (continued)

Anatomical region	Site	Reference	Number	Tot.
		Rabau <i>et al.</i> , 1988 (328)	1	
		Balibrea <i>et al.</i> , 2007 (329)	1	59
Abdominal organs	Appendix	Dirksen <i>et al.</i> , 2010 (330)	1	1
		Pancreas		
		Hardt <i>et al.</i> , 1993 (331)	1	
		Stoeckler <i>et al.</i> , 2007 (332)	1	
		Bonapasta <i>et al.</i> , 2010 (333)	1	
		Takamizawa <i>et al.</i> , 2011 (334)	1	
		Inoue <i>et al.</i> , 2018 (335)	1	
		Sun <i>et al.</i> , 2017 (336)	1	
		Song <i>et al.</i> , 2014 (337)	1	
		Molino <i>et al.</i> , 2014 (338)	1	
		Razzetta <i>et al.</i> , 2011 (316)	1	
		Lam <i>et al.</i> , 2011 (339)	1	
		Mourra <i>et al.</i> , 2010 (340)	1	
		Ang <i>et al.</i> , 2007 (341)	1	
		Crippa <i>et al.</i> , 2006 (342)	3	
		Haque <i>et al.</i> , 2005 (343)	1	
		Z'graggen <i>et al.</i> , 1998 (344)	1	
		Mountney <i>et al.</i> , 1997 (345)	1	
		Sanuki-Fujimoto <i>et al.</i> , 2008 (84)	6	
		Peritoneum	Kliiger <i>et al.</i> , 2017 (247)	1
	Saranovic <i>et al.</i> , 2011 (298)		1	
	Shan <i>et al.</i> , 2016 (346)		1	
	Osaku <i>et al.</i> , 2015 (347)		1	
	Cardi <i>et al.</i> , 2013 (348)		5	
	D'Annibale <i>et al.</i> , 2007 (349)		1	
	Kobayashi <i>et al.</i> , 2007 (350)		1	
	McLemore <i>et al.</i> , 2005 (231)		50	
	Sanuki-Fujimoto <i>et al.</i> , 2008 (84)		27	87
	Gallbladder		Doval <i>et al.</i> , 2006 (351)	1
		Markelov <i>et al.</i> , 2011 (352)	1	
		Di Vita <i>et al.</i> , 2011 (353)	1	
		Urade <i>et al.</i> , 2019 (354)	1	
		Zamkowski <i>et al.</i> , 2017 (355)	1	
		Abdelilah <i>et al.</i> , 2014 (356)	1	

Table 1 (continued)

Table 1 (continued)

Anatomical region	Site	Reference	Number	Tot.
		Manouras <i>et al.</i> , 2008 (357)	1	
		Zagouri <i>et al.</i> , 2007 (358)	1	8
	Spleen	Bartolotti <i>et al.</i> , 2012 (359)	1	
		El Fadli <i>et al.</i> , 2017 (360)	1	
		Sufficool <i>et al.</i> , 2013 (361)	1	
		Foroudi <i>et al.</i> , 1999 (362)	1	
		Chapel <i>et al.</i> , 1999 (363)	1	
		Cummings <i>et al.</i> , 1992 (364)	2	
		Sanuki-Fujimoto <i>et al.</i> , 2008 (84)	2	9
	Kidney	Kykalos <i>et al.</i> , 2010 (365)	1	
		Mhamdi <i>et al.</i> , 2017 (366)	1	
		Nasu <i>et al.</i> , 2015 (367)	1	
		Karczmarek-Borowska <i>et al.</i> , 2015 (368)	1	
		Wu <i>et al.</i> , 2015 (369)	6	
		Herzberg <i>et al.</i> , 1991 (370)	1	
		Sanuki-Fujimoto <i>et al.</i> , 2008 (84)	1	12
	Bladder	Al Ibraheemi <i>et al.</i> , 2016 (371)	1	
		Jordan <i>et al.</i> , 2018 (372)	1	
		Kase <i>et al.</i> , 2018 (373)	1	
		Xiao <i>et al.</i> , 2012 (374)	3	
		Vulcano <i>et al.</i> , 2010 (375)	1	
		Gatti <i>et al.</i> , 2005 (376)	1	
		Soon <i>et al.</i> , 2004 (377)	1	
		Elia <i>et al.</i> , 1999 (378)	1	10
	Ureter	Gabsi <i>et al.</i> , 2018 (379)	1	
		Zunarelli <i>et al.</i> , 1995 (380)	1	2
	Adrenal gland	Mizuyama <i>et al.</i> , 2013 (381)	1	
		Andjelic-Dekic <i>et al.</i> , 2014 (382)	1	
		Paunovic <i>et al.</i> , 2014 (383)	1	
		Demirci <i>et al.</i> , 2011 (384)	1	
		Liu <i>et al.</i> , 2010 (385)	1	
		Bausewein <i>et al.</i> , 2006 (386)	1	
		Davì <i>et al.</i> , 1996 (387)	1	
		Sanuki-Fujimoto <i>et al.</i> , 2008 (84)	2	9
	Retroperitoneum	Sanuki-Fujimoto <i>et al.</i> , 2008 (84)	16	

Table 1 (continued)

Table 1 (continued)

Anatomical region	Site	Reference	Number	Tot.
		Kim <i>et al.</i> , 2018 (213)	1	17
	Pelvis	Shan <i>et al.</i> , 2016 (346)	1	
		Colak <i>et al.</i> , 2005 (388)	1	2
Nervous System	Meninges	Kashiwagi <i>et al.</i> , 2012 (389)	4	
		Laurencet <i>et al.</i> , 2000 (390)	1	
		Higashi <i>et al.</i> , 2000 (391)	1	
		Mego <i>et al.</i> , 2011 (392)	2	
		Rao <i>et al.</i> , 2017 (393)	15	
		Alnajjar <i>et al.</i> , 2017 (394)	19	
		Seki <i>et al.</i> , 2016 (395)	1	
		Pan <i>et al.</i> , 2015 (396)	1	
		Meattini <i>et al.</i> , 2012 (397)	33	
		Tseng <i>et al.</i> , H. 2003 (398)	1	
		Kosmas <i>et al.</i> , 2000 (65)	1	
		Jayson <i>et al.</i> , 1994 (399)	35	
		Sanuki-Fujimoto <i>et al.</i> , 2008 (84)	16	
		Madgula <i>et al.</i> , 2014 (400)	1	125
	Intramedullary spinal cord	Higashi <i>et al.</i> , 2000 (391)	1	
		Gasser <i>et al.</i> , 2001 (401)	1	
		Choi <i>et al.</i> , 2010 (402)	1	
		Garcia <i>et al.</i> , 2016 (403)	1	
		Aiello <i>et al.</i> , 2017 (404)	1	
		Payer <i>et al.</i> , 2015 (405)	3	
		Hsu <i>et al.</i> , 2013 (406)	1	
		Zebrowski <i>et al.</i> , 2010 (407)	3	
		Watanabe <i>et al.</i> , 2006 (408)	1	
		Villegas <i>et al.</i> , 2004 (409)	1	
		Chen <i>et al.</i> , 1995 (410)	1	
		Schwechheimer <i>et al.</i> , 1985 (411)	1	
		Moffie <i>et al.</i> , 1980 (412)	1	
		West <i>et al.</i> , 1979 (413)	1	18
	Intraventricular	Della Puppa <i>et al.</i> , 2010 (414)	1	
		Sajko <i>et al.</i> , 2009 (415)	1	2
	Cerebellum	Saha <i>et al.</i> , 2018 (416)	1	
		Singh <i>et al.</i> , 2015 (417)	1	

Table 1 (continued)

Table 1 (continued)

Anatomical region	Site	Reference	Number	Tot.
		Rowe <i>et al.</i> , 2015 (418)	1	
		Higashi <i>et al.</i> , 2000 (391)	1	4
	Peripheral nervous system	Artico <i>et al.</i> , 1991 (419)	1	
		Backhouse <i>et al.</i> , 1998 (420)	1	
		Cherekaev <i>et al.</i> , 2013 (421)	1	
		Suryanarayanan <i>et al.</i> , 2005 (422)	1	
		Ito <i>et al.</i> , 2010 (423)	1	
		Schulz <i>et al.</i> , 2009 (424)	1	
		Zingale <i>et al.</i> , 2002 (425)	1	
		Hirota <i>et al.</i> , 1998 (426)	1	
		Breadon <i>et al.</i> , 1977 (427)	1	9
	Brainstem	Reyes <i>et al.</i> , 2011 (428)	1	1
	Brain	de Ceuster <i>et al.</i> , 2016 (429)	1	
		Chakrabarti <i>et al.</i> , 2013 (430)	1	
		Kashiwagi <i>et al.</i> , 2012 (389)	3	
		Low <i>et al.</i> , 2012 (431)	1	
		Modi <i>et al.</i> , 2006 (432)	1	
		Saisho <i>et al.</i> , 2005 (433)	2	
		Higashi <i>et al.</i> , 2000 (391)	4	
		Chou <i>et al.</i> , 1998 (434)	1	
		Koller <i>et al.</i> , 1986 (435)	1	15

it is less common to find BC metastasis in other remote sites. In this review we mainly focused on anatomical sites where few cases of metastases have been reported in literature.

In clinical practice the knowledge of common sites of metastases helps the physician to detect early symptoms corresponding to secondary lesions, however when BC metastasizes in less expected sites the diagnosis could be delayed.

BC is amongst the most common tumours to metastasize to the head and neck, it constitutes ~15–20% of all metastases to this region and has been described in almost every head and neck anatomic subsite. However, since metastases to the head and neck are uncommon to begin with, breast carcinoma metastases are still relatively rare in clinical practice. Parenchymal metastases to

the submandibular and parotid glands can be difficult to distinguish from new primary tumors arising there, specifically salivary duct carcinoma. In these cases immunohistochemistry only can help differential diagnosis (15). Among metastatic orbital neoplasms, BC is the most common primary tumour, in particular, 55 cases were reported as affecting orbital soft tissue and 55 cases choroid, being bilateral in less than 1% of cases (1/55). A median time to onset of orbital metastases from BC diagnosis is 4.5–6.5 years and the majority of these patients have ER positive Her2 positive BC. A biological explanation for this tropism might be that steroid hormones, needed for tear production are produced in the orbital fat or in alternative, orbital metastases could be a late complication in patients with slow growing ER positive disease (17). Whether there is a tropism of lobular cancer cells to the orbital tissue or this is

purely due to the more infiltrative nature of this tumor type along with its general tendency for spreading to myriad body sites is a matter of speculation (18). Prognosis in cases of orbital metastases from BC is determined by metastatic burden. A mean survival time of 5–22 months after orbital diagnosis has been reported in the literature. Furthermore, orbital metastases can cause various local problems, such as exophthalmos, exposure keratitis, optic neuropathy, and limited extraocular muscle motion. As enucleation confers no benefit in terms of survival, external beam radiotherapy is the most commonly used palliative treatment (16). Although BC rarely metastasizes to the head and neck region, awareness should be raised when BC patients experience headache or have sinus-related symptoms. The most of these patients have very poor prognosis, however chemotherapy and radiotherapy may be effective to prolong survival (126). Despite the principle that metastatic deposits have a predilection for highly vascularized organs, the thyroid is rarely a metastatic site. We found 39 cases of BC metastasis to the thyroid gland reported in literature, the true prevalence oscillates from 3% to 34% of all thyroid metastases, whilst it is much more common to find synchronous or metachronous malignancies (84,170–187). The suspicion of metastatic disease should be raised by thyroid lumps in BC survivors, although indicating poor prognosis, the role of surgery in these lesions should be considered for local disease to control, palliate and prevent the potential morbidity on the airway (441,442).

Despite the well-known BC propensity to spread to the central nervous system, the prevalence of symptomatic central nervous system metastases among patients with BC ranges from 5% to 16%, although autopsic studies have reported prevalence rates of up to 30% (414). In our review we found 18 cases of intramedullary spinal cord metastases (see *Table 1*). The mechanism of intramedullary spread is not well established but it may involve lymphatic or haematological transit, direct spread from the vertebrae or ‘drop-down’ metastases from the brain. The most common symptoms are paresis and dysesthesia or bladder dysfunction, both surgery and radiotherapy are recommended both for diagnosis and treatment of brain metastases (405). Interestingly, Zebrowski *et al.* (407) suggested a potential association between the inability of trastuzumab to cross the blood-brain barrier and the occurrence of intramedullary metastases in Her2 positive disease. Additionally, some studies report a predisposition of lobular histotype to leptomeningeal carcinomatosis, whilst in the case of ductal carcinoma spreading to the meninges a high

histological grade and triple-negative biology seems to be prevalent (394).

Although very rare (9 cases reported), metastasis to the spinal nerve root ganglion can be the first manifestation of distant hematogenous metastases of BC. The clinical course is characterized by increasing radicular symptoms-especially intractable pain. Surgical intervention with tumour debulking followed by radiotherapy provides local tumour control and palliation from pain (422–425).

Soft tissue metastasis from any primary malignancy is considered very rare, it can be in subcutaneous and muscular tissue (117). In this review we found 33 cases of soft tissues metastases involving skeletal muscle or subcutaneous tissue or both of the upper and lower limbs, trunk, shoulders, and buttocks (117–120). Some studies have reported a frequency of 0.8% based on autopsies while few reported an incidence of 0.2% based on clinical studies (443,444). This rarity can be due to the fact that soft tissues produce anti-carcinogenic factors like lactic acid, beta adrenergic receptors or protease inhibitors which serve as a deterrent for metastatic invasion (116,445,446). As for other metastatic sites a multimodality approach generally is adopted depending upon the performance status of the patient, any comorbid condition, type of primary malignancy, site and size of the metastatic lesion. RT and chemotherapy have been generally considered the primary modality of therapy either in combination or separately while surgery is reserved for patients not responding to radiation or chemotherapy. A high degree of clinical suspicion and immuno-histopathological confirmation are required to identify and diagnose any soft tissue swelling of the body in a previously treated primary breast cancer patient to prevent any inappropriate treatment causing undue morbidity or even mortality (117).

Gastrointestinal (GI) tract metastases from BC are also considered rare, their incidence in autopsy series varied from 8% to 35% (274,447). This localization can easily simulate a primary GI cancer and any region of the GI tract can be involved, from the tongue (145) to the anus (448). Most series report a greater propensity of lobular carcinoma to metastasize to the GI tract and peritoneum, but data on this tropism are poor and inconclusive (231,449,450). The most common site of GI tract metastasis is the stomach, 185 cases in our review. Colon involvement is quite common (59 cases), whilst small intestine involvement has been reported in 24 cases and is more frequently diagnosed at autopsy. In particular, ductal carcinoma seems to produce nodular stomach lesions, while lobular BC tend to cause

more diffuse disease (451). The GI tract metastases are uncommon and peculiar, the main issue is to identify symptoms like nausea, vomiting, diarrhoea or abdominal pain and start the differential diagnosis with CT scan, endoscopy and biopsy. According to literature reports, surgery is crucial when possible, nevertheless chemotherapy and endocrine therapy were commonly used, very rarely radiotherapy can also play a role (452). Other abdominal organs are also rare sites of BC metastasis often mimicking primary tumours, so the final diagnosis occurs after biopsy or surgical excision.

BC metastases can also involve genital organs and the placenta. Most cases of uterine metastases presents as vaginal bleeding or abdominal discomfort, although the vast majority of these have been diagnosed during autopsy (78,453). Studies have showed that the incidence of ovarian metastases in BC patients is 13–47%. It seems that the metastatic lesions reach the ovaries and genital organs through the lymphatic and blood vessels, or through trans-coelomic spread, then the reciprocal interaction between intrinsic BC molecular characteristics and the local microenvironment explains the metastatic organotropism (103,454). The most common sign of uterine or vaginal metastases is vaginal bleeding, while ovarian metastases frequently present as an asymptomatic ovarian mass (455,456). In any case, the central task is to differentiate primary versus secondary tumours, as this will affect the clinical decision process, treatment and prognosis. The surgical metastasis excision, hysterectomy or oophorectomy not only provide diagnostic information, but they could also have a curative effect along with systemic therapy (104). The local control of bleeding can also benefit from radiation therapy, uterine artery embolization and conisation (73). However, genital tract and ovarian metastases represent the late stage of a systemic disease, for instance BC patients with ovarian metastases have a 6–26% 5-year survival rate (106,454,457). The lack of symptoms and poor outcomes emphasize the relevance of a regular gynaecological surveillance in all BC survivors, despite guidelines citing different approaches (73). In 2003, Alexander *et al.* (108) have reported the most comprehensive review of placental involvement (15 cases), where BC cells were located in the intervillous space without any involvement of the fetal villous stroma and vascular circulation. Fetal immune response seems to play a key role in avoiding the fetal involvement when possible, although maternal prognosis remains very poor (109,110). Malignant disease in pregnancy provoke a challenging

situation for gynaecologists, breast surgeons, oncologists and neonatologists, all placentas should be evaluated by pathologists and each single case of metastasis should be discussed within a multidisciplinary team (109).

The analysis of BC metastatic pattern has shown that lobular tumours were more likely to metastasize to the peritoneum, adrenal glands, uterus and pleural surface (458). Additionally, the aggressiveness of lobular carcinoma seems to be associated to metastasis at unusual sites, in particular meningeal dissemination was more frequently associated to lobular BC (459–462). A retrospective study on 3783 patients about the distribution and frequency of metastases at unusual sites showed that the majority of unusual metastases are associated with prior metastases at more unusual sites, which appear, on average, 1 year before. The prognosis of metastatic BC patients was the same irrespective of the metastasis site and no risk factors for unusual metastasis were identified (84). In general, it is uncommon to find isolated rare metastases, the vast majority of the rare metastases described develop together with metastases in other sites, thus highlighting a worsening systemic disease.

Conclusions

Despite the improvements in diagnosis, surgical techniques, general patient care, and local and systemic adjuvant therapies, most deaths from cancer result from metastases that are resistant to conventional therapies. The process of cancer metastasis is sequential and selective and incorporates stochastic elements, hence the growth of metastases represents the endpoint of the interplay of tumour cells with host factors.

On the research level, the recent advances in our understanding of the metastatic process at the cellular and molecular level provide unprecedented potential for the improvement and the development of effective adjuvant therapies.

On the clinical level, the early diagnosis of secondary lesions represents the only chance to control the disease and prolong survival, hence the knowledge of the common as well as rare sites of metastases can help the physician to detect symptoms and plan the most appropriate treatment.

Acknowledgments

Funding: None.

Footnote

Provenance and Peer Review: This article was commissioned by the Guest Editors (Emanuela Esposito and Micheline De Laurentiis) for the focused issue “Rare Tumors of the Breast” published in *Translational Cancer Research*. This article has undergone external peer review.

Conflicts of Interest: All authors have completed the ICMJE uniform disclosure form (available at <http://dx.doi.org/10.21037/tcr.2019.07.24>). The focused issue “Rare Tumors of the Breast” was commissioned by the editorial office without any funding or sponsorship. The authors have no other conflicts of interest to declare.

Ethical Statement: The authors are accountable for all aspects of the work in ensuring that questions related to the accuracy or integrity of any part of the work are appropriately investigated and resolved.

Open Access Statement: This is an Open Access article distributed in accordance with the Creative Commons Attribution-NonCommercial-NoDerivs 4.0 International License (CC BY-NC-ND 4.0), which permits the non-commercial replication and distribution of the article with the strict proviso that no changes or edits are made and the original work is properly cited (including links to both the formal publication through the relevant DOI and the license). See: <https://creativecommons.org/licenses/by-nc-nd/4.0/>.

References

1. Bray F, Ferlay J, Soerjomataram I, et al. Global cancer statistics 2018: GLOBOCAN estimates of incidence and mortality worldwide for 36 cancers in 185 countries. *CA Cancer J Clin* 2018;68:394-424.
2. Runowicz CD, Leach CR, Henry NL, et al. American Cancer Society/American Society of Clinical Oncology Breast Cancer Survivorship Care Guideline. *J Clin Oncol* 2016;34:611-35.
3. Rosselli Del Turco M, Palli D, Cariddi A, et al. Intensive diagnostic follow-up after treatment of primary breast cancer. A randomized trial. National Research Council Project on Breast Cancer follow-up. *JAMA* 1994;271:1593-7.
4. Palli D, Russo A, Saieva C, et al. Intensive vs clinical follow-up after treatment of primary breast cancer: 10-year update of a randomized trial. National Research Council Project on Breast Cancer Follow-up. *JAMA* 1999;281:1586.
5. Gradishar WJ, Anderson BO, Balassanian R, et al. Breast Cancer, Version 4.2017, NCCN Clinical Practice Guidelines in Oncology. *J Natl Compr Canc Netw* 2018;16:310-20.
6. Khatcheressian JL, Hurley P, Bantug E, et al. Breast cancer follow-up and management after primary treatment: American Society of Clinical Oncology clinical practice guideline update. *J Clin Oncol* 2013;31:961-5.
7. Fauci AS, Hauser SL, Jameson JL, et al. *Harrison's Manual of Medicine*, 19e. 19th ed. McGraw-Hill's AccessMedicine. New York, NY: McGraw-Hill Education LLC, 2016.
8. Reeves D, Levine MR, Lash R. Nonpalpable breast carcinoma presenting as orbital infiltration: case presentation and literature review. *Ophthalmic Plast Reconstr Surg* 2002;18:84-8.
9. Asproudis I, Gorezis S, Charalabopoulos K, et al. Breast carcinoma metastasis to the orbit and paranasal sinuses: a case report. *Exp Oncol* 2004;26:246-8.
10. Eckardt AM, Rana M, Essig H, et al. Orbital metastases as first sign of metastatic spread in breast cancer: case report and review of the literature. *Head Neck Oncol* 2011;3:37.
11. Mora-Guzmán I, Maqueda González R, Doblado Cardellach B, et al. Isolated orbital metastasis as an initial presentation of a breast cancer. *Cir Esp* 2018;96:119.
12. Maliepaard M, Mesham M, Aleksic Z, et al. Ocular metastasis as initial presentation in breast cancer. *S Afr Med J* 2017;107:694-6.
13. Spraker MB, Francis CE, Korde L, et al. Solitary Orbital Metastasis 35 Years after a Diagnosis of Lobular Carcinoma in Situ. *Cureus* 2017;9:e1404.
14. Pinto Proença R, Fernandes J, Burnier MN, et al. Orbital metastasis from an occult breast carcinoma (T0, N1, M1). *BMJ Case Rep* 2018. doi: 10.1136/bcr-2017-223542.
15. Gondim DD, Chernock R, El-Mofty S, et al. The Great Mimicker: Metastatic Breast Carcinoma to the Head and Neck with Emphasis on Unusual Clinical and Pathologic Features. *Head Neck Pathol* 2017;11:306-13.
16. Kim JH, Choi SY, Cho CK, et al. Bilateral orbital metastases from breast cancer: a case report of successful palliation using stereotactic radiotherapy. *Breast J* 2011;17:669-71.
17. Pierson TM, Tebit EV, El Sayed A, et al. Orbital Metastases from Breast Cancer: Retrospective Analysis at an Academic Cancer Center. *Breast J* 2016;22:447-50.
18. Raap M, Antonopoulos W, Dämmrich M, et al. High frequency of lobular breast cancer in distant metastases to

- the orbit. *Cancer Med* 2015;4:104-11.
19. Zwicker F, Herfarth K, Welzel T, et al. Palliative radiotherapy of retrobulbar orbit metastases due to breast cancer. *Onkologie* 2008;31:529-33.
 20. Torres JJ, Medel R, Alonso T, et al. Orbital metastases from male breast cancer in two cases. *Ophthalmic Plast Reconstr Surg* 2007;23:154-6.
 21. Schick U, Lermen O, Hassler W. Management of orbital metastases. *Zentralbl Neurochir* 2006;67:1-7.
 22. Dieing A, Schulz CO, Schmid P, et al. Orbital metastases in breast cancer: report of two cases and review of the literature. *J Cancer Res Clin Oncol* 2004;130:745-8.
 23. Amemiya T, Hayashida H, Dake Y. Metastatic orbital tumors in Japan: a review of the literature. *Ophthalmic Epidemiol* 2002;9:35-47.
 24. Rossi L, Zancla S, Civitelli L, et al. An unusual orbital metastasis of breast cancer. *Breast Dis* 2014;34:173-6.
 25. Bajcsay A, Kontra G, Récsán Z, et al. Lens-sparing external beam radiotherapy of intraocular metastases: our experiences with twenty four eyes. *Neoplasma* 2003;50:459-64.
 26. Murthy R, Gupta A, Hegde S, et al. Bilateral multiple extraocular muscle metastasis from breast carcinoma. *Indian J Ophthalmol* 2011;59:381-2.
 27. Chang YC, Hsieh TC, Kao CH. Single Ophthalmic Metastasis After Definitive Therapy of Locoregional Breast Cancer. *Am J Med Sci* 2017;354:440.
 28. Nifosí G, Zuccarello M. Unilateral localized extraocular muscle metastasis by lobular breast carcinoma. *BMJ Case Rep* 2018. doi: 10.1136/bcr-2018-224726.
 29. Framarino-Dei-Malatesta M, Chiarito A, Bianciardi F, et al. Metastases to extraocular muscles from breast cancer: case report and up-to-date review of the literature. *BMC Cancer* 2019;19:36.
 30. Weiss R, Grisold W, Jellinger K, et al. Metastasis of solid tumors in extraocular muscles. *Acta Neuropathol* 1984;65:168-71.
 31. Lell M, Schulz-Wendtland R, Hafner A, et al. Bilateral orbital tumour as the presentation of mammographically occult breast cancer. *Neuroradiology* 2004;46:682-5.
 32. Kouvaris JR, Gkongkou PV, Papadimitriou CA, et al. Bilateral metastases to extraocular muscles from lobular breast carcinoma. *Onkologie* 2008;31:387-9.
 33. Spitzer SG, Bersani TA, Mejico LJ. Multiple bilateral extraocular muscle metastases as the initial manifestation of breast cancer. *J Neuroophthalmol* 2005;25:37-9.
 34. van der Heijden A, Twijnstra A, Lamers WP, et al. An unusual cause of diplopia in a cancer patient. *Eur J Cancer* 1991;27:1315-6.
 35. Glazer LC, Harris GJ, Simons KB. Orbital metastasis as the presenting sign of adenocarcinoma of the breast. *Ophthalmic Plast Reconstr Surg* 1991;7:252-5.
 36. Correa de Mello P, Brasil OFM. Isolated Retinal Metastasis From Breast Cancer. *Retina* 2017;37:e125-e7.
 37. Shields JA, Shields CL, Kiratli H, et al. Metastatic tumors to the iris in 40 patients. *Am J Ophthalmol* 1995;119:422-30.
 38. Shah RK, Lamichhane S. Ocular metastasis from breast carcinoma simulating anterior scleritis: a case report. *J Med Case Rep* 2017;11:249.
 39. Biswas J, Ho TC, Bhavsar K. Bilateral metastasis to the retina, choroids and optic nerve from breast cancer: a clinicopathological case. *Indian J Ophthalmol* 2007;55:71-2.
 40. Sirimaharaj M, Hunyor AP, Chan WC, et al. Unusual ocular metastasis from breast cancer. *Clin Exp Ophthalmol* 2006;34:74-6.
 41. Schlaen ND, Naves AE. Orbital and choroidal metastases from carcinoma of the male breast. *Arch Ophthalmol* 1986;104:1344-6.
 42. Skalicky SE, Hirst LW, Conway RM. Metastatic breast carcinoma presenting as a conjunctival lesion. *Clin Exp Ophthalmol* 2007;35:767-9.
 43. Sánchez Orgaz M, Gonzalez Pessolani T, Pozo Kreilinger JJ, et al. Orbital and conjunctival metastasis from lobular breast carcinoma. *Orbit* 2017;36:197-200.
 44. Radovanović AB, Rasić D, Buta M, et al. Breast cancer metastasis to the conjunctiva. *Vojnosanit Pregl* 2013;70:331-4.
 45. Kiratli H, Shields CL, Shields JA, et al. Metastatic tumours to the conjunctiva: report of 10 cases. *Br J Ophthalmol* 1996;80:5-8.
 46. Kaur G, Ismail R, Harun H. Metastatic mucinous carcinoma of the eyelid. *Malays J Pathol* 2005;27:117-8.
 47. Martorell-Calatayud A, Requena C, Díaz-Recuero JL, et al. Mask-like metastasis: report of 2 cases of 4 eyelid metastases and review of the literature. *Am J Dermatopathol* 2010;32:9-14.
 48. Goodier MA, Jordan JR. Metastatic breast cancer to the lower eyelid. *Laryngoscope* 2010;120 Suppl 4:S129.
 49. Kuo SC, Hsiao SC, Chiou CC, et al. Metastatic carcinoma of the breast: a case with the unusual presentation of unilateral periorbital edema. *Jpn J Ophthalmol* 2008;52:305-7.
 50. Douglas RS, Goldstein SM, Einhorn E, et al. Metastatic breast cancer to 4 eyelids: a clinicopathologic report. *Cutis*

- 2002;70:291-3.
51. Claessens N, Rakic L, Arrese JE, et al. Breast cancer metastatic to the eyelids. *Eur J Dermatol* 2000;10:473-4.
 52. Rosenblum GA. Metastatic breast cancer in the eyelid. *Cutis* 1983;31:411-5, 7.
 53. Lawton RL, Hobbs B, Jochimsen P. Metastases to eyelids: breast. *J Surg Oncol* 1980;13:117-20.
 54. Ozturk B, Buyukberber S, Coskun U, et al. Solitary iris metastasis from breast cancer with dramatic course: case report. *Med Oncol* 2007;24:463-5.
 55. Mennel RG. Ocular metastases from breast cancer. *Clin Breast Cancer* 2001;1:318-9.
 56. Reddy SC, Madhavan M, Mutum SS. Anterior uveal and episcleral metastases from carcinoma of the breast. *Ophthalmologica* 2000;214:368-72.
 57. Williams NJ, Leris AC, Kouriefs C, et al. Choroidal metastasis-the initial presentation of breast carcinoma. *Eur J Surg Oncol* 2000;26:817-8.
 58. Solav S, Bhandari R, Sowani A, et al. Choroidal metastasis from carcinoma of breast detected on F18-FDG PET CT scan: A case report and review of literature. *Indian J Nucl Med* 2010;25:160-3.
 59. Arya M, Duker JS. Vinorelbine-induced regression of a choroidal metastasis from primary breast carcinoma. *Int J Retina Vitreous* 2018;4:17.
 60. Luo Z, Cai Q, Zhao Y, et al. Late distant recurrence of breast carcinoma and metastasis to the main bronchus and choroid: A case report. *Medicine (Baltimore)* 2018;97:e10754.
 61. Antosz ZS, Walocha J, Poręba R, et al. Sudden loss of vision due to breast cancer metastasis to the eyeball. *Neuro Endocrinol Lett* 2014;35:249-51.
 62. Liu T, Xu Y, Wan L, et al. Choroid as the first recurrence site: 13 years after breast carcinoma. *J Cancer Res Ther* 2012;8:639-40.
 63. Hood CT, Budd GT, Zakov ZN, et al. Male breast carcinoma metastatic to the choroid: report of 3 cases and review of the literature. *Eur J Ophthalmol* 2011;21:459-67.
 64. Oleksy P, Pogrzebielski A, Karska-Basta I, et al. A case of choroidal metastasis in a male breast cancer. *Klin Oczna* 2010;112:311-3.
 65. Kosmas C, Malamos NA, Antonopoulos M. Complete regression of choroidal metastases from breast cancer after docetaxel-based systemic chemotherapy. *Med Pediatr Oncol* 2000;34:229-30.
 66. Kreusel KM, Heimann H, Wiegel T, et al. Choroidal metastasis in men with metastatic breast cancer. *Am J Ophthalmol* 1999;128:253-5.
 67. Chen YR, Lin TH, Chan SM, et al. Bilateral choroidal metastases as the initial presentation of a small breast carcinoma: a case report. *Zhonghua Yi Xue Za Zhi (Taipei)* 1998;61:99-103.
 68. Paoli D. Regression of choroidal metastasis from a carcinoma of the male breast: case report. *Ophthalmologica* 1998;212 Suppl 1:74-6.
 69. Gupta RK, Lallu S, McHutchison AG, et al. Fine needle aspiration of Sister Mary Joseph's nodule. *Cytopathology* 1991;2:311-4.
 70. Thatcher N, Thomas PR. Choroidal metastases from breast carcinoma: a survey of 42 patients and the use of radiation therapy. *Clin Radiol* 1975;26:549-53.
 71. Pambuccian SE, Bachowski GJ, Twigg LB. Signet ring cell lobular carcinoma of the breast presenting in a cervicovaginal smear. A case report. *Acta Cytol* 2000;44:824-30.
 72. Nair RR, Conroy MD, Jeyarajah AR. Obstructive uropathy secondary to parametrial metastasis: an unusual presentation of breast carcinoma. *Eur J Gynaecol Oncol* 2009;30:214-5.
 73. Proença S, Reis MI, Cominho J, et al. Metastatic Breast Cancer in Uterine Cervix: A Rare Presentation. *J Low Genit Tract Dis* 2016;20:e1-3.
 74. Toyoshima M, Iwahashi H, Shima T, et al. Solitary uterine metastasis of invasive lobular carcinoma after adjuvant endocrine therapy: a case report. *J Med Case Rep* 2015;9:47.
 75. Bogliolo S, Morotti M, Valenzano Menada M, et al. Breast cancer with synchronous massive metastasis in the uterine cervix: a case report and review of the literature. *Arch Gynecol Obstet* 2010;281:769-73.
 76. Mousavi A, Karimi Zarchi M. Isolated cervical metastasis of breast cancer: a case report and literature review. *J Low Genit Tract Dis* 2007;11:276-8.
 77. Green AE, Biscotti C, Michener C, et al. Isolated cervical metastasis of breast cancer: a case report and review of the literature. *Gynecol Oncol* 2004;95:267-9.
 78. Pauer HU, Viereck V, Burfeind P, et al. Uterine cervical metastasis of breast cancer: a rare complication that may be overlooked. *Onkologie* 2003;26:58-60.
 79. Sinkre P, Milchgrub S, Miller DS, et al. Uterine metastasis from a heterologous metaplastic breast carcinoma simulating a primary uterine malignancy. *Gynecol Oncol* 2000;77:216-8.
 80. Kesavan S, Lee IW. An unusual tumour metastasis to the cervix. *Ann Acad Med Singapore* 2000;29:780-2.

81. Hepp HH, Hoos A, Leppien G, et al. Breast cancer metastatic to the uterine cervix: analysis of a rare event. *Cancer Invest* 1999;17:468-73.
82. Kennebeck CH, Alagoz T. Signet ring breast carcinoma metastases limited to the endometrium and cervix. *Gynecol Oncol* 1998;71:461-4.
83. Taxy JB, Trujillo YP. Breast cancer metastatic to the uterus. Clinical manifestations of a rare event. *Arch Pathol Lab Med* 1994;118:819-21.
84. Sanuki-Fujimoto N, Takeda A, Amemiya A, et al. Pattern of tumor recurrence in initially nonmetastatic breast cancer patients: distribution and frequency of metastases at unusual sites. *Cancer* 2008;113:677-82.
85. Kemp B, Schröder W, Hermann A, et al. Uterine metastasis of invasive lobular breast carcinoma. Case report and review of the literature with reference to differential diagnostic problems and clinical consequences. *Zentralbl Gynakol* 1997;119:500-2.
86. Moey MY, Hassan OA, Papageorgiou CN, et al. The potential role of HER2 upregulation in metastatic breast cancer to the uterus: a case report. *Clin Case Rep* 2016;4:928-34.
87. Çift T, Aslan B, Bulut B, et al. Unusual uterine metastasis of invasive ductal carcinoma: A case report. *Turk J Obstet Gynecol* 2016;13:164-6.
88. Rahmani M, Nili F, Tabibian E. Endometrial Metastasis from Ductal Breast Carcinoma: A Case Report with Literature Review. *Am J Case Rep* 2018;19:494-9.
89. Aytakin A, Bilgetekin I, Ciltas A, et al. Lobular breast cancer metastasis to uterus during adjuvant tamoxifen treatment: A case report and review of the literature. *J Cancer Res Ther* 2018;14:1135-7.
90. Briki R, Cherif O, Bannour B, et al. Uncommon metastases of invasive lobular breast cancer to the endometrium: a report of two cases and review of the literature. *Pan Afr Med J* 2018;30:268.
91. Franco-Márquez R, Torres-Gaytán AG, Narro-Martinez MA, et al. Metastasis of Breast Lobular Carcinoma to Endometrium Presenting as Recurrent Abnormal Uterine Bleeding: A Case Report and Review of Literature. *Case Rep Pathol* 2019;2019:5357194.
92. Ertas IE, Sayhan S, Karagoz G, et al. Signet-ring cell carcinoma of the breast with uterine metastasis treated with extensive cytoreductive surgery: a case report and brief review of the literature. *J Obstet Gynaecol Res* 2012;38:948-52.
93. D'souza MM, Sharma R, Tripathi M, et al. Cervical and uterine metastasis from carcinoma of breast diagnosed by PET/CT: an unusual presentation. *Clin Nucl Med* 2010;35:820-3.
94. Karvouni E, Papakonstantinou K, Dimopoulou C, et al. Abnormal uterine bleeding as a presentation of metastatic breast disease in a patient with advanced breast cancer. *Arch Gynecol Obstet* 2009;279:199-201.
95. Scopa CD, Aletra C, Lifschitz-Mercer B, et al. Metastases of breast carcinoma to the uterus. Report of two cases, one harboring a primary endometrioid carcinoma, with review of the literature. *Gynecol Oncol* 2005;96:543-7.
96. Chehal A, Seoud M, Taher A, et al. Endometrial metastasis from signet-ring breast carcinoma: case report. *Eur J Gynaecol Oncol* 2002;23:563-4.
97. Horn LC, Einkenkel J, Baier D. Endometrial metastasis from breast cancer in a patient receiving tamoxifen therapy. *Gynecol Obstet Invest* 2000;50:136-8.
98. Gandhi AK, Roy S, Mridha AR, et al. Vulvar metastasis from carcinoma breast unveiling distant metastasis: Exploring an unusual metastatic pattern. *J Egypt Natl Canc Inst* 2015;27:243-6.
99. Engelstaedter V, Mylonas I. Lower genital tract metastases at time of first diagnosis of mammary invasive lobular carcinoma. *Arch Gynecol Obstet* 2011;283 Suppl 1:93-5.
100. Sheen-Chen SM, Eng HL, Huang CC. Breast cancer metastatic to the vulva. *Gynecol Oncol* 2004;94:858-60.
101. Curtin WM, Murthy B. Vulvar metastasis of breast carcinoma. A case report. *J Reprod Med* 1997;42:61-3.
102. Valenzano Menada M, Papadia A, Lorenzi P, et al. Breast cancer metastatic to the vulva after local recurrence occurring on a rectus abdominis myocutaneous flap: a case report and review of the literature. *Eur J Gynaecol Oncol* 2003;24:577-9.
103. Pineda A, Sall S. Metastasis to the vagina from carcinoma of the breast. *J Reprod Med* 1978;20:243-5.
104. Bellati F, Palaia I, Gasparri ML, et al. First case of isolated vaginal metastasis from breast cancer treated by surgery. *BMC Cancer* 2012;12:479.
105. Durga G, Gandhi JS, Mehta A. Malignant phyllodes tumor metastatic to bilateral ovaries: A Krukenberg-like presentation. *J Cancer Res Ther* 2018;14:1138-41.
106. Fujii M, Okino M, Fujioka K, et al. Pseudo-Meigs' syndrome caused by breast cancer metastasis to both ovaries. *Breast Cancer* 2006;13:344-8.
107. Julien V, Labadie M, Gauthier G, et al. Clitoral metastasis from ductal breast cancer revealing metastases in multiple sites and review of the literature. *J Low Genit Tract Dis* 2012;16:66-9.
108. Alexander A, Samlowski WE, Grossman D, et al.

- Metastatic melanoma in pregnancy: risk of transplacental metastases in the infant. *J Clin Oncol* 2003;21:2179-86.
109. Froehlich K, Stensheim H, Markert UR, et al. Breast carcinoma in pregnancy with spheroid-like placental metastases—a case report. *APMIS* 2018;126:448-52.
 110. Eltorky M, Khare VK, Osborne P, et al. Placental metastasis from maternal carcinoma. A report of three cases. *J Reprod Med* 1995;40:399-403.
 111. Liu CH, Chang C, Sy E, et al. Metaplastic breast carcinoma with multiple muscle metastasis: a case report. *Medicine (Baltimore)* 2015;94:e662.
 112. Khettab M, Barrascout E, Lamuraglia M. Sternocleidomastoid muscle metastasis of breast cancer: case report. *Eur J Gynaecol Oncol* 2017;38:113-4.
 113. Almusarhed M, Eldeeb H. Solitary biceps muscle metastasis from breast cancer. *BMJ Case Rep* 2017. doi: 10.1136/bcr-2017-220597.
 114. Salemis NS. Skeletal muscle metastasis from breast cancer: management and literature review. *Breast Dis* 2015;35: 37-40.
 115. Khandelwal AR, Takalkar AM, Lilien DL, et al. Skeletal muscle metastases on FDG PET/CT imaging. *Clin Nucl Med* 2012;37:575-9.
 116. Surov A, Hainz M, Holzhausen HJ, et al. Skeletal muscle metastases: primary tumours, prevalence, and radiological features. *Eur Radiol* 2010;20:649-58.
 117. Purkayastha A, Sharma N. Extremely rare presentation of soft tissue metastasis from carcinoma breast as a massive swelling of upper extremity. *Ann Palliat Med* 2016;5:145-8.
 118. Rao MY, Wu JB. Invasive ductal breast cancer with extensive subcutaneous metastases in trunk: a case report. *Eur Rev Med Pharmacol Sci* 2015;19:4101-4.
 119. Metere A, Di Cosimo C, Chiesa C, et al. An unusual subcutaneous breast cancer metastasis in a 86-year-old woman. *Eur Rev Med Pharmacol Sci* 2012;16:562-4.
 120. Plaza JA, Perez-Montiel D, Mayerson J, et al. Metastases to soft tissue: a review of 118 cases over a 30-year period. *Cancer* 2008;112:193-203.
 121. Jaffe D, Kim E, Aboulafia A. Erosive Breast Cancer Metastasis to the Ankle: A Case Report. *J Foot Ankle Surg* 2016;55:1297-301.
 122. Monserez D, Vlamincck S, Kuhweide R, et al. Symmetrical ethmoidal metastases from ductal carcinoma of the breast, suggesting transcribrosal spread. *Acta Otorhinolaryngol Belg* 2001;55:251-7.
 123. Pignataro L, Peri A, Ottaviani F. Breast carcinoma metastatic to the ethmoid sinus: a case report. *Tumori* 2001;87:455-7.
 124. Fyrmpas G, Televantou D, Papageorgiou V, et al. Unsuspected breast carcinoma presenting as orbital complication of rhinosinusitis. *Eur Arch Otorhinolaryngol* 2008;265:979-82.
 125. Reimann K, Schulze M, Adam P, et al. Metastasis to the paranasal sinuses from primary breast cancer. *HNO* 2011;59:915-7.
 126. Xiong J, Chen J, Zheng L, et al. Rare metastasis to paranasal sinuses from triple-negative breast cancer: A case report and literature review. *Medicine (Baltimore)* 2017;96:e8718.
 127. Walker DT, Barbur S, Mathew R, et al. Sinus involvement in breast cancer: case report. *J Laryngol Otol* 2013;127:619-20.
 128. Marchioni D, Monzani D, Rossi G, et al. Breast carcinoma metastases in paranasal sinuses, a rare occurrence mimicking a primary nasal malignancy. case report. *Acta Otorhinolaryngol Ital* 2004;24:87-91.
 129. Pitkäranta A, Markkola A, Malmberg H. Breast cancer metastasis presenting as ethmoiditis. *Rhinology* 2001;39:107-8.
 130. Austin JR, Kershiznek MM, McGill D, et al. Breast carcinoma metastatic to paranasal sinuses. *Head Neck* 1995;17:161-5.
 131. Tiwari V, Pande SC, Verma K, et al. Paranasal sinus and retro-orbital metastasis in a case of breast carcinoma: a clinicoradiological review. *BMJ Case Rep* 2014. doi: 10.1136/bcr-2014-204094.
 132. Namad T, Benbrahim Z, Najib R, et al. Maxillofacial metastasis from breast cancer. *Pan Afr Med J* 2014;19:156.
 133. Imre A, Sakarya EU, Imre SS, et al. Orbital apex syndrome as a sign of unsuspected breast carcinoma. *J Craniofac Surg* 2013;24:1476-8.
 134. Atasoy BM, Cetin IA, Bozkurt SU, et al. Metastasis to paranasal sinuses and orbita of breast cancer with a rare metachronous tumor of the uterine cervix. *J Craniofac Surg* 2013;24:e64-5.
 135. Ando K, Masumoto N, Sakamoto M, et al. Parotid Gland Metastasis of Breast Cancer: Case Report and Review of the Literature. *Breast Care (Basel)* 2011;6:471-3.
 136. Agarwal G, Sonthineni C, Mayilvaganan S, et al. Surgical Outcomes of Primary Versus Post-Neoadjuvant Chemotherapy Breast Conservation Surgery: A Comparative Study from a Developing Country. *World J Surg* 2018;42:1364-74.
 137. Cao XS, Cong BB, Yu ZY. Parotid gland metastasis from carcinoma of the breast detected by PET/CT: Case report

- and review. *Medicine (Baltimore)* 2018;97:e10616.
138. Rawet T, Jegannathan A, Soumian S. Parotid gland: an unusual site of breast cancer metastasis. *BMJ Case Rep* 2017. doi: 10.1136/bcr-2017-221842.
 139. Sellinger M, Neubauer K, William M, et al. Contralateral metastasis of parotid gland in advanced breast cancer with peripheral facial paralysis. *Arch Gynecol Obstet* 2011;284:1557-60.
 140. Dangore-Khasbage SB, Degwekar SS, Bhowate RR, et al. Metastatic involvement of parotid from carcinoma of the breast--a case report. *Oral Maxillofac Surg* 2009;13:49-53.
 141. Perez-Fidalgo JA, Chirivella I, Laforga J, et al. Parotid gland metastasis of a breast cancer. *Clin Transl Oncol* 2007;9:264-5.
 142. Zhang JZ, Gu M. Malignant phyllodes tumor of the breast metastatic to the parotid gland diagnosed by fine needle aspiration biopsy. A case report. *Acta Cytol* 2003;47:253-8.
 143. Erra S, Costamagna D. Breast cancer metastatic to the submandibular gland. Case report. *G Chir* 2011;32:194-8.
 144. Cain AJ, Goodlad J, Denholm SW. Metachronous bilateral submandibular gland metastases from carcinoma of the breast. *J Laryngol Otol* 2001;115:683-4.
 145. Suárez Roa Mde L, Ruiz Godoy Rivera LM, Vela Chávez T, et al. Breast malignant phyllodes tumour metastasising to soft tissues of oral cavity. *Clin Transl Oncol* 2007;9:258-61.
 146. Owosho AA, Xu B, Kadempour A, et al. Metastatic solid tumors to the jaw and oral soft tissue: A retrospective clinical analysis of 44 patients from a single institution. *J Craniomaxillofac Surg* 2016;44:1047-53.
 147. Bar R, Netzer A, Ostrovsky D, et al. Abrupt tonsillar hemorrhage from a metastatic hemangiosarcoma of the breast: case report and literature review. *Ear Nose Throat J* 2011;90:116-20.
 148. Sera T, Kashiwagi S, Takashima T, et al. Multiple metastatic malignant phyllodes tumor of the breast with tonsillar metastasis: a case report. *BMC Res Notes* 2017;10:55.
 149. Maruzzo M, Giorgi CA, Marioni G, et al. Late onset (22 years) of simultaneous tonsillar and cervical lymph node metastases from breast ductal carcinoma. *Am J Otolaryngol* 2012;33:627-30.
 150. Barton TK, Kesterson GH, Wellman D, et al. Tonsillar metastasis from carcinoma of the breast with ultrastructural and steroid receptor analyses. *Laryngoscope* 1980;90:477-85.
 151. Saab GA, Abdul-Karim FW, Samara M. Breast carcinoma metastatic to the nasopharynx. *J Laryngol Otol* 1987;101:723-5.
 152. Copson B, Pratap U, McLean C, et al. Nasopharyngeal metastasis of breast carcinoma with HER 2 discordance: a case report. *ANZ J Surg* 2018;88:508-9.
 153. Murhekar K, Majhi U, Krishnamurthy A, et al. Diagnostic dilemma involving a mass in the parapharyngeal space: A metastatic breast carcinoma masquerading as a malignant salivary gland tumor. *Indian J Nucl Med* 2015;30:248-50.
 154. Raut V, Sinnathuray AR, McClean G, et al. Metastatic breast carcinoma in the parapharyngeal space. *J Laryngol Otol* 2001;115:750-2.
 155. Nguyen CH, Weitzner S. Metastatic carcinoma of breast in the hypopharynx. *South Med J* 1983;76:1590-1.
 156. Agrawal S, Jayant K, Agarwal RK, et al. An unusual case of metastatic male breast cancer to the nasopharynx-review of literature. *Ann Palliat Med* 2015;4:233-8.
 157. Schuler PJ, Heikaus S, Friebe-Hoffmann U, et al. Breast cancer metastases in the head and neck region. *HNO* 2010;58:859-65.
 158. Wanamaker JR, Kraus DH, Eliachar I, et al. Manifestations of metastatic breast carcinoma to the head and neck. *Head Neck* 1993;15:257-62.
 159. Weng B, Wang Q, Lin S, et al. Nasal cavity metastasis of breast cancer: a case report and review of the literature. *Int J Clin Exp Pathol* 2014;7:7028-33.
 160. Pusiol T, Franceschetti I, Bonfioli F, et al. Middle ear metastasis from dormant breast cancer as the initial sign of disseminated disease 20 years after quadrantectomy. *Ear Nose Throat J* 2013;92:121-4.
 161. Marques E, Brandis A, Samii M, et al. Late metastasis of breast adenocarcinoma into internal auditory canal and cerebellopontine angle: case report. *Arq Neuropsiquiatr* 2002;60:639-42.
 162. Çelik M, Şahin B, Tepe M, et al. Breast Cancer Metastasis on the Neck Mimicking a Glomus Tumor. *J Craniofac Surg* 2017;28:e271-3.
 163. Takei H, Rouah E, Barrios R. Intravascular carcinomatosis of central nervous system due to metastatic inflammatory breast cancer: A case report. *Neuropathology* 2015;35:456-61.
 164. Cooney BM, Ruth GJ, Behrman DA, et al. Malignant cystosarcoma phyllodes of the breast metastatic to the oral cavity: report of a case and review of the literature. *Oral Surg Oral Med Oral Pathol* 1988;66:599-604.
 165. Scipio JE, Murti PR, Al-Bayaty HF, et al. Metastasis of breast carcinoma to mandibular gingiva. *Oral Oncol* 2001;37:393-6.
 166. Malhotra G, Nair N, Awasare S. F-18 FDG PET scan

- findings in a case of carcinoma of the breast with a rare site of metastases to the gingival region. *Clin Nucl Med* 2006;31:820-1.
167. Eichhorn W, Wehrmann M, Blessmann M, et al. Metastases in odontogenic cysts: literature review and case presentation. *Oral Surg Oral Med Oral Pathol Oral Radiol Endod* 2010;109:582-6.
 168. Kechagias N, Ntomouchtsis A, Patrikidou A, et al. Metastasis of a ductal breast carcinoma to the buccal mucosa of the mandible with tooth involvement. *Oral Maxillofac Surg* 2012;16:377-81.
 169. Friedrich RE, Abadi M. Distant metastases and malignant cellular neoplasms encountered in the oral and maxillofacial region: analysis of 92 patients treated at a single institution. *Anticancer Res* 2010;30:1843-8.
 170. Rajesh KS, Varma BR, Bhat KM. Metastasis to maxillary gingiva from carcinoma of breast. A case report. *Indian J Dent Res* 1998;9:23-7.
 171. Yang SI, Park KK, Kim JH. Thyroid metastasis from breast carcinoma accompanied by papillary thyroid carcinoma. *Case Rep Oncol* 2014;7:528-33.
 172. Bourcier K, Fermeaux V, Leobon S, et al. Lobular Breast Carcinoma Metastasis to the Thyroid Gland: Case Report and Literature Review. *J Breast Cancer* 2018;21:463-7.
 173. Ghias AF, Epps G, Cottrill E, Mardekian SK. Multifocal Metastatic Breast Carcinoma to the Thyroid Gland Histologically Mimicking C Cell Lesions. *Case Rep Pathol* 2019;2019:9890716.
 174. Kho MR, Abelardo AD. Isolated thyroid metastasis from benign phyllodes tumour. *BMJ Case Rep* 2018. doi: 10.1136/bcr-2018-224420.
 175. Plonczak AM, DiMarco AN, Dina R, et al. Breast cancer metastases to the thyroid gland - an uncommon sentinel for diffuse metastatic disease: a case report and review of the literature. *J Med Case Rep* 2017;11:269.
 176. Debnam JM, Kwon M, Fornage BD, et al. Sonographic Evaluation of Intrathyroid Metastases. *J Ultrasound Med* 2017;36:69-76.
 177. Magers MJ, Dueber JC, Lew M, et al. Metastatic ductal carcinoma of the breast to the thyroid gland diagnosed with fine needle aspiration: A case report with emphasis on morphologic and immunophenotypic features. *Diagn Cytopathol* 2016;44:530-4.
 178. Rossi ED, Martini M, Straccia P, et al. Is thyroid gland only a "land" for primary malignancies? role of morphology and immunocytochemistry. *Diagn Cytopathol* 2015;43:374-80.
 179. HooKim K, Gaitor J, Lin O, et al. Secondary tumors involving the thyroid gland: A multi-institutional analysis of 28 cases diagnosed on fine-needle aspiration. *Diagn Cytopathol* 2015;43:904-11.
 180. Kolarević D, Tomasević Z, Marković I, et al. Rare localisation of breast cancer metastasis to thyroid gland. *Vojnosanit Pregl* 2012;69:1106-8.
 181. Calzolari F, Sartori PV, Talarico C, et al. Surgical treatment of intrathyroid metastases: preliminary results of a multicentric study. *Anticancer Res* 2008;28:2885-8.
 182. Saber A, Ramzy S, Gouda I. Metastasis to the thyroid gland; unusual site of metastasis. *Gulf J Oncolog* 2007;1:51-7.
 183. Leboeuf R, Bénard F, Langlois MF. Thyroid cancer presenting as a PET incidentaloma in a patient with concomitant breast cancer metastases to the thyroid. *Clin Nucl Med* 2006;31:382-5.
 184. Gong Y, Jalali M, Staerckel G. Fine needle aspiration cytology of a thyroid metastasis of metaplastic breast carcinoma: a case report. *Acta Cytol* 2005;49:327-30.
 185. Lam KY, Lo CY. Metastatic tumors of the thyroid gland: a study of 79 cases in Chinese patients. *Arch Pathol Lab Med* 1998;122:37-41.
 186. Ferrara G, Ianniello GP, Nappi O. Thyroid metastases from a ductal carcinoma of the breast. A case report. *Tumori* 1997;83:783-7.
 187. Rosen IB, Bedard YC, Walfish PG, et al. Metastasis of cancer of the thyroid gland as a cause of goitre. *Can Med Assoc J* 1978;118:1265-8.
 188. Lee SH, Kim BH, Bae MJ, et al. Concurrence of primary hyperparathyroidism and metastatic breast carcinoma affected a parathyroid gland. *J Clin Endocrinol Metab* 2013;98:3127-30.
 189. Watanabe T, Adachi I, Kimura S, et al. A case of advanced breast cancer associated with hypocalcemia. *Jpn J Clin Oncol* 1983;13:441-8.
 190. Ghosn M, Ghayad E, Biagini J, et al. Hypothalamo-hypophyseal and gastric metastasis of a breast neoplasm. Clinical case and a review of the literature. *Bull Cancer* 1991;78:1071-3.
 191. Fukunaga A, Yazaki T, Shimizu K, et al. A case of pituitary metastasis in a patient with male breast cancer developing anterior lobe dysfunction successfully treated by using hormone replacement therapy. *No Shinkei Geka* 2014;42:629-33.
 192. Rozen WM, Mann GB. Angiosarcoma arising in an unirradiated breast with subsequent pituitary metastasis. *Clin Breast Cancer* 2007;7:811-3.
 193. Poursadegh Fard M, Borhani Haghighi A, Bagheri MH.

- Breast cancer metastasis to pituitary infundibulum. *Iran J Med Sci* 2011;36:141-4.
194. Nose K, Ogata T, Tsugawa J, et al. Pituitary metastasis of breast cancer mimicking IgG4-related hypophysitis. *eNeurologicalSci* 2018;14:13-5.
 195. Castle-Kirszbaum M, Goldschlager T, Ho B, et al. Twelve cases of pituitary metastasis: a case series and review of the literature. *Pituitary* 2018;21:463-73.
 196. Kam J, Mann GB, Phillips C, et al. Solitary pituitary metastasis from HER2-positive breast cancer. *Asia Pac J Clin Oncol* 2017;13:e181-e4.
 197. Ravnik J, Smigoc T, Bunc G, et al. Hypophyseal metastases: A report of three cases and literature review. *Neurol Neurochir Pol* 2016;50:511-6.
 198. Burkhardt T, Henze M, Kluth LA, et al. Surgical management of pituitary metastases. *Pituitary* 2016;19:11-8.
 199. Gormally JF, Izard MA, Robinson BG, et al. Pituitary metastasis from breast cancer presenting as diabetes insipidus. *BMJ Case Rep* 2014. doi: 10.1136/bcr-2014-203683.
 200. Magalhães JF, Bacchin RP, Costa PS, et al. Breast cancer metastasis to the pituitary gland. *Arq Bras Endocrinol Metabol* 2014;58:869-72.
 201. Spinelli GP, Lo Russo G, Miele E, et al. Breast cancer metastatic to the pituitary gland: a case report. *World J Surg Oncol* 2012;10:137.
 202. Naqi R, Azeemuddin M. Solitary metastasis of breast carcinoma in the infundibulum. *J Pak Med Assoc* 2012;62:169-70.
 203. Dogan M, Karakilic E, Oz II, et al. Breast cancer with diabetes insipidus. *Exp Oncol* 2008;30:324-6.
 204. Gołkowski F, Trofimiuk M, Czepko R, et al. Two rare cases of pituitary metastases from breast and kidney cancers. *Exp Clin Endocrinol Diabetes* 2007;115:537-40.
 205. Kurkjian C, Armor JF, Kamble R, et al. Symptomatic metastases to the pituitary infundibulum resulting from primary breast cancer. *Int J Clin Oncol* 2005;10:191-4.
 206. Sturm I, Kirschke S, Krahl D, et al. Panhypopituitarism in a patient with breast cancer. *Onkologie* 2004;27:480-2.
 207. Ruiz Hernández G, Chesa-Jiménez J, San Martín Ciges E, et al. Panhypopituitarism as a consequence of metastase of breast cancer in sella turcica. *Nuklearmedizin* 1996;35:143-5.
 208. Paulus P, Paridaens R, Mockel J, et al. Argyrophilic breast carcinoma, single metastasis to the pituitary gland. *Bull Cancer* 1990;77:377-84.
 209. Yap HY, Tashima CK, Blumenschein GR, et al. Diabetes insipidus and breast cancer. *Arch Intern Med* 1979;139:1009-11.
 210. Tears RJ, Silverman EM. Clinicopathologic review of 88 cases of carcinoma metastatic to the pituitary gland. *Cancer* 1975;36:216-20.
 211. Flis DW, Shah AT, Tracy JC, et al. Metastatic breast carcinoma of the jugular foramen: a rare case of Villaret syndrome. *Head Neck* 2015;37:E146-9.
 212. Khaw K, Ramli N, Rahmat K. Ptosis due to cavernous sinus syndrome as a rare presentation of advanced breast metastasis in a patient with delayed diagnosis. *Malays Fam Physician* 2012;7:31-3.
 213. Kim DH, Son SM, Choi YJ. Gastric metastasis from invasive lobular breast cancer, mimicking primary gastric cancer: A case report. *Medicine (Baltimore)* 2018;97:e0258.
 214. Rampado S, Ruol A, Guido M, et al. Mediastinal carcinosis involving the esophagus in breast cancer: the "breast-esophagus" syndrome: report on 25 cases and guidelines for diagnosis and treatment. *Ann Surg* 2007;246:316-22.
 215. Fukunaga A, Sasamura Y, Takada A, et al. Solitary thymic metastasis of breast cancer 13 years after surgery. *Asian Cardiovasc Thorac Ann* 2017;25:469-71.
 216. Fujioka S, Nakamura H, Miwa K, et al. Thymic metastasis of breast cancer 22 years after surgery: a case report. *Asian J Endosc Surg* 2013;6:330-2.
 217. Park SB, Kim HH, Shin HJ, et al. Thymic metastasis in breast cancer: a case report. *Korean J Radiol* 2007;8:360-3.
 218. Bhojwani N, Harwani A, Hartman JB, et al. Metastatic Breast Carcinoma to the Coronaries: A Rare Cause of Acute Myocardial Infarction. *Methodist Debakey Cardiovasc J* 2016;12:179-82.
 219. Sandhu HS, Mahendrakar SKM, Ladhani SS, et al. Superior Vena Cava as Gateway to Heart: Metastatic Breast Carcinoma Causing Ball in a Loop Metastasis to Right Atrium. *J Clin Diagn Res* 2017;11:XD03-5.
 220. Bhambhani A, Ayyagari S, Mohapatra T, et al. Malignant phyllodes tumor of the left atrium. *Indian Heart J* 2014;66:241-3.
 221. Katalinic D, Stern-Padovan R, Ivanac I, et al. Symptomatic cardiac metastases of breast cancer 27 years after mastectomy: a case report with literature review--pathophysiology of molecular mechanisms and metastatic pathways, clinical aspects, diagnostic procedures and treatment modalities. *World J Surg Oncol* 2013;11:14.
 222. Eminowicz G, Achilleos K, Payne S, et al. Solitary atrial metastases: a rare clinical challenge. *BMJ Case Rep* 2011. doi: 10.1136/bcr.11.2010.3506.
 223. Garg N, Moorthy N, Agrawal SK, et al. Delayed cardiac

- metastasis from phyllodes breast tumor presenting as cardiogenic shock. *Tex Heart Inst J* 2011;38:441-4.
224. Kawase T, Fujii H, Nakahara T, et al. Intense accumulation of Tc-99m MDP in pericardial metastasis from breast cancer. *Clin Nucl Med* 2009;34:173-4.
225. Broom RJ, Harvey VJ, Lee KM. A durable complete remission between two isolated presentations of metastatic breast cancer, the second with intracardiac disease. *Clin Breast Cancer* 2006;7:162-3.
226. Lieberman EB, Arthur J, Steenbergen C, et al. Antemortem diagnosis of an endomyocardial breast cancer metastasis by transvenous endomyocardial biopsy. *Chest* 1993;103:1280-1.
227. Labib SB, Schick EC, Isner JM. Obstruction of right ventricular outflow tract caused by intracavitary metastatic disease: analysis of 14 cases. *J Am Coll Cardiol* 1992;19:1664-8.
228. Wada Y, Harada N, Ohara K, et al. Esophageal metastasis of breast carcinoma. *Breast Cancer* 2009;16:151-6.
229. Anaya DA, Yu M, Karmy-Jones R. Esophageal perforation in a patient with metastatic breast cancer to esophagus. *Ann Thorac Surg* 2006;81:1136-8.
230. Koike M, Akiyama S, Kodera Y, et al. Breast carcinoma metastasis to the esophagus: report of two cases. *Hepatogastroenterology* 2005;52:1116-8.
231. McLemore EC, Pockaj BA, Reynolds C, et al. Breast cancer: presentation and intervention in women with gastrointestinal metastasis and carcinomatosis. *Ann Surg Oncol* 2005;12:886-94.
232. Sunada F, Yamamoto H, Kita H, et al. A case of esophageal stricture due to metastatic breast cancer diagnosed by endoscopic mucosal resection. *Jpn J Clin Oncol* 2005;35:483-6.
233. Erman M, Karaoğlu A, Oksüzöğlü B, et al. Solitary esophageal metastasis of breast cancer after 11 years: a case report. *Med Oncol* 2002;19:171-5.
234. Simchuk EJ, Low DE. Direct esophageal metastasis from a distant primary tumor is a submucosal process: a review of six cases. *Dis Esophagus* 2001;14:247-50.
235. Varanasi RV, Saltzman JR, Krims P, et al. Breast carcinoma metastatic to the esophagus: clinicopathological and management features of four cases, and literature review. *Am J Gastroenterol* 1995;90:1495-9.
236. Herrera JL. Case report: esophageal metastasis from breast carcinoma presenting as achalasia. *Am J Med Sci* 1992;303:321-3.
237. Roostaeian J, Yoon AP, Sanchez IS, et al. The effect of prior abdominal surgery on abdominally based free flaps in breast reconstruction. *Plast Reconstr Surg* 2014;133:247e-55e.
238. Malhotra A, Guturu P, Basim MS, et al. A rare case of breast cancer metastasis presenting as linitis plastica of the stomach and colon (with videos). *Gastrointest Endosc* 2009;70:552-3; discussion 553.
239. Hara F, Kiyoto S, Takabatake D, et al. Metastatic Breast Cancer to the Stomach Resembling Early Gastric Cancer. *Case Rep Oncol* 2010;3:142-7.
240. Dória MT, Maesaka JY, Martins SN, et al. Gastric metastasis as the first manifestation of an invasive lobular carcinoma of the breast. *Autops Case Rep* 2015;5:49-53.
241. Geredeli C, Dogru O, Omeroglu E, et al. Gastric Metastasis of Triple Negative Invasive Lobular Carcinoma. *Rare Tumors* 2015;7:5764.
242. Ricciuti B, Leonardi GC, Ravaioi N, et al. Ductal Breast Carcinoma Metastatic to the Stomach Resembling Primary Linitis Plastica in a Male Patient. *J Breast Cancer* 2016;19:324-9.
243. Dos Santos Fernandes G, Batista Bugiato Faria LD, de Assis Pereira I, et al. Gastric Metastasis of Breast Cancer: A Case Series. *Rare Tumors* 2016;8:6305.
244. Villa Guzmán JC, Espinosa J, Cervera R, et al. Gastric and colon metastasis from breast cancer: case report, review of the literature, and possible underlying mechanisms. *Breast Cancer (Dove Med Press)* 2016;9:1-7.
245. Jmour O, Belaïd A, Mghirbi F, et al. Gastric metastasis of bilateral breast cancer. *J Gastrointest Oncol* 2017;8: E16-20.
246. Khan I, Malik R, Khan A, et al. Breast Cancer Metastases to the Gastrointestinal Tract Presenting with Anemia and Intra-abdominal Bleed. *Cureus* 2017;9:e1429.
247. Kliiger J, Gorbaty M. Metastasis to the pancreas and stomach from a breast cancer primary: a case report. *J Community Hosp Intern Med Perspect* 2017;7:234-7.
248. Ulmer LL, Cormier I, Jha LK, et al. Use of Endoscopic Ultrasound in a Diagnostic Dilemma: Metastatic Breast Cancer to the Stomach. *Case Rep Gastrointest Med* 2018;2018:2820352.
249. Bushan K, Kammar P, Singh C, et al. Infiltrating Lobular Breast Cancer Presenting as Isolated Gastric Metastasis: a Case Report. *Indian J Surg Oncol* 2018;9:318-22.
250. Güler SA, Şimşek T, Pösteki G, et al. A Very Rare Reason for Gastric Perforation, Caused by Gastric Metastasis of Breast Cancer: Case Presentation. *Eur J Breast Health* 2018;15:59-62.
251. Woo J, Lee JH, Lee KE, et al. Gastric Metastasis as the First Presentation One Year Before Diagnosis of Primary

- Breast Cancer. *Am J Case Rep* 2018;19:354-9.
252. Gurzu S, Baniyas L, Bara T, et al. The Epithelial-Mesenchymal Transition Pathway in Two Cases with Gastric Metastasis Originating from Breast Carcinoma, One with a Metachronous Primary Gastric Cancer. *Recent Pat Anticancer Drug Discov* 2018;13:118-24.
253. Yim K, Ro SM, Lee J. Breast cancer metastasizing to the stomach mimicking primary gastric cancer: A case report. *World J Gastroenterol* 2017;23:2251-7.
254. Choi DI, Chi HS, Lee SH, et al. A Rare Case of Phyllodes Tumor Metastasis to the Stomach Presenting as Anemia. *Cancer Res Treat* 2017;49:846-9.
255. Mullally WJ, O'Suilleabháin CB, Brady C, et al. Vinorelbine induced perforation of a metastatic gastric lesion. *Ir J Med Sci* 2017;186:571-5.
256. Rodrigues MV, Tercioti-Junior V, Lopes LR, et al. Breast cancer metastasis in the stomach: when the gastrectomy is indicated? *Arq Bras Cir Dig* 2016;29:86-9.
257. Zuhair AR, Maron AR. Occult bilateral invasive lobular carcinoma of the breast presenting as gastroduodenal metastases: a case report. *Breast Dis* 2015;35:63-5.
258. Rachan Shetty KS, Challa VR, Lakshmaiah KC, et al. Gastric metastases from breast cancer: A report of two cases and review of literature. *J Cancer Res Ther* 2015;11:660.
259. Wysocka K, Okoń K, Matyja A. Breast cancer metastatic to the gastric wall. *Pol J Pathol* 2011;62:282-5.
260. Critchley AC, Harvey J, Carr M, et al. Synchronous gastric and colonic metastases of invasive lobular breast carcinoma: case report and review of the literature. *Ann R Coll Surg Engl* 2011;93:e49-50.
261. Almubarak MM, Laé M, Cacheux W, et al. Gastric metastasis of breast cancer: a single centre retrospective study. *Dig Liver Dis* 2011;43:823-7.
262. Ghirarduzzi A, Sivelli R, Martella E, et al. Gastric metastasis from breast carcinoma. Report of three cases, diagnostic-therapeutic critical close examination and literature review. *Ann Ital Chir* 2010;81:141-6.
263. Yamamoto D, Yoshida H, Sumida K, et al. Gastric tumor from metastasis of breast cancer. *Anticancer Res* 2010;30:3705-8.
264. Trouillet N, Robert B, Charfi S, et al. Gastric metastases. An endoscopic series of ten cases. *Gastroenterol Clin Biol* 2010;34:305-9.
265. Ellis MC, Mason T, Barnett J, et al. Gastric malignancies in breast cancer survivors: pathology and outcomes. *Am J Surg* 2009;197:633-6.
266. Ciulla A, Castronovo G, Tomasello G, et al. Gastric metastases originating from occult breast lobular carcinoma: diagnostic and therapeutic problems. *World J Surg Oncol* 2008;6:78.
267. Jhaveri A, Nagral A, Dhabar B, et al. Chronic diarrhea--an unusual presentation of metastatic invasive lobular cancer of breast. *Indian J Gastroenterol* 2006;25:312-3.
268. Savanis G, Simatos G, Tzaida O, et al. Gastrointestinal tract metastasis as first presentation of breast cancer. *J BUON* 2006;11:79-81.
269. Whitty LA, Crawford DL, Woodland JH, et al. Metastatic breast cancer presenting as linitis plastica of the stomach. *Gastric Cancer* 2005;8:193-7.
270. Akcali Z, Sakalli H, Ozyilkan O, et al. Prognostically favorable abdominal breast cancer metastases with stomach involvement. *Onkologie* 2005;28:270-2.
271. Tremblay F, Jamison B, Meterissian S. Breast cancer masquerading as a primary gastric carcinoma. *J Gastrointest Surg* 2002;6:614-6.
272. Oda, Kondo H, Yamao T, et al. Metastatic tumors to the stomach: analysis of 54 patients diagnosed at endoscopy and 347 autopsy cases. *Endoscopy* 2001;33:507-10.
273. Pera M, Riera E, Lopez R, et al. Metastatic carcinoma of the breast resembling early gastric carcinoma. *Mayo Clin Proc* 2001;76:205-7.
274. Washington K, McDonagh D. Secondary tumors of the gastrointestinal tract: surgical pathologic findings and comparison with autopsy survey. *Mod Pathol* 1995;8:427-33.
275. Houghton AD, Pheils P. Isolated duodenal metastasis from breast carcinoma. *Eur J Surg Oncol* 1987;13:367-9.
276. Sarkar N, Kejariwal D, Roy S. Isolated duodenal metastasis from breast carcinoma. *J Assoc Physicians India* 2002;50:962-3.
277. Sato T, Muto I, Hasegawa M, et al. Breast signet-ring cell lobular carcinoma presenting with duodenal obstruction and acute pancreatitis. *Asian J Surg* 2007;30:220-3.
278. Jones C, Tong AW, Mir M, et al. Lobular carcinoma of the breast with gastrointestinal metastasis. *Proc (Bayl Univ Med Cent)* 2015;28:50-3.
279. Giestas S, Lopes S, Souto P, et al. Ampullary Metastasis From Breast Cancer: A Rare Cause of Obstructive Jaundice. *GE Port J Gastroenterol* 2016;23:300-3.
280. Lin Y, Wong SI, Wang Y, et al. Periapillary Metastases from Breast Cancer: A Case Report and Literature Review. *Case Rep Oncol Med* 2019;2019:3479568.
281. Wang X, Jin M, Ye Q, et al. Solitary duodenum metastasis from breast cancer with 8 years' latency: A case report. *Medicine (Baltimore)* 2018;97:e9550.

282. Zhao R, Li Y, Yu X, et al. Duodenal metastasis from recurrent invasive lobular carcinoma of breast: a case report and literature review. *Int J Clin Oncol* 2012;17:160-4.
283. Asoglu O, Karanlik H, Barbaros U, et al. Malignant phyllode tumor metastatic to the duodenum. *World J Gastroenterol* 2006;12:1649-51.
284. Lottini M, Neri A, Vuolo G, et al. Duodenal obstruction from isolated breast cancer metastasis: a case report. *Tumori* 2002;88:427-9.
285. Titus AS, Baron TH, Listinsky CM, et al. Solitary breast metastasis to the ampulla and distal common bile duct. *Am Surg* 1997;63:512-5.
286. Hernández V, Flor-Lorente B, Burgués O, et al. Anasarca as presentation of lobular breast carcinoma. *Gastroenterol Hepatol* 2000;23:338-40.
287. Choi JE, Park SY, Jeon MH, et al. Solitary small bowel metastasis from breast cancer. *J Breast Cancer* 2011;14:69-71.
288. Liu M, Zhang L, Guo L, et al. Intestinal metastasis from breast invasive ductal carcinoma after a long latency: case report and literature review. *Onco Targets Ther* 2018;11:8599-603.
289. Bilen MA, Laucirica R, Rimawi MF, et al. Jejunal intussusception due to malignant phyllodes tumor of the breast. *Clin Breast Cancer* 2012;12:219-21.
290. Cho DH, Jeon YS, Choi MY, et al. Ileal metastasis of breast cancer in a patient with a BRCA2 gene mutation: report of a case. *Surg Today* 2011;41:1665-9.
291. Mouawad NJ, Cleary RK. Small bowel obstruction as the primary presentation of undiagnosed metastatic lobular breast carcinoma. *Breast Dis* 2011;33:35-40.
292. Kelly RJ, Barrett C, Swan N, et al. Metastatic phyllodes tumor causing small-bowel obstruction. *Clin Breast Cancer* 2009;9:193-5.
293. Oyasiji T, Shoemake P, Bakhos C, et al. Small bowel obstruction from metastatic breast cancer masquerading as an obstructed incisional hernia. *Conn Med* 2009;73:403-6.
294. Al-Qahtani MS. Gut metastasis from breast carcinoma. *Saudi Med J* 2007;28:1590-2.
295. Haberstick R, Tüech JJ, Wilt M, et al. Anal localization as first manifestation of metastatic ductal breast carcinoma. *Tech Coloproctol* 2005;9:237-8.
296. Titi MA, Anabtawi A, Newland AD. Isolated gastrointestinal metastasis of breast carcinoma: a case report. *Case Rep Med* 2010;2010:615923.
297. Okido M, Seo M, Hamada Y, et al. Metastatic breast carcinoma simulating linitis plastica of the colon: report of a case. *Surg Today* 2011;41:542-5.
298. Saranovic D, Kovac JD, Knezevic S, et al. Invasive lobular breast cancer presenting an unusual metastatic pattern in the form of peritoneal and rectal metastases: a case report. *J Breast Cancer* 2011;14:247-50.
299. Mistrangelo M, Cassoni P, Castellano I, et al. Obstructive colon metastases from lobular breast cancer: report of a case and review of the literature. *Tumori* 2011;97:800-4.
300. Cherian N, Qureshi NA, Cairncross C, et al. Invasive lobular breast carcinoma metastasising to the rectum. *BMJ Case Rep* 2017;2017.
301. Falco G, Mele S, Zizzo M, et al. Colonic metastasis from breast carcinoma detection by CESM and PET/CT: A case report. *Medicine (Baltimore)* 2018;97:e10888.
302. Blachman-Braun R, Felemovicus I, Barker K, et al. Widespread metastatic breast cancer to the bowel: an unexpected finding during colonoscopy. *Oxf Med Case Reports* 2019;2019:omy133.
303. Samra B, Ghanem S, Ilyas G, et al. Screening Colonoscopy Unmasking Colonic Metastasis from an Occult Breast Ductal Carcinoma: A Case Report and Review of the Literature. *Case Rep Oncol Med* 2019;2019:8432079.
304. Schellenberg AE, Wood ML, Baniak N, et al. Metastatic ductal carcinoma of the breast to colonic mucosa. *BMJ Case Rep* 2018. doi: 10.1136/bcr-2018-224216.
305. Ruymbeke H, Harlet L, Stragier B, et al. Anorectal metastasis from breast carcinoma: a case report and review of the literature. *BMC Res Notes* 2018;11:268.
306. Tsujimura K, Teruya T, Kiyuna M, et al. Colonic metastasis from breast carcinoma: a case report. *World J Surg Oncol* 2017;15:124.
307. Buka D, Dvořák J, Richter I, et al. Gastric and Colorectal Metastases of Lobular Breast Carcinoma: A Case Report. *Acta Medica (Hradec Kralove)* 2016;59:18-21.
308. Rengifo C, Titi S, Walls J. Anal metastasis as the sentinel and isolated presentation of invasive ductal breast carcinoma. *Ann R Coll Surg Engl* 2016;98:e68-70.
309. Mroz A, Kiedrowski M. An unusual case of colonic adenocarcinoma development in the region of disseminating lobular breast carcinoma infiltration: diagnostic approach and review of the literature. *Int J Clin Exp Pathol* 2015;8:7470-4.
310. Zhou XC, Zhou H, Ye YH, et al. Invasive ductal breast cancer metastatic to the sigmoid colon. *World J Surg Oncol* 2012;10:256.
311. Takeuchi H, Hiroshige S, Yoshikawa Y, et al. A case of synchronous metastasis of breast cancer to stomach and

- colon. *Anticancer Res* 2012;32:4051-5.
312. Bochicchio A, Tartarone A, Ignomirelli O, et al. Anal metastasis from breast cancer: a case report and review of the literature. *Future Oncol* 2012;8:333-6.
313. Gerova VA, Tankova LT, Mihova AA, et al. Gastrointestinal metastases from breast cancer: report of two cases. *Hepatogastroenterology* 2012;59:178-81.
314. Nikolić I, Ivković-Kapicl T, Kukić B, et al. Uncommon metastatic site from breast cancer. *Vojnosanit Pregl* 2012;69:806-8.
315. Amin AA, Reddy A, Jha M, et al. Rectal metastasis from breast cancer: an interval of 17 years. *BMJ Case Rep* 2011. doi: 10.1136/bcr.01.2011.3683.
316. Razzetta F, Tassara E, Saro F, et al. Rare abdominal metastases from occult lobular breast cancer: report of two cases. *Updates Surg* 2011;63:129-33.
317. Efthimiadis C, Kosmidis C, Fotiadis P, et al. Breast cancer metastatic to the rectum: a case report. *Tech Coloproctol* 2011;15 Suppl 1:S91-3.
318. Balja MP, Vrdoljak DV, Stanec M, et al. Rectal metastasis from lobular carcinoma of the breast: a case report. *Coll Antropol* 2010;34:719-21.
319. Théraux J, Bretagnol F, Guedj N, et al. Colorectal breast carcinoma metastasis diagnosed as an obstructive colonic primary tumor. A case report and review of the literature. *Gastroenterol Clin Biol* 2009;33:1114-7.
320. Birla R, Mahawar KK, Orizu M, et al. Caecal metastasis from breast cancer presenting as intestinal obstruction. *World J Surg Oncol* 2008;6:47.
321. Uygun K, Kocak Z, Altaner S, et al. Colonic metastasis from carcinoma of the breast that mimics a primary intestinal cancer. *Yonsei Med J* 2006;47:578-82.
322. Signorelli C, Pomponi-Formiconi D, Nelli F, et al. Single colon metastasis from breast cancer: a clinical case report. *Tumori* 2005;91:424-7.
323. Law WL, Chu KW. Scirrhus colonic metastasis from ductal carcinoma of the breast: report of a case. *Dis Colon Rectum* 2003;46:1424-7.
324. Dhar S, Kulaylat MN, Gordon K, et al. Solitary papillary breast carcinoma metastasis to the large bowel presenting as primary colon carcinoma: case report and review of the literature. *Am Surg* 2003;69:799-803.
325. Bamias A, Baltayiannis G, Kamina S, et al. Rectal metastases from lobular carcinoma of the breast: report of a case and literature review. *Ann Oncol* 2001;12:715-8.
326. Koutsomanis D, Renier JF, Ollivier R, et al. Colonic metastasis of breast carcinoma. *Hepatogastroenterology* 2000;47:681-2.
327. Flamme F, Jacobowitz D, Feoli F, et al. Diminutive polyp: a rare presentation of breast cancer metastases to the colon. *Acta Gastroenterol Belg* 1994;57:260-3.
328. Rabau MY, Alon RJ, Werbin N, et al. Colonic metastases from lobular carcinoma of the breast. Report of a case. *Dis Colon Rectum* 1988;31:401-2.
329. Balibrea JM, Cantero R, García-Calvo M, et al. Perianal metastases from lobular breast carcinoma. *Clin Transl Oncol* 2007;9:606-9.
330. Dirksen JL, Souder MG, Burick AJ. Metastatic Breast Carcinoma Presenting as Perforated Appendicitis. *Breast Care (Basel)* 2010;5:409-10.
331. Hardt W, Parent B, Januschka J, et al. A rare case of an isolated metastasis of the head of the pancreas of a breast cancer with obstruction of the efferent bile ducts. *Pathologie* 1993;14:167-71.
332. Stoeckler F, Hagmüller E, Rumpelt HJ, et al. A rare cause of distal bile duct stenosis. *J Gastrointest Cancer* 2007;38:157-9.
333. Bonapasta SA, Gregori M, Lanza R, et al. Metastasis to the Pancreas from Breast Cancer: Difficulties in Diagnosis and Controversies in Treatment. *Breast Care (Basel)* 2010;5:170-3.
334. Takamizawa J, Kuze S, Kyokane T, et al. [A case of pancreatic metastasis from breast cancer during multimodality therapy]. *Gan To Kagaku Ryoho* 2011;38:301-3.
335. Inoue M, Ohta T, Shioya H, et al. Inflammatory myofibroblastic tumors of the breast with simultaneous intracranial, lung, and pancreas involvement: ultrasonographic findings and a review of the literature. *J Med Ultrason (2001)* 2018;45:331-5.
336. Sun X, Zuo K, Huang D, et al. Pancreatic metastasis from invasive pleomorphic lobular carcinoma of the breast: a rare case report. *Diagn Pathol* 2017;12:52.
337. Song SW, Cheng JF, Liu N, et al. Diagnosis and treatment of pancreatic metastases in 22 patients: a retrospective study. *World J Surg Oncol* 2014;12:299.
338. Molino C, Mocerino C, Braucci A, et al. Pancreatic solitary and synchronous metastasis from breast cancer: a case report and systematic review of controversies in diagnosis and treatment. *World J Surg Oncol* 2014;12:2.
339. Lam WW, Loke KS, Loi HY, et al. Pancreatic metastasis detected by F-18 FDG PET/CT in a patient with breast cancer. *Clin Nucl Med* 2011;36:479-80.
340. Mourra N, Arrive L, Ballardur P, et al. Isolated metastatic

- tumors to the pancreas: Hôpital St-Antoine experience. *Pancreas* 2010;39:577-80.
341. Ang TL, Ng VW, Fock KM, et al. Diagnosis of a metastatic phyllodes tumor of the pancreas using EUS-FNA. *JOP* 2007;8:35-8.
342. Crippa S, Angelini C, Mussi C, et al. Surgical treatment of metastatic tumors to the pancreas: a single center experience and review of the literature. *World J Surg* 2006;30:1536-42.
343. Haque S, Gopaldas RR, Plymyer MR, et al. Pancreatic mass of unusual etiology: case report of metastatic disease after a prolonged lag phase. *Am Surg* 2005;71:1082-5.
344. Z'graggen K, Fernández-del Castillo C, Rattner DW, et al. Metastases to the pancreas and their surgical extirpation. *Arch Surg* 1998;133:413-7; discussion 418-9.
345. Mountney J, Maury AC, Jackson AM, et al. Pancreatic metastases from breast cancer: an unusual cause of biliary obstruction. *Eur J Surg Oncol* 1997;23:574-6.
346. Shan J, Zhang S, Wang Z, et al. Breast malignant phyllodes tumor with rare pelvic metastases and long-term overall survival: A case report and literature review. *Medicine (Baltimore)* 2016;95:e4942.
347. Osaku T, Ogata H, Magoshi S, et al. Metastatic nonpalpable invasive lobular breast carcinoma presenting as rectal stenosis: a case report. *J Med Case Rep* 2015;9:88.
348. Cardi M, Sammartino P, Framarino ML, et al. Treatment of peritoneal carcinomatosis from breast cancer by maximal cytoreduction and HIPEC: a preliminary report on 5 cases. *Breast* 2013;22:845-9.
349. D'Annibale M, Esposito A, Boschetto A, et al. Solitary peritoneal metastases from ductal breast cancer. *Chir Ital* 2007;59:191-6.
350. Kobayashi T, Adachi S, Matsuda Y, et al. A case of metastatic lobular breast carcinoma with detection of the primary tumor after ten years. *Breast Cancer* 2007;14:333-6.
351. Doval DC, Bhatia K, Pavithran K, et al. Breast carcinoma with metastasis to the gallbladder: an unusual case report with a short review of literature. *Hepatobiliary Pancreat Dis Int* 2006;5:305-7.
352. Markelov A, Taheri H, Vunnamadala K, et al. Biliary dyskinesia as a rare presentation of metastatic breast carcinoma of the gallbladder: a case report. *Case Rep Pathol* 2011;2011:806570.
353. Di Vita M, Zanghì A, Lanzafame S, et al. Gallbladder metastases of breast cancer: from clinical-pathological patterns to diagnostic and therapeutic strategy. *Clin Ter* 2011;162:451-6.
354. Urade T, Oka S, Iimori S, et al. A resected case of gallbladder metastasis with symptoms of acute cholecystitis in multiple metastatic ductal carcinoma of the breast. *Clin J Gastroenterol* 2019;12:52-6.
355. Zamkowski M, Kąkol M, Makarewicz W, et al. Patient with metastatic breast cancer presenting as acute cholecystitis with one-year survival on hormonotherapy. *Pol Przegl Chir* 2017;89:46-9.
356. Abdelilah B, Mohamed O, Yamoul R, et al. Acute cholecystitis as a rare presentation of metastatic breast carcinoma of the gallbladder: A case report and review of the literature. *Pan Afr Med J* 2014;17:216.
357. Manouras A, Lagoudianakis EE, Genetzakis M, et al. Metastatic breast carcinoma initially presenting as acute cholecystitis: a case report and review of the literature. *Eur J Gynaecol Oncol* 2008;29:179-81.
358. Zagouri F, Sergentanis TN, Koulocheri D, et al. Bilateral synchronous breast carcinomas followed by a metastasis to the gallbladder: a case report. *World J Surg Oncol* 2007;5:101.
359. Bartolotti M, Franceschi E, Di Battista M, et al. Cytologically confirmed splenic metastases in breast cancer. *Future Oncol* 2012;8:1495-500.
360. El Fadli M, Kerrou K, Alaoui Mhamdi H, et al. Breast cancer metastasis to the spleen: a case report and literature review. *Oxf Med Case Reports* 2017;2017:omx069.
361. Sufficool K, Wang J, Doherty S. Isolated splenic metastasis from carcinoma of the breast: a case report. *Diagn Cytopathol* 2013;41:914-6.
362. Foroudi F, Ahern V, Peduto A. Splenosis mimicking metastases from breast carcinoma. *Clin Oncol (R Coll Radiol)* 1999;11:190-2.
363. Chapel F, Baume D, Bereder JM. Unusual vascular changes in the red pulp of the spleen accompanying breast carcinoma metastasis. *Pathol Res Pract* 1999;195:53-6; discussion 57-8.
364. Cummings OW, Mazur MT. Breast carcinoma diffusely metastatic to the spleen. A report of two cases presenting as idiopathic thrombocytopenic purpura. *Am J Clin Pathol* 1992;97:484-9.
365. Kykalos S, Mantas D, Dimitroulis D, et al. A rare case of breast cancer metastasis. *Breast Dis* 2010;31:53-5.
366. Mhamdi HA, Kourie HR, Jungels C, et al. Adenoid cystic carcinoma of the breast - an aggressive presentation with pulmonary, kidney, and brain metastases: a case report. *J Med Case Rep* 2017;11:303.
367. Nasu H, Miura K, Baba M, et al. Breast cancer metastatic to the kidney with renal vein involvement. *Jpn J Radiol* 2015;33:107-11.

368. Karczmarek-Borowska B, Bukala A, Syrek-Kaplita K, et al. A Rare Case of Breast Malignant Phyllodes Tumor With Metastases to the Kidney: Case Report. *Medicine (Baltimore)* 2015;94:e1312.
369. Wu AJ, Mehra R, Hafez K, et al. Metastases to the kidney: a clinicopathological study of 43 cases with an emphasis on deceptive features. *Histopathology* 2015;66:587-97.
370. Herzberg AJ, Bossen EH, Walther PJ. Adenoid cystic carcinoma of the breast metastatic to the kidney. A clinically symptomatic lesion requiring surgical management. *Cancer* 1991;68:1015-20.
371. Al Ibraheemi AA. Case report of metastatic invasive breast lobular carcinoma to the urinary bladder. *Int J Hematol Oncol Stem Cell Res* 2016;10:51-5.
372. Jordan LA, Green L. Late breast cancer metastasis to the urinary bladder presenting with bilateral hydronephrosis. *Radiol Case Rep* 2018;13:1238-41.
373. Kase AM, Menke D, Tan W. Breast cancer metastasis to the bladder: a literature review. *BMJ Case Rep* 2018. doi: 10.1136/bcr-2017-222031.
374. Xiao GQ, Chow J, Unger PD. Metastatic tumors to the urinary bladder: clinicopathologic study of 11 cases. *Int J Surg Pathol* 2012;20:342-8.
375. Vulcano E, Montesano M, Battista C, et al. Urinary complications from breast cancer metastasis: case report and review of the literature. *G Chir* 2010;31:243-5.
376. Gatti G, Zurrada S, Gilardi D, et al. Urinary bladder metastases from breast carcinoma: review of the literature starting from a clinical case. *Tumori* 2005;91:283-6.
377. Soon PS, Lynch W, Schwartz P. Breast cancer presenting initially with urinary incontinence: a case of bladder metastasis from breast cancer. *Breast* 2004;13:69-71.
378. Elia G, Stewart S, Makhuli ZN, et al. Metastatic breast cancer diagnosed during a work-up for urinary incontinence: a case report. *Int Urogynecol J Pelvic Floor Dysfunct* 1999;10:39-42.
379. Gabsi A, Yahiaoui Y, Zenhani A, et al. Ureteral metastasis in carcinoma of the breast. *Urol Case Rep* 2018;21:38-40.
380. Zunarelli E, Pollastri CA, Calo M, et al. Metastatic breast carcinoma presenting as urinoma. *Pathologica* 1995;87:712-4.
381. Mizuyama Y, Shinto O, Tamura T, et al. A case of solitary adrenal metastasis from breast cancer successfully resected by laparoscopy. *Gan To Kagaku Ryoho* 2013;40:2351-3.
382. Andjelić-Dekić N, Božović-Spasojević I, Milošević S, et al. A rare case of isolated adrenal metastasis of invasive ductal breast carcinoma. *Srp Arh Celok Lek* 2014;142:597-601.
383. Paunovic I, Zivaljevic V, Diklic A, et al. Prognostic parameters after surgery for adrenal metastases: a single institution experience. *Acta Chir Belg* 2014;114:198-202.
384. Demirci U, Buyukberber S, Cakir T, et al. Isolated mucinous adrenal metastasis in a breast cancer patient. *J Oncol Pharm Pract* 2011;17:444-7.
385. Liu XJ, Shen P, Wang XF, et al. Solitary adrenal metastasis from invasive ductal breast cancer: an uncommon finding. *World J Surg Oncol* 2010;8:7.
386. Bausewein C, Kühnbach R, Haberland B. Adrenal insufficiency caused by bilateral adrenal metastases -- a rare treatable cause for recurrent nausea and vomiting in metastatic breast cancer. *Onkologie* 2006;29:203-5.
387. Davì MV, Francia G, Brazzarola P, et al. An unusual case of adrenal failure due to isolated metastases of breast cancer. *J Endocrinol Invest* 1996;19:488-9.
388. Colak T, Akca T, Dirlik M, et al. Signet ring cell carcinoma of the breast as a source of pelvic floor metastatic mass. A case report. *Acta Chir Belg* 2005;105:224-6.
389. Kashiwagi S, Asano Y, Watanabe M, et al. Four cases of meningeal metastasis originating from breast cancer. *Gan To Kagaku Ryoho* 2012;39:1917-9.
390. Laurencet FM, Anchisi S, Tullen E, et al. Mental neuropathy: report of five cases and review of the literature. *Crit Rev Oncol Hematol* 2000;34:71-9.
391. Higashi H, Fukutomi T, Watanabe T, et al. Seven cases of breast cancer recurrence limited to the central nervous system without other visceral metastases. *Breast Cancer* 2000;7:153-6.
392. Mego M, Sycova-Mila Z, Obertova J, et al. Intrathecal administration of trastuzumab with cytarabine and methotrexate in breast cancer patients with leptomeningeal carcinomatosis. *Breast* 2011;20:478-80.
393. Rao R, Hoda SA, Marcus A, et al. Metastatic Breast Carcinoma in Cerebrospinal Fluid: A Cytopathological Review of 15 Cases. *Breast J* 2017;23:456-60.
394. Alnajjar H, Rosen L, Javidiparsijani S, et al. Prognostic Markers and Histologic Subtypes in Patients with Meningeal Carcinomatosis in Breast Cancer. *Acta Cytol* 2017;61:140-4.
395. Seki S, Kamide T, Tamase A, et al. Intraparenchymal hemorrhage from dural metastasis of breast cancer mimicking meningioma. *Neuroradiol J* 2016;29:179-82.
396. Pan Z, Yang G, Yuan T, et al. 'Hot cross bun' sign with leptomeningeal metastases of breast cancer: a case report and review of the literature. *World J Surg Oncol* 2015;13:43.
397. Meattini I, Livi L, Saieva C, et al. Prognostic factors and clinical features in patients with leptomeningeal

- metastases from breast cancer: a single center experience. *J Chemother* 2012;24:279-84.
398. Tseng SH, Liao CC, Lin SM, et al. Dural metastasis in patients with malignant neoplasm and chronic subdural hematoma. *Acta Neurol Scand* 2003;108:43-6.
399. Jayson GC, Howell A, Harris M, et al. Carcinomatous meningitis in patients with breast cancer. An aggressive disease variant. *Cancer* 1994;74:3135-41.
400. Madgula IM, Hemmerdinger CM, Clark P. Metastatic breast cancer presenting as sequential cranial nerve palsy: a case report. *J Med Case Rep* 2014;8:430.
401. Gasser TG, Pospiech J, Stolke D, et al. Spinal intramedullary metastases. Report of two cases and review of the literature. *Neurosurg Rev* 2001;24:88-92.
402. Choi HC, Yoon DH, Kim SC, et al. Two separate episodes of intramedullary spinal cord metastasis in a single patient with breast cancer. *J Korean Neurosurg Soc* 2010;48:162-5.
403. Garcia R, Sallabanda K, Santa-Olalla I, et al. Robotic Radiosurgery for the Treatment of Intramedullary Spinal Cord Metastases: A Case Report and Literature Review. *Cureus* 2016;8:e609.
404. Aiello D, Mazzola R, Gregucci F, et al. Surprising complete response of intramedullary spinal cord metastasis from breast cancer: a case report and literature review. *Tumori* 2017;103:e28-30.
405. Payer S, Mende KC, Westphal M, et al. Intramedullary spinal cord metastases: an increasingly common diagnosis. *Neurosurg Focus* 2015;39:E15.
406. Hsu KC, Li TY, Chu HY, et al. Conus medullaris metastasis in breast cancer: report of a case and a review of the literature. *Surg Today* 2013;43:910-4.
407. Zebrowski A, Wilson L, Lim A, et al. Intramedullary spinal cord metastases in breast cancer are associated with improved longer-term systemic control. *Future Oncol* 2010;6:1517-9.
408. Watanabe M, Nomura T, Toh E, et al. Intramedullary spinal cord metastasis: a clinical and imaging study of seven patients. *J Spinal Disord Tech* 2006;19:43-7.
409. Villegas AE, Guthrie TH. Intramedullary spinal cord metastasis in breast cancer: clinical features, diagnosis, and therapeutic consideration. *Breast J* 2004;10:532-5.
410. Chen YJ, Fan FS, Chen PM. Intramedullary spinal cord metastasis: a case report. *Zhonghua Yi Xue Za Zhi (Taipei)* 1995;56:58-61.
411. Schwechheimer K, Lemminger JM. Intramedullary metastases: report of 4 cases and review of the literature. *Clin Neuropathol* 1985;4:28-37.
412. Moffie D, Stefanko SZ. Intramedullary metastasis. *Clin Neurol Neurosurg* 1980;82:199-202.
413. West CG. Spinal subarchnoid metastatic spread from non-neuraxial primary neoplasms. Case report. *J Neurosurg* 1979;51:251-3.
414. Della Puppa A, Dal Pos S, Zovato S, et al. Solitary intraventricular brain metastasis from a breast carcinoma. *J Neurooncol* 2010;97:123-6.
415. Sajko T, Rotim K, Kudelić N, et al. Intraventricular location of metastatic breast carcinoma: a case report. *Acta Clin Croat* 2009;48:55-8.
416. Saha S, Kumar A, Kumar C, et al. Paraneoplastic cerebellar degeneration as a manifestation of metastatic recurrent carcinoma breast: rare scenario. *BMJ Case Rep* 2018. doi: 10.1136/bcr-2017-222575.
417. Singh J, Majumdar K, Gupta R, et al. Cerebellar metastases of recurrent phyllodes tumor breast; a rare phenomenon reflecting the unpredictable outcome. *J Cancer Res Ther* 2015;11:1035.
418. Rowe JJ, Prayson RA. Metastatic malignant phyllodes tumor involving the cerebellum. *J Clin Neurosci* 2015;22:226-7.
419. Artico M, Scarpinati M, Salvati M, et al. Late intraneural metastasis of the brachial plexus from mammary carcinoma. Report of a case. *J Neurosurg Sci* 1991;35:51-3.
420. Backhouse O, Simmons I, Frank A, et al. Optic nerve breast metastasis mimicking meningioma. *Aust N Z J Ophthalmol* 1998;26:247-9.
421. Cherekaev VA, Lasunin NV, Stepanian MA, et al. Breast carcinoma metastasis to the optic nerve: case report and review of literature. *Zh Vopr Neirokhir Im N N Burdenko* 2013;77:42-8; discussion 48.
422. Suryanarayanan R, Dezso A, Ramsden RT, et al. Metastatic carcinoma mimicking a facial nerve schwannoma: the role of computerized tomography in diagnosis. *J Laryngol Otol* 2005;119:1010-2.
423. Ito K, Miyahara T, Goto T, et al. Solitary metastatic cauda equina tumor from breast cancer -case report-. *Neurol Med Chir (Tokyo)* 2010;50:417-20.
424. Schulz M, Lamont D, Muthu T, et al. Metastasis of breast cancer to a lumbar spinal nerve root ganglion. *Spine (Phila Pa 1976)* 2009;34:E735-9.
425. Zingale A, Ponzo G, Ciavola G, et al. Metastatic breast cancer delayed brachial plexopathy. A brief case report. *J Neurosurg Sci* 2002;46:147-9.
426. Hirota N, Fujimoto T, Takahashi M, et al. Isolated trigeminal nerve metastases from breast cancer: an unusual cause of trigeminal mononeuropathy. *Surg Neurol*

- 1998;49:558-61.
427. Breadon GE, Cody DT, Weiland LH. Facial palsy: unusual etiology. *Laryngoscope* 1977;87:26-34.
428. Reyes KB, Lee HY, Ng I, et al. Abducens (sixth) nerve palsy presenting as a rare case of isolated brainstem metastasis from a primary breast carcinoma. *Singapore Med J* 2011;52:e220-2.
429. de Ceuster LM, de Bruijn SF, Hoffmann CF. Miliary cerebral calcifications: A rare presentation of breast cancer metastasis. *Neurology* 2016;86:879.
430. Chakrabarti I, Ghosh N, Giri A. Cytologic diagnosis of undifferentiated high grade pleomorphic sarcoma of breast presenting with brain metastasis. *J Neurosci Rural Pract* 2013;4:188-90.
431. Low YY, Thomas J, Wan WK, et al. Brain metastases as a cause of malignant cerebrospinal fluid ascites: case report and review of the literature. *CNS Oncol* 2012;1:29-37.
432. Modi M, Singla V, Bhatia R, et al. Isolated nuclear oculomotor nerve palsy due to a solitary midbrain metastasis: a rare presentation. *Indian J Ophthalmol* 2006;54:286-7.
433. Saisho S, Takashima S, Ohsumi S, et al. Two cases with long-term disease-free survival after resection and radiotherapy for solitary brain metastasis from breast cancer with extensive nodal metastases. *Breast Cancer* 2005;12:221-5.
434. Chou TM, Demer JL. Isolated inferior rectus palsy caused by a metastasis to the oculomotor nucleus. *Am J Ophthalmol* 1998;126:737-40.
435. Koller M, Ram Z, Findler G, et al. Brain metastasis: a rare manifestation of adenoid cystic carcinoma of the breast. *Surg Neurol* 1986;26:470-2.
436. Paget S. The distribution of secondary growths in cancer of the breast. 1889. *Cancer Metastasis Rev* 1989;8:98-101.
437. Talmadge JE, Fidler IJ. AACR centennial series: the biology of cancer metastasis: historical perspective. *Cancer Res* 2010;70:5649-69.
438. Virchow R. Cellular pathology. As based upon physiological and pathological histology. Lecture XVI--Atheromatous affection of arteries. 1858. *Nutr Rev* 1989;47:23-5.
439. Langley RR, Fidler IJ. Tumor cell-organ microenvironment interactions in the pathogenesis of cancer metastasis. *Endocr Rev* 2007;28:297-321.
440. Ribatti D, Mangialardi G, Vacca A. Stephen Paget and the 'seed and soil' theory of metastatic dissemination. *Clin Exp Med* 2006;6:145-9.
441. Cichoń S, Anielski R, Konturek A, et al. Metastases to the thyroid gland: seventeen cases operated on in a single clinical center. *Langenbecks Arch Surg* 2006;391:581-7.
442. Chen H, Nicol TL, Udelsman R. Clinically significant, isolated metastatic disease to the thyroid gland. *World J Surg* 1999;23:177-80; discussion 181.
443. Pearson CM. Incidence and type of pathologic alterations observed in muscle in a routine autopsy survey. *Neurology* 1959;9:757-66.
444. James JJ, Evans AJ, Pinder SE, et al. Bone metastases from breast carcinoma: histopathological - radiological correlations and prognostic features. *Br J Cancer* 2003;89:660-5.
445. Seely S. Possible reasons for the high resistance of muscle to cancer. *Med Hypotheses* 1980;6:133-7.
446. Djaldetti M, Sredni B, Zigelman R, et al. Muscle cells produce a low molecular weight factor with anti-cancer activity. *Clin Exp Metastasis* 1996;14:189-96.
447. Caramella E, Bruneton JN, Roux P, et al. Metastases of the digestive tract. Report of 77 cases and review of the literature. *Eur J Radiol* 1983;3:331-8.
448. Puglisi M, Varaldo E, Assalino M, et al. Anal metastasis from recurrent breast lobular carcinoma: a case report. *World J Gastroenterol* 2009;15:1388-90.
449. Van Trappen P, Serreyn R, Elewaut AE, et al. Abdominal pain with anorexia in patients with breast carcinoma. *Ann Oncol* 1998;9:1243-5.
450. Nazareno J, Taves D, Preiksaitis HG. Metastatic breast cancer to the gastrointestinal tract: a case series and review of the literature. *World J Gastroenterol* 2006;12:6219-24.
451. Pectasides D, Psyri A, Pliarchopoulou K, et al. Gastric metastases originating from breast cancer: report of 8 cases and review of the literature. *Anticancer Res* 2009;29:4759-63.
452. Ambroggi M, Stroppa EM, Mordenti P, et al. Metastatic breast cancer to the gastrointestinal tract: report of five cases and review of the literature. *Int J Breast Cancer* 2012;2012:439023.
453. Peters IT, van Zwet EW, Smit VT, et al. Prevalence and Risk Factors of Ovarian Metastases in Breast Cancer Patients <41 Years of Age in the Netherlands: A Nationwide Retrospective Cohort Study. *PLoS One* 2017;12:e0168277.
454. Tian W, Zhou Y, Wu M, et al. Ovarian metastasis from breast cancer: a comprehensive review. *Clin Transl Oncol* 2019;21:819-27.
455. Abdalla AS, Lazarevska A, Omer MM, et al. Metastatic Breast Cancer to the Cervix Presenting with Abnormal Vaginal Bleeding During Chemotherapy: A Case Report and Literature Review. *Chirurgia (Bucur)* 2018;113:564-70.

456. Zannoni GF, Vellone VG, Petrillo M, et al. Secondary malignancies of the uterine cervix: a potential diagnostic pitfall. *Virchows Arch* 2013;463:23-9.
457. Ayhan A, Guvenal T, Salman MC, et al. The role of cytoreductive surgery in nongenital cancers metastatic to the ovaries. *Gynecol Oncol* 2005;98:235-41.
458. Borst MJ, Ingold JA. Metastatic patterns of invasive lobular versus invasive ductal carcinoma of the breast. *Surgery* 1993;114:637-41; discussion 641-2.
459. Harris M, Howell A, Chrissohou M, et al. A comparison of the metastatic pattern of infiltrating lobular carcinoma

- and infiltrating duct carcinoma of the breast. *Br J Cancer* 1984;50:23-30.
460. Dixon AR, Ellis IO, Elston CW, et al. A comparison of the clinical metastatic patterns of invasive lobular and ductal carcinomas of the breast. *Br J Cancer* 1991;63:634-5.
461. Lamovec J, Bracko M. Metastatic pattern of infiltrating lobular carcinoma of the breast: an autopsy study. *J Surg Oncol* 1991;48:28-33.
462. Jain S, Fisher C, Smith P, et al. Patterns of metastatic breast cancer in relation to histological type. *Eur J Cancer* 1993;29A:2155-7.

Cite this article as: Di Micco R, Santurro L, Gasparri ML, Zuber V, Fiacco E, Gazzetta G, Smart CE, Valentini A, Gentilini OD. Rare sites of breast cancer metastasis: a review. *Transl Cancer Res* 2019;8(Suppl 5):S518-S552. doi: 10.21037/tcr.2019.07.24