



STX4 expression is associated with classification, clinical stage and lymphatic metastasis in ovarian cancer

Wenfeng Ye^{1,2#}, Dawei Zhu^{1#}, Bin Xu^{1#}, Ming Xu², Yingting Liu¹, Jun Xie³, Qi Wang¹, Jingting Jiang^{1,4}

¹Department of Tumor Biological Treatment, ²Department of Obstetrics and Gynecology, ³Department of pathology, The Third Affiliated Hospital, Soochow University, Changzhou 213003, China; ⁴Jiangsu Engineering Research Center for Tumor Immunotherapy, Changzhou 213003, China

Contributions: (I) Conception and design: J Jiang, W Ye, D Zhu; (II) Administrative support: J Jiang; (III) Provision of study materials or patients: M Xu, J Xie; (IV) Collection and assembly of data: W Ye; (V) Data analysis and interpretation: B Xu; (VI) Manuscript writing: All authors; (IV) Final approval of manuscript: All authors.

[#]These authors contributed equally to this work.

Correspondence to: Jingting Jiang, MD, PhD. Department of Tumor Biological Treatment and Research Center for Cancer Immunotherapy Technology of Jiangsu Province, The Third Affiliated Hospital, Soochow University, Changzhou 213003, China. Email: jiangjingting@suda.edu.cn.

Background: Ovarian cancer (OC) is one of the most common malignant tumors in female reproductive system and 55–75% of the patients relapsed after surgery and standard postoperative chemotherapy and radiotherapy. The SNARE proteins, syntaxin4 (STX4) is localized in the plasma membrane to drive vesicle fusion which of integrin-containing vesicles with the plasma membrane is the final step of integrins delivery and play a role in the occurrence, development, invasion and metastasis of cancer cells.

Methods: Immunohistochemistry analysis was used to investigate the correlation between STX4 expression and clinicopathological features of epithelial OC patients.

Results: Our study demonstrated that STX4 was positively expressed in OC tissues and the expression of STX4 was positively correlated with the clinical stage of human OC classification and node metastasis, suggesting that STX4 was involved in the occurrence and development of OC.

Conclusions: Our findings suggested that STX4-targeted treatment could be used as a potential therapeutic strategy for OC.

Keywords: Ovarian cancer (OC); syntaxin4 (STX4); clinicopathological feature

Submitted Dec 05, 2018. Accepted for publication Feb 25, 2019.

doi: 10.21037/tcr.2019.02.11

View this article at: <http://dx.doi.org/10.21037/tcr.2019.02.11>

Introduction

Ovarian cancer (OC) is one of the most common malignant tumors in female reproductive system. In China (1), OC is the most frequent cause of cancer-related death from gynecological malignancies, and the majority of patients are diagnosed at an advanced stage (2). Furthermore, 55–75% of the patients relapsed after surgery and standard postoperative chemotherapy and radiotherapy, and are rarely cured after recurrence. The 5-year survival rate for OC patients at stage IIIc and IV is 29% and 13%, respectively (3,4). Therefore, it is urgently necessary to understand the molecular mechanism underlying recurrence and

progression of OC and discover specific molecular markers for the diagnosis and treatment of OC. New treatments are needed for advanced and recurrent OC. More and more attention has been paid to immunotherapy, a new adjuvant therapy, to break the body's immune tolerance to tumor and improve the immune response of the body's immune system to cancer.

Metastasis, including local tumor growth, migration and invasion of cancer cells into lymphatic and blood vessels, survive and spread in the circulation, and extravasation and establishment of secondary colonies at distant sites (5), is responsible for more than 90% of cancer deaths. As a family of heterodimeric receptors for cell adhesion to the

extracellular matrix (ECM), integrins, such as fibronectin, laminin, collagen and vitronectin (6), play critical roles in cell migration, cancer progression and metastasis. As transmembrane proteins, integrins are transported in vesicles and delivered to the cell surface by vesicular trafficking. Fusion of integrin-containing vesicles with the plasma membrane is the final step of integrin delivery. The SNARE (soluble N-ethylmaleimide-sensitive factor attachment protein receptor) proteins, syntaxin (STX) 1, 2, 3 and 4, are localized in the plasma membrane to drive vesicle fusion. Studies have shown that the SNARE proteins play a fundamental role in the occurrence, development, invasion and metastasis of cancer cells, and more and more attention has been paid to them as therapeutic targets for various tumors (7,8). STX is one of the components of SNARE family, which consists of three groups of proteins, including synaptosomal-associated protein (SNAP), STX and vesicle-associated membrane protein (VAMP) (9-11). STX family proteins are composed of 16 members, including STX1, STX2, STX3 and STX4, which are localized in the plasma membrane. STXs have been linked to a variety of malignancies. For example, STX8 can affect epidermal growth factor receptor (EGFR) in glioblastoma. The signal transduction of growth factor is involved in tumor development process. Previous data have suggested that STX3- or STX4-dependent integrin trafficking is important in migration and survival of cancer cells, which may be valuable targets for cancer therapy (12).

However, only very few studies have established a correlation between STX4 expression and OC progression and differentiation. In the present study, we aimed to investigate the correlation between STX4 expression and clinicopathological features of epithelial OC patients. Our findings suggested that STX4-targeted treatment could be used as a potential therapeutic strategy for OC.

Methods

Clinical samples

All clinical tissue samples were obtained from the Third Affiliated Hospital of Soochow University (Changzhou, China) between January 2008 and January 2017. These specimens, including 80 cases of primary epithelial OC (five well-differentiated cases, eight moderately differentiated cases, 52 poorly differentiated cases and 15 undifferentiated cases in reports), one case of borderline epithelial OC and 12 cases of benign epithelial OC, were collected from

patients who underwent surgery. Detailed clinicopathologic variables of the patients are summarized in *Table 1*. The study design was approved by the ethics committee of Soochow University (Changzhou, China; No. 2018046). Written informed consent was obtained from every patient.

Immunohistochemistry

The primary antibodies used for immunohistochemistry were commercially available, including STX-4 antibody (ab77037, Abcams, CO, USA). Formalin-fixed, paraffin-embedded consecutive sections (4- μ m thick) were heated at 85 °C for 2 h and then cooled at room temperature for 20 min. The slides were immersed in dimethylbenzene three times for deparaffinage 15 min each time and then consecutively hydrated in 100%, 95% and 75% ethanol for 5 min. For antigen retrieval, slides were heated at 125 °C for 5 min in 2% EDTA-citrate antigen retrieval solution (MVS-0099, Fuzhou Maixin Biotech. Co., Ltd., Fuzhou, China) in a pressure cooker. Subsequently, slides were rinsed with PBS (PBS-0061, Fuzhou Maixin Biotech. Co., Ltd., Fuzhou, China) for three times and then immersed in hydrogen peroxide at room temperature for 30 min to block endogenous peroxidase, followed by incubation with 3% BSA at 37 °C for 30 min to block nonspecific binding. Next, the slides were incubated with primary antibody against STX4 (1:200 diluted using antibody diluent) at 4 °C for 14 h. A MaxVision™ rapid immunohistochemistry kit (KIT-5020, Fuzhou Maixin Biotech. Co., Ltd., Fuzhou, China) was used in the present study, and the binding process of secondary antibody was carried out according to the manufacturer's instructions. A DAB substrate kit (DAB-0031, Fuzhou Maixin Biotech. Co., Ltd., Fuzhou, China) was employed and its staining process was conducted according to the manufacturer's instructions. After staining, the sections were counterstained using hematoxylin, followed by dehydration through ethanol and xylene.

Evaluation of immunohistochemical staining and statistical analysis

All slides were independently examined by two senior pathologists who were blinded to the clinical parameters of patients. The immunostaining density of STX4 was assessed according to the H-score method: H-score = (% unstained tumor cells \times 0) + (% weakly stained tumor cells \times 1) + (% moderately stained tumor cells \times 2) + (% strongly stained tumor cells \times 3). The H-scores ranged from 0 (100% negative

Table 1 Correlation between clinicopathological features and STX4 expression

Variables	Patients (n)	STX4 immunostaining score	Z/ χ^2	P
T character			4.315	<0.001
Benign tumors	12	70.00±60.49		
Malignancy tumors	80	185.18±69.20		
T classification			2.418	0.016
Serous adenocarcinoma	69	169.41±79.90		
Mucinous adenocarcinoma	7	90.00±70.30		
N metastasis			2.069	0.039
Y	8	223.75±25.60		
N	29	177.41±63.65		
Clinical stage			2.325	0.020
I	19	157.11±65.92		
II/III/IV	61	193.92±68.37		
Differentiation			3.718	0.156
Poorly differentiated	52	208.73±48.66		
Moderately differentiated	8	155.63±74.04		
Well-differentiated	5	175.00±95.26		

Due to statistical reasons, one borderline OC patient and two endometrioid adenocarcinoma patients were not included. STX4, syntaxin 4; SD, standard deviation; T, tumor; N, lymph node.

tumor cells) to 300 (100% strong staining tumor cells). Results from the two pathologists were averaged and used in the statistical analysis. All data were expressed as the mean \pm standard deviation ($M \pm SD$). Statistical analysis was performed using SPSS version 22.0 (SPSS Inc., St. Chicago, IL, USA). The correlation among all the groups was compared by Kruskal-Wallis test and Mann-Whitney U test. $P < 0.05$ was considered statistically significant.

Results

Immunohistochemistry

STX4 staining was observed in various proportions of tumor cells and localized in cell membrane (brown granular). In all 93 cases, the average H-score of STX4 expression in benign patients and OC patients was 70.00 ± 60.49 and 185.18 ± 69.20 , respectively ($u = 4.315$, $P < 0.05$; *Table 1* and *Figure 1*). The H-score of STX4 for one patient with borderline epithelial tumor, was 265. In all the patients with epithelial OC, 69 cases (86.25%) were serous cystadenocarcinoma, and seven cases were mucinous

cystadenocarcinoma (8.75%), with a staining score of 169.41 ± 79.90 and 90.00 ± 70.30 , respectively ($u = 2.418$, $P < 0.05$; *Table 1* and *Figure 2*). The staining H-score of STX4 in patients with endometrioid carcinoma (two cases, 2.5%) was 167.50 ± 3.54 , and there was no statistical significance between endometrioid carcinoma and serous cystadenocarcinoma ($P > 0.05$; *Figure 2*).

Relationship with clinicopathological variables

In the 80 epithelial OC patients, 19 cases (23.75%) were in early stage (stage I), and 61 cases were in late stage (76.25%), including stage II, III and IV. The staining score of STX4 in patients of early and late stages was 157.11 ± 65.92 and 193.92 ± 68.37 , respectively ($u = 2.325$, $P < 0.05$). Additionally, the staining score of STX4 in stage II was 208.57 ± 64.61 , which was significantly different from that of stage I ($P < 0.05$).

Among 80 epithelial OC patients, lymphadenectomy was performed on 37 cases, in which 29 patients (78.38%) had no lymphatic metastasis and 8 patients (21.62%) exhibited lymphatic metastasis, with a staining score of 177.41 ± 63.65 and 223.75 ± 25.60 , respectively ($u = 2.069$, $P < 0.05$; *Table 1*).

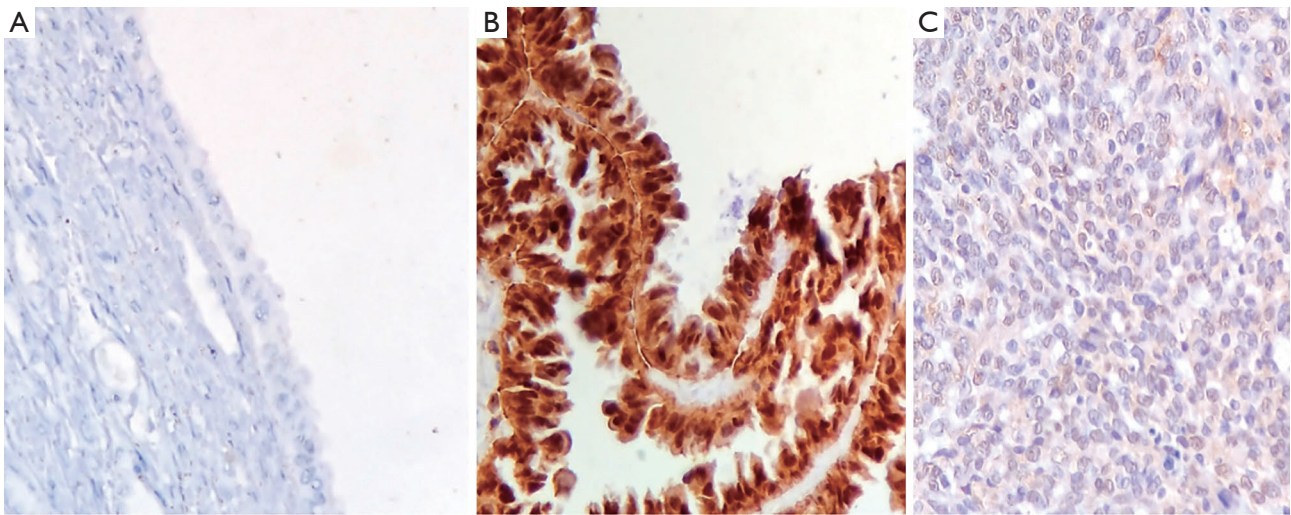


Figure 1 STX4 immunohistochemical staining in three types of OC (HE ×200). (A) Benign ovarian tumor; (B) borderline ovarian tumor; (C) OC. STX4, syntaxin 4; OC, ovarian cancer.

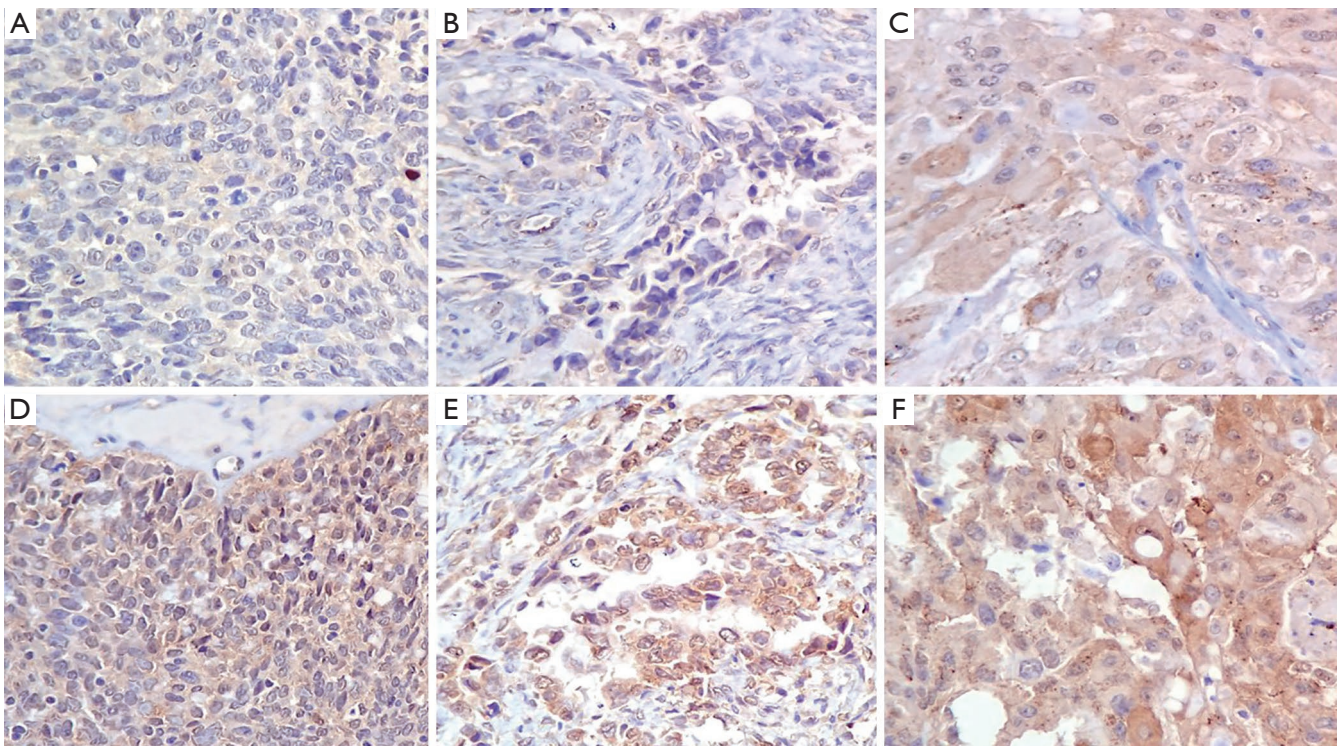


Figure 2 STX4 immunohistochemical staining in different types of OC (HE ×200). (A) Low intensity STX4 expression in serous adenocarcinoma; (B) low intensity STX4 expression in mucinous adenocarcinoma; (C) low intensity STX4 expression in endometrioid adenocarcinoma; (D) high intensity STX4 expression in serous adenocarcinoma; (E) high intensity STX4 expression in mucinous adenocarcinoma; (F) high intensity STX4 expression in endometrioid adenocarcinoma. OC. STX4, syntaxin 4; OC, ovarian cancer.

In the 80 epithelial OC patients, 52 cases (65.00%) were poorly differentiated, eight cases (10.00%) were moderately differentiated, and five patients (6.25%) were well differentiated, with a staining score of 208.73 ± 48.66 , 155.63 ± 74.04 and 175.00 ± 95.26 , respectively ($Z=3.718$, $P>0.05$; *Table 1*). However, there was no statistical significance among these subgroups.

Discussion

Study has shown that depletion of *STX4* reduces the proportion of cells forming active invadopodia by >50%. *STX4* and synaptosomal-associated protein 23 (SNAP23) are associated with vesicle-associated membrane protein 7 (VAMP7) possibly in a complex, and function to deliver membrane type-1 matrix metalloproteinase (MT1-MMP) to invadopodia during degradation of ECM by MDA-MB-231 breast tumor cells (13). Recent models suggest that tumor cell invasion can be mediated by subcellular structures called invadopodia, which can facilitate MMP-mediated degradation of ECM (14). Evidence from *in vivo* studies has supported that invadopodia plays a role in the dissemination of tumor cell populations (15,16). Membrane trafficking of proteins to invadopodia is required for their formation and function in support of tumor cell invasion (17).

In HeLa cervical adenocarcinoma cells and PANC-1 pancreatic adenocarcinoma cells, depletion of *STX4* reduces the cell surface expressions of $\alpha 5\beta 1$ and $\alpha 3\beta 1$ integrins, indicating that *STX4* is involved in $\alpha 5\beta 1$ and $\alpha 3\beta 1$ trafficking to the cell surface (12). In addition, depletion of *STX4* inhibits cell adhesion to fibronectin and chemotactic cell migration, and triggers apoptosis, suggesting that *STX4*-mediated integrin trafficking is important for migration and survival of cancer cells. In migrating cells, *STX4* has been shown to associate with lipid rafts, which are concentrated at the leading edge to establish front-rear polarity (18,19). In macrophages, *STX4* forms a complex with VAMP3 and SNAP-23 to deliver $\alpha 5\beta 1$ integrin to the cell surface (20). Study has indicated that cells lacking *STX4* have multiple actin-rich spindly protrusions, and they are unable to exocytose VAMP3-positive recycling endosomes. The multiple sites of protrusion in cells that lack *STX4* indicate a defect in cell polarity in these cells (21).

Immunocytochemistry reveals that transient transfection of AGS cells, a human gastric epithelial cancer cell line, with dominant-negative mutant *STX 4* decreases the expression of plasma membrane MT1-MMP. MMPs also play promoting roles in cancer invasion and metastasis (2).

For example, MMPs regulate the degradation of ECM surrounding the tumor surface (22) and enhance neovascularization during invasion and metastasis of cancer (23). In neuronal cells, *STX4* has recently been shown to define a site of exocytosis for AMPA receptor-containing recycling compartments at the tips of dendritic spines that direct membrane fusion and regulate postsynaptic plasticity (24). The location of *STX4* to the basolateral membrane in polarized epithelial cells is thought to regulate delivery of cargo specifically located on the basolateral membrane (25,26). In all above-mentioned cases, *STX4* plays a fundamental role in the polarized delivery of vesicles to specific locations on the plasma membrane, suggesting that *STX4* acts to define sites of focal exocytosis in the plasma membrane. Taken together, these results suggest that *STX4*/SNAP23 is a key regulator in focal exocytosis of recycling compartments in the plasma membrane both in macrophages and other cell types (21).

Our study demonstrated that *STX4* was positively expressed in OC tissues. Meanwhile, the expression of *STX4* was positively correlated with the clinical stage of human OC, classification and node metastasis, suggesting that *STX4* was involved in the occurrence and development of OC. Based on our findings, we speculated that the activation of *STX4* might promote the proliferation and invasion of cancer cells, leading the development of OC. Since the operation in 80 of the 90 cases we analyzed was performed during the last 3 years, the information on overall survival (OS) and disease-free survival (DFS) could not be determined. Therefore, the relationship between *STX4* expression and OS or DFS was not assessed in the present study.

Collectively, we showed that *STX4* was over-expressed in OC, and such abnormal expression of *STX4* promoted the progression of OC, indicating that the invasiveness of tumor cells might be possibly inhibited by targeting *STX4* in cancer cells. Taken together, our findings provided an experimental foundation for therapeutic strategy, and suggested that RNA interference technology or other relevant methods might be used to decrease the expression of *STX4* and suppress the invasion of OC cells. However, the effects of *STX4* on the clinical outcomes of OC needed to be further investigated, including both *in vitro* experiment and animal model.

Acknowledgments

Funding: Project supported by the National Key R&D

Program (No. 2018YFC1313400), the National Science and Technology Supporting Program (No. 2015BAI12B12), the Joint Research Fund for Overseas Chinese, Hong Kong and Macao Scholars (No. 31729001), the National Natural Science Foundation of China (No. 31570877, No. 31570908), the Key R&D Project of Science and Technology Department of Jiangsu Province (BE2018645).

Footnote

Conflicts of Interest: All authors have completed the ICMJE uniform disclosure form (available at <http://dx.doi.org/10.21037/tcr.2019.02.11>). The authors have no conflicts of interest to declare.

Ethical Statement: The authors are accountable for all aspects of the work in ensuring that questions related to the accuracy or integrity of any part of the work are appropriately investigated and resolved. The study was conducted in accordance with the Declaration of Helsinki (as revised in 2013). The study design was approved by the ethics committee of Soochow University (Changzhou, China; No. 2018046). Written informed consent was obtained from every patient.

Open Access Statement: This is an Open Access article distributed in accordance with the Creative Commons Attribution-NonCommercial-NoDerivs 4.0 International License (CC BY-NC-ND 4.0), which permits the non-commercial replication and distribution of the article with the strict proviso that no changes or edits are made and the original work is properly cited (including links to both the formal publication through the relevant DOI and the license). See: <https://creativecommons.org/licenses/by-nc-nd/4.0/>.

References

- Li J, Yang W, Wu X. Prognostic factors and role of salvage surgery in chemorefractory ovarian germ cell malignancies: a study in Chinese patients. *Gynecol Oncol* 2007;105:769-75.
- Kim PS, Djazayeri S, Zeineldin R. Novel nanotechnology approaches to diagnosis and therapy of ovarian cancer. *Gynecol Oncol* 2011;120:393-403.
- Chen SS, Michael A, Butler-Manuel SA. Advances in the treatment of ovarian cancer: a potential role of antiinflammatory phytochemicals. *Discov Med* 2012;13:7-17.
- Chi DS, Eisenhauer EL, Zivanovic O, et al. Improved progression-free and overall survival in advanced ovarian cancer as a result of a change in surgical paradigm. *Gynecol Oncol* 2009;114:26-31.
- Huber MA, Kraut N, Beug H. Molecular requirements for epithelial-mesenchymal transition during tumor progression. *Curr Opin Cell Biol* 2005;17:548-58.
- Hynes RO. Integrins: bidirectional, allosteric signaling machines. *Cell* 2002;110:673-87.
- Meng J, Wang J. Role of SNARE proteins in tumorigenesis and their potential as targets for novel anti-cancer therapeutics. *Biochim Biophys Acta* 2015;1856:1-12.
- Collins LE, DeCoursey J, Soledad di Luca M, et al, An Emerging Role for SNARE Proteins in Dendritic Cell Function. *Front Immunol* 2015;6:133.
- Söllner T, Whiteheart SW, Brunner M, et al, SNAP receptors implicated in vesicle targeting and fusion. *Nature* 1993;362:318-24.
- Trimble WS, Cowan DM, Scheller RH. VAMP-1: a synaptic vesicle-associated integral membrane protein. *Proc Natl Acad Sci U S A* 1988;85:4538-42.
- Bennett MK, Calakos N, Scheller RH. Syntaxin: a synaptic protein implicated in docking of synaptic vesicles at presynaptic active zones. *Science* 1992;257:255-9.
- Day P, Riggs KA, Hasan N, et al. Syntaxins 3 and 4 mediate vesicular trafficking of $\alpha 5\beta 1$ and $\alpha 3\beta 1$ integrins and cancer cell migration. *Int J Oncol* 2011;39:863-71.
- Williams KC, McNeilly RE, Coppolino MG. SNAP23, Syntaxin4, and vesicle-associated membrane protein 7 (VAMP7) mediate trafficking of membrane type 1-matrix metalloproteinase (MT1-MMP) during invadopodium formation and tumor cell invasion. *Mol Biol Cell* 2014;25:2061-70.
- Murphy DA, Courtneidge SA. The 'ins' and 'outs' of podosomes and invadopodia: characteristics, formation and function. *Nat Rev Mol Cell Biol* 2011;12:413-26.
- Clark ES, Brown B, Whigham AS, et al. Aggressiveness of HNSCC tumors depends on expression levels of cortactin, a gene in the 11q13 amplicon. *Oncogene* 2009;28:431-44.
- Lohmer LL, Kelley LC, Hagedorn EJ, et al. Invadopodia and basement membrane invasion in vivo. *Cell Adh Migr* 2014;8:246-55.
- Poincloux R, Lizárraga F, Chavrier P. Matrix invasion by tumour cells: a focus on MT1-MMP trafficking to invadopodia. *J Cell Sci* 2009;122:3015-24.
- Lafont F, Verkade P, Galli T, et al. Raft association of SNAP receptors acting in apical trafficking in Madin-

- Darby canine kidney cells. *Proc Natl Acad Sci U S A* 1999;96:3734-8.
19. Chamberlain LH, Gould GW. The vesicle- and target-SNARE proteins that mediate Glut4 vesicle fusion are localized in detergent-insoluble lipid rafts present on distinct intracellular membranes. *J Biol Chem* 2002;277:49750-4.
 20. Veale KJ, Offenhäuser C, Whittaker SP, et al. Recycling endosome membrane incorporation into the leading edge regulates lamellipodia formation and macrophage migration. *Traffic* 2010;11:1370-9.
 21. Veale KJ, Offenhäuser C, Murray RZ. The role of the recycling endosome in regulating lamellipodia formation and macrophage migration. *Commun Integr Biol* 2011;4:44-7.
 22. Yana I, Seiki M. MT-MMPs play pivotal roles in cancer dissemination. *Clin Exp Metastasis* 2002;19:209-15.
 23. Hiraoka N, Allen E, Apel IJ, et al. Matrix metalloproteinases regulate neovascularization by acting as pericellular fibrinolysins. *Cell* 1998;95:365-77.
 24. Kennedy MJ, Davison IG, Robinson CG, et al. Syntaxin-4 defines a domain for activity-dependent exocytosis in dendritic spines. *Cell* 2010;141:524-35.
 25. Low SH, Chapin SJ, Wimmer C, et al. The SNARE machinery is involved in apical plasma membrane trafficking in MDCK cells. *J Cell Biol* 1998;141:1503-13.
 26. ter Beest MB, Chapin SJ, Avrahami D, ET AL. The role of syntaxins in the specificity of vesicle targeting in polarized epithelial cells. *Mol Biol Cell* 2005;16:5784-92.

Cite this article as: Ye W, Zhu D, Xu B, Xu M, Liu Y, Xie J, Wang Q, Jiang J. *STX4* expression is associated with classification, clinical stage and lymphatic metastasis in ovarian cancer. *Transl Cancer Res* 2019;8(2):466-472. doi: 10.21037/tcr.2019.02.11