



High efficacy of alectinib in a patient with advanced lung adenocarcinoma with 2 rare *ALK* fusion sites: a case report

Yan Li¹, Peng Duan², Yan Guan¹, Qing Chen¹, Anna Grenda³, Petros Christopoulos⁴, Marc G. Denis⁵, Qisen Guo¹

¹Department of Medical Oncology, Shandong Cancer Hospital and Institute, Shandong First Medical University & Shandong Academy of Medical Sciences, Jinan, China; ²Department of Oncology, The Third People's Hospital of Qingdao, Qingdao, China; ³Department of Pneumology, Oncology and Allergology, Medical University of Lublin, Lublin, Poland; ⁴Department of Thoracic Oncology, Thoraxklinik at Heidelberg University Hospital, Heidelberg, Germany; ⁵Nantes Université, CHU Nantes, Laboratoire de Biochimie, Nantes, France

Correspondence to: Qisen Guo. Department of Medical Oncology, Shandong Cancer Hospital and Institute, Shandong First Medical University & Shandong Academy of Medical Sciences, Jinan 250117, China. Email: guoqs369@163.com.

Abstract: Anaplastic lymphoma kinase (*ALK*) fusions have been identified in approximately 5% of non-small cell lung cancer (NSCLC) cases. *ALK*-tyrosine kinase inhibitors (TKIs) are the standard first-line treatment for patients with *ALK*-positive (*ALK*+) advanced NSCLC. Along with widespread use of next-generation sequencing (NGS) for the molecular diagnosis of lung cancer, an increasing number of *ALK* fusion partners are being reported, with the majority being effective for *ALK*-TKIs. Here, we present the case of a 42-year-old female with no smoking history who was diagnosed with stage IVB lung adenocarcinoma. Two rare *ALK* fusions were detected simultaneously by NGS in this patient: latent transforming growth factor beta-binding protein 1 (*LTBP1*)-*ALK* and huntingtin-interacting protein 1 (*HIP1*)-*ALK*. *HIP1*-*ALK* fusion was also detected by further RNA sequencing, but *LTBP1*-*ALK* failed to give a positive signal. The patient received alectinib as first-line therapy and consequently achieved a good response. Progression-free survival (PFS) was more than 19 months, and the treatment with alectinib is ongoing currently. During treatment, clinical symptoms disappeared and no significant adverse events occurred. This is the first case report describing a patient with an NSCLC tumor harboring 2 rare *ALK* fusions who responded to alectinib. Our report enriches the knowledge of *ALK* fusion sites and provides an effective clinical basis for the screening of sensitive fusions.

Keywords: Novel fusions; anaplastic lymphoma kinase (*ALK*); alectinib; lung adenocarcinoma; case report

Submitted Oct 13, 2021. Accepted for publication Jan 21, 2022.

doi: 10.21037/tlcr-21-1039

View this article at: <https://dx.doi.org/10.21037/tlcr-21-1039>

Introduction

Anaplastic lymphoma kinase (*ALK*) gene rearrangement, a driver gene alteration underlying the carcinogenesis of non-small cell lung cancer (NSCLC), has been identified in approximately 5% of patients with advanced NSCLC (1-3). The *ALK* gene, located on the short arm of chromosome 2 (*locus* 2p23), encodes for the *ALK* protein. *ALK* is a transmembrane receptor tyrosine kinase which consists of an extracellular ligand-binding domain, a transmembrane segment, a transmembrane domain, and an intracellular tyrosine kinase domain (4-6). *ALK* was originally identified

in anaplastic large-cell lymphoma (ALCL) in 1994 as *NPM-ALK* fusion (7). In 2007, Soda *et al.* first identified *ALK* rearrangement in NSCLC, with the most common fusion being echinoderm microtubule-associated protein-like 4 (*EML4*)-*ALK* (8-11). Subsequent studies in mice showed this type of gene fusion to be strongly carcinogenic. Prior to the introduction of *ALK* inhibitors, patients with *EML4-ALK* had a poor prognosis. The oncogenic activity of *EML4-ALK* mainly depends on the fused protein of *EML4* and *ALK*, which activates tyrosine kinase and thus multiple downstream signaling pathways, leading to the abnormal

proliferation and inhibited apoptosis of tumor cells. ALK inhibitors impede the proliferation of tumor cells by binding to the tyrosine kinase domain located at the intracellular domain of the ALK protein and inhibiting the kinase activity of EML4-ALK fusion protein. Similar to *EML4-ALK*, most rare *ALK* rearrangements occur between a 5' fusion partner and the 3' part of the *ALK* gene encoding the kinase domain, creating an oncogenic *ALK* tyrosine kinase that activates multiple downstream known cancer signaling pathways, including the phosphoinositide 3-kinase (PI3K)-AKT, CRKL-C3G pathway, mitogen-activated protein kinase/ERK kinase (MEKK)2/3-mitogen-activated protein kinase/ERK (MEK)5-extracellular signal-regulated kinase 5 (ERK5) pathway, Janus kinase (JAK)/signal transducer and activator of transcription (STAT) pathway, and mitogen-activated protein kinase (MAPK) pathway, resulting in increased cell proliferation and survival (12,13).

Since the discovery of *EML4-ALK* in NSCLC, a number of ALK tyrosine kinase inhibitors (TKIs) have been developed to treat *ALK*-positive (*ALK*+) NSCLC. Rapid progress in the use of targeted therapies has led to significant improvements in progression-free survival (PFS) and overall survival (OS) in patients with metastatic *ALK*-rearranged NSCLC. Thus far, 6 *ALK*-TKIs have been approved for routine clinical use, including crizotinib, ceritinib, alectinib, brigatinib, ensartinib, and lorlatinib. The selective *ALK*-TKI, alectinib is recommended as the preferred first-line therapy option for patients with *ALK*+ metastatic NSCLC, as it has shown excellent PFS and OS, is supported by clinical trial data, and has been approved by the US Food and Drug Administration (FDA) (14-16). These trials also demonstrated that alectinib significantly improved central nervous system (CNS) efficacy versus chemotherapy or crizotinib.

Concurrently, the methods for detecting those with *ALK*+ NSCLC have shifted from traditional immunochemistry (IHC) and fluoresce in situ hybridization (FISH) to the more modern next-generation sequencing (NGS). Along with the widespread use of NGS in molecular diagnosis of lung cancer, a greater number of novel partner genes have been described, although *EML4-ALK* remains the major fusion variant in *ALK*+ NSCLC, accounting for about 95% of *ALK* fusion variants in *ALK*+ NSCLC (17). Thus far, more than 92 distinct *ALK* fusion partners (including noncoding RNAs) have been identified in NSCLC (18), most of which are effective against *ALK*-TKIs. It found that the most fusion site is located at exon 20 of *ALK* gene.

This is the first reported case of a concurrent

combination of two rare *ALK* fusions that showed a favorable response to alectinib. Our report enriches the knowledge of *ALK* fusion types and broadens the clinical basis for the screening and mechanistic workup of sensitive variants. We present the following article in accordance with the CARE reporting checklist (available at <https://tcr.amegroups.com/article/view/10.21037/tcr-21-1039/rc>).

Case presentation

A 42-year-old Chinese woman was admitted to Shandong Cancer Hospital and Institute for an irritating cough and shortness of breath which had persisted for about 2 months. The patient had been healthy in the past, and she had no history of smoking or family history of cancer. A contrast-enhanced computed tomography (CT) scan (March 10, 2020) showed a 6.7 cm × 5.4 cm mass in the right lower lobe and multiple masses with varying size in the brain. No bone metastases were identified by radionuclide bone scanning (figures not shown). A biopsy specimen was obtained by CT-guided lung biopsy. The cell morphology was consistent with lung adenocarcinoma (*Figure 1A*), and the tumor cells were positive for thyroid transcription factor-1 (TTF-1) and cytokeratin (CK)7, and negative for CK5 (*Figure 1B*). After comprehensive evaluation, the patient was diagnosed with metastatic lung adenocarcinoma (cT4N2M1c, stage IVB).

In order to clarify the genetic alterations of the tumor, we performed NGS on DNA isolated from the formalin-fixed paraffin-embedded (FFPE) tissue acquired from the primary tumor biopsy. Based on a 456-gene panel (Berry Oncology Corporation, Fujian, China), DNA sequencing results identified 2 novel *ALK* fusions sites: huntingtin-interacting protein 1 (*HIP1*)-*ALK* (allelic frequency: 9.38%) (*Figure 2*) and latent transforming growth factor beta-binding protein 1 (*LTBP1*)-*ALK* (allelic frequency: 10.28%) (*Figure 3*). Further IHC, using the D5F3 antibody (Ventana Medical Systems, Tucson, AZ, USA; *Figure 4A*) and FISH (*Figure 4B*) for *ALK* were both strongly positive. The positive expression of *ALK* in IHC and the FISH results suggested that the *ALK* fusion was expressed at the protein level, indicating a carcinogenic mutation present in this patient. To further confirm this result and explore the exact fusion pattern, an RNA fusion panel based on amplicon sequencing was designed to identify the fusion variation (Berry Oncology). The NGS detection on RNA confirmed the *HIP1-ALK* fusion, but failed for *LTBP1-ALK*. Fusion results were validated using reverse transcriptase polymerase chain reaction (RT-PCR) and Sanger sequencing.

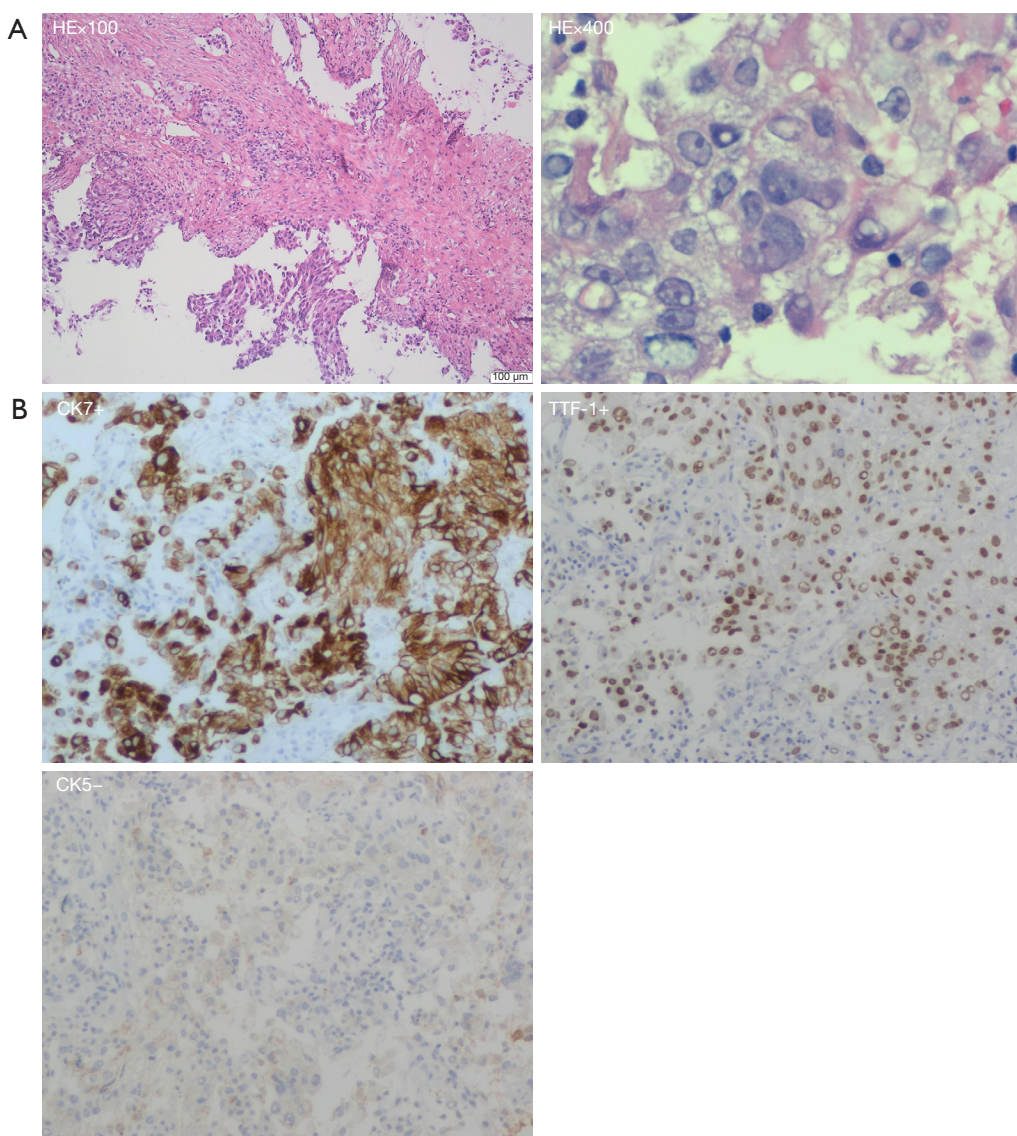


Figure 1 Histological findings from biopsy specimens. (A) Hematoxylin and eosin (HE) staining of tumor tissue (100 \times , 400 \times) showed lung adenocarcinoma; (B) immunohistochemistry (IHC) analysis of tumor tissue showed it was positive for thyroid transcription factor-1 (TTF-1) (100 \times) and cytokeratin (CK)7 (100 \times), and negative for CK5 (100 \times).

The sequence analysis of *HIP1-ALK* cDNA showed that exon 30 of *HIP1* was fused to exon 20 of *ALK* in-frame, generating a fusion messenger RNA (mRNA) harboring an intact 5,415-base pair open reading frame encoding a deduced 1,805-amino acid protein sequence that contained epsin N-terminal homology, coiled-coil, C-terminal homology, juxtamembrane, and kinase domains (Figures 2,5). The sequence analysis of *LTBP1-ALK* cDNA showed that exon 3 of *LTBP1* was fused to exon 19 of *ALK* in-frame (Figure 3).

The patient was treated with alectinib (600 mg twice per day) as first-line therapy as soon as the *LTBP1-ALK* and *HIP1-ALK* fusions were identified (March 31, 2020). After 1 month of therapy, the patient achieved complete remission of the clinical symptoms, including cough and shortness of breath, with no obvious adverse reaction other than mild constipation. CT scan images (April 27, 2020) revealed a significant response in the target lesion of the right lower lobe, which had obviously shrunk (4.0 cm \times 3.0 cm), while the brain lesions had nearly disappeared. The patient

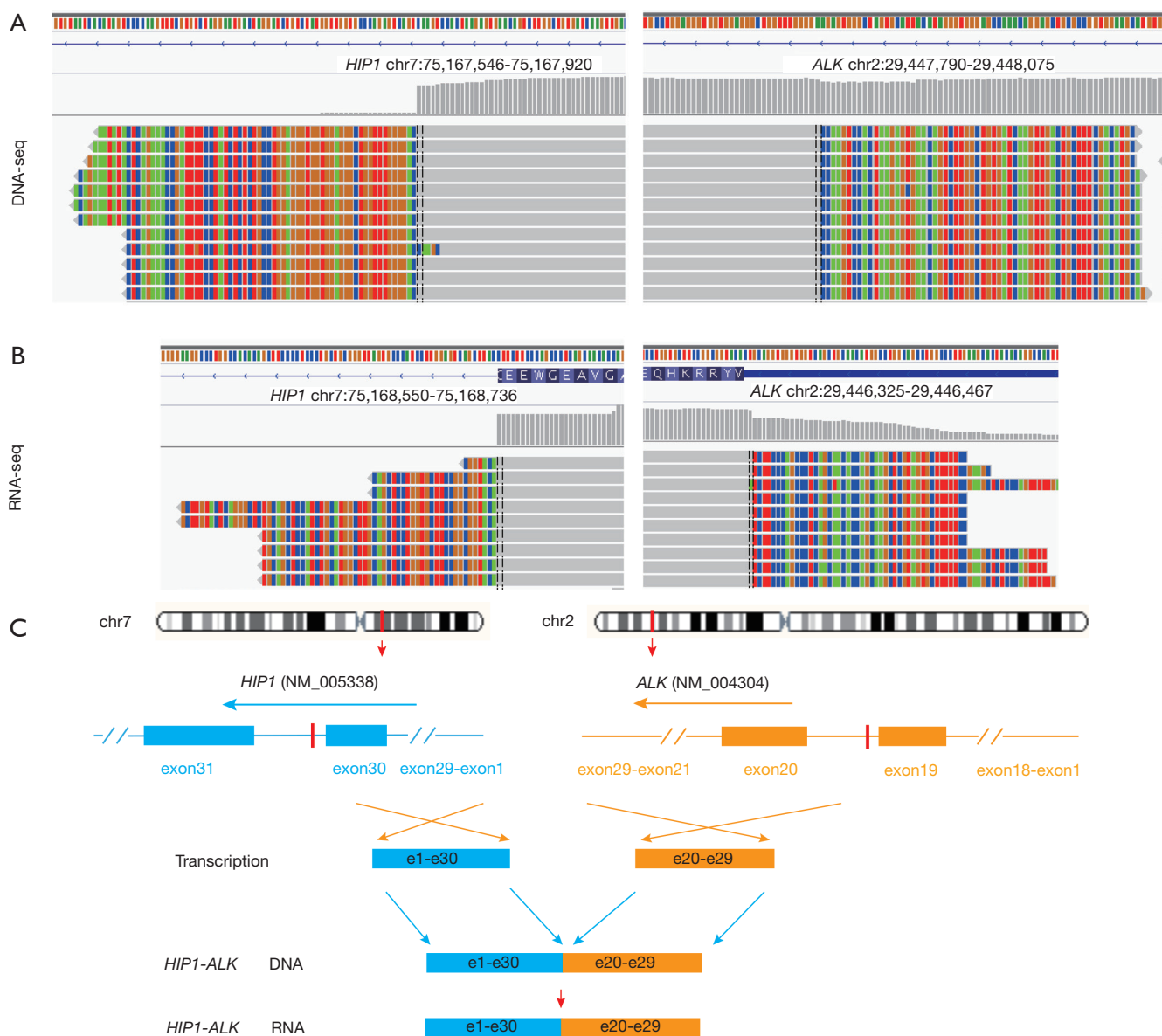


Figure 2 Identification and validation of the huntingtin-interacting protein 1 (*HIP1*)-anaplastic lymphoma kinase (*ALK*) fusion in a NSCLC patient. (A) DNA sequencing reads of *HIP1* and *ALK* were visualized by the Integrative Genomics Viewer (IGV); (B) RNA sequencing reads of *HIP1* and *ALK* were visualized by the Integrative Genomics Viewer (IGV); (C) a schematic map showing the structure of the *HIP1-ALK* fusion locus. NSCLC, non-small cell lung cancer.

achieved partial response (PR) according to the Response Evaluation Criteria in Solid Tumors, version 1.1 (RECIST 1.1) and until the last follow-up (November 03, 2021), the notable response was maintained (*Figure 6*). At the data cutoff (November 03, 2021), the patient remained on alectinib treatment, which had yielded a PFS of more than 19 months. As of this writing, alectinib treatment is ongoing. We will follow this patient and explore the

mechanisms of alectinib resistance should disease recurrence or progress occur.

All procedures performed in this study were in accordance with the ethical standards of the institutional and/or national research committee(s) and with the Helsinki Declaration (as revised in 2013). Written informed consent was obtained from the patient for publication of this case report and accompanying images. A copy of the written

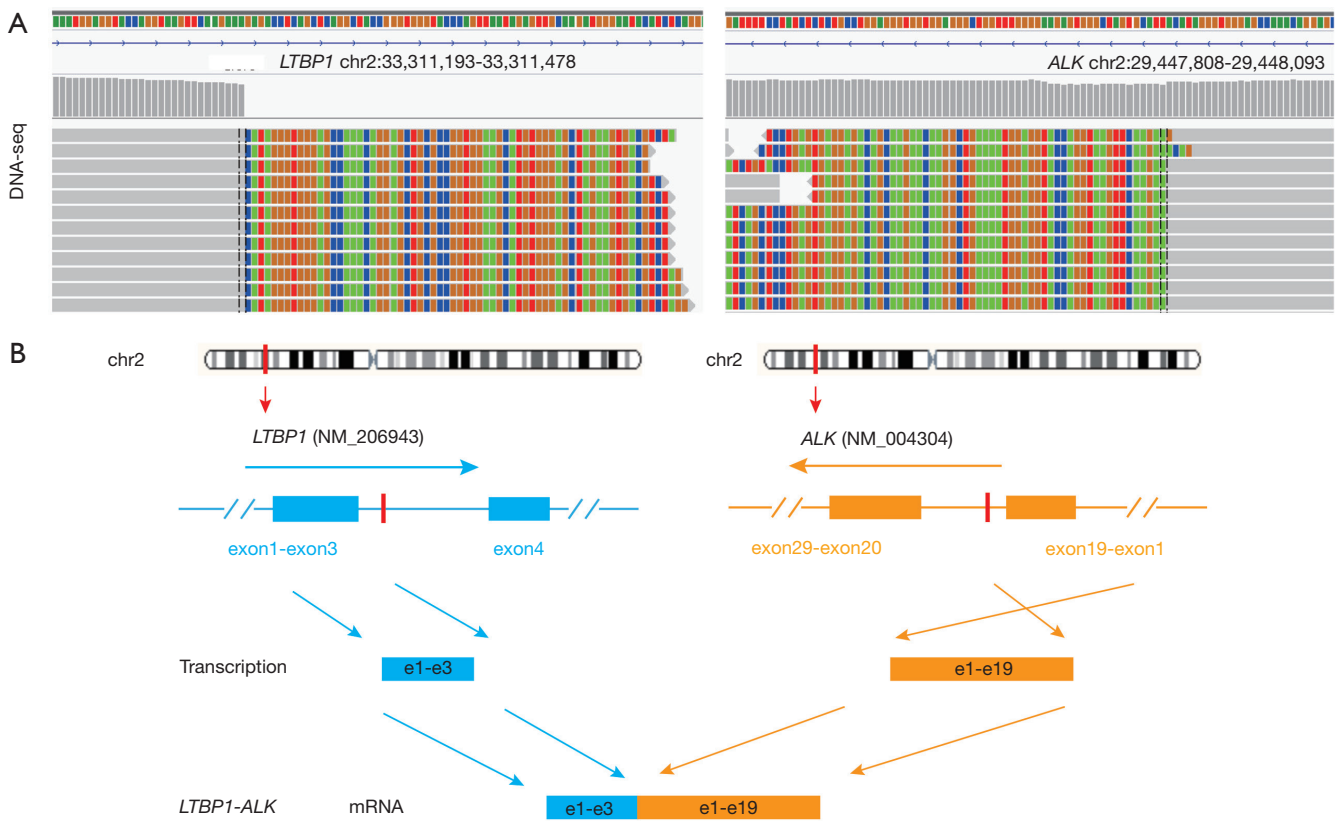


Figure 3 Identification and validation of the latent transforming growth factor beta-binding protein 1 (*LTBP1*)-anaplastic lymphoma kinase (*ALK*) fusion in a NSCLC patient. (A) DNA sequencing reads of *LTBP1* and *ALK* were visualized by the Integrative Genomics Viewer (IGV); (B) a schematic map showing the structure of the *LTBP1-ALK* fusion locus. NSCLC, non-small cell lung cancer.

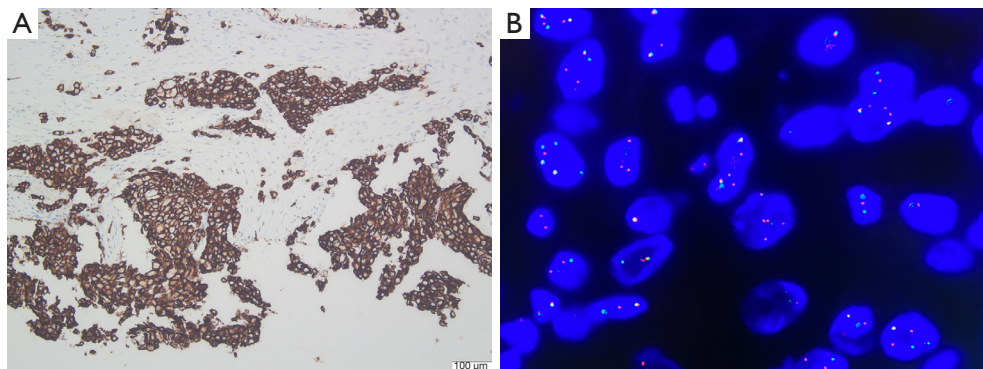


Figure 4 Molecular detection at the protein level. (A) Immunohistochemistry (IHC) analysis indicated the tumor sample being positive for anaplastic lymphoma kinase (ALK) (100 \times), using the D5F3 antibody (Ventana Medical Systems, Tucson, AZ, USA); (B) fluorescent in situ hybridization (FISH) detection of tumor tissue showed it was positive for ALK (1,000 \times).

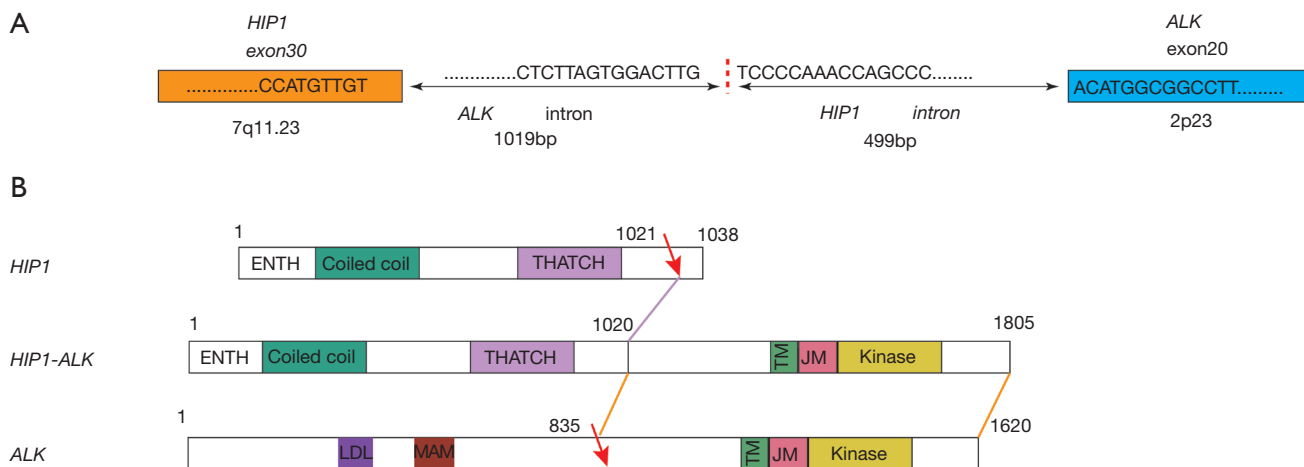


Figure 5 Illustration of the *HIP1-ALK* fusion at the DNA and mRNA levels. (A) Sequence analysis of the region fused between huntingtin-interacting protein 1 (*HIP1*) and anaplastic lymphoma kinase (*ALK*) at the genome and transcript levels. (B) Functional domain analysis of *HIP1*, *ALK*, and *HIP1-ALK* protein sequences.

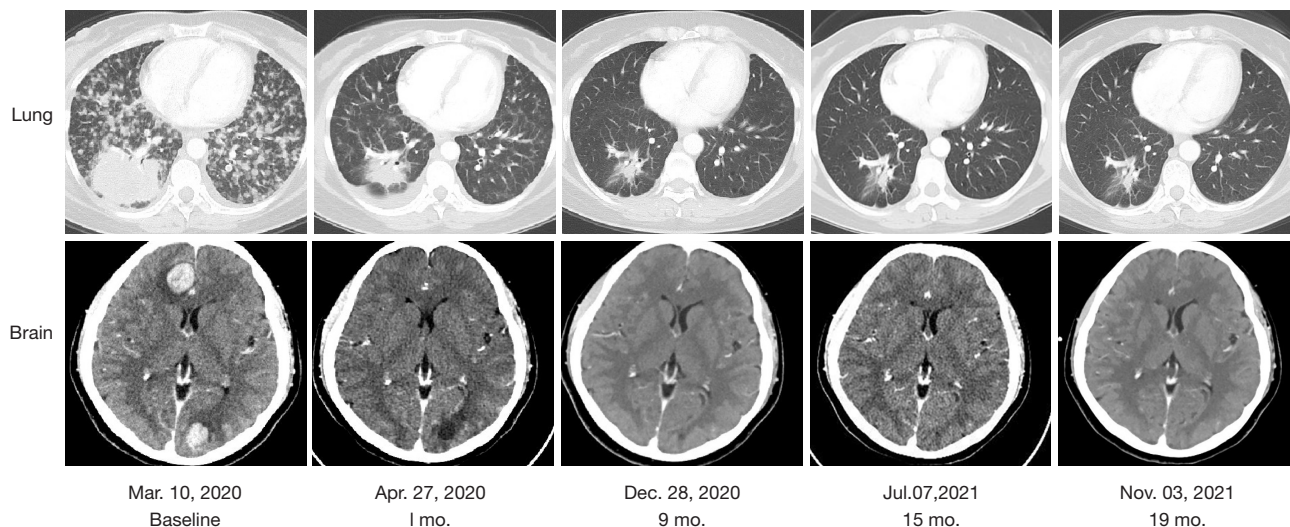


Figure 6 Imaging evaluation of the therapeutic effects of targeted therapy.

consent is available for review by the editorial office of this journal.

International multidisciplinary team (iMDT) discussion

Discussion among physicians from Shandong Cancer Hospital and Institute

ALK fusion is known as a “diamond mutation” because of its very low mutation rate and good response to *ALK*-

TKIs which can considerably improve the PFS and OS of patients with *ALK+* NSCLC. Thus, the ability to detect *ALK* fusions is important to benefit these patients. Based on this clinical need, there has been constant innovation in molecular detection technology. In clinical application, NGS has gradually taken the place of traditional methods such as FISH and IHC. Currently, high-throughput sequencing technology has increased the chance of identifying new fusion genes that have activities similar to classic *ALK* fusions (19,20), potentially matching more

Table 1 Catalog of previous reports of *HIP1-ALK*+ lung cancer

No.	Year	Chromosomal location	Fusion breakpoint	Response to ALK-TKI	Tumor source	Detection method	VAF	FISH/IHC	References
1	2014	7q11.23	(H28:A20)	Not treated with ALK TKI (PDX crizotinib sensitive)	Tumor	RNA NGS	NR	ND/ND	Douglas D. Fang, <i>et al.</i>
2	2014	7q11.23	(H21:A20)	PR to crizotinib	Tumor	RT-PCR	NR	+/+	Mineui Hong, <i>et al.</i>
3	2014	7q11.23	(H30:A20)	PR to crizotinib & alectinib	Tumor	DNA NGS	NR	+/ND	Sai-Hong Ignatius Ou, <i>et al.</i>
4	2016	–	(H19:A20)	Not treated with ALK TKI	–	–	NR	+/+	Jin Sung Jang, <i>et al.</i>
5	2019	7q11.23	(H28:A20)	PR to crizotinib (PFS 26.9 m)	Tumor	DNA NGS (WES)	NR	ND/ND	Mathilde Couëtoux du Tertre, <i>et al.</i>
6	2020	7q11.23	(H22:A21)	PR to crizotinib (PFS 7.0 m)	Tumor	DNA NGS	NR	ND/ND	Panwen Tian, <i>et al.</i>
7	2021	7q11.23	(H19:A20)	NR to crizotinib; PR to alectinib	Tumor	DNA NGS	1.67%	ND/+	Mengnan Li, <i>et al.</i>

+, positive. *HIP1*, huntingtin-interacting protein 1; *ALK*, anaplastic lymphoma kinase; TKI, tyrosine kinase inhibitor; NGS, next-generation sequencing; RT-PCR, reverse transcriptase polymerase chain reaction; WES, whole exome sequencing; VAF, variant frequency; FISH, fluorescent in situ hybridization; IHC, immunohistochemistry; NR, not reported; ND, not detected.

patients to existing drugs. NGS-based assessment for *ALK* fusions is more accurate and comprehensive, and has the unique advantage of being able to detect unknown *ALK* fusion partners and identify the exact breakpoints. DNA and RNA-based NGS assay should be thus both valuable in fusion detection. DNA-based NGS can identify genomic rearrangements not limited to fusion, such as amplification of the *ALK* locus, a newly discovered truncated form that activates drivers but does not lead to fusion transcripts and proteins (21). RNA-based NGS offers a more direct approach to detecting clinically actionable fusions compared to RNA sequencing, which focuses more on exons post-splicing and may thus bypass genomic complexities (22). Future optimization of NGS panel probe design will be essential to tiling the selected intronic regions of fusion partner genes. Meanwhile, RNA and protein level assays may be critical for clarifying the function of complex *ALK* rearrangements and better informing decisions concerning treatment in clinical practice (23).

This is the first reported case of a concurrent combination of two rare *ALK* fusions that showed a favorable response to alectinib. It is of particular interest that *LTBP1-ALK* was detected at the DNA level but not expressed at the RNA level in this case. Details regarding the RNA-NGS panel from Berry Oncology used in this study are not publicly available, as the DNA and RNA panels are an in-house design, the publication of which is constrained by intellectual property rights, trade secrets,

and commercial interests. The RNA-NGS used here was PCR (amplicon)-based. Since *LTBP1* is not a common or established fusion partner for *ALK*, we speculate that *LTBP1* was simply not included in the RNA-NGS panel of this study.

There have been 7 previous reports of *HIP1-ALK*+ lung cancer (24–30) (Table 1), and patients with this fusion have received mixed therapeutic effects from ALK-TKIs. Among these patients, 3 receiving first-line crizotinib treatment and 1 receiving first-line alectinib treatment achieved PR, while 1 patient showed resistance to crizotinib but received benefit from alectinib. Of note, only 1 among the described cases had the H30:A20 fusion variant (case 3 in Table 1) that was detected in our case (Figure 2) and showed sensitivity to both crizotinib and alectinib (26). The reasons for the variable efficacy of crizotinib in patients with *HIP1-ALK* fusion and the related mechanism still need to be investigated. Although there was a single case of a patient with an H19:A20 fusion variant with resistance to crizotinib in the literature (Table 1, case 7), no *HIP1-ALK* case with primary alectinib resistance has been reported to date.

Two reports of lung cancer *LTBP1-ALK* fusion mutations exist (31,32) (Table 2), and both patients received first-line treatment with crizotinib and reached PR. The kinase domain of *ALK* is located in exon 20 (4), and the tyrosine kinase domain (exon 20 of *ALK*) was present in these cases; however, in our case, the *LTBP1-ALK* occurred in *ALK* intron 19 (the retained portion was exon 1–19), leaving the

Table 2 Catalog of previous reports of *LTBP1-ALK*+ lung cancer

No.	Year	Chromosomal location	Fusion breakpoint	Response to ALK-TKI	Tumor source	Detection method	VAF	FISH/IHC	References
8	2018	–	–	PR to crizotinib	Tumor	RT-PCR Sanger sequencing	2.7%	+/+	Cristina Aguado, <i>et al.</i>
9	2020	–	(L1-30:A20-29)	PR to crizotinib	Tumor	DNA NGS	13.30%	+/+	Huiwen Qian, <i>et al.</i>

+, positive. *LTBP1*, latent transforming growth factor beta-binding protein 1; *ALK*, anaplastic lymphoma kinase; TKI, tyrosine kinase inhibitor; RT-PCR, reverse transcriptase polymerase chain reaction; NGS, next-generation sequencing; VAF, variant frequency; FISH, fluorescent in situ hybridization; IHC, immunochemistry.

kinase domain behind. Even if it had been transcribed, the protein would not have contained the *ALK* tyrosine kinase domain. Therefore, the efficacy of alectinib in this case was only based on the *HIP1-ALK* fusion.

Previous studies have demonstrated that the 5' fusion partner, i.e. the gene partner and the exact fusion variant, i.e., involved exon of the 5'-partner gene, can affect *ALK* TKI drug sensitivity (33,34). However, our understanding of the mechanisms that govern how the 5' partner affects the biology of the fusion and responsiveness to *ALK*-TKIs is still limited. Therefore, a subsequent step in research will be to identify the drug-sensitive fusions and drug-resistant fusion mutations in *ALK*+ NSCLC patients. To this end, our report enriches the knowledge of *ALK* fusion types and broadens the clinical basis for the screening and mechanistic workup of sensitive variants.

Several issues regarding the diagnosis and treatment of this patient were further discussed and are presented here

Question 1: Why was *LTBP1-ALK* detected at the DNA level but not at the RNA level?

Expert opinion 1: Dr. Anna Grenda

RNA molecules undergo posttranscriptional processing that can alter the exon composition of the mature mRNA molecule. Therefore, it could be that the break/fusion site that was observed at the DNA level was cleaved/modified in such a way that the fusion partner was not present. It could be that some of the RNA molecules had a fusion variant; however, the number of fused molecules was below the detection threshold.

Expert opinion 2: Dr. Marc G. Denis

There are two possible explanations. The first one is related to the assay used. The *LTBP1-ALK* rearrangement at the DNA level involves exon 1–19 of the *ALK* gene. It would be interesting to know if the RNA sequencing assay is able to detect RNA transcripts containing these exons fused to the

first 3 exons of *LTBP1*.

The second hypothesis is that this gene rearrangement is not transcribed or is transcribed at a low level. Transcription of this *LTBP1-ALK* hybrid gene depends on the *LTBP1* promoter, which might be weak in lung tumor cells.

FISH analysis and DNA-based NGS assays do not indicate if the gene is transcribed. This is an important advantage of RNA sequencing and of other RNA-based approaches. Without RNA transcripts, the fusion protein is not expressed, and the targeted therapies cannot be efficient.

Expert opinion 3: Dr. Petros Christopoulos

The RNA-NGS used here was PCR (amplicon)-based, so presumably *LTBP1* was simply not included in the RNA-NGS panel of this study. This is very likely, because *LTBP1* is not a common or established fusion partner for *ALK*; for example, *LTBP1* is not included in the Ion AmpliSeq RNA Fusion Lung Cancer Research panel from Thermo Fisher. Unfortunately, no details are given about the RNA-NGS panel from Berry Oncology used in this study.

Question 2: What are the reasons for the different efficacy of crizotinib in patients with *HIP1-ALK* fusion?

Expert opinion 1: Dr. Anna Grenda

NGS has resulted in the possibility of identifying new mutational variants of uncertain significance as well as new, rare fusion variants that may impact the efficacy of a molecularly targeted treatment. The identification of *HIP1-ALK* fusions is in line with the trend of expanding information on the biology and efficacy of anti-*ALK*-TKI, which has not been fully explained. The different efficacy of crizotinib in patients with this type of change may result from the way these two genes fuse (i.e., where they break and join) which will ultimately determine the amino acid composition of the fusion protein and thus the affinity to the drug. The molecular background, or the coexistence of mutations in suppressor genes which are

not directly a therapeutic target but whose dysfunctions may have an impact on a worse prognosis for patients, may be important for the effectiveness of treatment. A holistic approach to this topic through genomic, transcriptomic, and proteomic analysis can provide a lot of information regarding the differences in the effectiveness of treatment with molecularly targeted therapies.

Expert opinion 2: Dr. Marc G. Denis

Targeted therapies have been shown to be effective when a specific alteration is present in the tumor. In clinical trials, response rates are often high (>50%), but not all patients respond to these treatments. Certain characteristics of patients and/or of their tumors may be responsible for the lack of response. This is particularly the case with mutations in other genes. For example, co-mutations in the TP53 tumor suppressor gene have been associated with a reduced response to treatment. Since the number of *HIP1-ALK* fusion patients is limited, it will be difficult to demonstrate which tumor characteristic is responsible for variable efficacy of ALK inhibitors.

Expert opinion 3: Dr. Petros Christopoulos

This is the subject of ongoing studies. Generally, the 5'-partner (i.e., *EML4* in *EML4-ALK*, and *HIP1* in *HIP1-ALK*) (I) determines how strong the oncoprotein expression will be (because this relies on the promoter of the 5'-partner gene), and (II) causes the oligomerization and autophosphorylation of oncoprotein molecules. Both of these effects enhance the oncogenicity of the fusion protein, which can therefore differ depending on the exact fusion partner. Furthermore, several other molecular features can additionally influence the responsiveness to ALK TKI, like the presence of co-mutations, such as TP53, and the immune microenvironment. I am not aware of any published results comparing the exact biochemical properties of *ALK* fusion oncoproteins with *HIP1* vs. other 5'-partners.

Question 3: How does the 5' partner affect the biology of the fusion or responsiveness to ALK-TKIs?

Expert opinion 1: Dr. Anna Grenda

Depending on the *ALK* fusion partner, the fusion protein may have a different degree of affinity for ALK inhibitors. Recognition, matching, and strong binding of the therapeutic molecule to the fusion protein appear to have a large impact on the efficacy of anti-ALK targeted therapy. The amino acid composition of the *ALK* fusion protein into which the fusion partner has contributed its sequence, may affect the spatial arrangement of the protein and thus

alter the affinity and binding strength of crizotinib to the fusion protein, which may be associated with alterations in the efficacy of anti-ALK-TKI treatment. Thanks to NGS technology, new fusion partners, not previously described, can be identified, which broadens the knowledge about the biology of *ALK* fusion and its impact on the effectiveness of targeted treatment.

Expert opinion 2: Dr. Marc G. Denis

The 5' partner is involved at several levels. First, the promoter of the corresponding gene drives the transcription of the fusion. The concentration of the specific transcript (and of the corresponding protein) may thus vary. Second, the structure of the protein will be different. The amino terminal part may have an impact on the overall structure of the protein and thus on the tyrosine kinase activity.

Expert opinion 3: Dr. Petros Christopoulos

Generally, the 5'-partner (e.g., *EML4* in *EML4-ALK*, and *HIP1* in *HIP1-ALK*) (I) determines how strong the oncoprotein expression will be (because this relies on the promoter of the 5'-partner gene) and (II) causes the oligomerization and autophosphorylation of oncoprotein molecules. Both of these effects enhance the oncogenicity of the fusion protein. In addition, even among *ALK* fusions with *EML4* as the 5'-partner, different breakpoints can result in different biological properties. For example, it is known that V3 (E6;A20) has a higher stability and stronger interaction with the cytoskeleton than do the longer *EML4-ALK* variants V1 (E13;A20) and V2 (E20;A20), which results in worse prognosis for V3-driven tumors. However, I am not aware of any published data comparing the strength of expression, strength of oligomerization, protein stability, and ability to interact with the cytoskeleton for *ALK* fusion oncoproteins with *HIP1* vs. other 5'-partners.

Acknowledgments

We thank Xiaoxing Su and Yan Lei from Berry Oncology Corporation for Bioinformatics technology support.

Funding: This work was supported by a grant from the Shandong Key Research and Development Program (No. 2019GSF108251).

Footnote

Reporting Checklist: The authors have completed the CARE reporting checklist Available at <https://tldr.amegroups.com/article/view/10.21037/tldr-21-1039/rc>

Conflicts of Interest: All authors have completed the ICMJE uniform disclosure form (available at <https://tldr.amegroups.com/article/view/10.21037/tlcr-21-1039/coif>). All authors report bioinformatics technology support from Xiaoxing Su and Yan Lei who are from Berry Oncology Corporation. YL and QG report funding from the Shandong Key Research and Development Program (No. 2019GSF108251). PC has received research funding from AstraZeneca, Novartis, Roche, and Takeda, speaker's honoraria from AstraZeneca, Novartis, Roche, Takeda, support for attending meetings from AstraZeneca, Eli Lilly, Novartis, Takeda, and personal fees for participating to advisory boards from Boehringer Ingelheim, Chugai, Pfizer and Roche, all outside the submitted work. The authors have no other conflicts of interest to declare.

Ethical Statement: The authors are accountable for all aspects of the work in ensuring that questions related to the accuracy or integrity of any part of the work are appropriately investigated and resolved. All procedures performed in this study were in accordance with the ethical standards of the institutional and/or national research committee(s) and with the Helsinki Declaration (as revised in 2013). Written informed consent was obtained from the patient for publication of this case report and accompanying images. A copy of the written consent is available for review by the editorial office of this journal.

Open Access Statement: This is an Open Access article distributed in accordance with the Creative Commons Attribution-NonCommercial-NoDerivs 4.0 International License (CC BY-NC-ND 4.0), which permits the non-commercial replication and distribution of the article with the strict proviso that no changes or edits are made and the original work is properly cited (including links to both the formal publication through the relevant DOI and the license). See: <https://creativecommons.org/licenses/by-nc-nd/4.0/>.

References

1. Kwak EL, Bang YJ, Camidge DR, et al. Anaplastic lymphoma kinase inhibition in non-small-cell lung cancer. *N Engl J Med* 2010;363:1693-703.
2. Devarakonda S, Morgensztern D, Govindan R. Genomic alterations in lung adenocarcinoma. *Lancet Oncol* 2015;16:e342-51.
3. Addeo A, Tabbò F, Robinson T, et al. Precision medicine in ALK rearranged NSCLC: A rapidly evolving scenario. *Crit Rev Oncol Hematol* 2018;122:150-6.
4. Duyster J, Bai RY, Morris SW. Translocations involving anaplastic lymphoma kinase (ALK). *Oncogene* 2001;20:5623-37.
5. Hallberg B, Palmer RH. Mechanistic insight into ALK receptor tyrosine kinase in human cancer biology. *Nat Rev Cancer* 2013;13:685-700.
6. Wu J, Savooji J, Liu D. Second- and third-generation ALK inhibitors for non-small cell lung cancer. *J Hematol Oncol* 2016;9:19.
7. Morris SW, Kirstein MN, et al. Fusion of a kinase gene, ALK, to a nucleolar protein gene, NPM, in non-Hodgkins-lymphoma. *Science* 1994;263:1281-4. Erratum in: *Science* 1995;267:316-7.
8. Soda M, Choi YL, Enomoto M, et al. Identification of the transforming EML4-ALK fusion gene in non-small-cell lung cancer. *Nature* 2007;448:561-6.
9. Inamura K, Takeuchi K, Togashi Y, et al. EML4-ALK fusion is linked to histological characteristics in a subset of lung cancers. *J Thorac Oncol* 2008;3:13-7.
10. Noh KW, Lee MS, Lee SE, et al. Molecular breakdown: a comprehensive view of anaplastic lymphoma kinase (ALK)-rearranged non-small cell lung cancer. *J Pathol* 2017;243:307-19.
11. von Laffert M, Warth A, Penzel R, et al. Multicenter immunohistochemical ALK-testing of non-small-cell lung cancer shows high concordance after harmonization of techniques and interpretation criteria. *J Thorac Oncol* 2014;9:1685-92.
12. Chiarle R, Voena C, Ambrogio C, et al. The anaplastic lymphoma kinase in the pathogenesis of cancer. *Nat Rev Cancer* 2008;8:11-23.
13. Guan J, Umopathy G, Yamazaki Y, et al. FAM150A and FAM150B are activating ligands for anaplastic lymphoma kinase. *Elife* 2015;4:e09811.
14. Peters S, Camidge DR, Shaw AT, et al. Alectinib versus Crizotinib in Untreated ALK-Positive Non-Small-Cell Lung Cancer. *N Engl J Med* 2017;377:829-38.
15. Hida T, Nokihara H, Kondo M, et al. Alectinib versus crizotinib in patients with ALK-positive non-small-cell lung cancer (J-ALEX): an open-label, randomised phase 3 trial. *Lancet* 2017;390:29-39.
16. Larkins E, Blumenthal GM, Chen H, et al. FDA Approval: Alectinib for the Treatment of Metastatic, ALK-Positive Non-Small Cell Lung Cancer Following Crizotinib. *Clin Cancer Res* 2016;22:5171-6.
17. Ross JS, Ali SM, Fasan O, et al. ALK Fusions in a Wide Variety of Tumor Types Respond to Anti-ALK Targeted

- Therapy. *Oncologist* 2017;22:1444-50.
18. Ou SI, Zhu VW, Nagasaka M. Catalog of 5' Fusion Partners in ALK-positive NSCLC Circa 2020. *JTO Clin Res Rep* 2020;1:100015.
 19. Lipson D, Capelletti M, Yelensky R, et al. Identification of new ALK and RET gene fusions from colorectal and lung cancer biopsies. *Nat Med* 2012;18:382-4.
 20. Peled N, Palmer G, Hirsch FR, et al. Next-generation sequencing identifies and immunohistochemistry confirms a novel crizotinib-sensitive ALK rearrangement in a patient with metastatic non-small-cell lung cancer. *J Thorac Oncol* 2012;7:e14-e16.
 21. Cazes A, Louis-Brennetot C, Mazot P, et al. Characterization of rearrangements involving the ALK gene reveals a novel truncated form associated with tumor aggressiveness in neuroblastoma. *Cancer Res* 2013;73:195-204.
 22. Benayed R, Offin M, Mullaney K, et al. High Yield of RNA Sequencing for Targetable Kinase Fusions in Lung Adenocarcinomas with No Mitogenic Driver Alteration Detected by DNA Sequencing and Low Tumor Mutation Burden. *Clin Cancer Res* 2019;25:4712-22.
 23. Xia P, Zhang L, Li P, et al. Molecular characteristics and clinical outcomes of complex ALK rearrangements identified by next-generation sequencing in non-small cell lung cancers. *J Transl Med* 2021;19:308.
 24. Fang DD, Zhang B, Gu Q, et al. HIP1-ALK, a novel ALK fusion variant that responds to crizotinib. *J Thorac Oncol* 2014;9:285-94.
 25. Hong M, Kim RN, Song JY, et al. HIP1-ALK, a novel fusion protein identified in lung adenocarcinoma. *J Thorac Oncol* 2014;9:419-22.
 26. Ou SH, Klempner SJ, Greenbowe JR, et al. Identification of a novel HIP1-ALK fusion variant in Non-Small-Cell Lung Cancer (NSCLC) and discovery of ALK I1171 (I1171N/S) mutations in two ALK-rearranged NSCLC patients with resistance to Alectinib. *J Thorac Oncol* 2014;9:1821-5.
 27. Jang JS, Wang X, Vedell PT, et al. Custom Gene Capture and Next-Generation Sequencing to Resolve Discordant ALK Status by FISH and IHC in Lung Adenocarcinoma. *J Thorac Oncol* 2016;11:1891-900.
 28. Couëtoux du Tertre M, Marques M, Tremblay L, et al. Analysis of the Genomic Landscape in ALK+ NSCLC Patients Identifies Novel Aberrations Associated with Clinical Outcomes. *Mol Cancer Ther* 2019;18:1628-36.
 29. Tian P, Liu Y, Zeng H, et al. Unique molecular features and clinical outcomes in young patients with non-small cell lung cancer harboring ALK fusion genes. *J Cancer Res Clin Oncol* 2020;146:935-44.
 30. Li M, Tang Q, Chen S, et al. A novel HIP1-ALK fusion variant in lung adenocarcinoma showing resistance to Crizotinib. *Lung Cancer* 2021;151:98-100.
 31. Aguado C, Gil MD, Yeste Z, et al. Response to crizotinib in a non-small-cell lung cancer patient harboring an EML4-ALK fusion with an atypical LTBP1 insertion. *Onco Targets Ther* 2018;11:1117-20.
 32. Qian H, Li J, Zou L, et al. LTBP1-ALK: A novel fusion identified in malignant pleural effusions from a patient with advanced lung adenocarcinoma. *Lung Cancer* 2020;144:93-7.
 33. Childress MA, Himmelberg SM, Chen H, et al. ALK Fusion Partners Impact Response to ALK Inhibition: Differential Effects on Sensitivity, Cellular Phenotypes, and Biochemical Properties. *Mol Cancer Res* 2018;16:1724-36.
 34. Christopoulos P, Kirchner M, Endris V, et al. EML4-ALK V3, treatment resistance, and survival: refining the diagnosis of ALK+ NSCLC. *J Thorac Dis* 2018;10:S1989-91.
- (English Language Editor: J. Gray)

Cite this article as: Li Y, Duan P, Guan Y, Chen Q, Grenda A, Christopoulos P, Denis MG, Guo Q. High efficacy of alectinib in a patient with advanced lung adenocarcinoma with 2 rare ALK fusion sites: a case report. *Transl Lung Cancer Res* 2022;11(1):100-110. doi: 10.21037/tlcr-21-1039