

Available online at www.sciencedirect.com

ScienceDirect

journal homepage: www.elsevier.com/locate/radcr

Case Report

Giant cholesterol granuloma of petrous apex ☆

Ilir Ahmetgjekaj, PhD^a, Edlira Harizi, MD^b, Abdur Rahman, MD^c, Fjolla Hyseni, MD^d, Fareeha Nasir, MD^e, Arlind Decka, MD^f, Masum Rahman, MD^g, Kledisa Shemsi, MD^h, Kristi Saliaj, MDⁱ, Samar Akram, MD^j, Ina Kola, MD^k, Juna Musa, MD, MSc^{l,*}

^a Department of Radiology, UBT and UCC, Pristina, Kosovo

^b Department of Neurology, Regional Hospital Durres, Durres, Albania

^c Department of Medicine, Life and care hospital Ltd, Dhaka, Bangladesh

^d Medical Researcher, NYU Langone Health, New York, USA

^e Department of Internal Medicine, Harlem Hospital Center, New York, USA

^f Department of General Surgery, Westchester Medical Center, Valhalla, NY, USA

^g Department of Neurological Surgery, Mayo Clinic, Rochester, MN, USA

^h Department of Emergency, General practitioner, Regional Hospital Durres, Durres, Albania

ⁱ University of Medicine, Tirana, Albania

^j Department of Neurological Surgery, Mayo Clinic, Rochester, MN, USA

^k Department of Plastic Surgery, Tirana, Albania

^l Department of Surgery, Mayo Clinic, Rochester, Minnesota, 55904, USA

ARTICLE INFO

Article history:

Received 28 November 2021

Revised 26 December 2021

Accepted 30 December 2021

Keywords:

Cholesterol granuloma

Congenital cyst

MRI

Mass

ABSTRACT

Cholesterol granulomas are chronic inflammatory lesions located primarily in the apex of the petrous part of the temporal bone. They are benign, tumor-like lesions, consisting of a cystic cavity filled with a chocolate-brown fluid and present as hyperintense masses on T1 and T2 sequences on MRI. The most common causes of cholesterol granulomas are chronic middle ear infections and traumas, explaining their prevalence in young to middle aged patients. Due to their progressively expanding nature, clinical presentation include vertigo, diplopia, tinnitus, hearing loss and seizures. Treatment of cholesterol granulomas consists of two different approaches: watch and wait or radical surgery to remove the granulomatous tissue. We present the case of a 38-year-old male patient who was admitted to the Neurology Clinic with complaints of loss of consciousness, headache, pain on the left side of the face and tinnitus in the left ear. These symptoms had been present for some time and gradually worsened in intensity and frequency. Initially after an EEG was performed, the patient showed signs of focal epilepsy and began treatment accordingly. Subsequently, a CT and an MRI of the head and neck were performed, which showed a large, well demarcated expansile mass within the left petrous apex, which was hyperintense on T1 and T2. Based on his clinical presentation and radiologic findings, a diagnosis of cholesterol granuloma was

☆ Competing Interests: The authors declare no conflict of interests.

* Corresponding author. J. Musa, 101 east center street, Rochester, Minnesota 55904.

E-mail address: musajuna@gmail.com (J. Musa).

<https://doi.org/10.1016/j.radcr.2021.12.046>

1930-0433/© 2022 Published by Elsevier Inc. on behalf of University of Washington. This is an open access article under the CC BY-NC-ND license (<http://creativecommons.org/licenses/by-nc-nd/4.0/>)

established. Through this case report we hope to emphasize the role imaging modalities play in the diagnosis and appropriate management of cholesterol granulomas.

© 2022 Published by Elsevier Inc. on behalf of University of Washington.

This is an open access article under the CC BY-NC-ND license (<http://creativecommons.org/licenses/by-nc-nd/4.0/>)

Introduction

Cholesterol granulomas are benign cysts that occur most commonly in the petrous apex of the temporal bone of the skull, a structure that is located near the middle ear. They are not easy to diagnose because of their resemblance with several other lesions [1].

In the past they were called “congenital epidermoid cysts”. Now the terminology has changed and they can also be called chocolate cysts because they are composed of a fluid which contains cholesterol crystals, red blood cells and their breakdown products, multinucleated giant cells and hemosiderin, surrounded by a fibrous capsule. This capsule contains very fragile blood vessels which are prone to being easily damaged and bleeding, thus preventing the resolution of the granuloma [2].

Cholesterol granulomas are believed to be the result of the blockage in the normal aeration of the petrous bone air cells, which result in the damage of the mucosal blood vessels and the precipitation of cholesterol crystals [3]. These crystals are perceived as foreign bodies from the immune cells, leading to an immune response against them and a chronic inflammation resulting in the formation of a granuloma [4]. They affect mostly patients which are young or middle aged, with no preference between genders [2]. Cholesterol granulomas are usually unilateral [5]. The causes for these lesions are believed to be chronic middle ear infections or traumas that cause rupture of the blood vessels in the air cells of the bones of the skull [6].

They may remain asymptomatic for long periods of time. Symptoms usually are related to the expansion of the granuloma and the effect this has on the surrounding structures. Early signs and symptoms include: headaches, diplopia, facial pain or spasms, vertigo and hearing loss. Facial pain is seen in about 20% of patients with cholesterol granuloma, and is because of the compression or irritation of the Trigeminal ganglion on the ipsilateral side [7]. Late symptoms can include: middle ear effusion, tinnitus, speech and swallowing problems and seizures [8].

The diagnosis of cholesterol granulomas is made using an MRI or CT scan. There are some differentiating classical signs of the granuloma on CT scan. The mass is usually well-marginated and expansile, isodense with the brain. On MRI the mass is hyperintense on T1 and T2, and doesn't show a change on gadolinium enhancement [9].

They show a great number of similarities with [congenital cholesteatomas](#) but they are more being. The incidence of petrous apex cholesterol granuloma is at 0.6 cases per 1 million populations, making them extremely rare lesions, but still 10 times more common than petrous apex cholesteatomas [7].

Case presentation

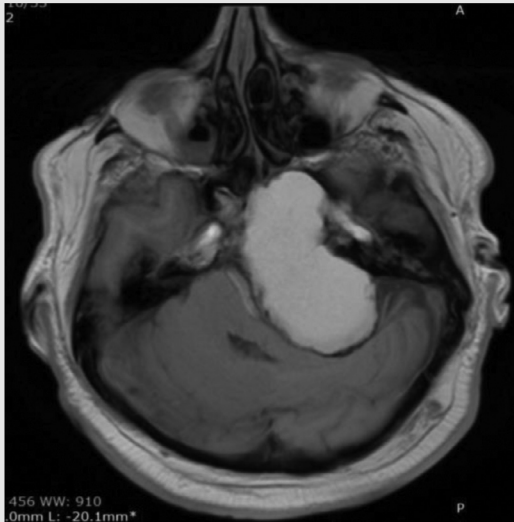A 38-year-old male patient presented to the Neurology Clinic, with complaints of loss of consciousness, headaches, tinnitus in his left ear and a history of chronic otitis media. The patient also reported unilateral pain in the areas supplied by the trigeminal nerve, including the cheek, jaw, teeth, gums, lips and less commonly the eye and forehead. Attacks became progressively more frequent and intense, with the pain becoming increasingly sharper in the course of a few months. His family history was significant for a diagnosis of prostate cancer of his father and arterial hypertension of his mother. His personal medical history was unremarkable. He reported no consumption of alcohol, no smoking and no known food or drug allergies. No primary history of malignancy.

Physical examination was within normal limits, with no significant findings in the cardiovascular, respiratory, abdominal, musculoskeletal and neurological examinations. His complete blood count (CBC) and comprehensive metabolic panel (CMP) was normal. On account of his seizures, an EEG was performed, showing slow mixed polymorphic waves of the delta type and 8 waves with F-T localization on the left, with a tendency to spread and contralaterally associated with paroxysmal elements characteristic of Focal Epilepsy. Taking into consideration his type of epilepsy and the concomitant presence of trigeminal neuralgia, the patient was started on Carbamazepine therapy, initially at 200 mg daily and progressively titrating it to 800 mg daily, divided into two doses, for a period of three months with subsequent EEG follow-up. He was referred for an ENT consult and additional imaging, as well.

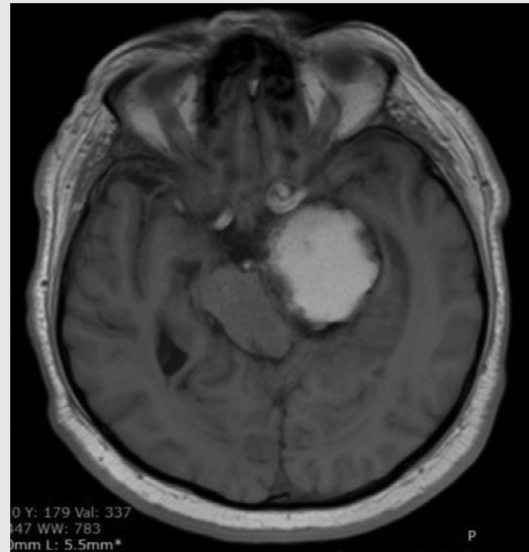
A head MRI was ordered, using TSE/T2W sequence in axial and with fat-sat in coronal plane; TSE/T1W sequence in sagittal and axial planes; FLAIR/T2W sequence in axial plane; Diffusion weighted and ADC mapping MRI images and Post-Contrast T1W sequence in axial, sagittal and coronal planes. It revealed a large, well-demarcated, lobulated heterogeneous expansile mass within the left petrous apex. The lesion is overall hyperintense on T1WI, due to the cholesterol component, heterogeneously-central hyperintense and showed a low signal peripherally, due to the hemosiderin rim on T2WI. No diffusion restriction on DWI/ADC and no enhancement following Gadolinium administration, was evident on T1WI.

Additionally, the mass extended into the sphenoid sinus anteriorly and invaded the left cerebellopontine cistern on the left and a large mass effect was noted, over the pons and on the left cerebellum. It was separate from the inner ear structures and middle ear cavity. No signs of hydrocephalus were present.

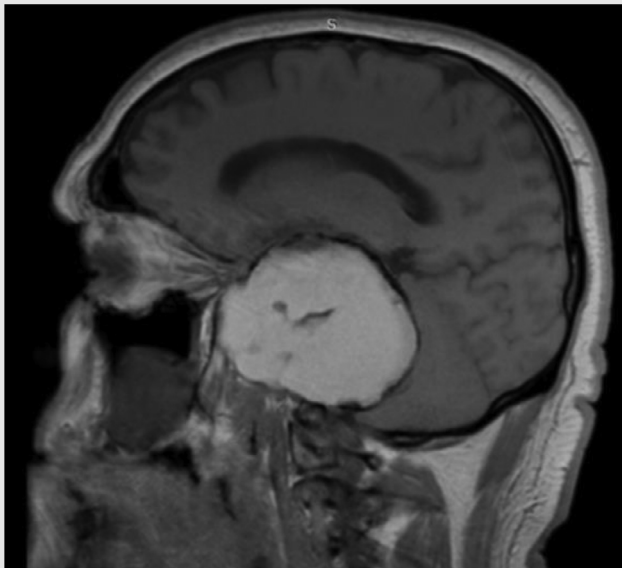
Imaging findings accompanied by the clinical presentation with partial seizures pointed to a diagnosis of a cholesterol granuloma, also known in this location as a giant cholesterol cyst.



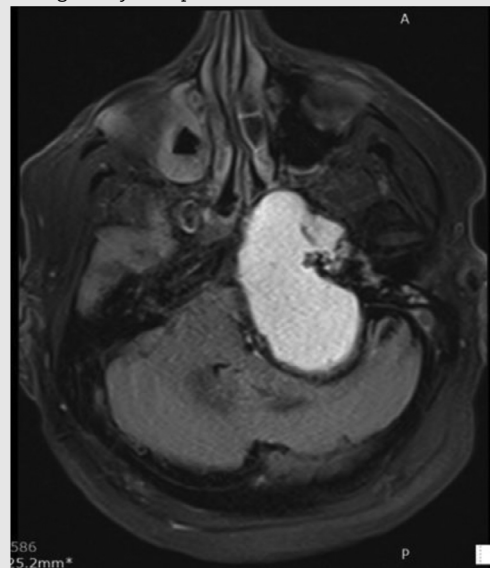
MRI of brain sequence T1WI axial plane results: large well-demarcated, lobulated heterogeneous expansile mass within the left petrous apex. The lesion is overall hyperintense on T1WI (due to cholesterol component)



MRI of brain sequence T1WI axial plane results: Additionally, mass extends into the sphenoid sinus anteriorly, and shows a large mass effect over the pons and on the left cerebellum. No sign of hydrocephalus.



MRI of brain sequence Sagittal T1WI plane results: large well-demarcated, lobulated heterogenous expansile mass within the left petrous apex. The lesion is overall hyperintense on T1WI (due to cholesterol component). Additionally, mass extends into the sphenoid sinus anteriorly, and invades the left cerebellopontine cistern on the left and shows a large mass effect over the pons and on the left cerebellum. It is separate from the inner ear structures and middle ear cavity. No sign of hydrocephalus.



MRI of brain sequence FLAIR axial plane results:

(continued on next page)

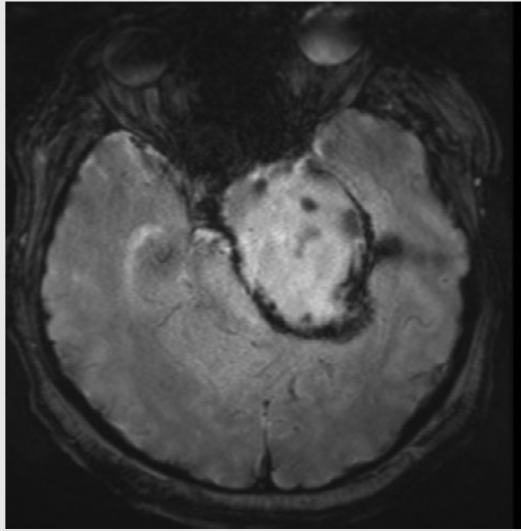
Discussion

Petrous apex cholesterol granulomas are rare expansile lesions, encompassing cystic and chronic inflammatory elements, cholesterol crystals and surrounding fibrous tissue [10–13]. They arise as an inflammatory reaction in response

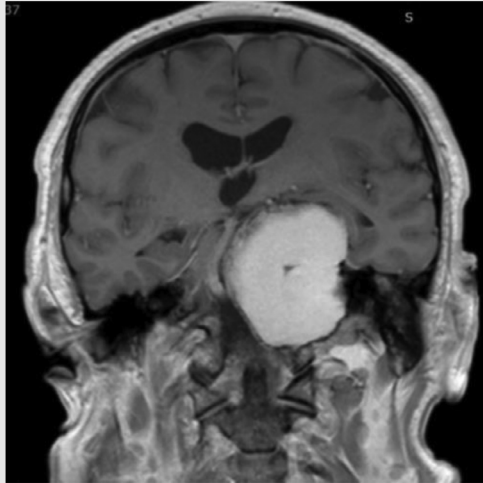
to the presence of by-products of hemoglobin degradation, in particular cholesterol crystals [10–13].

Two main theories have been proposed to explain the pathogenesis of these lesions and despite their different mechanisms, they share three underlying factors, imperative to the development of cholesterol granulomas: hemorrhage, drainage obstruction and impairment of ventilation [12]. The

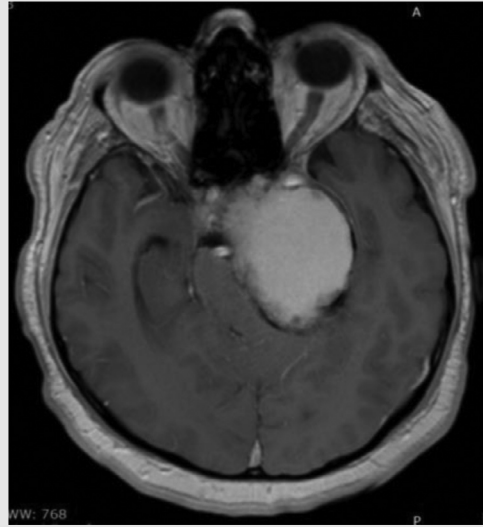
(continued)



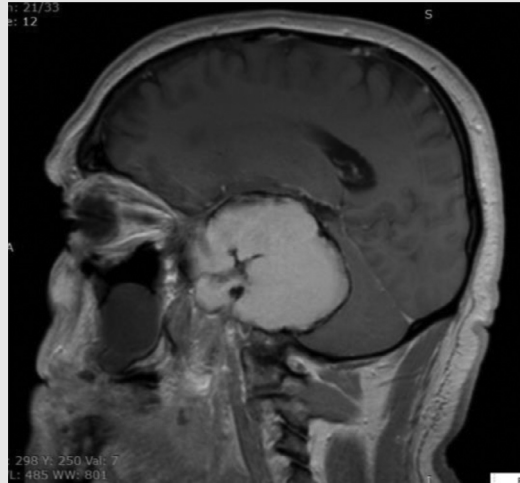Hemo



MRI of brain sequence Coronal T1WI post Gd plane results.



MRI of brain sequence T1WI axial plane post contrast results:



MRI of brain sequence Sagittal T1WI post Gd plane results.

older theory asserts that occlusion of the mastoid air cells is the culprit, leading to a negative pressure caused by reabsorption of gas that induces fluid extravasation into mucosal cells [10–13]. The resultant mucosal edema prompts ensuing hemorrhage from mucosal vessels into the pneumatized cells [10–13]. The novel theory suggests that hyperpneumatization of the petrous apex, during the development of air cells, elicits erosion of the marrow-filled cavities and exposure of the bone marrow, that subsequently predisposes for recurrent hemorrhage and obstruction [10–13]. In both scenarios, the hemoglobin in the extravasated blood in the mastoid air cells undergoes progressive degradation into hemosiderin and cholesterol crystals [10–13]. This leads to an inflammatory reaction and granuloma formation [10–13].

Although the reported incidence of cholesterol granulomas is low, they are one of the primary petrous apex lesions [14]. Imaging modalities are crucial to establishing the diagno-

sis. CT scans and MRI provide sensitive and specific findings that help distinguish cholesterol granulomas from other common lesions of the petrous apex. Important differential diagnoses to consider include cholesteatomas, petrous apex effusions, mucoceles, cysts, apical petrositis and tumors [13,14]. On CT scans cholesterol granulomas appear as well-defined, non-enhancing, expansile masses, associated with cortical thinning and trabecular erosion [10,13,14]. On MRI, they exhibit high signal intensity on T1- and T2-weighted MRI, due to the accumulation of by-products of hemoglobin degradation, high signal intensity on FLAIR MRI and low signal intensity on diffusion-weighted MRI. After Gadolinium administration, no central enhancement is evident [10,13,14]. A hypointense peripheral rim in T2-weighted images represents the hemosiderin deposits [10,13,14]. These specific features were present in the imaging tests that were performed in our patient, that ultimately led to the conclusive diagnosis.

Conclusion

Through this case report, we hope to add to the existing body of literature on petrous apex cholesterol granulomas, highlighting its vague clinical presentation and pathognomonic radiologic findings. Additionally we hope to emphasize the role imaging modalities play in the timely diagnosis, appropriate preoperative evaluation, differential diagnosis, thereby guiding surgical treatment and follow up.

Patient consent

An Patient consent is obtained.

REFERENCES

- [1] <https://www.mountsinai.org/locations/skull-base-surgery-center/conditions/cholesterol-granulomas>.
- [2] Hoeffner E, Mukherji S, Gandhi G, Gomez-Hassan D. Temporal Bone Imaging Book. Thieme 2022:244–53 ISBN:1588904016.
- [3] Eisenberg MB, Haddad G, Al-Mefty O. Petrous apex cholesterol granulomas: evolution and management. *J Neurosur* 1997;86(5):822–9.
- [4] Maeta M, Saito R, Nakagawa F, Miyahara T. Surgical intervention in middle-ear cholesterol granuloma. *J Laryngol Otol* 2003;117:344–8.
- [5] Nakano Y. Cholesterol granuloma. *Pract Otol (Kyoto)* 1990;83:1761–6.
- [6] Friedmann I, Graham MD. The ultrastructure of cholesterol granuloma of the middle ear: an electron microscopic study. *J laryngol Otol* 2002;116:877–81.
- [7] Isaacson B. Cholesterol granuloma and other petrous apex lesions. *Otolaryngol Clin North Am* 2015;48(2):361–73.
- [8] Wiet R. Ear and temporal bone surgery. Thieme 2006:360–8 ISBN:1588901211.
- [9] Dinh CT, Stefania Goncalves, Rita Bhatia, Kim Truong, Fred Telischi, Simon Angeli, et al. Atypical radiographic features of skull base cholesterol granuloma. *Eur Arch Otorhinolaryngol* 2016;273(6):1425–31.
- [10] Royer Mark C, Pensak Myles L. Cholesterol granulomas. *Curr Opin Otolaryngol Head Neck Surg* 2007;15:319–22. doi:10.1097/MOO.0b013e3282a08f74.
- [11] Kim Ho Chan, et al. Petrous apex cholesterol granuloma presenting as endolymphatic hydrops: a case report. *Clin Exp Otorhinolaryngol* 2009;2:151–4. doi:10.3342/ceo.2009.2.3.151.
- [12] Kuruma T, et al. Large cholesterol granuloma of the middle ear eroding into the middle cranial fossa. *Case Rep Otolaryngol* 2017:4793786. doi:10.1155/2017/4793786.
- [13] Ho M, et al. Petrous apex cholesterol granuloma: pictorial review of radiological considerations in diagnosis and surgical histopathology. *JLaryngol Otol* 2013;127:339–48. doi:10.1017/S0022215113000091.
- [14] Chapman Philip R, et al. Petrous apex lesions: pictorial review. *Ajr. Am J Roentgenol* 2011;196:WS26–37 Quiz S40-3. doi:10.2214/AJR.10.7229.