





Review Article

# Treatments of Hepatocellular Carcinoma with Portal Vein Tumor Thrombus: Current Status and Controversy



Zhu-Jian Deng<sup>#</sup>, Le Li<sup>#</sup>, Yu-Xian Teng, Yu-Qi Zhang, Yu-Xin Zhang, Hao-Tian Liu, Jian-Li Huang, Zhen-Xiu Liu, Liang Ma<sup>\*</sup> and Jian-Hong Zhong<sup>\*</sup>

Hepatobiliary Surgery Department, Guangxi Liver Cancer Diagnosis and Treatment Engineering and Technology Research Center, Guangxi Medical University Cancer Hospital, Nanning, Guangxi, China

Received: 13 May 2021 | Revised: 30 June 2021 | Accepted: 12 July 2021 | Published: 10 August 2021

## Abstract

The proportions of patients with hepatocellular carcinoma (HCC) involving portal vein tumor thrombus (PVTT) varies greatly in different countries or regions, ranging from 13% to 45%. The treatment regimens for PVTT recommended by HCC guidelines in different countries or regions also vary greatly. In recent years, with the progress and development of surgical concepts, radiotherapy techniques, systematic therapies (for example, VEGF inhibitors, tyrosine kinase inhibitors and immune checkpoint inhibitors), patients with HCC involving PVTT have more treatment options and their prognoses have been significantly improved. To achieve the maximum benefit, both clinicians and patients need to think rationally about the indications of treatment modalities, the occurrence of severe adverse events, and the optimal fit for the population. In this review, we provide an update on the treatment modalities available for patients with HCC involving PVTT. Trials with large sample size for patients with advanced or unresectable HCC are also reviewed.

**Citation of this article:** Deng ZJ, Li L, Teng YX, Zhang YQ, Zhang YX, Liu HT, *et al.* Treatments of Hepatocellular Carcinoma with Portal Vein Tumor Thrombus: Current Status and Controversy. *J Clin Transl Hepatol* 2022;10(1):147–158. doi: 10.14218/JCTH.2021.00179.

## Introduction

Hepatocellular carcinoma (HCC) is the seventh most common malignant tumor, resulting in more than 600,000 deaths every year.<sup>1</sup> Due to the lack of typical symptoms and signs

of early-stage HCC, HCC is often diagnosed as intermediate or advanced disease.<sup>2</sup> The complex hepatic vascular system, including portal vein, hepatic vein, hepatic artery and intrahepatic bile duct, may be the main reason for the invasion of hepatic vascular system growth characteristics of HCC. Macrovascular invasion (MVI) refers to obvious invasion of the main portal vein and its branches, hepatic vein and its branches, or inferior vena cava. In all types of MVI, portal vein tumor thrombus (PVTT) is the most frequent form. HCC patients with PVTT showed a worse prognosis than those without, which may be related to the high tumor invasiveness, insufficient hepatic reserve function, portal hypertension caused by PVTT and other complications. The median survival time with the best supportive care is only 4 to 6 months.<sup>3,4</sup>

Due to the large difference of incidence of PVTT in different regions, high tumor invasiveness, and the poor prognoses, European and American HCC guidelines do not recommend hepatic resection or transarterial chemoembolization (TACE) for patients with HCC involving PVTT. For example, the European,<sup>5</sup> American<sup>6</sup> and ESMO<sup>7</sup> guidelines for the diagnosis and treatment of HCC based on the Barcelona Clinical Liver Cancer (BCLC) staging system only recommend systematic treatment regimens such as targeted drugs, and even consider PVTT to be a contraindication of hepatic resection. But in recent years, the Asian HCC guidelines, in addition to the results from large sample, multicenter, randomized clinical trials, also recognized the results from real-world practice. Beyond recommending targeted drugs, nivolumab and other immunotherapy as the first-line treatment, Pan-Asian has adapted the ESMO Clinical Practice Guidelines,<sup>8,9</sup> Asian-Pacific guidelines,<sup>10</sup> and guidelines in Korea,<sup>11</sup> Taiwan,<sup>12</sup> and mainland China<sup>13</sup> for the diagnosis and treatment of HCC; they also suggest that local therapies, such as TACE, local radiotherapy, hepatic resection, and hepatic arterial infusion chemotherapy (HAIC), can also be used as an optional regimen for patients with PVTT.

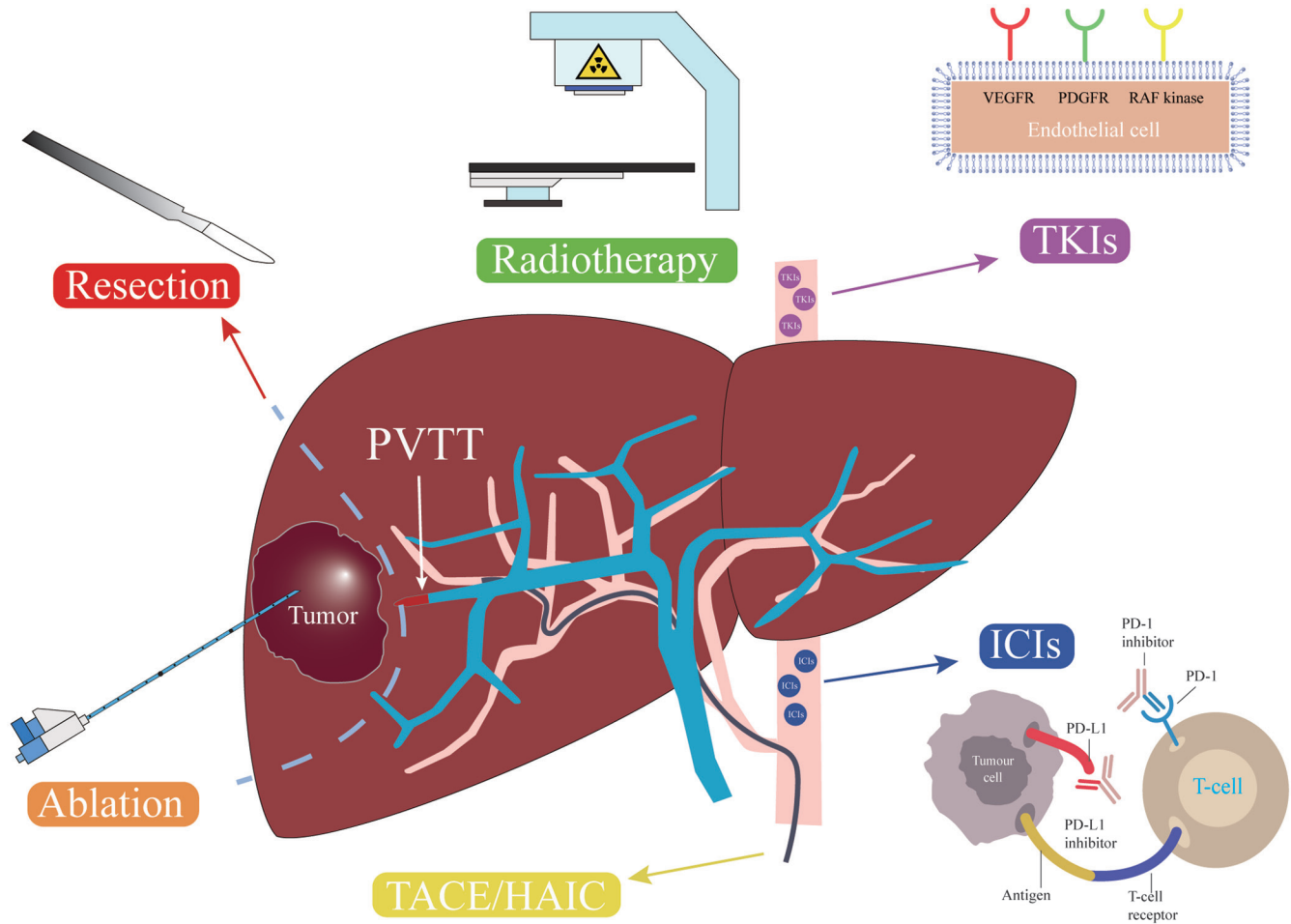
In recent years, with the progress and development of surgical concepts, radiotherapy techniques, targeted drugs and immunotherapy, patients with HCC involving PVTT have more treatment options and their prognoses have been significantly improved.<sup>14–17</sup> These therapeutic methods have different mechanisms of action (Fig. 1). Therefore, this updated review summarizes the current situation, existing controversies and future development of treatment measures for HCC with PVTT. In order to provide the latest and comprehensive clinical evidence, a systematic literature search was performed in PubMed by using the keywords of 'hepatocellular carcinoma', 'advanced', 'unresectable', and 'portal

**Keywords:** Hepatocellular carcinoma; Portal vein tumor thrombus; Treatment modality.

**Abbreviations:** BCLC, Barcelona Clinical Liver Cancer; CI, confidence interval; HCC, hepatocellular carcinoma; HR, hazard ratio; MVI, macrovascular invasion; ORR, objective response rate; PVTT, portal vein tumor thrombus; RECIST, Response Evaluation Criteria in Solid Tumors; TACE, transarterial chemoembolization.

<sup>#</sup>Contributed equally to this work.

**\*Correspondence to:** Jian-Hong Zhong and Liang Ma, Hepatobiliary Surgery Department, Guangxi Medical University Cancer Hospital, Nanning, Guangxi 530021, China. ORCID: <https://orcid.org/0000-0002-1494-6396> (JHZ), <https://orcid.org/0000-0001-8106-373X> (LM). Tel/Fax: +86-771-5301253, E-mail: zhongjianhong@gxmu.edu.cn (JHZ), malianggxyd@163.com (LM).



**Fig. 1. Different therapeutic methods have different mechanisms of action for patients with HCC involving PVTT.** HAIC, hepatic arterial infusion chemotherapy; HCC, hepatocellular carcinoma; ICIs, immune checkpoint inhibitors; PVTT, portal vein tumor thrombus; TACE, transarterial chemoembolization; TKI, tyrosine kinase inhibitors.

vein tumor thrombus’. We focus our discussion herein on the phase Ib to III clinical trials related to treatment of advanced or unresectable HCC with PVTT published after January 1, 2010 (mainly full-text), as well as prospective or retrospective comparative studies with relatively large sample size.

**Epidemiology of PVTT**

The proportions of patients with HCC involving PVTT varies greatly in different countries or regions, which may be related to the economic living standard of the location. A study from China involving 6,241 patients with primary HCC found the proportion of PVTT was about 45%.<sup>2</sup> In 2014, a study in Hong Kong showed that 39.1% of 3,856 HCC patients had PVTT.<sup>18</sup> In 2016, a study from Italy reported that 42.0% of 5,183 HCC patients had PVTT.<sup>19</sup> Data from the 19th national liver cancer survey in Japan revealed that 13.0% patients with HCC were accompanied by PVTT and 4.6% by hepatic vein tumor thrombus.<sup>20</sup>

**Classification of PVTT**

Although American Joint Committee on Cancer tumor-node-

metastasis, BCLC,<sup>21</sup> Japan Integrated Staging,<sup>22</sup> Hong Kong Liver Cancer,<sup>18</sup> ITA.LL.CA,<sup>19</sup> and other HCC guidelines from other countries or regions<sup>5-13,23,24</sup> emphasize the effect of PVTT on patients’ prognoses; notably, the diversity of PVTT growth sites determines the great difference of their prognoses. Therefore, it is necessary to classify PVTT according to the scope of PVTT involvement, and then select different treatment regimens according to different types.

The first classification system of PVTT was reported by the Liver Cancer Study Group of Japan.<sup>25,26</sup> This system is based on the clinical features, imaging findings, pathological findings of PVTT, and patients’ prognoses. PVTT is divided into five grades in this classification system (Table 1).<sup>25,26</sup> Since then, this classification system was cited by data from Japan’s annual liver cancer census. For example, the report of the 19th Japan’s annual liver cancer census<sup>20</sup> showed that the proportion of Vp0, Vp1, Vp3, and Vp4 were 87.1%, 3.1%, 2.6%, 3.9%, and 3.4%, respectively, according to imaging diagnosis, and 84.1%, 9.7%, 3.1%, 2.2%, and 1.0%, respectively, according to postoperative pathological diagnosis. This classification system is relatively highly recognized by scholars around the world. In 2007, another PVTT classification system was reported by scholars from China.<sup>27</sup> Their first version included type I to type IV (Table 2).<sup>27,28</sup> In 2011, type I<sub>0</sub> was added.<sup>28</sup> Recently, this classification system has been highly recog-

**Table 1. PVTT classification system from the Liver Cancer Study Group of Japan<sup>25,26</sup>**

Grade	Definition
Vp0	Absence of invasion of (or tumor thrombus in) the portal vein
Vp1	Invasion of (or tumor thrombus in) distal to the second-order branches of the portal vein, but not of the second-order branches
Vp2	Invasion of (or tumor thrombus in) second-order branches of the portal vein
Vp3	Invasion of (or tumor thrombus in) first-order branches of the portal vein
Vp4	Invasion of (or tumor thrombus in) the main trunk of the portal vein and/or contra-lateral portal vein branch to the primarily involved lobe

PVTT, portal vein tumor thrombus.

nized by scholars in mainland China.<sup>13,29</sup>

## Treatments for HCC with PVTT

### Hepatic resection

At present, in addition to the HCC diagnosis and treatment guidelines in China<sup>13</sup> and Japan,<sup>23</sup> which have their own independent HCC staging systems, HCC guidelines in other countries or regions mostly adopt the BCLC staging system.<sup>5-9,11,12,24</sup> However, the indications for hepatic resection defined by the BCLC staging system in successive versions are very narrow, and HCC with PVTT has been considered contraindicated for hepatic resection.<sup>21,30,31</sup> Therefore, in recent years, many HCC researchers all over the world have questioned the indications of hepatic resection in the BCLC staging system. An influential study that was published in 2013 by Torzilli *et al.*<sup>32</sup> retrospectively analyzed clinical data of 2,046 patients who underwent hepatic resection from 10 medical centers of eastern and western countries. There were 297 (14.5%) patients with BCLC stage C disease and 275 (13.4%) patients with macrovascular invasion. Five years overall survival and recurrence-free survival were 38% and 18% after hepatic resection. Patients who underwent hepatic resection in this study had significantly better long-term overall survival than patients who underwent TACE in other studies. Therefore, Torzilli *et al.*<sup>32</sup> proposed that guidelines based on the BCLC system should be modified to appropriately expand indications of hepatic resection. However, the proposal of Torzilli *et al.*<sup>32</sup> immediately sparked a heated debate among several leading liver cancer experts. For example, Bruix,<sup>33,34</sup> a leading member of the BCLC group, and Mazzaferro,<sup>35</sup> the main founder of the Milan standard for liver transplantation, still do not agree with the proposal of Torzilli and coworkers,<sup>32</sup> but several surgical experts in the field of liver cancer in Asia<sup>36-38</sup> fully agree with Torzilli and coworkers. Moreover, the findings of Torzilli were completely consistent with our findings that hepatic resection was associated with significantly better overall survival than TACE in selected patients with stage C HCC

and preserved liver function.<sup>39</sup> Therefore, "we're still in an update process of the BCLC system."<sup>40</sup> "Surgeons should not shy away from hepatic resection when it is feasible, though they should be prepared for the fact that the procedure is technically demanding".<sup>41</sup>

In 2015, a systematic review which included 24 studies involving 4,389 patients with HCC and macrovascular invasion after hepatic resection found the median perioperative mortality was 2.7% (0-24%), the median complication rate was 30.2% (4.0-42%), the median overall survival at 1, 3, 5 years were 50%, 23% and 18%, and the corresponding median recurrence-free survival were 32%, 20% and 18%.<sup>42</sup> However, due to insufficient information of included studies, subgroup analysis based on PVTT classification was not performed. In 2016, a retrospective study from Japan included 6,474 patients with HCC involving PVTT.<sup>43</sup> In that study, 2,093 patients underwent hepatic resection, while 438 patients underwent palliative treatments. The perioperative mortality in the hepatic resection group was 3.7%. Patients in the hepatic resection group had significantly higher overall survival than those in the non-resection group among patients with Child-Pugh class A or B liver function (all  $p < 0.001$ ). Results from propensity score analysis confirmed these findings. Subgroup analysis based on PVTT classification indicated that the advantage of hepatic resection was only in patients with Vp1-3 but was not significant in patients with Vp4 (hazard ratio [HR]: 0.84, 95% confidence interval [CI]: 0.63-1.12). In 2016, a retrospective study from China established a model to select patients who would benefit most from hepatic resection.<sup>44</sup> The training cohort enrolled 432 HCC patients with I/II stage (Vp1-3) PVTT, while the internal validation cohort enrolled 285 patients. Patients from three other centers were assigned as three external validation cohorts ( $n=286, 189, \text{ and } 135$ , respectively). The Eastern Hepatobiliary Surgery Hospital-PVTT score ( $\leq / > 3$ ) significantly differentiated overall survival, with median survival of 17.0 and 7.9 months, respectively ( $p < 0.001$ ).<sup>44</sup> The study did not include patients with type III (Vp4) PVTT or those who underwent non-hepatic resection. Therefore, it is unknown whether this predictive model is appropriate for patients with type III PVTT or those receiving other treatment regimens.

**Table 2. PVTT classification system from China<sup>27,28</sup>**

Type	Definition
I <sub>0</sub>	Tumor thrombus formation found under microscopy
I	Tumor thrombi involving segmental branches of portal vein or above
II	Tumor thrombi involving right/left portal vein
III	Tumor thrombi involving the main portal vein trunk
IV	Tumor thrombi involving the superior mesenteric vein

PVTT, portal vein tumor thrombus.

In conclusion, although hepatic resection for HCC involving PVTT is not recommended in European and American HCC guidelines,<sup>5-7</sup> the HCC guidelines in Asia have appropriately expanded the surgical indications.<sup>8-13,23,24</sup> Large-sample studies in real world settings suggest that many HCC patients with type I/II (Vp1-3) PVTT may have good long-term outcomes from hepatic resection.<sup>43,44</sup> However, a high rate of postoperative recurrence is one of the most striking features of hepatic resection in patients with HCC involving PVTT. In recent years, a large number of studies have shown that postoperative adjuvant TACE can significantly reduce the rate of recurrence and ultimately prolong survival time.<sup>45-47</sup> In addition, phase III clinical trials (e.g., Imbrave 050)<sup>48</sup> exploring the efficacy of adjuvant targeted agents and immune checkpoint inhibitors after hepatic resection are ongoing and the results are expected to guide clinical treatment.

### Radiotherapy

In 1994, Chen *et al.*<sup>49</sup> from Taiwan first reported the efficacy of external radiotherapy to treat PVTT. In this study, 10 patients with unilateral PVTT received radiotherapy (3,000–5,000 cGY) using a linear accelerator under localization by real-time ultrasound. The PVTT in five patients completely disappeared; while in the other five patients, it showed partial shrinkage. However, external radiotherapy had poor precision positioning ability at that time, which could easily cause irreversible liver function damage or even liver failure. With the improvement of external radiotherapy in recent years and the rapid development of three-dimensional conformal radiotherapy, proton beam therapy, intensity-modulated radiotherapy, and stereotactic radiotherapy, the clinical application of external radiotherapy for HCC is becoming more and more extensive, and there are more and more reports in the publicly-available literature. The new version of guidelines from Europe<sup>5</sup> and America<sup>6</sup> have started to mention the application of external radiotherapy, but without specific recommendations. The ESMO guideline<sup>7</sup> recommended external radiation to treat early HCC. However, guidelines in Korea,<sup>11</sup> Taiwan,<sup>12</sup> and mainland China<sup>13</sup> recommended external radiotherapy (or combined with other treatments) to treat several stages of HCC, including that with PVTT.

In 2018, a systematic review including 37 studies involving 2,513 HCC patients with PVTT analyzed the differences of the efficacy and safety between different modes of radiotherapy.<sup>50</sup> In three groups of patients who received stereotactic radiotherapy, three-dimensional conformal radiotherapy or selective internal radiation therapy, 1-year overall survival rates were 48.5%, 43.8% and 46.5% and objective response rates (includes tumor and/or PVTT) were 70.7%, 51.3% and 33.3%, respectively. In the three-dimensional conformal radiotherapy group and the selective internal radiation therapy group, adverse events of at least grade 3 were mainly lymphopenia and bilirubin elevation. The stereotactic body radiotherapy group rarely experienced adverse events of at least grade 3. However, this study did not perform subgroup analysis based on PVTT classification. A recent retrospective study compared the efficacy of intensity-modulated radiotherapy ( $n=154$ ) and stereotactic radiotherapy ( $n=133$ ) for HCC patients with PVTT. The two methods were associated with similar overall survival, progression-free survival, intrahepatic control, and local control.<sup>51</sup> In 2018, a retrospective study compared the efficacy of 134 HCC patients with PVTT who received three-dimensional conformal radiotherapy and 189 patients who received hepatic resection.<sup>52</sup> In the analysis of the total sample, patients in the hepatic resection group had a signif-

icantly better overall survival than those in the radiotherapy group. Among patients with type I (Vp1-2) PVTT, hepatic resection was associated with significantly better overall survival than radiotherapy. Among patients with type II (Vp3) PVTT, patients in the two groups had similar overall survival. However, among patients with type III (Vp4) PVTT, patients in the radiotherapy group had significantly better overall survival than those in the hepatic resection group.<sup>52</sup> In 2016, a multicenter retrospective study ( $n=1,580$ ) compared the median survival time of patients with HCC involving PVTT who received hepatic resection, TACE, TACE combined with sorafenib, or TACE combined with radiotherapy.<sup>53</sup> Among patients with type I (Vp1-2) PVTT, the hepatic resection group had the best overall survival. Among patients with type II (Vp3) PVTT, median survival time in the hepatic resection group and in the TACE combined with radiotherapy group were 12.5 and 10.6 months, respectively ( $p=0.046$ ). Among patients with type III (Vp4) PVTT, median survival time was longer in the TACE combined with radiotherapy group than in the hepatic resection group (8.9 vs. 6.0 months,  $p=0.401$ ). In 2018, a single-center randomized controlled study from Korea compared the prognoses of patients with HCC involving PVTT who received sorafenib ( $n=45$ ) or TACE combined with three-dimensional conformal radiotherapy ( $n=45$ ).<sup>54</sup> Patients in the combination group had significantly higher progression-free survival (86.7% vs. 34.3%,  $p<0.001$ ), radiographic response (33.3% vs. 2.2%,  $p<0.001$ ), longer median time to progression (31.0 vs. 11.7 weeks,  $p<0.001$ ), and longer median survival time (55.0 vs. 43.0 weeks,  $p=0.04$ ) than those in the sorafenib group. Moreover, five (11.1%) patients in the combination group had the opportunity to undergo radical hepatic resection due to tumor down staging. No patient in the combination group suspended treatment due to liver dysfunction.<sup>54</sup>

The SARAH study that was published in 2017 enrolled patients with local advanced HCC from 25 centers in France. There were 237 patients in the yttrium-90 radiotherapy group and 222 patients in the sorafenib group. The median survival times were similar between the two groups (8.0 vs. 9.9 months,  $p=0.18$ ), and the incidence of serious adverse events were 77% and 82%.<sup>55</sup> Another study from Italy also found yttrium-90 radiotherapy and sorafenib provide similar overall survival.<sup>56</sup> The third study ( $n=120$ ) investigated the safety and efficacy of yttrium-90 for patients with HCC and PVTT. The median overall survival was 14.1 months and median progression-free survival was 6.5 months.<sup>57</sup> A systematic review including 17 studies ( $n=722$ ) showed that the median time to progression was 5.6 months, the median objective response rate was 19.7%, and the median survival time was 9.7 months in patients with HCC involving PVTT who underwent yttrium-90 internal radiotherapy.<sup>58</sup>

In recent years, there are some reports about the application of radiotherapy as neoadjuvant treatment of hepatic resection. In 2019, a randomized controlled study compared the efficacy of neoadjuvant three-dimensional conformal radiotherapy combined with hepatic resection ( $n=82$ ) and hepatic resection alone ( $n=82$ ) in HCC patients with type II/III (Vp3-4) PVTT.<sup>59</sup> A total of 17 (20.7%) patients in the neoadjuvant group had PVTT regression. Neoadjuvant was associated with significantly higher 2-year overall survival than hepatic resection alone (27.4% vs. 9.4%,  $p<0.001$ ).

In summary, external radiotherapy has played an increasingly important role in the multidisciplinary treatment of patients with HCC involving PVTT. External radiotherapy combined with other treatments provides the greatest benefit to such patients. At present, three-dimensional conformal radiotherapy is the most widely reported external radiotherapy technique with relatively clear curative efficacy. High-level evidence has recently suggested the value of proton beam radiotherapy<sup>60</sup> and stereotactic radiotherapy<sup>61</sup>

in the treatment of small HCC, and positive results of these two methods in PVTT are expected.

### Treatments via hepatic artery

The treatments of HCC through the hepatic artery mainly include yttrium-90 internal radiotherapy, TACE and HAIC. TACE is still recognized as one of the most commonly used treatments for unresectable HCC.<sup>10-13</sup> In the past decade, many studies have reported the efficacy of TACE to treat patients with HCC involving PVTT. Median survival time was 9 (4 to 16) months, and 1- and 3-year overall survival rates were 48% and 18%, respectively.<sup>4,62-70</sup> In general, patients who underwent hepatic resection had significantly better overall survival than those who underwent TACE,<sup>67,68,71</sup> especially for patients with type I/II (Vp1-3) PVTT.<sup>68</sup>

In recent years, with the wide application of targeted drugs, transarterial treatments combined with targeted drugs have been increasingly used. The TACTICS study compared the efficacy of TACE combined with sorafenib ( $n=80$ ) and TACE alone ( $n=76$ ) for unresectable HCC (11.8% were BCLC stage C disease). Patients in the combination group had a significantly longer median progression-free survival (25.2 vs. 13.5 months) and time-to-progression (26.7 vs. 16.4 months) than those in the TACE group.<sup>72</sup> A retrospective study compared the efficacy of sorafenib combined with TACE ( $n=164$ ) versus sorafenib alone ( $n=191$ ) for BCLC stage C HCC (51.3% involving PVTT). Patients in the combination group had significantly longer time-to-progression (2.5 vs. 2.1 months) and median survival time (8.9 vs. 5.9 months) than those in the sorafenib group.<sup>73</sup> A multi-center randomized controlled study compared the efficacy of sorafenib combined with HAIC ( $n=125$ ) versus sorafenib alone ( $n=122$ ) to treat patients with HCC involving PVTT (Vp1-4).<sup>74</sup> Patients in the combination group also had significantly longer median survival time (13.4 vs. 7.1 months) and median progression-free survival (7.0 vs. 2.6 months) than those in the sorafenib group. However, the combination group had a higher rate of grade 3/4 adverse events than the sorafenib group.

These studies suggest that TACE or HAIC combined with sorafenib may be good candidates for patients with HCC involving PVTT. Clinical trials of TACE or HAIC combined with other targeted drugs (such as lenvatinib, apatinib, etc.) or immune checkpoint inhibitors (such as nivolumab, trelizumab, etc.) are ongoing (NCT03755791, NCT03778957, NCT04191889, NCT03937830, etc.), and more positive results are expected to guide clinical practice.

### Systematic treatment

Since publication of the SHARP study in 2008,<sup>75</sup> systematic drugs for advanced or unresectable HCC have developed rapidly (Table 3).<sup>75-98</sup> Compared with placebo, sorafenib significantly prolonged median survival time for patients with advanced HCC (European and American populations, 10.7 vs. 7.9 months,  $p<0.001$ ;<sup>75</sup> Asian Pacific population, 6.5 vs. 4.2 months,  $p=0.014$ <sup>76</sup>). Sorafenib is the first effective drug used as a first-line systematic therapy, but patients are prone to drug resistance. Therefore, several trials investigated the efficacy of sunitinib,<sup>77</sup> brivanib,<sup>78</sup> linifanib,<sup>79</sup> and sorafenib combined with erlotinib.<sup>80</sup> However, when comparing with sorafenib, all these trials did not meet their primary end point of overall survival. One trial comparing the efficacy of FOLFOX4 (intravenously infusional fluorouracil, leucovorin, and oxaliplatin) and doxorubicin also did not meet its primary end point of overall survival.<sup>81</sup> The REFLECT study analyzed the efficacy of lenvatinib in 954 patients (79% with BCLC stage C HCC) with unresect-

able HCC.<sup>82</sup> The median survival time was similar between lenvatinib and sorafenib groups (13.6 vs. 12.3 months). However, patients in the lenvatinib group had significantly longer progression-free survival than those in the sorafenib group (7.4 vs. 3.7 months), especially in Asian populations, patients with hepatitis B virus-related HCC, or those with BCLC stage C disease. Lenvatinib was the first drug with non-inferiority to sorafenib in overall survival. The ZGDH3 study<sup>83</sup> evaluated the safety and efficacy of donafenib versus sorafenib as first-line treatment for advanced HCC. Median survival time was significantly better in the donafenib group than in the sorafenib group (12.1 vs. 10.3,  $p=0.036$ ). Compared with sorafenib (5.1%) and donafenib (4.6%), lenvatinib (18.8) was associated with the highest objective response rate (ORR) measured according to Response Evaluation Criteria in Solid Tumors (RECIST) 1.1. In addition, donafenib (37.5%) was associated with lower adverse events of at least grade 3 than that of lenvatinib (56.7) or sorafenib (44.8%; Fig. 2A).

As a single-arm clinical trial, CheckMate 040 (phase I/II)<sup>84</sup> established the clinical indication of nivolumab, with ORR of 14.3% per RECIST v1.1. It was approved by the USA's Food and Drug Administration to be used as a second-line treatment for advanced HCC. The Checkmate 459 study<sup>85</sup> compared the efficacy of nivolumab and sorafenib as first-time treatments in 743 patients with advanced HCC and failed to acquire the per specified criteria. The HR of overall survival was 0.85 (95%CI: 0.72-1.02). KEYNOTE-524 (phase Ib trial) explored the efficacy of lenvatinib combined with pembrolizumab for 104 patients with unresectable HCC (68.3% with BCLC stage C HCC). The median overall survival was 22 months and the incidence of adverse events of at least grade 3 was 67%.<sup>86</sup> The IMbrave150 study<sup>87</sup> included 501 patients with unresectable HCC (82% BCLC stage C HCC) who received atezolizumab plus bevacizumab or sorafenib. Overall survival (HR: 0.58, 95% CI: 0.42-0.79), progression-free survival (HR: 0.59, 95% CI: 0.47-0.76), and ORR (27.3% vs. 11.9%) of patients who received atezolizumab plus bevacizumab were significantly better than those who received sorafenib. However, the ORR was only 8.5% among those who underwent atezolizumab monotherapy ( $n=59$ ).<sup>88</sup> A recent phase II trial from China reported the efficacy and safety of camrelizumab plus apatinib ( $n=70$ ) for patients with advanced HCC. The ORR was 34.3% but with a high incidence of adverse events of at least grade 3 (78.6%; Fig. 2A).<sup>89</sup>

Due to sorafenib-treated patients showing a propensity to drug resistance, some researchers have explored the efficacy and safety of other targeted drugs and immune checkpoint inhibitors as second-line systemic treatment. The RESORCE study (86.7% BCLC stage C HCC) confirmed that sorafenib followed by regorafenib extended the survival time of HCC patients to more than 26 months.<sup>90</sup> This survival time is encouraging. However, the ORR was only 6.6% with a high incidence of adverse events of at least grade 3 (66.3%; Fig. 2B). Another study included 707 patients (86.7% BCLC stage C HCC) who had received previous treatment with sorafenib for advanced HCC and found cabozantinib significantly prolonged median survival time (10.2 vs. 8.0 months,  $p=0.005$ ) and progression-free survival (5.2 vs. 1.9 months,  $p<0.001$ ) compared with placebo.<sup>91</sup> Also, the ORR was as low as 3.8%, and the incidence of adverse events of at least grade 3 was as high as 67.7%.<sup>91</sup> Ramucirumab (35.3% BCLC stage C HCC) also significantly prolonged median survival time (8.5 vs. 7.3 months,  $p=0.020$ ) and progression-free survival (2.8 vs. 1.6 months,  $p<0.001$ ) compared with placebo in patients with HCC and  $\alpha$ -fetoprotein concentrations of at least 400 ng/mL who had previously received sorafenib.<sup>92</sup> Moreover, ramucirumab was well tolerated.<sup>92,93</sup> The KEYNOTE-240 study<sup>94</sup> (79.4% BCLC stage C HCC) compared the efficacy

Table 3. Clinical trials of first- or second-line systemic therapy for patients with advanced or unresectable HCC (sample size of at least 100 in a trial)

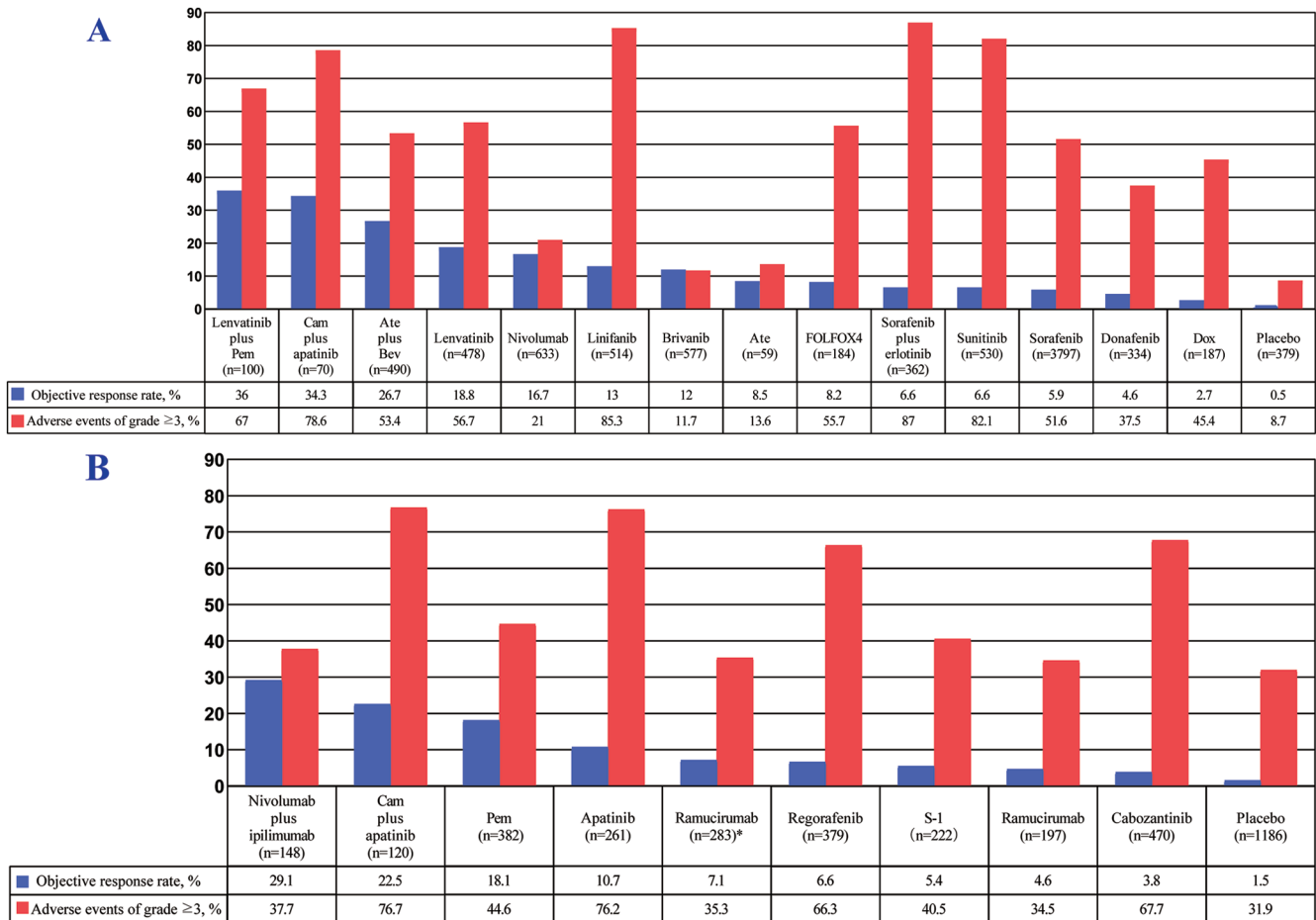
Trials	Phase	Experimental arms	Follow-up duration, months	ORR according to RECIST 1.1, %	Median survival time, months	HR (95%CI) of OS	Median PFS time, months <sup>a</sup>	HR (95%CI) of PFS	Treatment-related adverse events of grade ≥3, %
First-line									
Llovet et al. 2008 (SHARP) <sup>75</sup>	III	Sorafenib (n=299) vs. placebo (n=303)	-	0.7 vs. 0.3	10.7 vs. 7.9	0.69 (0.55-0.87)	5.5 vs. 2.8	0.58 (0.45-0.74)	15.2 vs. 10.6
Cheng et al. 2009 <sup>76</sup>	III	Sorafenib (n=150) vs. placebo (n=76)	-	3.3 vs. 1.3	6.5 vs. 4.2	0.68 (0.50-0.93)	2.8 vs. 1.4	0.57 (0.42-0.79)	23.5 vs. 1.3
Cheng et al. 2013 <sup>77</sup>	III	Sunitinib (n=530) vs. sorafenib (n=544)	7.4 vs. 7.8	6.6 vs. 6.1	7.9 vs. 10.2	1.30 (1.13-1.50)	3.6 vs. 3.0	1.13 (0.99-1.30)	82.1 vs. 74.2
Johnson et al. 2013 (BRISK-FL) <sup>78</sup>	III	Brivanib (n=577) vs. sorafenib (n=578)	-	12.0 vs. 8.8	9.5 vs. 9.9	1.06 (0.93-1.22)	4.2 vs. 4.1	1.01 (0.88-1.16)	11.7 vs. 11.3
Cainap et al. 2015 <sup>79</sup>	III	Linifanib (n=514) vs. sorafenib (n=521)	-	13.0 vs. 6.9	9.1 vs. 9.8	1.05 (0.90-1.22)	5.4 vs. 4.0	0.76 (0.64-0.90)	85.3 vs. 75.0
Zhu et al. 2015 (SEARCH) <sup>80</sup>	III	Sorafenib plus erlotinib (n=362) vs. sorafenib plus placebo (n=358)	-	6.6 vs. 3.9	9.5 vs. 8.5	0.93 (0.78-1.10)	3.2 vs. 4.0	1.14 (0.94-1.37)	87.0 vs. 83.9
Qin et al. 2013 (FOLFOX4) <sup>81</sup>	III	FOLFOX4 (n=184) vs. doxorubicin (n=187)	-	8.2 vs. 2.7	6.4 vs. 5.0	0.69 (0.50-0.94)	2.9 vs. 1.8	0.62 (0.49-0.79)	37.5 vs. 49.7
El-Khoueiry et al. 2017 (CheckMate 040) <sup>84</sup>	I/II	Nivolumab dose-expansion (n=214) vs. dose-escalation phase (n=48)	-	19.6 vs. 14.6	Not reached vs. 15	-	4.0 vs. 3.4	-	18.7 vs. 25.0
Kudo et al. 2018 (REFLECT) <sup>82</sup>	III	Lenvatinib (n=478) vs. sorafenib (n=476)	27.7 vs. 27.2	18.8 vs. 6.5	13.6 vs. 12.3	0.92 (0.79-1.06)	7.4 vs. 3.7	0.66 (0.57-0.77)	56.7 vs. 48.6
Yau et al. 2019 (CheckMate 459) <sup>85</sup>	III	Nivolumab (n=371) vs. sorafenib (n=372)	22.8	15.4 vs. 7.0	16.4 vs. 14.7	0.85 (0.72-1.02)	3.7 vs. 3.8	-	21.8 vs. 48.1
Qin et al. 2021 (ZGDH3) <sup>83</sup>	II/III	Donafenib (n=334) vs. sorafenib (n=334)	-	4.6 vs. 2.7 <sup>b</sup>	12.1 vs. 10.3	0.83 (0.70-0.99)	3.7 vs. 3.6	-	37.5 vs. 49.7
Finn et al. 2020 (KEYNOTE 524) <sup>86</sup>	Ib	Lenvatinib plus pembrolizumab (n=100)	10.6	36.0	22.0	-	9.3	-	67
Lee et al. 2020 (GO30140) <sup>88</sup>	Ib	Atezolizumab plus bevacizumab (n=104) vs. atezolizumab plus bevacizumab (n=60) vs. atezolizumab (n=59)	12.4 vs. 6.6 vs. 6.7	32.7 vs. 13.3 vs. 8.5	17.1 vs. not reached vs. not reached	-	7.4 vs. 5.7 vs. 2.0	-	52.9 vs. 36.7 vs. 13.6
Finn et al. 2020 (Imbrave 150) <sup>87</sup>	III	Atezolizumab plus bevacizumab (n=336) vs. sorafenib (n=165)	15.6	27.3 vs. 11.9	19.2 vs. 13.4	0.66 (0.54-0.85)	6.8 vs. 4.3	0.59 (0.47-0.76)	56.5 vs. 55.1
Xu et al. 2021 (RESCUE) <sup>89</sup>	II	Camrelizumab plus apatinib (n=70)	16.7	34.3	Not reached	-	5.7	-	78.6

(continued)

Table 3. (continued)

Trials	Phase	Experimental arms	Follow-up duration, months	ORR according to RECIST 1.1, %	Median survival time, months	HR (95%CI) of OS	Median PFS time, months <sup>a</sup>	HR (95%CI) of PFS	Treatment-related adverse events of grade ≥3, %
Second-line									
Zhu et al. 2015 (REACH) <sup>93</sup>	III	Ramucirumab (n=283) vs. placebo (n=282)	8.3 vs. 7.0	7.1 vs. 0.7	9.2 vs. 7.6	0.87 (0.72-1.05)	2.8 vs. 2.1	0.63 (0.52-0.75)	35.3 vs. 28.0
Bruix et al. 2017 (RESORECE) <sup>90</sup>	III	Regorafenib (n=379) vs. placebo (n=194)	7.0	6.6 vs. 2.6	10.6 vs. 7.8	0.63 (0.50-0.79)	3.4 vs. 1.5	0.43 (0.35-0.52)	66.3 vs. 38.3
Kudo et al. 2017 (S-CUBE) <sup>97</sup>	III	S-1 (n=222) vs. placebo (n=111)	32.4 vs. 32.9	5.4 vs. 0.9	11.1 vs. 11.2	0.86 (0.67-1.10)	2.6 vs. 1.4	0.60 (0.46-0.77)	40.5 vs. 21.6
Abou-Alfa et al. 2018 <sup>91</sup>	III	Cabozantinib (n=470) vs. placebo (n=237)	-	3.8 vs. 0.4	10.2 vs. 8.0	0.76 (0.63-0.92)	5.2 vs. 1.9	0.44 (0.36-0.52)	67.7 vs. 36.3
Zhu et al. 2018 (KEYNOTE224) <sup>95</sup>	II	Pembrolizumab (n=104)	12.3	17.3	12.9	-	4.9	-	24.0
Zhu et al. 2019 (REACH-2) <sup>92</sup>	III	Ramucirumab (n=197) vs. placebo (n=95)	7.6	4.6 vs. 1.1	8.5 vs. 7.3	0.71 (0.53-0.95)	2.8 vs. 1.6	0.45 (0.34-0.60)	34.5 vs. 29.5
Finn et al. 2020 (KEYNOTE 240) <sup>94</sup>	III	Pembrolizumab (n=278) vs. placebo (n=135)	13.8 vs. 10.6	18.3 vs. 4.4	13.9 vs. 10.6	0.78 (0.61-0.99)	3.0 vs. 2.8	0.72 (0.57-0.90)	52.7 vs. 46.3
Yau et al. 2020 (CheckMate 040) <sup>96</sup>	I/II	Nivolumab plus ipilimumab (arm A, n=50; arm B, n=49; arm C, n=49)	30.7	32.0 vs. 26.5 vs. 28.6	22.8 vs. 12.5 vs. 12.7	-	-	-	53.1 vs. 28.6 vs. 31.3
Qin et al. 2021 (AHELP) <sup>98</sup>	III	Apatinib (n=261) vs. placebo (n=132)	7.6	10.7 vs. 1.5	8.7 vs. 6.8	0.79 (0.62-0.99)	4.5 vs. 1.9	0.47 (0.37-0.60)	76.2 vs. 18.9
Xu et al. 2021 (RESCUE) <sup>89</sup>	II	Camrelizumab plus apatinib (n=120)	14.0	22.5	Not reached	-	5.5	-	76.7

<sup>a</sup>The level of response was measured according to modified RECIST 1.1. <sup>b</sup>The method of response was not reported. CI, confidence interval; HCC, hepatocellular carcinoma; HR, hazard ratio; OS, overall survival; PFS, progression-free survival.



**Fig. 2. Percentages of ORRs and adverse events of at least grade 3 in clinical trials of systematic therapy for advanced or unresectable HCC.** (A) First-line therapy. (B) Second-line therapy. The level of response was measured according to RECIST 1.1. The total sample size equals the sum of the sample sizes for each trial. Percentages were obtained by the number of cases (ORR or adverse events of grade ≥3) in each trial divided by the total sample size of trials. \*For patients with  $\alpha$ -fetoprotein concentrations of at least 400 ng/mL. Ate, atezolizumab; Bev, bevacizumab; Cam, camrelizumab; Dox, doxorubicin; FOLFOX4, intravenously infusional fluorouracil, leucovorin, and oxaliplatin; Pem, pembrolizumab.

of pembrolizumab and placebo for patients with advanced HCC previously treated with sorafenib. Although pembrolizumab prolonged median overall survival time (13.9 vs. 10.6 months,  $p=0.024$ ) and median progression-free survival time (3.0 vs. 2.8 months,  $p=0.002$ ), overall and progression-free survival did not reach statistical significance per specified criteria, which are consistent with the findings of KEYNOTE-224.<sup>95</sup> Another Checkmate 040 study<sup>96</sup> (phase I/II) included 148 HCC patients who had sorafenib resistance. In a ratio of 1:1:1, patients were randomly divided into three groups to explore the prognostic impact of different dose regimens of nivolumab combined with ipilimumab. The study found that patients who received "nivolumab 1 mg/kg plus ipilimumab 3 mg/kg (every 3 weeks) for four cycles, followed by nivolumab 240 mg (every 2 weeks)" had the best survival time (22.8 months) and highest ORR (32.0%). The chemotherapy drug fluoropyrimidine (S-1) was also investigated as second-line therapy in patients with sorafenib-refractory advanced HCC. However, S-1 did not prolong overall survival compared with placebo.<sup>97</sup> The efficacy and safety of apatinib with<sup>89</sup> ( $n=120$ ) or without<sup>98</sup> camrelizumab ( $n=261$ ) as second-line therapy were also reported from China. The corresponding ORRs were 22.5% and 10.7%, respectively, and the incidence rates of adverse events of at least grade 3 were 76.7% and 76.2%, respectively (Fig. 2B). And last, some

studies also demonstrated that metronomic capecitabine may be an efficient and safe second-line systemic therapy after sorafenib failure in patients with HCC.<sup>99,100</sup>

In conclusion, combination therapy with tyrosine kinase inhibitors and immune checkpoint inhibitors as first-line therapy provides the highest ORR (>30%), suggesting promise for patients with HCC involving PVTT. As second-line therapy, however, nivolumab plus ipilimumab or camrelizumab plus apatinib provides an acceptable ORR for such patients (>20%). However, when administered either as first- or second-line therapy, camrelizumab plus apatinib is associated with the highest incidence of adverse events of at least grade 3 (Fig. 2). The sample size of the underlying supporting trials should be taken into account when recommending their corresponding study findings. Therefore, the ASCO guideline on systemic therapy for advanced HCC<sup>101</sup> stated that atezolizumab plus bevacizumab, sorafenib, or lenvatinib may be offered as first-line treatment for most patients with advanced HCC; following first-line therapy with sorafenib or lenvatinib, second-line therapy options include cabozantinib, regorafenib or ramucirumab (for patients with  $\alpha$ -fetoprotein  $\geq 400$  ng/mL), and pembrolizumab or nivolumab. Until now, no clinical trial or cohort study investigating systematic therapy for different classification of PVTT has been reported.



## Future directions

Due to the large differences in the incidence of HCC, the different pathogenic factors of HCC, and the differences in the culture and economic living standards of the population in eastern and western countries, the recommended treatment opinions of HCC official guidelines in eastern and western countries are also not consistent. Different guidelines offer treatment recommendations based on different classification systems and points of view. In addition, future studies are expected to continue to explore markers that predict efficacy. Finally, due to the great influence of different PVTT classification on the prognosis of patients with HCC, further exploration on PVTT classification is expected in future clinical trials related to multiple kinase inhibitors and immune checkpoint inhibitors.

Many patients with HCC involving PVTT have a long-term survival benefit from the most traditional treatment, such as hepatic resection, but with high rate of postoperative recurrence. It is necessary to combine neoadjuvant or adjuvant therapy to reduce recurrence rate and ultimately improve overall survival. Adjuvant targeted agents plus immune checkpoint inhibitors after surgery may be a therapeutic direction in the future.<sup>48</sup> Three-dimensional conformal radiotherapy, proton radiotherapy and stereotactic radiotherapy have definite efficacy in controlling PVTT. In addition, radiotherapy acts as a strong modulator of the tumor immune microenvironment. Radiotherapy combined with immune checkpoint inhibitors augments the tumoricidal effect by upregulating the major histocompatibility complex and increasing susceptibility to T-cell-mediated cell death.<sup>102</sup> Radiotherapy combined with other treatment measures to control primary lesions and improve the survival time of patients is important. Although the efficacy of monotherapy with a multi-kinase inhibitor or immune checkpoint inhibitor is unsatisfactory for patients with advanced HCC, "T+A" treatment is brilliant. With the diversification of therapeutic drugs and regimens, more emphasis should be placed on multidisciplinary treatment in clinical practice, and the comprehensive treatment concept of local treatment plus systematic treatment should be strengthened. It is believed that the survival period of patients with HCC, including those complicated with PVTT, will be greatly prolonged in the future. Finally, some conventional drugs in new use, such as heparins, may also be useful for patients with HCC and PVTT.<sup>103</sup>

## Conclusions

Hepatic resection is the most effective therapy for selected patients with HCC and PVTT, while radiotherapy, TACE, HAIC, multi-kinase inhibitors, and immune checkpoint inhibitors are also used to prolong progression-free survival so as to improve overall survival for such patients. At present, more and more clinical trials on immune checkpoint inhibitors, chimeric antigen receptor T-cell, etc., are under development or scheduled to be carried out in the near future, throughout various countries and regions around the world.<sup>104</sup> However, in clinical practice, both clinicians and patients need to rationally consider the indications of these drugs or regimens, the occurrence of fatal adverse events, and the optimal fit for the population.

## Funding

This review was in part supported by the National Natural Science Foundation of China (No. 82060510), the 'Guangxi BaGui Scholars' Special Fund (No. 2019AQ20), the Guangxi

Natural Science Foundation (Nos. 2018GXNSFBA138018, 2020GXNSFAA159022, and 2018GXNSFAA050124), and the Guangxi Undergraduate Training Program for Innovation and Entrepreneurship (Nos. 202110598178 and 202110598073).

## Conflict of interest

JHZ has been an editorial board member of *Journal of Clinical and Translational Hepatology* since 2021. The other authors have no conflict of interests related to this publication.

## Author contributions

Conception and design of the study (JHZ), acquisition, analysis, or interpretation of data (JHZ, ZJD, YXT, LL, YQZ, YXZ, HTL, JLH, ZXL, LM), drafting of the manuscript (JHZ, ZJD, YXT, LL, YQZ, YXZ, HTL, JLH, ZXL, LM), critical revision of the manuscript for important intellectual content (JHZ), statistical analysis (JHZ, JLH, ZXL, ZJD), obtained funding (JHZ, LM), administrative, technical, or material support (LM), supervision (JHZ, LM). In addition, all authors participated in the data analysis and reading and approval of the final version to be published. JHZ had full access to all of the data in the study and serves as guarantor, taking full responsibility for the integrity of the data and the accuracy of the data analysis.

## Data sharing statement

All data are presented in the manuscript and no additional data are available.

## References

- [1] Sung H, Ferlay J, Siegel RL, Laversanne M, Soerjomataram I, Jemal A, *et al*. Global cancer statistics 2020: GLOBOCAN estimates of incidence and mortality worldwide for 36 cancers in 185 countries. *CA Cancer J Clin* 2021; 71(3):209–249. doi:10.3322/caac.21660.
- [2] Zhong JH, Peng NF, You XM, Ma L, Xiang X, Wang YY, *et al*. Tumor stage and primary treatment of hepatocellular carcinoma at a large tertiary hospital in China: a real-world study. *Oncotarget* 2017;8(11):18296–18302. doi:10.18632/oncotarget.15433.
- [3] Chan SL, Chong CC, Chan AW, Poon DM, Chok KS. Management of hepatocellular carcinoma with portal vein tumor thrombosis: review and update at 2016. *World J Gastroenterol* 2016;22(32):7289–7300. doi:10.3748/wjg.v22.i32.7289.
- [4] Xiang X, Lau WY, Wu ZY, Zhao C, Ma YL, Xiang BD, *et al*. Transarterial chemoembolization versus best supportive care for patients with hepatocellular carcinoma with portal vein tumor thrombus multicenter study. *Eur J Surg Oncol* 2019;45(8):1460–1467. doi:10.1016/j.ejso.2019.03.042.
- [5] European Association for the Study of the Liver. EASL clinical practice guidelines: management of hepatocellular carcinoma. *J Hepatol* 2018; 69(1):182–236. doi:10.1016/j.jhep.2018.03.019.
- [6] Heimbach JK, Kulik LM, Finn RS, Sirlin CB, Abecassis MM, Roberts LR, *et al*. AASLD guidelines for the treatment of hepatocellular carcinoma. *Hepatology* 2018;67(1):358–380. doi:10.1002/hep.29086.
- [7] Vogel A, Cervantes A, Chau I, Daniele B, Llovet JM, Meyer T, *et al*. Hepatocellular carcinoma: ESMO clinical practice guidelines for diagnosis, treatment and follow-up. *Ann Oncol* 2019;30(5):871–873. doi:10.1093/annonc/mdy510.
- [8] Chen LT, Martinelli E, Cheng AL, Pentheroudakis G, Qin S, Bhattacharyya GS, *et al*. Pan-Asian adapted ESMO Clinical Practice Guidelines for the management of patients with intermediate and advanced/recurred hepatocellular carcinoma: a TOS-ESMO initiative endorsed by CSCO, ISMPO, JSMO, KSMO, MOS and SSO. *Ann Oncol* 2020;31(3):334–351. doi:10.1016/j.annonc.2019.12.001.
- [9] Park YH, Senkus-Konefka E, Im SA, Pentheroudakis G, Saji S, Gupta S, *et al*. Pan-Asian adapted ESMO Clinical Practice Guidelines for the management of patients with early breast cancer: a KSMO-ESMO initiative endorsed by CSCO, ISMPO, JSMO, MOS, SSO and TOS. *Ann Oncol* 2020; 31(4):451–469. doi:10.1016/j.annonc.2020.01.008.
- [10] Omata M, Cheng AL, Kokudo N, Kudo M, Lee JM, Jia J, *et al*. Asia-Pacific clinical practice guidelines on the management of hepatocellular carcinoma: a 2017 update. *Hepatology* 2017;11(4):317–370. doi:10.1007/s12072-017-9799-9.

- [11] Korean Liver Cancer Association; National Cancer Center. 2018 Korean Liver Cancer Association-National Cancer Center Practice Guidelines for the Management of hepatocellular carcinoma. *Gut Liver* 2019;13(3):227-299. doi:10.5009/gnl19024.
- [12] Shao YY, Wang SY, Lin SM, Diagnosis G, Systemic Therapy G. Management consensus guideline for hepatocellular carcinoma: 2020 update on surveillance, diagnosis, and systemic treatment by the Taiwan Liver Cancer Association and the Gastroenterological Society of Taiwan. *J Formos Med Assoc* 2021;120(4):1051-1060. doi:10.1016/j.jfma.2020.10.031.
- [13] Zhou J, Sun H, Wang Z, Cong W, Wang J, Zeng M, et al. Guidelines for the diagnosis and treatment of hepatocellular carcinoma (2019 Edition). *Liver Cancer* 2020;9(6):682-720. doi:10.1159/000509424.
- [14] Jiang JF, Lao YC, Yuan BH, Yin J, Liu X, Chen L, et al. Treatment of hepatocellular carcinoma with portal vein tumor thrombus: advances and challenges. *Oncotarget* 2017;8(20):33911-33921. doi:10.18632/oncotarget.15411.
- [15] Llovet JM, De Baere T, Kulik L, Haber PK, Gretten TF, Meyer T, et al. Locoregional therapies in the era of molecular and immune treatments for hepatocellular carcinoma. *Nat Rev Gastroenterol Hepatol* 2021;18(5):293-313. doi:10.1038/s41575-020-00395-0.
- [16] Tovoli F, Negrini G, Benevento F, Faggiano C, Goio E, Granito A. Systemic treatments for hepatocellular carcinoma: challenges and future perspectives. *Hepat Oncol* 2018;5(1):HEP01. doi:10.2217/hep-2017-0020.
- [17] Yin J, Bo WT, Sun J, Xiang X, Lang JY, Zhong JH, et al. New evidence and perspectives on the management of hepatocellular carcinoma with portal vein tumor thrombus. *J Clin Transl Hepatol* 2017;5(2):169-176. doi:10.14218/JCTH.2016.00071.
- [18] Yau T, Tang VY, Yao TJ, Fan ST, Lo CM, Poon RT. Development of Hong Kong Liver Cancer staging system with treatment stratification for patients with hepatocellular carcinoma. *Gastroenterology* 2014;146(7):1691-1700. doi:10.1053/j.gastro.2014.02.032.
- [19] Farihati F, Vitale A, Spolverato G, Pawlik TM, Huo TL, Lee YH, et al. Development and validation of a new prognostic system for patients with hepatocellular carcinoma. *PLoS Med* 2016;13(4):e1002006. doi:10.1371/journal.pmed.1002006.
- [20] Kudo M, Izumi N, Ichida T, Ku Y, Kokudo N, Sakamoto M, et al. Report of the 19th follow-up survey of primary liver cancer in Japan. *Hepatol Res* 2016;46(5):372-390. doi:10.1111/hepr.12697.
- [21] Bruix J, Gores GJ, Mazzaferro V. Hepatocellular carcinoma: clinical frontiers and perspectives. *Gut* 2014;63(5):844-855. doi:10.1136/gutjnl-2013-306627.
- [22] Kudo M, Chung H, Osaki Y. Prognostic staging system for hepatocellular carcinoma (CLIP score): its value and limitations, and a proposal for a new staging system, the Japan Integrated Staging Score (JIS score). *J Gastroenterol* 2003;38(3):207-215. doi:10.1007/s005350300038.
- [23] Kokudo N, Takemura N, Hasegawa K, Takayama T, Kubo S, Shimada M, et al. Clinical practice guidelines for hepatocellular carcinoma: the Japan Society of Hepatology 2017 (4th JSH-HCC guidelines) 2019 update. *Hepatol Res* 2019;49(10):1109-1113. doi:10.1111/hepr.13411.
- [24] Kumar A, Acharya SK, Singh SP, Arora A, Dhiman RK, Aggarwal R, et al. 2019 update of Indian National Association for Study of the Liver Consensus on prevention, diagnosis, and management of hepatocellular carcinoma in India: the Puri II recommendations. *J Clin Exp Hepatol* 2020;10(1):43-80. doi:10.1016/j.jceh.2019.09.007.
- [25] Liver Cancer Study Group of Japan. The general rules for the clinical and pathological study of primary liver cancer, 2nd ed, Kanehara Shuppan, Tokyo. 1987 (In Japanese).
- [26] Liver Cancer Study Group of Japan. The general rules for the clinical and pathological study of primary liver cancer, second english edition, Kanehara & Co., Ltd., Tokyo. 2003.
- [27] Shuqun C, Mengchao W, Han C, Feng S, Jiahe Y, Guanghui D, et al. Tumor thrombus types influence the prognosis of hepatocellular carcinoma with the tumor thrombi in the portal vein. *Hepatogastroenterology* 2007;54(74):499-502.
- [28] Shi J, Lai EC, Li N, Guo WX, Xue J, Lau WY, et al. A new classification for hepatocellular carcinoma with portal vein tumor thrombus. *J Hepatobiliary Pancreat Sci* 2011;18(1):74-80. doi:10.1007/s00534-010-0314-0.
- [29] Cheng S, Chen M, Cai J. National Research Cooperative Group for diagnosis and treatment of hepatocellular carcinoma with tumor thrombus. Chinese expert consensus on multidisciplinary diagnosis and treatment of hepatocellular carcinoma with portal vein tumor thrombus: 2016 edition. *Oncotarget* 2017;8(5):8867-8876. doi:10.18632/oncotarget.12817.
- [30] Bruix J, Reig M, Sherman M. Evidence-based diagnosis, staging, and treatment of patients with hepatocellular carcinoma. *Gastroenterology* 2016;150(4):835-853. doi:10.1053/j.gastro.2015.12.041.
- [31] Llovet JM, Kelley RK, Villanueva A, Singal AG, Pikarsky E, Roayaie S, et al. Hepatocellular carcinoma. *Nat Rev Dis Primers* 2021;7(1):6. doi:10.1038/s41572-020-00240-3.
- [32] Torzilli G, Belghiti J, Kokudo N, Takayama T, Capussotti L, Nuzzo G, et al. A snapshot of the effective indications and results of surgery for hepatocellular carcinoma in tertiary referral centers: is it adherent to the EASL/AASLD recommendations?: an observational study of the HCC East-West study group. *Ann Surg* 2013;257(5):929-937. doi:10.1097/SLA.0b013e31828329b8.
- [33] Bruix J, Fuster J. A snapshot of the effective indications and results of surgery for hepatocellular carcinoma in tertiary referral centers: is it adherent to the EASL/AASLD recommendations? an observational study of the HCC east-west study group. *Ann Surg* 2015;262(1):e30. doi:10.1097/SLA.0000000000000381.
- [34] Romagnoli R, Mazzaferro V, Bruix J. Surgical resection for hepatocellular carcinoma: moving from what can be done to what is worth doing. *Hepatology* 2015;62(2):340-342. doi:10.1002/hep.27831.
- [35] Mazzaferro V, Roayaie S, Poon R, Majno PE. Dissecting EASL/AASLD recommendations with a more careful knife: a comment on "surgical misinterpretation" of the BCLC staging system. *Ann Surg* 2015;262(1):e17-18. doi:10.1097/SLA.0000000000000398.
- [36] Yang T, Lau WY, Zhang H, Huang B, Lu JH, Wu MC. Grey zone in the Barcelona Clinic Liver Cancer Classification for hepatocellular carcinoma: surgeons' perspective. *World J Gastroenterol* 2015;21(27):8256-8261. doi:10.3748/wjg.v21.i27.8256.
- [37] Yang T, Lau WY, Zhang H, Wu MC, Shen F. Hepatic surgeons are like the child who rescued dying fishes. *Hepatology* 2016;63(3):1054. doi:10.1002/hep.27980.
- [38] Zhong JH, Xiang BD. Controversies of hepatectomy and adjuvant therapy for hepatocellular carcinoma: moving forward. *Hepatoma Res* 2019;5:18. doi:10.20517/2394-5079.2019.01.
- [39] Zhong JH, Ke Y, Gong WF, Xiang BD, Ma L, Ye XP, et al. Hepatic resection associated with good survival for selected patients with intermediate and advanced-stage hepatocellular carcinoma. *Ann Surg* 2014;260(2):329-340. doi:10.1097/SLA.0000000000000236.
- [40] Zhong JH, Ma L, Xiang BD, Li LQ, Yang T. We're still in an update process of the BCLC system. *Ann Surg* 2018;267(2):e23-e24. doi:10.1097/SLA.0000000000001922.
- [41] Zhong JH, Torzilli G, Xing H, Li C, Han J, Liang L, et al. Controversies and evidence of hepatic resection for hepatocellular carcinoma. *BBA Clin* 2016;6:125-130. doi:10.1016/j.bbaci.2016.10.001.
- [42] Zhong JH, Rodriguez AC, Ke Y, Wang YY, Wang L, Li LQ. Hepatic resection as a safe and effective treatment for hepatocellular carcinoma involving a single large tumor, multiple tumors, or macrovascular invasion. *Medicine (Baltimore)* 2015;94(3):e396. doi:10.1097/MD.0000000000000396.
- [43] Kokudo T, Hasegawa K, Matsuyama Y, Takayama T, Izumi N, Kadoya M, et al. Survival benefit of liver resection for hepatocellular carcinoma associated with portal vein invasion. *J Hepatol* 2016;65(5):938-943. doi:10.1016/j.jhep.2016.05.044.
- [44] Zhang XP, Gao YZ, Chen ZH, Chen MS, Li LQ, Wen TF, et al. An eastern hepatobiliary surgery hospital/portal vein tumor thrombus scoring system as an aid to decision making on hepatectomy for hepatocellular carcinoma patients with portal vein tumor thrombus: a multicenter study. *Hepatology* 2019;69(5):2076-2090. doi:10.1002/hep.30490.
- [45] Zhong JH, Li H, Li LQ, You XM, Zhang Y, Zhao YN, et al. Adjuvant therapy options following curative treatment of hepatocellular carcinoma: a systematic review of randomized trials. *Eur J Surg Oncol* 2012;38(4):286-295. doi:10.1016/j.ejso.2012.01.006.
- [46] Zhong JH, Li LQ. Postoperative adjuvant transarterial chemoembolization for participants with hepatocellular carcinoma: a meta-analysis. *Hepatol Res* 2010;40(10):943-953. doi:10.1111/j.1872-034X.2010.00710.x.
- [47] Liang L, Li C, Diao YK, Jia HD, Xing H, Pawlik TM, et al. Survival benefits from adjuvant transcatheter arterial chemoembolization in patients undergoing liver resection for hepatocellular carcinoma: a systematic review and meta-analysis. *Therap Adv Gastroenterol* 2020;13:1756284820977693. doi:10.1177/1756284820977693.
- [48] Hack SP, Spahn J, Chen M, Cheng AL, Kaseb A, Kudo M, et al. Imbrave 050: a Phase III trial of atezolizumab plus bevacizumab in high-risk hepatocellular carcinoma after curative resection or ablation. *Future Oncol* 2020;16(15):975-989. doi:10.2217/fon-2020-0162.
- [49] Chen SC, Lian SL, Chang WY. The effect of external radiotherapy in treatment of portal vein invasion in hepatocellular carcinoma. *Cancer Chemother Pharmacol* 1994;33(Suppl):S124-S127. doi:10.1007/BF00686683.
- [50] Rim CH, Kim CY, Yang DS, Yoon WS. Comparison of radiation therapy modalities for hepatocellular carcinoma with portal vein thrombosis: A meta-analysis and systematic review. *Radiother Oncol* 2018;129(1):112-122. doi:10.1016/j.radonc.2017.11.013.
- [51] Li LQ, Zhou Y, Huang Y, Liang P, Liang SX, Su TS. Stereotactic body radiotherapy versus intensity-modulated radiotherapy for hepatocellular carcinoma with portal vein tumor thrombosis. *Hepatol Int* 2021;15(3):630-641. doi:10.1007/s12072-021-10173-y.
- [52] Su F, Chen KH, Liang ZG, Wu CH, Li L, Qu S, et al. Comparison of three-dimensional conformal radiotherapy and hepatic resection in hepatocellular carcinoma with portal vein tumor thrombus. *Cancer Med* 2018;7(9):4387-4395. doi:10.1002/cam4.1708.
- [53] Wang K, Guo WX, Chen MS, Mao YL, Sun BC, Shi J, et al. Multimodality treatment for hepatocellular carcinoma with portal vein tumor thrombus: a large-scale, multicenter, propensity matching score analysis. *Medicine (Baltimore)* 2016;95(11):e3015. doi:10.1097/MD.00000000000003015.
- [54] Yoon SM, Ryoo BY, Lee SJ, Kim JH, Shin JH, An JH, et al. Efficacy and safety of transarterial chemoembolization plus external beam radiotherapy vs sorafenib in hepatocellular carcinoma with macroscopic vascular invasion: a randomized clinical trial. *JAMA Oncol* 2018;4(5):661-669. doi:10.1001/jamaoncol.2017.5847.
- [55] Vilgrain V, Pereira H, Assenat E, Guiu B, Ilonca AD, Pageaux GP, et al. Efficacy and safety of selective internal radiotherapy with yttrium-90 resin microspheres compared with sorafenib in locally advanced and inoperable hepatocellular carcinoma (SARAH): an open-label randomised controlled phase 3 trial. *Lancet Oncol* 2017;18(12):1624-1636. doi:10.1016/S1473-2045(17)30683-6.
- [56] Gramezzi A, Golfieri R, Mosconi C, Cappelli A, Granito A, Cucchetti A, et al. Yttrium-90 radioembolization vs sorafenib for intermediate-locally advanced hepatocellular carcinoma: a cohort study with propensity score analysis. *Liver Int* 2015;35(3):1036-1047. doi:10.1111/liv.12574.
- [57] Spreafico C, Sposito C, Vaiani M, Cascella T, Bhoori S, Morosi C, et al. Evaluation of a prognostic score to predict response to Yttrium-90 radioembolization for hepatocellular carcinoma with portal vein invasion. *J Hepatol* 2018;68(4):724-732. doi:10.1016/j.jhep.2017.12.026.

- [58] Jia Z, Jiang G, Tian F, Zhu C, Qin X. A systematic review on the safety and effectiveness of yttrium-90 radioembolization for hepatocellular carcinoma with portal vein tumor thrombosis. *Saudi J Gastroenterol* 2016;22(5):353-359. doi:10.4103/1319-3767.191139.
- [59] Wei X, Jiang Y, Zhang X, Feng S, Zhou B, Ye X, *et al*. Neoadjuvant three-dimensional conformal radiotherapy for resectable hepatocellular carcinoma with portal vein tumor thrombus: a randomized, open-label, multicenter controlled study. *J Clin Oncol* 2019;37(24):2141-2151. doi:10.1200/JCO.2018.02184.
- [60] Kim TH, Koh YH, Kim BH, Kim MJ, Lee JH, Park B, *et al*. Proton beam radiotherapy vs. radiofrequency ablation for recurrent hepatocellular carcinoma: a randomized phase III trial. *J Hepatol* 2021;74(3):603-612. doi:10.1016/j.jhep.2020.09.026.
- [61] Wang L, Ke Q, Huang Q, Shao L, Chen J, Wu J. Stereotactic body radiotherapy versus radiofrequency ablation for hepatocellular carcinoma: a systematic review and meta-analysis. *Int J Hyperthermia* 2020;37(1):1313-1321. doi:10.1080/02656736.2020.1843719.
- [62] Ajit Y, Sudarsan H, Saumya G, Abhishek A, Navneet R, Piyush R, *et al*. Transarterial chemoembolization in unresectable hepatocellular carcinoma with portal vein thrombosis: a perspective on survival. *Oman Med J* 2014;29(6):430-436. doi:10.5001/omj.2014.114.
- [63] Chern MC, Chuang VP, Liang CT, Lin ZH, Kuo TM. Transcatheter arterial chemoembolization for advanced hepatocellular carcinoma with portal vein invasion: safety, efficacy, and prognostic factors. *J Vasc Interv Radiol* 2014;25(1):32-40. doi:10.1016/j.jvir.2013.10.013.
- [64] Choi JW, Kim HC, Lee JH, Yu SJ, Kim YJ, Yoon JH, *et al*. Transarterial chemoembolization of hepatocellular carcinoma with segmental portal vein tumor thrombus. *Eur Radiol* 2016;27(4):1448-1458. doi:10.1007/s00330-016-4511-3.
- [65] Gorodetski B, Chapiro J, Scherthaner R, Duran R, Lin M, Lee H, *et al*. Advanced-stage hepatocellular carcinoma with portal vein thrombosis: conventional versus drug-eluting beads transcatheter arterial chemoembolization. *Eur Radiol* 2017;27(2):526-535. doi:10.1007/s00330-016-4445-9.
- [66] Lin CC, Hung CF, Chen WT, Lin SM. Hepatic arterial infusion chemotherapy for advanced hepatocellular carcinoma with portal vein thrombosis: impact of early response to 4 weeks of treatment. *Liver Cancer* 2015;4(4):228-240. doi:10.1159/000367737.
- [67] Liu PH, Lee YH, Hsia CY, Hsu CY, Huang YH, Chiou YY, *et al*. Surgical resection versus transarterial chemoembolization for hepatocellular carcinoma with portal vein tumor thrombosis: a propensity score analysis. *Ann Surg Oncol* 2014;21(6):1825-1833. doi:10.1245/s10434-014-3510-3.
- [68] Peng ZW, Guo RP, Zhang YJ, Lin XJ, Chen MS, Lau WY. Hepatic resection versus transcatheter arterial chemoembolization for the treatment of hepatocellular carcinoma with portal vein tumor thrombus. *Cancer* 2012;118(19):4725-4736. doi:10.1002/ncr.26561.
- [69] Song DS, Bae SH, Song MJ, Lee SW, Kim HY, Lee YJ, *et al*. Hepatic arterial infusion chemotherapy in hepatocellular carcinoma with portal vein tumor thrombosis. *World J Gastroenterol* 2013;19(29):4679-4688. doi:10.3748/wjg.v19.i29.4679.
- [70] Tawada A, Chiba T, Ooka Y, Kanogawa N, Motoyama T, Saito T, *et al*. Efficacy of transarterial chemoembolization targeting portal vein tumor thrombus in patients with hepatocellular carcinoma. *Anticancer Res* 2014;34(8):4231-4237.
- [71] Ye JZ, Zhang YQ, Ye HH, Bai T, Ma L, Xiang BD, *et al*. Appropriate treatment strategies improve survival of hepatocellular carcinoma patients with portal vein tumor thrombus. *World J Gastroenterol* 2014;20(45):17141-17147. doi:10.3748/wjg.v20.i45.17141.
- [72] Kudo M, Ueshima K, Ikeda M, Torimura T, Tanabe N, Aikata H, *et al*. Randomised, multicentre prospective trial of transarterial chemoembolisation (TACE) plus sorafenib as compared with TACE alone in patients with hepatocellular carcinoma: TACTICS trial. *Gut* 2020;69(8):1492-1501. doi:10.1136/gutjnl-2019-318934.
- [73] Choi GH, Shim JH, Kim MJ, Ryu MH, Ryoo BY, Kang YK, *et al*. Sorafenib alone versus sorafenib combined with transarterial chemoembolization for advanced-stage hepatocellular carcinoma: results of propensity score analyses. *Radiology* 2013;269(2):603-611. doi:10.1148/radiol.13130150.
- [74] He M, Li Q, Zou R, Shen J, Fang W, Tan G, *et al*. Sorafenib plus hepatic arterial infusion of oxaliplatin, fluorouracil, and leucovorin vs sorafenib alone for hepatocellular carcinoma with portal vein invasion: a randomized clinical trial. *JAMA Oncol* 2019;5(7):953-960. doi:10.1001/jamaoncol.2019.0250.
- [75] Llovet JM, Ricci S, Mazzaferro V, Hilgard P, Gane E, Blanc JF, *et al*. Sorafenib in advanced hepatocellular carcinoma. *N Engl J Med* 2008;359(4):378-390. doi:10.1056/NEJMoa0708857.
- [76] Cheng AL, Kang YK, Chen Z, Tsao CJ, Qin S, Kim JS, *et al*. Efficacy and safety of sorafenib in patients in the Asia-Pacific region with advanced hepatocellular carcinoma: a phase III randomised, double-blind, placebo-controlled trial. *Lancet Oncol* 2009;10(1):25-34. doi:10.1016/S1470-2045(08)70285-7.
- [77] Cheng AL, Kang YK, Lin DY, Park JW, Kudo M, Qin S, *et al*. Sunitinib versus sorafenib in advanced hepatocellular cancer: results of a randomized phase III trial. *J Clin Oncol* 2013;31(32):4067-4075. doi:10.1200/JCO.2012.45.8372.
- [78] Johnson PJ, Qin S, Park JW, Poon RT, Raoul JL, Philip PA, *et al*. Brivanib versus sorafenib as first-line therapy in patients with unresectable, advanced hepatocellular carcinoma: results from the randomized phase III BRISK-FL study. *J Clin Oncol* 2013;31(28):3517-3524. doi:10.1200/JCO.2012.48.4410.
- [79] Cainap C, Qin S, Huang WT, Chung JJ, Pan H, Cheng Y, *et al*. Linifanib versus Sorafenib in patients with advanced hepatocellular carcinoma: results of a randomized phase III trial. *J Clin Oncol* 2015;33(2):172-179. doi:10.1200/JCO.2013.54.3298.
- [80] Zhu AX, Rosmorduc O, Evans TR, Ross PJ, Santoro A, Carrillo FJ, *et al*. SEARCH: a phase III, randomized, double-blind, placebo-controlled trial of sorafenib plus erlotinib in patients with advanced hepatocellular carcinoma. *J Clin Oncol* 2015;33(6):559-566. doi:10.1200/JCO.2013.53.7746.
- [81] Qin S, Bai Y, Lim HY, Thongprasert S, Chao Y, Fan J, *et al*. Randomized, multicenter, open-label study of oxaliplatin plus fluorouracil/leucovorin versus doxorubicin as palliative chemotherapy in patients with advanced hepatocellular carcinoma from Asia. *J Clin Oncol* 2013;31(28):3501-3508. doi:10.1200/JCO.2012.44.5643.
- [82] Kudo M, Finn RS, Qin S, Han KH, Ikeda K, Piscaglia F, *et al*. Lenvatinib versus sorafenib in first-line treatment of patients with unresectable hepatocellular carcinoma: a randomised phase 3 non-inferiority trial. *Lancet* 2018;391(10126):1163-1173. doi:10.1016/S0140-6736(18)30207-1.
- [83] Qin S, Bi F, Gu S, Bai Y, Chen Z, Wang Z, *et al*. Donafenib versus sorafenib in first-line treatment of unresectable or metastatic hepatocellular carcinoma: a randomized, open-label, parallel-controlled phase II-III trial. *J Clin Oncol* 2021;JCO2100163. doi:10.1200/JCO.21.00163.
- [84] El-Khoueiry AB, Sangro B, Yau T, Crocenzi TS, Kudo M, Hsu C, *et al*. Nivolumab in patients with advanced hepatocellular carcinoma (CheckMate 040): an open-label, non-comparative, phase 1/2 dose escalation and expansion trial. *Lancet* 2017;389(10088):2492-2502. doi:10.1016/S0140-6736(17)31046-2.
- [85] Yau T, Park JW, Finn RS, Cheng AL, Mathurin P, Edeline J, *et al*. CheckMate 459: a randomized, multi-center phase III study of nivolumab (NIVO) vs sorafenib (SOR) as first-line (1L) treatment in patients (pts) with advanced hepatocellular carcinoma (aHCC). *Ann Oncol* 2019;30(Suppl 5):v874. doi:10.1093/annonc/mdz394.
- [86] Finn RS, Ikeda M, Zhu AX, Sung MW, Baron AD, Kudo M, *et al*. Phase Ib study of lenvatinib plus pembrolizumab in patients with unresectable hepatocellular carcinoma. *J Clin Oncol* 2020;38(26):2960-2970. doi:10.1200/JCO.20.00808.
- [87] Finn RS, Qin S, Ikeda M, Galle PR, Ducreux M, Kim TY, *et al*. Atezolizumab plus bevacizumab in unresectable hepatocellular carcinoma. *N Engl J Med* 2020;382(20):1894-1905. doi:10.1056/NEJMoa1915745.
- [88] Lee MS, Ryoo BY, Hsu CH, Numata K, Stein S, Verret W, *et al*. Atezolizumab with or without bevacizumab in unresectable hepatocellular carcinoma (GO30140): an open-label, multicentre, phase 1b study. *Lancet Oncol* 2020;21(6):808-820. doi:10.1016/S1470-2045(20)30156-X.
- [89] Xu J, Shen J, Gu S, Zhang Y, Wu L, Wu J, *et al*. Camrelizumab in combination with apatinib in patients with advanced hepatocellular carcinoma (RESCUE): a nonrandomized, open-label, phase II trial. *Clin Cancer Res* 2021;27(4):1003-1011. doi:10.1158/1078-0432.CCR-20-2571.
- [90] Bruix J, Qin S, Merle P, Granito A, Huang YH, Bodoky G, *et al*. Regorafenib for patients with hepatocellular carcinoma who progressed on sorafenib treatment (RESORCE): a randomised, double-blind, placebo-controlled, phase 3 trial. *Lancet* 2017;389(10064):56-66. doi:10.1016/S0140-6736(16)32453-9.
- [91] Abou-Alfa GK, Meyer T, Cheng AL, El-Khoueiry AB, Rimassa L, Ryoo BY, *et al*. Cabozantinib in patients with advanced hepatocellular carcinoma. *N Engl J Med* 2018;379(1):54-63. doi:10.1056/NEJMoa1717002.
- [92] Zhu AX, Kang YK, Yen CJ, Finn RS, Galle PR, Llovet JM, *et al*. Ramucirumab after sorafenib in patients with advanced hepatocellular carcinoma and increased alpha-fetoprotein concentrations (REACH-2): a randomised, double-blind, placebo-controlled, phase 3 trial. *Lancet Oncol* 2019;20(2):282-296. doi:10.1016/S1470-2045(18)30937-9.
- [93] Zhu AX, Park JO, Ryoo BY, Yen CJ, Poon R, Pastorelli D, *et al*. Ramucirumab versus placebo as second-line treatment in patients with advanced hepatocellular carcinoma following first-line therapy with sorafenib (REACH): a randomised, double-blind, multicentre, phase 3 trial. *Lancet Oncol* 2015;16(7):859-870. doi:10.1016/S1470-2045(15)00050-9.
- [94] Finn RS, Ryoo BY, Merle P, Kudo M, Bouattour M, Lim HY, *et al*. Pembrolizumab as second-line therapy in patients with advanced hepatocellular carcinoma in KEYNOTE-240: a randomized, double-blind, phase III trial. *J Clin Oncol* 2020;38(3):193-202. doi:10.1200/JCO.19.01307.
- [95] Zhu AX, Finn RS, Edeline J, Cattani S, Ogasawara S, Palmer D, *et al*. Pembrolizumab in patients with advanced hepatocellular carcinoma previously treated with sorafenib (KEYNOTE-224): a non-randomised, open-label phase 2 trial. *Lancet Oncol* 2018;19(7):940-952. doi:10.1016/S1470-2045(18)30351-6.
- [96] Yau T, Kang YK, Kim TY, El-Khoueiry AB, Santoro A, Sangro B, *et al*. Efficacy and safety of nivolumab plus ipilimumab in patients with advanced hepatocellular carcinoma previously treated with sorafenib: the CheckMate 040 randomized clinical trial. *JAMA Oncol* 2020;6(11):e204564. doi:10.1001/jamaoncol.2020.4564.
- [97] Kudo M, Moriguchi M, Numata K, Hidaka H, Tanaka H, Ikeda M, *et al*. S-1 versus placebo in patients with sorafenib-refractory advanced hepatocellular carcinoma (S-CUBE): a randomised, double-blind, multicentre, phase 3 trial. *Lancet Gastroenterol Hepatol* 2017;2(6):407-417. doi:10.1016/S2468-1253(17)30072-9.
- [98] Qin SK, Li Q, Gu SZ, Chen XM, Lin LZ, Wang ZS, *et al*. Apatinib as second-line or later therapy in patients with advanced hepatocellular carcinoma (AHELP): a multicentre, double-blind, randomised, placebo-controlled, phase 3 trial. *Lancet Gastroenterol Hepatol* 2021;6(7):559-568. doi:10.1016/S2468-1253(21)00109-6.
- [99] Trevisani F, Brandi G, Garuti F, Barbera MA, Tortora R, Casadei Gardini A, *et al*. Metronomic capecitabine as second-line treatment for hepatocellular carcinoma after sorafenib discontinuation. *J Cancer Res Clin Oncol* 2018;144(2):403-414. doi:10.1007/s00432-017-2556-6.
- [100] Granito A, Marinelli S, Terzi E, Piscaglia F, Renzulli M, Venerandi L, *et al*. Metronomic capecitabine as second-line treatment in hepatocellular carcinoma after sorafenib failure. *Dig Liver Dis* 2015;47(6):518-522.

doi:10.1016/j.dld.2015.03.010.

- [101] Gordan JD, Kennedy EB, Abou-Alfa GK, Beg MS, Brower ST, Gade TP, *et al*. Systemic therapy for advanced hepatocellular carcinoma: ASCO guideline. *J Clin Oncol* 2020;38(36):4317–4345. doi:10.1200/JCO.20.02672.
- [102] Chen LC, Lin HY, Hung SK, Chiou WY, Lee MS. Role of modern radiotherapy in managing patients with hepatocellular carcinoma. *World J Gastroenterol* 2021;27(20):2434–2457. doi:10.3748/wjg.v27.i20.2434.

- [103] Korhan P, Yilmaz Y, Bagirsakci E, Gunes A, Topel H, Carr BI, *et al*. Pleiotropic effects of heparins: from clinical applications to molecular mechanisms in hepatocellular carcinoma. *Can J Gastroenterol Hepatol* 2018; 2018:7568742. doi:10.1155/2018/7568742.
- [104] Li N, Huang HY, Wu DW, Yang ZM, Wang J, Wang JS, *et al*. Changes in clinical trials of cancer drugs in mainland China over the decade 2009–18: a systematic review. *Lancet Oncol* 2019;20(11):e619–e626. doi:10.1016/