

REVIEW



The Myth of Prometheus in metastatic meningioma to the liver: from craniotomy to hepatectomy

CLAUDIA FLORIDA COSTEA¹⁾, ANDREI IONUȚ CUCU^{2,3)}, CAMELIA MARGARETA BOGDĂNICI¹⁾, DRAGOȘ VIOREL SCRIPCARIU⁴⁾, GABRIELA FLORENȚA DUMITRESCU³⁾, ANCA SAVA^{3,5)}, CRISTINA MIHAELA GHICIUC⁶⁾, DANIELA MARIA TĂNASE⁷⁾, MIHAELA DANA TURLIUC^{3,8)}, SIMONA DELIA NICOARĂ⁹⁾, SPERANȚA SCHMITZER¹⁰⁾, MANUELA CIOCOIU¹¹⁾, RALUCA ALINA DRAGOMIR¹²⁾, ȘERBAN TURLIUC¹³⁾

¹⁾Department of Ophthalmology, Faculty of Medicine, Grigore T. Popa University of Medicine and Pharmacy, Iași, Romania

²⁾Faculty of Medicine and Biological Sciences, Ștefan cel Mare University of Suceava, Romania

³⁾Prof. Dr. Nicolae Oblu Emergency Clinical Hospital, Iași, Romania

⁴⁾Department of General Surgery, Faculty of Medicine, Grigore T. Popa University of Medicine and Pharmacy, Iași, Romania

⁵⁾Department of Anatomy, Faculty of Medicine, Grigore T. Popa University of Medicine and Pharmacy, Iași, Romania

⁶⁾Department of Pharmacology, Faculty of Medicine, Grigore T. Popa University of Medicine and Pharmacy, Iași, Romania

⁷⁾Department of Internal Medicine, Faculty of Medicine, Grigore T. Popa University of Medicine and Pharmacy, Iași, Romania

⁸⁾Department of Neurosurgery, Faculty of Medicine, Grigore T. Popa University of Medicine and Pharmacy, Iași, Romania

⁹⁾Department of Ophthalmology, Faculty of Medicine, Iuliu Hațieganu University of Medicine and Pharmacy, Cluj-Napoca, Romania

¹⁰⁾Department of Ophthalmology, Faculty of Medicine, Carol Davila University of Medicine and Pharmacy, Bucharest, Romania

¹¹⁾Department of Pathophysiology, Faculty of Medicine, Grigore T. Popa University of Medicine and Pharmacy, Iași, Romania

¹²⁾Department of Anesthesiology and Oral Surgery, Faculty of Medicine, Grigore T. Popa University of Medicine and Pharmacy, Iași, Romania

¹³⁾Department of Psychiatry, Faculty of Medicine, Grigore T. Popa University of Medicine and Pharmacy, Iași, Romania

Abstract

Metastases from intracranial meningiomas are rare, and among them, meningiomas with hepatic dissemination are extremely rare. Therefore, there are currently no guidelines for staging and treatment of metastatic disease in meningioma, a disease that is a challenge for both the clinician and the pathologist. Our literature review revealed 24 cases of liver metastases originating from intracranial meningiomas. We used them to analyze the pathological patterns of dissemination and to assess the different management strategies available, the most efficient and beneficial being surgery and chemotherapy, especially in the case of meningiomas with hepatic and/or systemic dissemination.

Keywords: hepatic metastases, chemotherapeutic agents, chemotherapy, malignant meningiomas, metastatic meningioma.

Introduction

Meningiomas are tumors that arise from the arachnoid cap cells, being the most common slow-growing benign tumors of the central nervous system [1, 2], and those that are probably most known for a long time [3]. Regarding the epidemiology of meningiomas, our previous studies have shown an increasing incidence and that these tumors are relatively common in the region served by our hospital [4–6]. The *World Health Organization* (WHO) has divided them in three histopathological grades; atypical (*WHO* grade II) and anaplastic (*WHO* grade III) meningiomas were found to develop a more aggressive biological behavior [7, 8].

In extremely rare cases, *i.e.*, 0.1%, intracranial meningiomas can spread extracranial [9], the most common anatomical localizations being the lungs, pleura, mediastinum, axial bones, and lymph nodes [10–14]. Of all these extracranial disseminations of meningiomas, hepatic metastases

along with extra-axial bone metastases are even less common [10, 12, 13]. In the literature, disseminations of meningiomas have also been reported in the orbit [15].

Several reviews have reported that metastatic lesions located in the liver account for 9.5% of the cases [1, 9, 16–18], and Attuati *et al.* (2019) reported a frequency of hepatic metastases due to meningiomas (single organ metastases) of 3.2% (seven cases) [2]. Liver metastases from intracranial meningioma are usually asymptomatic [19, 20], and this makes their incidence to be underestimated.

Aim

The aim of this review was to describe the morphological grading of hepatic metastases of meningiomas, to analyze the metastatic pattern considering the histopathological grade of the primary meningioma and to assess the management strategies provided in literature, which consist mainly of surgical and chemotherapeutic approaches.

Materials and Methods

We conducted a comprehensive general review of hepatic metastases disseminated from intracranial meningiomas, where we analyzed the information from the *PubMed* English medical electronic database.

We identified in literature 24 cases of intracranial meningiomas with hepatic dissemination. We noted that most primary meningiomas were atypical/malignant ($n=14$), and only nine were benign meningiomas (*WHO* grade I) (Table 1). Fourteen of the 24 patients were women, and metastases were diagnosed especially in the elderly population. Most patients ($n=12$) had at least three hepatic lesions, while 10 patients had only one hepatic metastasis (Table 2).

As far as treatment is concerned, most patients received surgical treatment (biopsy and surgical resection) and chemotherapy, while conservative treatment was preferred for a smaller number of patients, especially in severe cases without therapeutic resources (Table 3).

Table 1 – Summary of *WHO* grade at diagnosis for primary meningioma

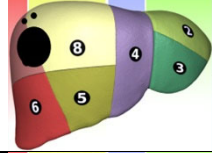
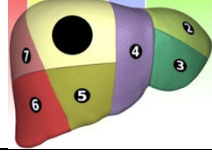
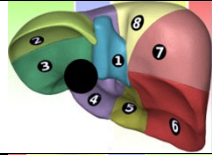

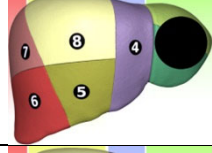


<i>WHO</i> grade at diagnosis ($n=24$)	No. of cases
Grade I	9
Grade II	12
Grade III	2
Not specified	1

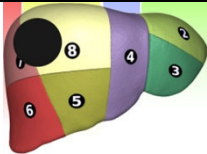


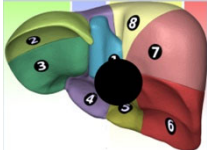





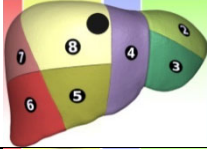
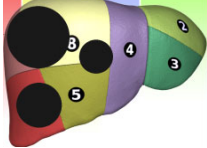
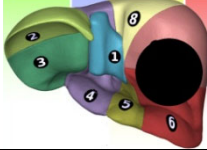
WHO: World Health Organization.

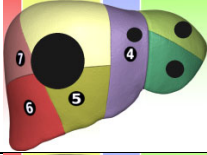
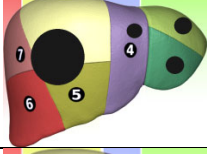
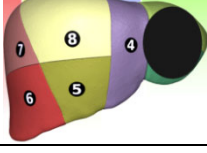
Table 2 – Summary of number of hepatic metastases

No. of hepatic lesions	No. of cases
1 hepatic lesion	10
3 hepatic lesions	2
>3 lesions	10
Not specified	2

Table 3 – Review of published papers on hepatic metastases from intracranial meningiomas

No.	Article	Sex, age [years]	Anatomical localization of meningioma (&)	Histopathological diagnosis of meningioma (&)	Hepatic metastases	Metastases localization in the liver	Treatment for hepatic lesions
1.	Beutler <i>et al.</i> , 2019 [21]	F, 71	Right parasagittal with occipital extracranial extension	Transitional meningioma (<i>WHO</i> grade I)	Multiple lesions (3)		Chemotherapy (Bevacizumab)
2.	Limarzi <i>et al.</i> , 2020 [22]	F, 68	Not specified	Atypical meningioma (<i>WHO</i> grade II)	Right hepatic lobe		Surgery (segmentectomy)
3.	Shimokawa <i>et al.</i> , 2020 [23]	F, 58	Large left frontal	Atypical meningioma (<i>WHO</i> grade II)	Hepatic mass*	No specified	Surgery (mass resection)
4.	Attuati <i>et al.</i> , 2019 [2]	F, 61	Torcular meningioma	Atypical meningioma (<i>WHO</i> grade II)	Not specified		Liver biopsy
5.	Unterrainer <i>et al.</i> , 2019 [24]	F, 43	Multiple meningiomas	Atypical meningioma (<i>WHO</i> grade II)	Multiple lesions		Not specified
6.	Obiorah & Ozdemirli, 2018 [25]	F, 54	Bifrontal parasagittal	<i>WHO</i> grade I meningioma	Left hepatic lobe*		Surgery (partial hepatectomy)
7.	Villanueva-Meyer <i>et al.</i> , 2018 [26]	F, 52	Multiple meningiomas	Atypical meningioma (<i>WHO</i> grade II)	IVb segment*		Liver biopsy
8.	Kessler <i>et al.</i> , 2017 [27]	M, 65	Left frontal meningioma	Anaplastic meningioma (<i>WHO</i> grade III)	Right hepatic lobe		Chemotherapy (Hydroxyurea for meningioma)
9.	Kessler <i>et al.</i> , 2017 [27]	M, 49	Superior sagittal sinus	Atypical meningioma (<i>WHO</i> grade II)	Not specified*	Not specified	Not specified

No.	Article	Sex, age [years]	Anatomical localization of meningioma (&)	Histopathological diagnosis of meningioma (&)	Hepatic metastases	Metastases localization in the liver	Treatment for hepatic lesions
10.	Forest <i>et al.</i> , 2014 [10]	F, 80	Right parietal	Atypical meningioma (<i>WHO</i> grade II)	Right hepatic lobe		Liver biopsy and surgical excision
11.	Forest <i>et al.</i> , 2014 [10]	M, 68	Right sphenoid meningioma	<i>WHO</i> grade I meningioma	Multiple lesions		Liver biopsy
12.	Lanfranchi & Nikpoor, 2013 [28]	M, 74	Right middle cranial fossa and right orbital cavity	Atypical meningioma (<i>WHO</i> grade II)	Multiple lesions		Not specified
13.	Lambertz <i>et al.</i> , 2011 [13]	F, 65	Right frontal extracranial meningioma	Atypical meningioma (<i>WHO</i> grade II)	Not specified		Chemotherapy (Hydroxyurea) Liver biopsy
14.	Taieb <i>et al.</i> , 2011 [29]	M, 30	Left orbital meningioma (multiple intracranial meningiomas)	Atypical meningioma (<i>WHO</i> grade II)	Multiple lesions		Observation
15.	Rampurwala <i>et al.</i> , 2011 [30]	F, 81	Not specified	Fibroblastic meningioma (<i>WHO</i> grade I)	Multiple lesions (12)*		Liver biopsy and observation
16.	Asghar <i>et al.</i> , 2009 [31]	M, 55	Left parieto-occipital	Atypical meningioma (<i>WHO</i> grade II)	Multiple lesions		Liver biopsy and chemotherapy (Ifosfamide)
17.	Garcia-Conde <i>et al.</i> , 2009 [32]	M, 44	Right lateral ventricle (trigone)	Anaplastic meningioma (<i>WHO</i> grade III)	Multiple lesions*		Liver biopsy
18.	Khalbuss <i>et al.</i> , 2005 [33]	F, 71	Left occipital	Meningioma with small-cell feature	Multiple lesions		Not specified
19.	Ku <i>et al.</i> , 2005 [34]	F, 47	Sphenoid bone meningioma	Fibrous meningioma (with a few regions of meningotheliomatous architecture) (<i>WHO</i> grade I)	Right hepatic lobe*		Liver biopsy and surgical resection
20.	Nabeya <i>et al.</i> , 1998 [20]	M, 60	Bifrontal parasagittal meningioma	Atypical meningioma with meningothelial features (malignant meningioma)	Right hepatic lobe*		Liver biopsy and surgical resection (right lobectomy)
21.	Enam <i>et al.</i> , 1996 [35]	F, 73	Midline frontoparietal	Meningothelial (with brain invasion, necrosis, nuclear pleomorphism, high mitotic rate)	Right hepatic lobe		Liver biopsy

No.	Article	Sex, age [years]	Anatomical localization of meningioma (&)	Histopathological diagnosis of meningioma (&)	Hepatic metastases	Metastases localization in the liver	Treatment for hepatic lesions
22.	Ferguson & Flinn, 1995 [19]	M, 37	Tentorial	Angioblastic meningioma (WHO grade I)	One in right hepatic lobe, multiple in left hepatic lobe		Chemoembolization (by selective catheterization of the right hepatic artery branches)
23.	Jenkinson <i>et al.</i> , 1987 [36]	M, 38	Right parieto-occipital meningioma	Angioblastic meningioma (WHO grade I)	One in right hepatic lobe, multiple in left hepatic lobe		Liver biopsy
24.	Akagi <i>et al.</i> , 1974 [37]	F, 33	Bifrontal parasagittal	Angioblastic meningioma (WHO grade I)	Left hepatic lobe		Observation

Images adapted according to Claude Couinaud Classification System; the numbers 1, 2, 3, 4, 5, 6, 7, 8 represent the liver segments; & – the anatomical localization of meningiomas and the histopathological diagnosis correspond to those of the authors; * – single systemic metastasis, only in the liver. The black dots approximate the localization, number and size of hepatic metastases (public domain). F: Female; M: Male; WHO: World Health Organization.

Pathological considerations

In general, extracranial metastases of meningioma are more common in anaplastic (30%) and atypical (5%) meningiomas [35]. Nevertheless, just like other authors [10], we consider this rate to be overestimated, as since 2016 the histopathological diagnosis criteria of atypical meningioma have been updated and are now more strictly defined. Moreover, in the past, the reported cases of ‘metastatic angioblastic meningioma’ were not genuine meningioma metastases, as they are currently diagnosed as hemangiopericytomas [10, 38–40].

Currently, there is no definitive criterion for predicting the ability of an intracranial meningioma to disseminate systemically. However, according to the data currently available in literature, the most important predictive factor for recurrence and metastasis in meningiomas seems to be the histological grade of the tumor [10, 17]. Other predictive factors that were also considered are: mitotic

rate, nuclear atypia, high cellularity, presence of small cells, patternless architecture, prominent nucleoli, presence of foci of necrosis, anaplastic features, and brain invasion [25, 30, 35, 40] (Figures 1–3).

Factors favoring meningioma dissemination

Some authors quoted the aggressive biological behavior of these tumors, especially atypical or malignant meningiomas [7], among the factors favoring metastases, although cases of benign meningiomas with remote dissemination have also been reported [9].

Other factors thought to influence remote meningioma spread were primary tumor localization in the proximity of venous drainage, subtotal tumor resections [41–43] or repeated surgical procedures, as many of the patients with remote metastases had a medical history of repeated surgical meningioma resections [9, 12, 44, 45].

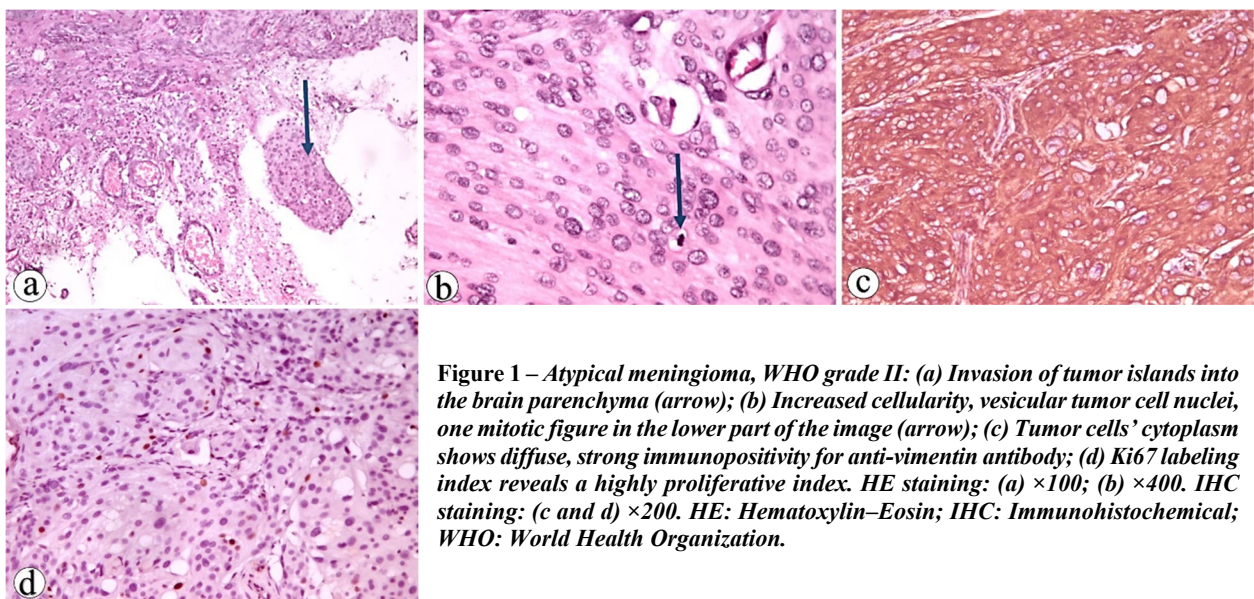


Figure 1 – Atypical meningioma, WHO grade II: (a) Invasion of tumor islands into the brain parenchyma (arrow); (b) Increased cellularity, vesicular tumor cell nuclei, one mitotic figure in the lower part of the image (arrow); (c) Tumor cells’ cytoplasm shows diffuse, strong immunopositivity for anti-vimentin antibody; (d) Ki67 labeling index reveals a highly proliferative index. HE staining: (a) $\times 100$; (b) $\times 400$. IHC staining: (c and d) $\times 200$. HE: Hematoxylin–Eosin; IHC: Immunohistochemical; WHO: World Health Organization.

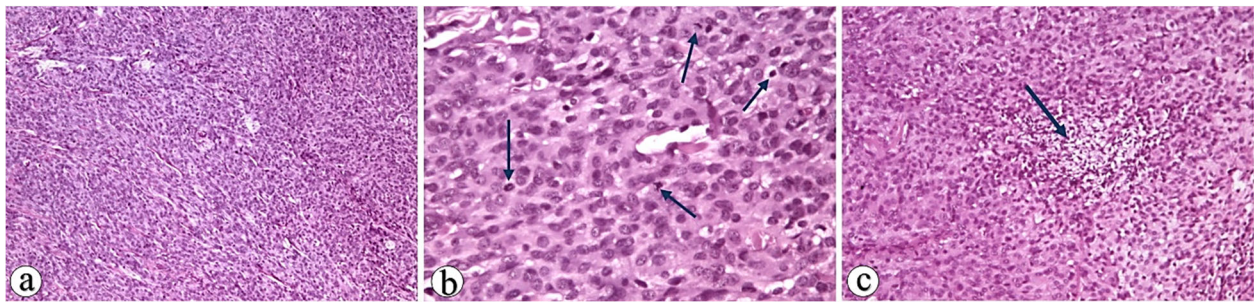


Figure 2 – Anaplastic meningioma, WHO grade III: (a) Hypercellular tumor with patternless or sheet-like growth (loss of lobular architecture); (b) Hypercellular tumor made of atypical meningothelial cells exhibiting vesicular nuclei with prominent nucleoli; many mitoses could be seen (≥ 4 mitoses/10 HPFs) (arrows); (c) Tumor spontaneous micronecrosis due to high metabolic demands, but insufficient cell nourishment and hypoxia (arrow). HE staining: (a and c) $\times 100$; (b) $\times 200$. HE: Hematoxylin–Eosin; HPFs: High-power fields; WHO: World Health Organization.

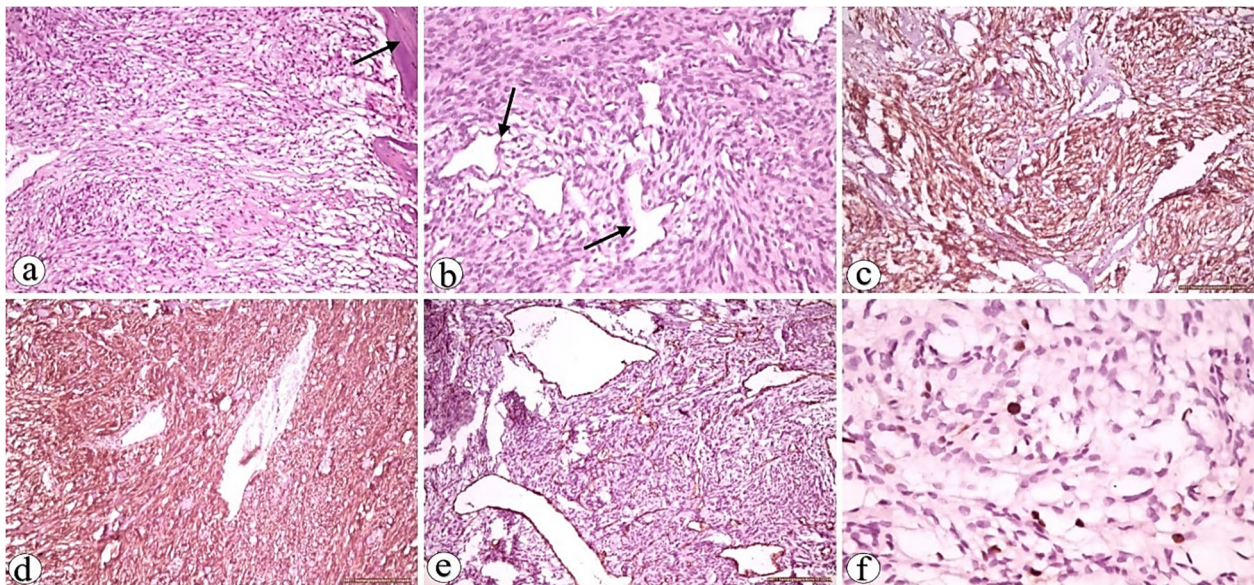


Figure 3 – Atypical meningioma, WHO grade II: (a) In the periphery, this tumor exhibits a meningeomatous growth pattern with a sheet-like architecture; the tumor mass infiltrated the adjacent dura mater (arrow); (b) The depth of the same tumor shows prominent hemangiopericytoma-like areas as there are some regions showing high cellularity and a staghorn vascular pattern (arrow); the tumor mass is made of spindle cells with indistinct cell boundaries, eosinophilic cytoplasm and oval nuclei with moderate pleomorphism and few mitoses; (c) Tumor cells from low density area are positive for anti-vimentin antibody; (d) Tumor cells of high-density area are also positive for anti-vimentin antibody; (e) Tumor cells are negative for anti-CD34 antibody, whereas endothelial cells show positivity for the same antibody; also, this immunostaining showed the great number of branching tumor vessels that have a hemangiopericytoma pattern; (f) Ki67 labeling index reveals a highly proliferative index. HE staining: (a) $\times 100$; (b) $\times 200$. IHC staining: (c–e) $\times 200$; (f) $\times 400$. CD34: Cluster of differentiation 34; HE: Hematoxylin–Eosin; IHC: Immunohistochemical; WHO: World Health Organization.

☐ Time until secondary lesion diagnosis

In a review of metastatic meningiomas, Forest *et al.* (2014) reported that the time elapsed until the diagnosis of metastasis varies greatly, depending on the histological grades of the primary tumor. Thus, he noted that, as expected, this time interval is shorter in higher histological grades, ranging between one year for grade III meningiomas and 11 years for grade I meningiomas [10]. However, it seems that the time reported in literature between the diagnosis of primary meningioma and the occurrence of metastases ranges between 6.4 and 31 years [30, 46]. Surov *et al.* (2013) also reported a median delay for the onset of meningioma metastases of 58 months after the primary meningioma diagnosis [9]. Metastatic meningioma to the liver may occur either simultaneously with an intracranial meningioma [34, 46] or several years after the surgical resection of intracranial meningioma [30, 32].

☐ Particular cases of hepatic metastases disseminated from intracranial meningiomas

We found three particular cases of meningiomas with hepatic metastases in literature. They were not included in the group of 24 patients that we analyzed.

The first is a rare intraspinal rhabdoid meningioma metastasis to the liver. The case was reported by Wang *et al.* (2011) and it was a 16-year-old boy with an intradural mass located between the C7 and T2 vertebrae, which spread multiple metastases to the liver and recurred despite radical surgery and radio- and chemotherapy [47].

Another particular case was a primary pulmonary malignant meningioma with lymph node but also hepatic metastasis [48]. The case was of a 108-year-old woman with a primary pulmonary meningioma in her right lung and it is considered by the author as the first case of this type, with autopsy-proven liver metastasis [48].

The third case is of a 68-year-old woman, known with intracranial atypical meningioma, which recurred two and four years later, for which she was operated again. A ventricular–peritoneal shunt was inserted on the last neurosurgery procedure, and three years later, a small recurrence was detected around the region of the shunt, for which she received external beam radiotherapy. She later came to the hospital for a large irregular mass in the IVb hepatic segment, developed in the vicinity of the ventricular–peritoneal shunt. This is the first case of its kind in literature [49].

☐ Pathways of metastatic spread in meningiomas

Metastasis of intracranial meningioma to the liver is extremely rare and its dissemination routes to other organs have not unfortunately been fully understood yet. However, several spread routes have been suggested, namely through the cerebrospinal fluid, venous system or lymphatics; among these, hematogenous spread through the venous system is thought to be the most common [11, 14, 25].

In the case of liver metastasis *via* the venous circulation (considered to be the most common), it seems that tumor cells can reach the liver through the vertebral venous system that connects the veins of the cranium and vertebral column to the thoracoabdominal wall [9, 25] or through the jugular veins [50, 51]. Surov *et al.* (2013) claim that tumor cells can reach the liver if they pass through the right atrium and from here into the inferior vena cava and further to the hepatic veins [9].

Several authors have claimed that meningioma invasion of adjacent dural sinuses (Figure 4) or venous plexus could be a possible risk factor associated with distant spreading, as they noted that meningiomas with parasagittal, falcine and torcular localization were the most prone to causing metastases [44, 52–55]. Similarly, in a review, Surov *et al.* (2013) noted that the venous sinuses were involved in 22% of cases [9].

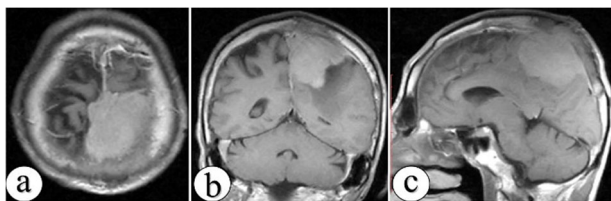


Figure 4 – Meningiomas with dural sinus invasion increase the risk of dissemination: atypical meningioma (WHO grade II meningioma) with invasion of the superior sagittal sinus; male, 58-year-old, head MRI (T1WI + contrast), with axial (a), coronal (b) and sagittal (c) section. MRI: Magnetic resonance imaging; T1WI: T1 weighted image; WHO: World Health Organization.

Another dissemination route suggested by Garcia-Conde *et al.* (2009) was hematogenous dissemination with micro-embolisms of tumor cells in the choroid plexus, in a case report of an intraventricular meningioma, with multiple hepatic metastases [32]. Metastatic spread may also be achieved through the cerebrospinal fluid, and Moir *et al.* (2010) described the occurrence of hepatic metastasis from an intracranial meningioma through a ventricular–peritoneal shunt [49]. Forest *et al.* (2014) also

considered direct dissemination from the bones, when bone and liver metastases coexist [10].

Nevertheless, the precise etiology of metastatic spread in meningioma remains unknown [10], some authors emphasizing the role of blood vessel invasion, tumor necrosis, cellularity or nuclear pleomorphism [35, 56].

☐ Treatment in metastatic meningioma

The most common presentation of metastatic meningioma to the liver is hypoglycemia [19, 20, 57, 58]. As concerns the pathophysiological mechanism of hypoglycemia, some authors believe that it is due to glycogen depletion by replacement of hepatic parenchymal with metastatic tumor and excessive use of glucose by the metastatic tumor cells [19]. Therefore, Obirah & Ozdemirli (2018) believe that hypoglycemia in a patient with intracranial meningioma should raise the suspicion of hepatic metastases [25].

Due to the rarity of metastatic meningioma to the liver, its treatment has not been standardized, since a general consensus on the treatment of meningioma metastasis has not yet been reached [10], and therefore, in such cases, the treatment options should be customized depending on the specificity of each case.

Due to the rarity of these cases of extracranial metastasis, there is currently no management protocol, and the prognosis of these patients is unknown [59, 60].

Despite important advances in modern therapies, surgical resection remains the best treatment option for most patients with intracranial meningiomas and hepatic dissemination.

Since meningiomas are generally slow-growing tumors, metastasectomies seem to have improved survival rates [10]. In a review of metastatic meningiomas, Forest *et al.* (2014) noted that resection of local recurrence and resection of the metastasis not only improved the prognosis, but also cured the disease, especially in cases of low-grade meningioma. On the other hand, death or disease progression rather occurred in grade II or III meningiomas [10]. Also, in the group of 24 cases that we reviewed, we noticed that most hepatic metastases were treated by surgical methods, namely tumor resection, and the postoperative results were good.

In 1995, Ferguson & Flinn reported a large metastatic meningioma in the right lobe of the liver with multiple small metastases in the left lobe in a 37-year-old patient, who was successfully treated by chemoembolization with Lipiodol mixed with Doxorubicin hydrochloride by selective catheterization of the right hepatic artery branches, with good clinical response. The two authors consider that in such cases, when neither surgical debulking nor total resection can be performed, reduction by chemoembolization may be an alternative [19]. Chemoembolization may also be used postoperatively, in case of residual tumor [20] or in patients with significant symptoms of hypoglycemia [19, 20].

Regarding asymptomatic hepatic metastases that were discovered incidentally, some authors recommend imaging follow-up [30].

In 2011, the *National Comprehensive Cancer Network* (NCCN) released Guidelines in which it recommended only three classes of chemotherapy drugs: somatostatin receptor agonists, interferon- α (IFN- α), and vascular endothelial growth factor (VEGF) signaling inhibitors

for the medical treatment of meningiomas [27, 61]. These recommendations later gave rise to several small studies or large prospective studies and clinical trials [62], in which other new drugs, such as anthracyclines and alkylating agents [44], Bevacizumab [63], or Vatalanib, a novel tyrosine kinase inhibitor [64] began to be studied.

In 2014, Kaley *et al.* (2014) conducted a review of 47 publications that reported the use of systemic chemotherapy in the treatment of recurrent meningiomas. They analyzed the efficacy of several chemotherapeutics (Temozolomide, Bevacizumab, Irinotecan, IFN- α , Hydroxyurea, Octreotide analogues, Gefitinib, Imatinib, Erlotinib, Mifepristone, Megestrol acetate), reporting a six-month poor progression free survival for WHO grade II and III meningiomas in case of systemic chemotherapy [65].

Hydroxyurea [66], Doxorubicin [67] and Trabectedin [68] have also been considered in the treatment of malignant intracranial meningiomas, although Newton *et al.* (2000 & 2007) showed reduced antitumor activity in the case of Hydroxyurea [69, 70]. Systemic multidrug chemotherapy using Vincristine, Cyclophosphamide, Ifosfamide and Doxorubicin has also been considered, but it has been shown to have reduced efficacy in slowing disease progression [10, 31].

Recent studies have shown promising results for Bevacizumab, as some authors have found that it increases progression-free survival in patients with meningiomas [63]. Vatalanib, a novel tyrosine kinase inhibitor, has shown its efficacy in systemic meningioma therapy [64], and targeted therapies against VEGF, epidermal growth factor receptor (EGFR), platelet-derived growth factor (PDGF) or mitogen-activated protein kinase (MAPK) pathways have also been considered, the effectiveness of which is being assessed [71, 72].

Conclusions

The diagnosis of metastatic meningioma in the absence of symptoms may be a challenge for both clinician and pathologist, and in such a case, treatment should be assessed by a multidisciplinary team including a neurosurgeon, a general surgeon, an oncologist, and a pathologist. In the case of an intracranial meningioma with malignant histological appearance, we recommend a close follow-up, especially when total resection is not possible. It should also be borne in mind that the metastatic spread of meningioma remains possible even in the case of benign meningioma. Moreover, the diagnosis of extracranial metastasis of meningiomas should always be included in the differential diagnosis of patients with a medical history of intracranial meningioma, especially in the case of symptoms of liver disease. Since metastatic disease in meningiomas is extremely rare, there are currently no guidelines regarding the treatment or staging of this disease. However, our report showed that most hepatic metastases due to meningioma were treated by surgery and chemotherapy. This may be an option in the case of high-grade refractory recurrent meningiomas, or in the case of multiple meningiomas with systemic dissemination.

Conflict of interests

The authors declare that they have no conflict of interests.

References

- Erman T, Hanta I, Hacıyakupoğlu S, Zorludemir S, Zeren H, Göçer AI. Huge bilateral pulmonary and pleural metastasis from intracranial meningioma: a case report and review of the literature. *J Neurooncol*, 2005, 74(2):179–181. <https://doi.org/10.1007/s11060-004-3014-2> PMID: 16193389
- Attuati L, Zaed I, Morselli C, Pecchioli G, Fornari M, Picozzi P. Multimodal management of metastatic malignant meningiomas: the role of radiosurgery in long-term local control. *World Neurosurg*, 2019, 128:562–572. <https://doi.org/10.1016/j.wneu.2019.05.058> PMID: 31102770
- Cucu AI, Costea CF, Perciaccante A, Carauleanu A, Turliuc S, Costachescu B, Poeata I, Turliuc MD. The history of *Arachne* through historic descriptions of meningiomas with hyperostosis: from prehistory to the present. *World Neurosurg*, 2019, 128: 37–46. <https://doi.org/10.1016/j.wneu.2019.04.199> PMID: 31048045
- Cucu AI, Costea CF, Carauleanu A, Dumitrescu GF, Sava A, Scripcariu IS, Costan VV, Turliuc S, Poeata I, Turliuc DM. Meningiomas related to the Chernobyl irradiation disaster in North-Eastern Romania between 1990 and 2015. *Rev Chim (Bucharest)*, 2018, 69(6):1562–1565. <https://doi.org/10.37358/RC.18.6.6369>
- Cucu AI, Costea CF, Poeată I, Costăchescu B, Dumitrescu GF, Sava A, Turliuc MD. Anatomical localization of atypical meningiomas: our experience on 81 patients. *Med Surg J (Rev Med Chir Soc Med Nat Iași)*, 2018, 122(4):744–752. <https://www.revmedchir.ro/index.php/revmedchir/article/view/1591>
- Cucu AI, Costea CF, Turliuc MD, Ghiciuc CM, Costachescu B, Popescu R, Dumitrescu GF, Sava A, Tanase DM, Arbore-Sorete R, Poeata I. Anatomical localization of intracranial grade II meningiomas in North-Eastern Romania: our 25-years experience. *Rom Neurosurg*, 2019, 33(3):232–238. <https://doi.org/10.33962/roneuro-2019-039>
- Ciocan LM, Dănilă L, Stănculescu DE, Neamțu SD, Mateescu GO, Stanca L. Prognostic factors in anterior skull base meningiomas. *Rom J Morphol Embryol*, 2014, 55(3 Suppl): 1063–1069. PMID: 25607386
- Cucu AI, Costea CF, Turliuc MD, Dumitrescu GF, Sava A, Poeată I. Are there any correlations between demographic characteristics, tumor location, and Ki-67 labeling index in intracranial atypical meningiomas (WHO grade II)? *Rom J Morphol Embryol*, 2019, 60(2):567–572. PMID: 31658330
- Surov A, Gottschling S, Bolz J, Kornhuber M, Alfieri A, Holzhausen HJ, Abbas J, Kösling S. Distant metastases in meningioma: an underestimated problem. *J Neurooncol*, 2013, 112(3):323–327. <https://doi.org/10.1007/s11060-013-1074-x> PMID: 23404622
- Forest F, Berremila SA, Gyenes C, Ginguéné C, Kassir R, Sulaiman A, Pasquier B, Porcheron J, Péoc'h M. Metastatic meningiomas: an unusual clinical and pathological diagnosis with highly variable outcome. *J Neurooncol*, 2014, 120(2): 411–421. <https://doi.org/10.1007/s11060-014-1567-2> PMID: 25081976
- Cucu AI, Turliuc MD, Costea CF, Costăchescu B, Ghiciuc CM, Dobrovăț B, Bogdănici CM, Tănase DM, Dumitrescu GF, Sava A, Poeată I. "The Silk Road" via subarachnoid cisterns: cerebrospinal fluid dissemination of meningiomas. *Rom Neurosurg*, 2019, 33(3):260–267. <https://doi.org/10.33962/roneuro-2019-043>
- Estanislau ES, Carvalho GTC, Reis BL, de Freitas Barbosa W, Brandão RACS, Sousa AA, Oliveira JB. Malignant meningioma with extracranial metastases. *Arq Neuropsiquiatr*, 2009, 67(3A): 730–732. <https://doi.org/10.1590/s0004-282x2009000400036> PMID: 19722065
- Lambertz N, Koehler J, Schulte DM, Kuehl H, Wohlschlaeger J, Hense J, Schuler M, Mueller OM. Multivisceral systemic metastases from an intracranial anaplastic meningioma: a case report and review of literature. *Clin Neurol Neurosurg*, 2011, 113(7):592–595. <https://doi.org/10.1016/j.clineuro.2011.02.017> PMID: 21435776
- Cucu AI, Turliuc DM, Costea CF, Costachescu B, Malaimare AE, Blaj LA, Trandafir V, Danca C, Poeata I. Pathways of metastatic spread in meningiomas. *Rom Neurosurg*, 2019, 33(1):12–16. <https://doi.org/10.33962/roneuro-2019-002>
- Garcia GA, Choy AE, Hasso AN, Minckler DS. Malignant orbital meningioma originating from the frontal lobe. *Ocul Oncol Pathol*, 2018, 4(3):186–190. <https://doi.org/10.1159/000481509> PMID: 29765952 PMID: PMC5939669

- [16] Chohan MO, Ryan CT, Singh R, Lanning RM, Reiner AS, Rosenblum MK, Tabar V, Gutin PH. Predictors of treatment response and survival outcomes in meningioma recurrence with atypical or anaplastic histology. *Neurosurgery*, 2018, 82(6): 824–832. <https://doi.org/10.1093/neuros/nyx312> PMID: 28645194 PMCID: PMC6257020
- [17] Fabi A, Nuzzo C, Vidiri A, Ciccarese M, Felici A, Cattani F, Cognetti F. Bone and lung metastases from intracranial meningioma. *Anticancer Res*, 2006, 26(5B):3835–3837. PMID: 17094409
- [18] Vik A, Kvikstad A, Unsgård G, Jørgensen JV, Torp SH. 54 år gammel mann med stor subkutan hevelse over vertex og fokale epileptiske anfall [A 54-year-old man with a large subcutaneous skull erosion and focal epileptic seizures]. *Tidsskr Nor Lægeforen*, 2006, 126(18):2386–2387. PMID: 17007100
- [19] Ferguson JM, Flinn J. Intracranial meningioma with hepatic metastases and hypoglycaemia treated by selective hepatic arterial chemo-embolization. *Australas Radiol*, 1995, 39(1):97–99. <https://doi.org/10.1111/j.1440-1673.1995.tb00246.x> PMID: 7535050
- [20] Nabeya Y, Okazaki Y, Watanabe Y, Tohnosu N, Yamazaki M, Matsuda M, Iizuka H, Akutsu N, Kono T, Sato H, Kubosawa H. Metastatic malignant meningioma of the liver with hypoglycemia: report of a case. *Surg Today*, 1998, 28(9):953–958. <https://doi.org/10.1007/s005950050260> PMID: 9744408
- [21] Beutler BD, Nguyen ET, Parker RA, Tran C, Acharya J, Torres FA, Gullapalli N. Metastatic meningioma: case report of a WHO grade I meningioma with liver metastases and review of the literature. *Radiol Case Rep*, 2019, 15(2):110–116. <https://doi.org/10.1016/j.radcr.2019.10.027> PMID: 31762868 PMCID: PMC6864214
- [22] Limarzi F, Solaini L, Ercolani G, Foschini MP, Saragoni L. Liver metastasis from a non-recurrent atypical cranial meningioma: a case report. *Pathologica*, 2020, 112(1):46–49. <https://doi.org/10.32074/1591-951X-29-19> PMID: 32202539 PMCID: PMC8138499
- [23] Shimokawa Y, Yamada Y, Kawanami K, Yamaki T, Sonoda Y. [A case of atypical meningioma with liver metastasis at 9 years after initial surgery]. *No Shinkei Geka*, 2020, 48(1):63–69. <https://doi.org/10.11477/mf.1436204135> PMID: 31983690
- [24] Unterrainer M, Ilhan H, Vettermann F, Cyran CC, Tonn JC, Niyazi M, Bartenstein P, Albert NL. Whole-body staging of metastatic atypical meningioma using ⁶⁸Ga-DOTATATE PET/CT. *Clin Nucl Med*, 2019, 44(3):227–228. <https://doi.org/10.1097/RLU.0000000000002422> PMID: 30589668
- [25] Obiorah IE, Ozdemirli M. Incidental metastatic meningioma presenting as a large liver mass. *Case Reports Hepatol*, 2018, 2018:1089394. <https://doi.org/10.1155/2018/1089394> PMID: 29854500 PMCID: PMC5964563
- [26] Villanueva-Meyer JE, Magill ST, Lee JC, Umetsu SE, Flavell RR. Detection of metastatic meningioma to the liver using ⁶⁸Ga-DOTA-Octreotate PET/CT. *Clin Nucl Med*, 2018, 43(9):e338–e340. <https://doi.org/10.1097/RLU.0000000000002183> PMID: 29939957
- [27] Kessler RA, Garzon-Muvdi T, Yang W, Weingart J, Olivi A, Huang J, Brem H, Lim M. Metastatic atypical and anaplastic meningioma: a case series and review of the literature. *World Neurosurg*, 2017, 101:47–56. <https://doi.org/10.1016/j.wneu.2017.01.070> PMID: 28143726
- [28] Lanfranchi M, Nikpoor N. Detection of meningioma metastasis to liver and lung using somatostatin receptor scintigraphy. *Clin Nucl Med*, 2013, 38(8):668–670. <https://doi.org/10.1097/RLU.0b013e31829962ac> PMID: 23797223
- [29] Taieb G, Campello C, Renard D, El Fertit H, Joujoux JM, Savin C, Labauge P. Multifocal extracranial meningioma metastases. *Arch Neurol*, 2011, 68(3):388–389. <https://doi.org/10.1001/archneurol.2011.28> PMID: 21403027
- [30] Rampurwala M, Pazoiki M, Schauer M. Delayed hepatic metastasis from a benign fibroblastic meningioma thirty-one years after surgical resection of the intracranial tumor. *J Clin Oncol*, 2011, 29(9):e214–e215. <https://doi.org/10.1200/JCO.2010.32.6694> PMID: 21172880
- [31] Asghar AH, Mahmood H, Faheem M, Rizvi S, Irfan J. Hepatic and skeletal metastases from primary intracranial atypical meningioma. *J Coll Physicians Surg Pak*, 2009, 19(5):316–317. PMID: 19409167
- [32] Garcia-Conde M, Roldan-Delgado H, Martel-Barth-Hansen D, Manzano-Sanz C. Anaplastic transformation of an atypical intraventricular meningioma with metastases to the liver: case report. *Neurocirugia (Astur)*, 2009, 20(6):541–549. PMID: 19967319
- [33] Khalbuss WE, Grigorian S, Bui MM, Elhosseiny A. Small-cell tumors of the liver: a cytological study of 91 cases and a review of the literature. *Diagn Cytopathol*, 2005, 33(1):8–14. <https://doi.org/10.1002/dc.20255> PMID: 15945087
- [34] Ku JK, Vasquez JC, Hoyt DB, Coimbra R. Metastatic meningioma to the liver successfully treated with a wedge resection and radiation therapy: report of a case. *Surg Today*, 2005, 35(1): 82–85. <https://doi.org/10.1007/s00595-004-2849-7> PMID: 15622471
- [35] Enam SA, Abdulrauf S, Mehta B, Malik GM, Mahmood A. Metastasis in meningioma. *Acta Neurochir (Wien)*, 1996, 138(10):1172–1177; discussion 1177–1178. <https://doi.org/10.1007/BF01809747> PMID: 8955436
- [36] Jenkinson ML, Watson AJ, Boyle S. Hepatic metastasis from intracranial meningioma. *Postgrad Med J*, 1987, 63(737):199–200. <https://doi.org/10.1136/pgmj.63.737.199> PMID: 3671258 PMCID: PMC2428285
- [37] Akagi T, Iwata K, Utsunomiya T, Yoshimura H. An autopsy case of meningioma with extracranial remote metastases. *Acta Pathol Jpn*, 1974, 24(5):667–671. <https://doi.org/10.1111/j.1440-1827.1974.tb01242.x> PMID: 4474791
- [38] Kabus D, Sidhu GS, Wiczorek RL, Choi HS. Metastatic meningioma. Hemangiopericytoma or angioblastic meningioma? *Am J Surg Pathol*, 1993, 17(11):1144–1150. <https://doi.org/10.1097/0000478-199311000-00007> PMID: 8214259
- [39] Gordon A, Maloney AF. A case of metastasizing meningioma. *J Neurol Neurosurg Psychiatry*, 1965, 28(2):159–162. <https://doi.org/10.1136/jnnp.28.2.159> PMID: 14285654 PMCID: PMC495875
- [40] Louis DN, Ohgaki H, Wiestler OD, Cavenee WK, Burger PC, Jouvet A, Scheithauer BW, Kleihues P. The 2007 WHO Classification of Tumours of the Central Nervous System. *Acta Neuropathol*, 2007, 114(2):97–109. <https://doi.org/10.1007/s00401-007-0243-4> PMID: 17618441 PMCID: PMC1929165
- [41] Adlakha A, Rao K, Adlakha H, Perry A, Crotty TB, Scheithauer BW, Ryu JH. Meningioma metastatic to the lung. *Mayo Clin Proc*, 1999, 74(11):1129–1133. <https://doi.org/10.4065/74.11.1129> PMID: 10560602
- [42] Kepes JJ. Meningiomas: biology, pathology and differential diagnosis. Masson Publishing, New York, USA, 1982. <https://www.worldcat.org/title/meningiomas-biology-pathology-and-differential-diagnosis/oclc/07945917>
- [43] Kleihues P, Burger PC, Scheithauer BW. Histological typing of tumours of the central nervous system. Springer-Verlag, Berlin–Heidelberg, 1993. <https://doi.org/10.1007/978-3-642-84988-6>
- [44] Kanthan R, Senger JL. Distant metastases from meningiomas – a myth or reality? *Ann Clin Pathol*, 2013, 1(1):1001. <https://www.jscimedcentral.com/Pathology/Articles/pathology-1-1001.php>
- [45] Rawat B, Franchetto AA, Elavathil J. Extracranial metastases of meningioma. *Neuroradiology*, 1995, 37(1):38–41. <https://doi.org/10.1007/BF00588517> PMID: 7708187
- [46] Kaminski JM, Movsas B, King E, Yang C, Kronz JD, Alli PM, Williams J, Brem H. Metastatic meningioma to the lung with multiple pleural metastases. *Am J Clin Oncol*, 2001, 24(6): 579–582. <https://doi.org/10.1097/0000421-200112000-00010> PMID: 11801758
- [47] Wang Z, Kong M, Li J, Xiao W, Zheng S. Intraspinal rhabdoid meningioma metastasis to the liver. *J Clin Neurosci*, 2011, 18(5):714–716. <https://doi.org/10.1016/j.jocn.2010.07.146> PMID: 21349724
- [48] Weber C, Pautex S, Zulian GB, Pusztaszeri M, Lobrinus JA. Primary pulmonary malignant meningioma with lymph node and liver metastasis in a centenarian woman, an autopsy case. *Virchows Arch*, 2013, 462(4):481–485. <https://doi.org/10.1007/s00428-013-1383-7> PMID: 23443940
- [49] Moir JAG, Haugk B, French JJ. Hepatic metastasis *via* a ventriculo-peritoneal shunt from an intracranial meningioma: case report and review of the literature. *Case Rep Gastroenterol*, 2010, 4(2):267–272. <https://doi.org/10.1159/000316118> PMID: 21373384 PMCID: PMC3047756

- [50] Som PM, Sacher M, Strenger SW, Biller HF, Malis LI. "Benign" metastasizing meningiomas. *AJNR Am J Neuroradiol*, 1987, 8(1):127–130. PMID: 3101455 PMCID: PMC8334031
- [51] Zaghoulani H, Yahyaoui S, Chabchoub I, Mallat N, Majdoub S, Amara H, Bakir D, Badreddine S, Kraiem C. Vertebral metastases from intracranial meningioma. *Acta Radiol Short Rep*, 2014, 3(4):2047981613494199. <https://doi.org/10.1177/2047981613494199> PMID: 25298865 PMCID: PMC4184420
- [52] Drummond KJ, Bittar RG, Fearnside MR. Metastatic atypical meningioma: case report and review of the literature. *J Clin Neurosci*, 2000, 7(1):69–72. <https://doi.org/10.1054/jocn.1998.0153> PMID: 10847658
- [53] Celli P, Palma L, Domenicucci M, Scarpinati M. Histologically benign recurrent meningioma metastasizing to the parotid gland: case report and review of the literature. *Neurosurgery*, 1992, 31(6):1113–1116; discussion 1116. <https://doi.org/10.1227/00006123-199212000-00020> PMID: 1470323
- [54] Ohta M, Iwaki T, Kitamoto T, Takeshita I, Tateishi J, Fukui M. MIB1 staining index and scoring of histological features in meningioma. Indicators for the prediction of biologic potential and postoperative management. *Cancer*, 1994, 74(12):3176–3189. [https://doi.org/10.1002/1097-0142\(19941215\)74:12<3176::aid-cnrcr2820741217>3.0.co;2-n](https://doi.org/10.1002/1097-0142(19941215)74:12<3176::aid-cnrcr2820741217>3.0.co;2-n) PMID: 7982181
- [55] Shuangshoti S, Hongsaprabhas C, Netsky MG. Metastasizing meningioma. *Cancer*, 1970, 26(4):832–841. [https://doi.org/10.1002/1097-0142\(197010\)26:4<832::aid-cnrcr2820260416>3.0.co;2-s](https://doi.org/10.1002/1097-0142(197010)26:4<832::aid-cnrcr2820260416>3.0.co;2-s) PMID: 5528265
- [56] Figueroa BE, Quint DJ, McKeever PE, Chandler WF. Extracranial metastatic meningioma. *Br J Radiol*, 1999, 72(857):513–516. <https://doi.org/10.1259/bjr.72.857.10505022> PMID: 10505022
- [57] Yoshida D, Sugisaki Y, Tamaki T, Saitoh N, Node Y, Shimura T, Teramoto A. Intracranial malignant meningioma with abdominal metastases associated with hypoglycemic shock: a case report. *J Neurooncol*, 2000, 47(1):51–58. <https://doi.org/10.1023/a:1006460827300> PMID: 10930100
- [58] Jestico JV, Lantos PL. Malignant meningioma with liver metastases and hypoglycaemia. A case report. *Acta Neuropathol*, 1976, 35(4):357–361. PMID: 961386
- [59] Koenig MA, Geocadin RG, Kulesza P, Olivi A, Brem H. Rhabdoid meningioma occurring in an unrelated resection cavity with leptomeningeal carcinomatosis. Case report. *J Neurosurg*, 2005, 102(2):371–375. <https://doi.org/10.3171/jns.2005.102.2.0371> PMID: 15739568
- [60] Merrell R. Section 10: The Nervous System – Brain tumors. In: Bope ET, Kellerman RD (eds). *Conn's current therapy 2016*. Elsevier Health Sciences, Philadelphia, PA, USA, 2015, 647–724. <https://www.worldcat.org/title/conn-s-current-therapy-2016/oclc/913557862>
- [61] Chamberlain MC. Treatment of meningioma, including in cases with no further surgical or radiotherapy options. *Oncology (Williston Park)*, 2015, 29(5):369–371. PMID: 25979547
- [62] Moazzam AA, Wagle N, Zada G. Recent developments in chemotherapy for meningiomas: a review. *Neurosurg Focus*, 2013, 35(6):E18. <https://doi.org/10.3171/2013.10.FOCUS13341> PMID: 24289126
- [63] Lou E, Sumrall AL, Turner S, Peters KB, Desjardins A, Vredenburgh JJ, McLendon RE, Herndon JE 2nd, McSherry F, Norfleet J, Friedman HS, Reardon DA. Bevacizumab therapy for adults with recurrent/progressive meningioma: a retrospective series. *J Neurooncol*, 2012, 109(1):63–70. <https://doi.org/10.1007/s11060-012-0861-0> PMID: 22535433 PMCID: PMC3404217
- [64] Raizer JJ, Grimm SA, Rademaker A, Chandler JP, Muro K, Helenowski I, Rice L, McCarthy K, Johnston SK, Mrugala MM, Chamberlain M. A phase II trial of PTK787/ZK 222584 in recurrent or progressive radiation and surgery refractory meningiomas. *J Neurooncol*, 2014, 117(1):93–101. <https://doi.org/10.1007/s11060-014-1358-9> PMID: 24449400
- [65] Kaley T, Barani I, Chamberlain M, McDermott M, Panageas K, Raizer J, Rogers L, Schiff D, Vogelbaum M, Weber D, Wen P. Historical benchmarks for medical therapy trials in surgery- and radiation-refractory meningioma: a RANO review. *Neuro Oncol*, 2014, 16(6):829–840. <https://doi.org/10.1093/neuonc/not330> PMID: 24500419 PMCID: PMC4022224
- [66] Mason WP, Gentili F, Macdonald DR, Hariharan S, Cruz CR, Abrey LE. Stabilization of disease progression by hydroxyurea in patients with recurrent or unresectable meningioma. *J Neurosurg*, 2002, 97(2):341–346. <https://doi.org/10.3171/jns.2002.97.2.0341> PMID: 12186462
- [67] Travitzky M, Libson E, Nemirovsky I, Hadas I, Gabizon A. Doxil-induced regression of pleuro-pulmonary metastases in a patient with malignant meningioma. *Anticancer Drugs*, 2003, 14(3):247–250. <https://doi.org/10.1097/00001813-200303000-00009> PMID: 12634620
- [68] Preusser M, Spiegl-Kreinecker S, Lötsch D, Wöhrer A, Schmook M, Dieckmann K, Saringer W, Marosi C, Berger W. Trabectedin has promising antineoplastic activity in high-grade meningioma. *Cancer*, 2012, 118(20):5038–5049. <https://doi.org/10.1002/cncr.27460> PMID: 22392434
- [69] Newton HB. Hydroxyurea chemotherapy in the treatment of meningiomas. *Neurosurg Focus*, 2007, 23(4):E11. <https://doi.org/10.3171/FOC-07/10/E11> PMID: 17961035
- [70] Newton HB, Slivka MA, Stevens C. Hydroxyurea chemotherapy for unresectable or residual meningioma. *J Neurooncol*, 2000, 49(2):165–170. <https://doi.org/10.1023/a:1026770624783> PMID: 11206012
- [71] Saraf S, McCarthy BJ, Villano JL. Update on meningiomas. *Oncologist*, 2011, 16(11):1604–1613. <https://doi.org/10.1634/theoncologist.2011-0193> PMID: 22028341 PMCID: PMC3233296
- [72] Chamberlain MC, Barnholtz-Sloan JS. Medical treatment of recurrent meningiomas. *Expert Rev Neurother*, 2011, 11(10):1425–1432. <https://doi.org/10.1586/em.11.38> PMID: 21955199

Corresponding authors

Andrei Ionuț Cucu, MD, PhD, 2nd Neurosurgery Clinic, Prof. Dr. Nicolae Oblu Emergency Clinical Hospital, 2 Ateneului Street, 700309 Iași, Romania; Phone +40748–378 468, e-mail: andreucucu@yahoo.com

Dragoș Viorel Scripcariu, MD, PhD, Department of General Surgery, Faculty of Medicine, Grigore T. Popa University of Medicine and Pharmacy, 16 Universității Street, 700115 Iași, Romania; Phone +40723–913 425, e-mail: dscripcariu@gmail.com

Received: March 29, 2021

Accepted: December 29, 2021