

[CASE REPORT]

Successful Treatment with High-dose Steroids for Acute Exacerbation of Idiopathic Pulmonary Fibrosis Triggered by COVID-19

Norihito Omote^{1,2}, Yoshihiro Kanemitsu^{2,3}, Takahiro Inoue^{2,4}, Toshiyuki Yonezawa^{2,5},
Takuji Ichihashi², Yuichiro Shindo^{1,2}, Koji Sakamoto¹, Akira Ando¹, Atsushi Suzuki¹,
Akio Niimi³, Satoru Ito⁵, Kazuyoshi Imaizumi⁴ and Naozumi Hashimoto¹

Abstract:

We herein report a case of acute exacerbation of idiopathic pulmonary fibrosis (AE-IPF) triggered by COVID-19. An 87-year-old woman tested positive for COVID-19 on a polymerase chain reaction test, and computed tomography revealed ground-glass opacity (GGO) superimposed on a background pattern consistent with usual interstitial pneumonia. Considering these data, we diagnosed her with AE-IPF. She experienced worsening of dyspnea and expansion of the GGO. Therefore, we introduced high-dose steroids (methylprednisolone 250 mg/day for 3 days). After the treatment, the pulmonary infiltrates improved. She was discharged from our hospital without severe disability. High-dose steroids can be a viable treatment option for AE-IPF triggered by COVID-19.

Key words: COVID-19, acute exacerbation, idiopathic pulmonary fibrosis, high-dose steroid, case report

(Intern Med 61: 233-236, 2022)

(DOI: 10.2169/internalmedicine.8163-21)

Introduction

Coronavirus disease 2019 (COVID-19) pneumonia is an acute respiratory disease caused by severe acute respiratory syndrome coronavirus 2 infection. Several drugs, including steroids and remdesivir, have been shown to be effective in recent randomized controlled trials for patients with severe COVID-19 (1, 2). However, despite the development of therapeutic strategies, patients with COVID-19 still exhibit a high mortality rate, especially among the elderly and those with comorbidities, including diabetes, renal failure, and respiratory diseases (3, 4). In particular, respiratory diseases, such as chronic obstructive pulmonary disease and interstitial lung disease (ILD), are also strongly associated with a high mortality (3, 5).

Idiopathic pulmonary fibrosis (IPF) is an irreversible and progressive ILD with an unknown etiology. Some patients with IPF experience acute exacerbation (AE) of the disease, with episodes of the sudden acceleration of the disease process (6, 7). AE-IPF is a severe and life-threatening complication of IPF that occurs without any identifiable causes or triggers, such as surgical intervention or infection (8).

We herein report a patient with AE-IPF triggered by COVID-19 who was successfully treated with a high-dose steroid.

Case Report

An 87-year-old asymptomatic woman was diagnosed with COVID-19 by transcription polymerase chain reaction (PCR). Three days later, she was admitted to our hospital to

¹Department of Respiratory Medicine, Nagoya University Graduate School of Medicine, Japan, ²Department of Internal Medicine, Aichi Prefectural Hospital, Japan, ³Department of Respiratory Medicine, Allergy and Clinical Immunology, Nagoya City University Graduate School of Medical Sciences, Japan, ⁴Department of Respiratory Medicine, Fujita Health University School of Medicine, Japan and ⁵Department of Respiratory Medicine and Allergology, Aichi Medical University, Japan

Received: June 17, 2021; Accepted: September 20, 2021; Advance Publication by J-STAGE: November 6, 2021

Correspondence to Dr. Norihito Omote, nori05692000@yahoo.co.jp

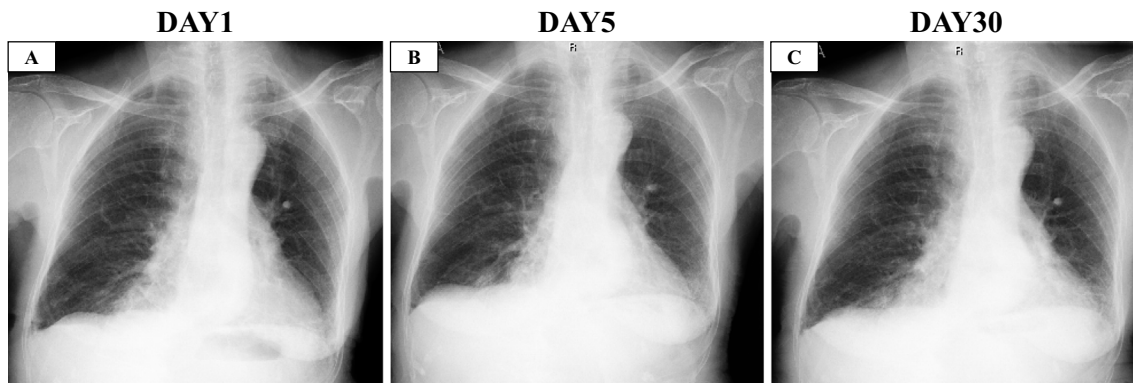


Figure 1. Chest X-ray images. A: On the day of admission to our hospital. B: On the day of the initiation of steroid therapy (five days after admission). C: Two weeks after the initiation of steroids.

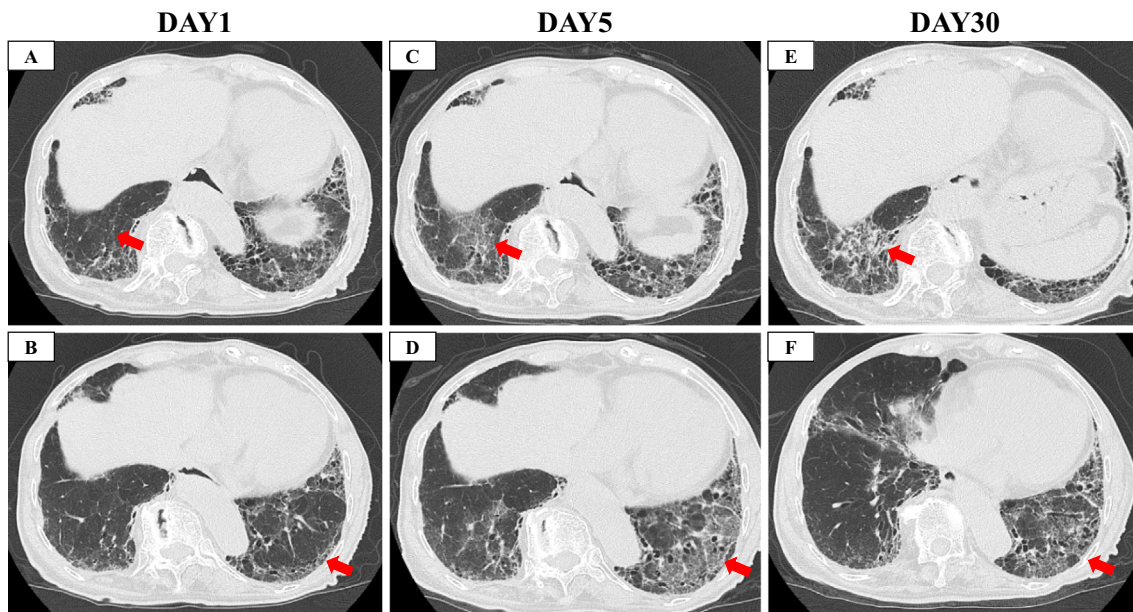


Figure 2. Computed tomography images. A, B: On the day of admission to our hospital. C, D: On the day of the initiation of steroid therapy (five days after admission). E, F: Two weeks after the initiation of steroids. Red arrows show newly observed ground-glass opacity (GGO), and red arrow heads show honeycomb.

quarantine her from her family. She had a cough and slightly worsening dyspnea without hypoxia (oxygen saturation of 98% on ambient air). There were no extra-thoracic manifestations suggesting the presence of an underlying connective tissue disease (CTD). Routine blood tests showed a white blood cell count of 2,880/mm³, C-reactive protein of 0.09 mg/dL, lactate dehydrogenase 204 U/mL, D-dimer 1.8 µg/mL, KL-6 370 U/mL, ferritin 106.7 ng/mL, and positivity for anti-SSA(Ro) antibody.

Chest X-ray and computed tomography (CT) showed bilateral ground-glass opacity (GGO) superimposed on a background reticular shadow and honeycomb in the bilateral lower lobes, suggesting the usual interstitial pneumonia pattern (Fig. 1A, 2A-B, 3A). Given these findings, we diagnosed her with AE-IPF triggered by COVID-19 and placed her on favipiravir from the first day of admission.

Five days later, she experienced hemoptysis, worsening of

dyspnea (without hypoxia), elevated D-dimer 4.3 µg/mL, and expansion of GGO on CT (Fig. 1B, 2C-D, 3B). Therefore, we decided to initiate intravenous high-dose steroids (methylprednisolone 250 mg/day for 3 days followed by methylprednisolone 1.0 mg/kg/day, total 40 mg/day). In addition, we switched her anti-viral therapy from favipiravir to remdesivir. With this treatment, the dyspnea and pulmonary infiltrate of the left lower lobe gradually improved (Fig. 1C, 2E-F, 3C). The systemic steroid was tapered from day 8 of steroid therapy initiation and discontinued entirely on day 32. Finally, she was discharged from our hospital on day 34 without severe disability.

Discussion

We successfully treated a patient with AE-IPF triggered by COVID-19 with high-dose steroids. The recent guidelines

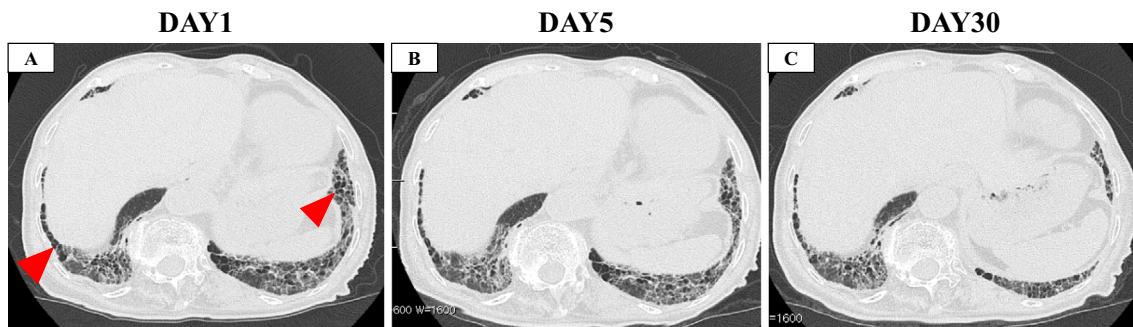


Figure 3. Computed tomography images. **A:** On the day of admission to our hospital. **B:** On the day of the initiation of steroid therapy (five days after admission). **C:** Two weeks after the initiation of steroids. Red arrows show newly observed ground-glass opacity (GGO), and red arrow heads show honeycomb.

concerning the management of patients with COVID-19 recommend the short-term use of low dose steroids (e.g. dexamethasone 6.0 mg for 10 days) based on the recovery study (1, 9, 10). However, the optimum dose and duration of steroid therapy, especially in high-risk groups, including those with IPF, remain unclear.

A recent study reported that high-dose steroids (methylprednisone 250 mg/day for 3 days) was a viable treatment option for severe COVID-19 (11). Kitayama et al. also reported a case of COVID-19 pneumonia resembling an AE-ILD rescued by steroid pulse therapy (12). Both patients with COVID-19 and IPF are exposed to hyperinflammatory states with elevated levels of cytokines, including interleukin 6 (IL-6) (13-15). Furthermore, high-dose steroids, including pulse therapy, are often used to manage AE-IPF (16, 17). These data imply that AE-IPF triggered by COVID-19 may need higher doses of steroids to suppress the disease activity than those with idiopathic and other triggers. Although the optimal duration of maintenance steroid therapy in AE-IPF is unclear, we terminated steroid therapy on day 32. This is because our patient was elderly, so we were concerned about adverse events with long-term maintenance steroid therapy. In addition, most studies have applied a short-term protocol of steroid therapy (3-10 days) for severe COVID-19 patients (1, 2, 11). In contrast, the Japanese guideline for the treatment of IPF suggests long-term maintenance of steroid therapy after an AE event (17). Further evidence is needed to answer clinical questions concerning maintenance steroid therapy in AE-IPF triggered by COVID-19.

The present patient met the diagnostic criteria for AE-IPF, and an AE event was triggered by COVID-19 (8). Previous studies have suggested that some cases of AE-IPF are induced by viral infections (18, 19). Song et al. noted no marked differences in the prognosis between patients with “idiopathic” AE and those whose condition was triggered by infection (20). In contrast, Kondoh et al. reported that AE-ILD triggered by COVID-19 had a worse prognosis than that triggered by other causes (21). Furthermore, Drake et al. reported that patients with COVID-19 with preexisting ILD had a significantly higher mortality than those without

ILD (5). These data indicate that AE-IPF triggered by COVID-19 results in greater disease severity than idiopathic and other infection-triggered AE-IPF. Although the 90-day mortality rate of AE-ILD triggered by COVID-19 is especially high (75%), our patient recovered without severe disability with steroid pulse therapy from the early stage of the disease onset (21). These findings suggest that the early initiation of intensive treatment, including pulse steroid therapy, may be beneficial for patients with AE-IPF triggered by COVID-19.

In summary, we reported a patient with AE-IPF triggered by COVID-19 successfully treated with high-dose steroids. Both patients with COVID-19 and IPF are exposed to hyperinflammatory states. Therefore, high-dose steroids can be a useful treatment option for AE-IPF triggered by COVID-19 to control disease activity.

Written informed consent was obtained from the patient for the publication of this case report and any accompanying images

The authors state that they have no Conflict of Interest (COI).

References

1. Horby P, Lim WS, Emberson JR, et al.; RECOVERY Collaborative Group. Dexamethasone in hospitalized patients with COVID-19. *N Engl J Med* **384**: 693-704, 2021.
2. Sterne JAC, Murthy S, Diaz JV, et al.; The WHO Rapid Evidence Appraisal for COVID-19 Therapies (REACT) Working Group. Association between administration of systemic corticosteroids and mortality among critically ill patients with COVID-19: a meta-analysis. *JAMA* **324**: 1330-1341, 2020.
3. Grasselli G, Greco M, Zanella A, et al. Risk factors associated with mortality among patients with COVID-19 in intensive care units in Lombardy, Italy. *JAMA Intern Med* **180**: 1345-1355, 2020.
4. Ioannou GN, Locke E, Green P, et al. Risk factors for hospitalization, mechanical ventilation, or death among 10131 US veterans with SARS-CoV-2 infection. *JAMA Netw Open* **3**: e2022310, 2020.
5. Drake TM, Docherty AB, Harrison EM, et al. Outcome of hospitalization for COVID-19 in patients with interstitial lung disease.

- An international multicenter study. *Am J Respir Crit Care Med* **202**: 1656-1665, 2020.
6. Collard HR, Moore BB, Flaherty KR, Brown KK, Kaner RJ, King TE Jr, et al. Acute exacerbations of idiopathic pulmonary fibrosis. *Am J Respir Crit Care Med* **176**: 636-643, 2007.
 7. Kondoh Y, Taniguchi H, Kawabata Y, Yokoi T, Suzuki K, Takagi K. Acute exacerbation in idiopathic pulmonary fibrosis. Analysis of clinical and pathologic findings in three cases. *Chest* **103**: 1808-1812, 1993.
 8. Collard HR, Ryerson CJ, Corte TJ, et al. Acute exacerbation of idiopathic pulmonary fibrosis. An international working group report. *Am J Respir Crit Care Med* **194**: 265-275, 2016.
 9. National Institutes of Health. Coronavirus disease 2019 (COVID-19) treatment guideline [Internet]. [cited 2020 Feb 18]. Available from: <https://www.covid19treatmentguidelines.nih.gov/>.
 10. Bhimraj A, Morgan RL, Shumaker AH, et al. Infectious Diseases Society of America guidelines on the treatment and management of patients with COVID-19. *Clin Infect Dis*. Forthcoming.
 11. Edalatfard M, Akhtari M, Salehi M, et al. Intravenous methylprednisolone pulse as a treatment for hospitalised severe COVID 19 patients results from a randomised controlled clinical trial. *Eur Respir J* **56**: 2002808, 2020.
 12. Kitayama T, Kitamura H, Hagiwara E, et al. COVID-19 pneumonia resembling an acute exacerbation of interstitial pneumonia. *Intern Med* **59**: 3207-3211, 2020.
 13. Webb BJ, Peltan ID, Jensen P, et al. Clinical criteria for COVID-19-associated hyperinflammatory syndrome: a cohort study. *Lancet Rheumatol* **2**: e754-e763, 2020.
 14. Lee JH, Jang JH, Park JH, et al. The role of interleukin-6 as a prognostic biomarker for predicting acute exacerbation in interstitial lung diseases. *PLoS One* **16**: e0255365, 2021.
 15. Arai TMH, Hirose M, Kida H, et al. Prognostic significance of serum cytokines during acute exacerbation of idiopathic interstitial pneumonias treated with thrombomodulin. *BMJ Open Respir Res* **8**: e000889, 2021.
 16. Kim DS, Park JH, Park BK, Lee JS, Nicholson AG, Colby T. Acute exacerbation of idiopathic pulmonary fibrosis: frequency and clinical features. *Eur Respir J* **27**: 143-150, 2006.
 17. Homma S, Bando M, Azuma A, et al. Japanese guideline for the treatment of idiopathic pulmonary fibrosis. *Respir Investig* **56**: 268-291, 2018.
 18. Wootton SC, Kim DS, Kondoh Y, et al. Viral infection in acute exacerbation of idiopathic pulmonary fibrosis. *Am J Respir Crit Care Med* **183**: 1698-1702, 2011.
 19. On R, Matsumoto T, Kushima H, Hirano R, Fujita M. Prevalence of viral infection in acute exacerbation of interstitial lung diseases in Japan. *Respir Investig* **58**: 473-478, 2020.
 20. Song JW, Hong SB, Lim CM, Koh Y, Kim DS. Acute exacerbation of idiopathic pulmonary fibrosis: incidence, risk factors and outcome. *Eur Respir J* **37**: 356-363, 2011.
 21. Kondoh Y, Kataoka K, Ando M, et al. COVID-19 and acute exacerbation of interstitial lung disease. *Respir Investig* **59**: 675-678, 2021.

The Internal Medicine is an Open Access journal distributed under the Creative Commons Attribution-NonCommercial-NoDerivatives 4.0 International License. To view the details of this license, please visit (<https://creativecommons.org/licenses/by-nc-nd/4.0/>).