



## CASE REPORT

# REVISED Case Report: Accidental firearm injury during trophy hunting and the role of paramedics in managing such cases at rural health posts in Nepal [version 2; peer review: 2 approved, 1 approved with reservations]

Previously titled: Case Report: Accidental firearm fatality during trophy hunting in Nepal

Alok Atreya <sup>1</sup>, Samata Nepal <sup>1</sup>, Ashal Timalisina<sup>1</sup>, Geeta Bashyal <sup>2</sup>, Lokaratna Gyawali <sup>2</sup>, Jenash Acharya <sup>3</sup>

<sup>1</sup>Lumbini Medical College, Palpa, Lumbini, 32500, Nepal

<sup>2</sup>District Hospital, Palpa, Lumbini, 32500, Nepal

<sup>3</sup>Kathmandu Medical College Teaching Hospital, Kathmandu, Bagmati, 44600, Nepal

**V2** First published: 06 Sep 2021, 10:893  
<https://doi.org/10.12688/f1000research.55659.1>

Latest published: 04 Mar 2022, 10:893  
<https://doi.org/10.12688/f1000research.55659.2>

## Abstract






Possession of a firearm without a certified valid license is against Nepalese law. Following a decade-long civil war, Nepal government issued stringent laws not allowing public to possess firearms without a valid reason, despite bearing a license. However, there are people who possess and use firearms for hunting purposes. The present case reports an accidental death of a teenage boy who used a musket for hunting. The present case highlights the fact that despite these stringent laws, illegal possession of arms for trophy hunting is still prevalent in rural Nepal. Furthermore, this study aims to highlight the importance of paramedics in early intervention, stabilization and transport of the sick and injured to the hospital in emergency situations. Also, recruitment of paramedics in the ambulance service might have prevented untimely death in this particular case.



## Keywords

Accidental injuries; wounds, gunshot; wounds, penetrating

## Open Peer Review

Approval Status   

	1	2	3
<b>version 2</b> (revision) 04 Mar 2022		 view	
<b>version 1</b> 06 Sep 2021	 view	  view	 view

1. **Vikash P. Meshram**, All India Institute of Medical Sciences, Jodhpur, India
2. **Gilbert Koome** , Mount Kenya University, Nairobi, Kenya
3. **Alessandro Leite Cavalcanti** , State University of Paraíba, Campina Grande, Brazil

Any reports and responses or comments on the article can be found at the end of the article.

**Corresponding author:** Alok Atreya ([alokraj67@hotmail.com](mailto:alokraj67@hotmail.com))

**Author roles:** **Atreya A:** Conceptualization, Writing – Original Draft Preparation, Writing – Review & Editing; **Nepal S:** Supervision, Writing – Review & Editing; **Timalsina A:** Writing – Original Draft Preparation; **Bashyal G:** Data Curation, Writing – Review & Editing; **Gyawali L:** Data Curation, Writing – Review & Editing; **Acharya J:** Supervision, Writing – Review & Editing

**Competing interests:** No competing interests were disclosed.

**Grant information:** The author(s) declared that no grants were involved in supporting this work.

**Copyright:** © 2022 Atreya A *et al.* This is an open access article distributed under the terms of the [Creative Commons Attribution License](#), which permits unrestricted use, distribution, and reproduction in any medium, provided the original work is properly cited.

**How to cite this article:** Atreya A, Nepal S, Timalsina A *et al.* **Case Report: Accidental firearm injury during trophy hunting and the role of paramedics in managing such cases at rural health posts in Nepal [version 2; peer review: 2 approved, 1 approved with reservations]** F1000Research 2022, 10:893 <https://doi.org/10.12688/f1000research.55659.2>

**First published:** 06 Sep 2021, 10:893 <https://doi.org/10.12688/f1000research.55659.1>

**REVISED Amendments from Version 1**

All the comments from the reviewers have been taken into account in the new revision. We have added epidemiological data of firearm injuries in the introduction. We have further discussed the role of paramedics in such situations in the context of Nepal. Some grammatical errors are also corrected in this version. The title was also amended.

**Any further responses from the reviewers can be found at the end of the article**

**Introduction**

Firearms are regarded as dangerous weapons in forensic practice. Firearm-related injuries are considered a major problem globally<sup>1</sup>. Annual firearm injury rate was 8.8/100000 population in Canada of which 5.5/100000 were unintentional among children and youths aged less than 24 years<sup>2</sup>. Possession of a firearm without a certified valid license is against Nepalese law. It is a cognizable offense to keep a firearm or ammunition. After a decade-long civil war in Nepal, amendments were made to the Arms and Ammunition Act 1962 (second amendment 2007), which included a clause that states: "Government of Nepal may, if it deems fit for the sake of public safety, give an order to withhold the arms or ammunition after having them seized anytime although anybody has a license to have in his/her possession the arms or ammunition". This rule came into effect immediately and the public were instructed to submit their firearms to the nearest police station. To control the civil war, the law was mandated for the public. However, there are still people who possess firearms in their homes<sup>3</sup>. Furthermore, hunting wild animals is cognizable offence in Nepal. Smuggling of hides and body parts of wildlife is a ludicrous business. Although the actual statistics are lacking in these regards, there have been cases of firearm injuries and fatalities as reported by Nepal police in their official webpage<sup>4</sup>. Nepalese police have further reported arrests made for possession of hides and body parts of wildlife<sup>4</sup>. Although illegal, the hunting of wild animals is quite common in rural Nepal, deer being the most highly prized trophy animal.

Nepal is a developing country in the south-east Asia region with a population of 29.1 million as per the census of 2021<sup>5</sup>. There are 28477 registered doctors in Nepal till December 31, 2020<sup>6</sup>. This country has 125 public hospitals, 196 primary health care centers (PHCC), and 3806 health posts (HP)<sup>7</sup>. Health posts are a first contact point for health services especially in the rural areas, however these HPs lack a doctor and are run by paramedics. The present case highlights the medical issue in which the ambulance service in rural Nepal lacks a paramedic. No intervention in the form of life support and prompt resuscitation is a reason for more lives lost on the way to the hospital.

**Case report****Circumstance**

During late January, a 13-year-old schoolboy from the Palpa district in Nepal planned hunting with four friends from the

neighborhood. They decided to sneak out after their supper late in the evening. Due to the cold winter weather, people in remote mountainous village of the Palpa district usually sleep at around 8 pm. The boys gathered at around 9 pm and geared up for the hunt. The 13-year-old schoolboy led the group carrying a musket. After entering the dense woods and climbing uphill they spotted a deer with their torch. The leading boy who brought the firearm fired a shot at the deer with the pre-loaded gun. Although the deer was hit, it managed to run away. Knowing that the deer was wounded, the boys thought the deer would not run far. They reloaded the musket and followed the injured animal. They had to leave the usual trail and ran down rough terrain. At one point there was a big drop with large, jagged rocks lying at the bottom (Figure 1). The boy carrying the gun handed it to the boy behind him and climbed down first. He was then passed the gun held at the muzzle end. After grasping the gun near the butt end with his right hand, he pulled the gun towards himself whilst trying to hold it near the mid-length with the left hand, however, there was a sudden slight thrust of the gun butt on a rock and the gun went off, shooting the boy.

The injured boy was rescued by the family members and the villagers within an hour of the incidence. He was then brought home. An ambulance was called, which arrived 45 minutes later to take him to the hospital, but before he could reach the hospital, he breathed his last breath the same night. In the present case, the patient was bleeding profusely through the wound on the chest. No intervention in the form of first-aid or basic life support was provided to the patient who died while being transported to the hospital.

For the validity of the statements made by the boys, police deployed a search team and found a dead male barking deer 400 m from the scene of the crime (Figure 2).



**Figure 1. Graphical illustration of the scene of the incident.**

## Autopsy

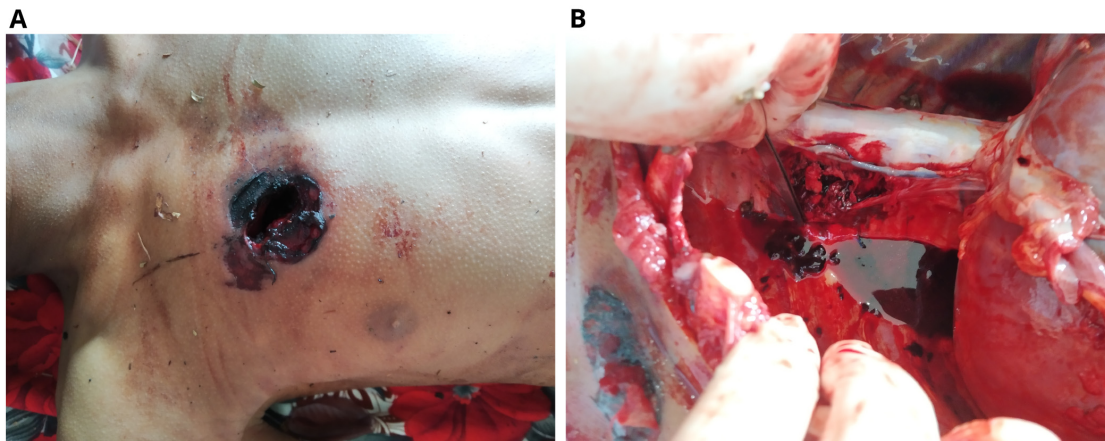
The dead body of a 13-year-old boy was brought for autopsy. The body was cold to touch and stiff at all joints. Postmortem lividity couldn't be seen on the back. There was an elliptical blackish laceration, suggestive of an entry wound of projectile, with abraded margin present over the right anterior chest having a maximum diameter of 3.5 cm (Figure 3). This wound was located 35 cm from the vertex, 108 cm from the heel of the right foot, 5 cm from the mid-sternal point in the midline, 7 cm from the sternal notch, and 13 cm from the mid-axillary line. There was a tattooing around the wound over an area of 7 x 5 cm. Following skin incision an oval wound was present over the right third intercostal space with a maximum diameter of 3 cm, the margin of which was burnt and black in color. There was contusion of surrounding intercostal muscles present. The right lung was collapsed with a laceration on the upper and middle lobes. The left lung appeared normal. The shot was lodged in between the fourth and fifth thoracic vertebrae on the right. There was no exit wound.

## Discussion

Paramedics are the experts who provide emergency medical care and stabilize the patient before and during transportation to tertiary care hospital for further management. However, in rural Nepal paramedic service is not available. Whenever an ambulance is called, it the ambulance driver who comes to receive the patient and then transports them to hospital. Due to the lack of first aid, stabilization, maintaining vitals and resuscitation in timely manner more sick and injured die on the way to hospital<sup>8</sup>. Prompt intervention using basic medical skills too can prolong survival and limit the complications. In high-income countries the role of paramedics has evolved to be competent to provide emergency medical services such as advance life support, acute presentations of mental illness and wide range of urgent-care presentations<sup>9</sup>. In the present case hemorrhage and collapsed right lung causing respiratory compromise contributed to death. Fluid resuscitation is a gold-standard strategy in early management of traumatic injury which involves loss of body fluid. In cases of severe bleeding,



**Figure 2.** Dead barking deer (A) and the gun used for hunting (B).



**Figure 3.** Entry wound in the front of the chest (A). The location of the shot in the thoracic spine (B).

blood transfusion should be done; in the absence or non-availability of blood, fluid replacement with crystalloids or colloids is an alternative<sup>10</sup>. In the present case had the paramedic secured an IV line and gave fluid, provided oxygen and had accompanied the patient till he reached the tertiary care, the outcome might had been different.

As per the 'Arms and Ammunition Act' of the Nepalese legislature, it is prohibited to possess or carry any type of arms and ammunition without proper license or contrary to the terms and conditions specified in the license. If anyone is found guilty, the offender can be arrested without a warrant, the arms and ammunition seized, and can be punished with three to five years of imprisonment and a fine ranging from 60 to 100,000 Nepalese rupees<sup>11</sup>.

Hunting of wildlife is prohibited in Nepal. If anyone wishes to hunt wildlife, an application is to be submitted to the concerned authority. All the details including the type of arms to be used, license number, licensing authority, and the number of hunters is to be mentioned. After evaluation of the application, the permit is issued with applicable fees. The type of animal that can be hunted, the number of animals that can be killed, and the method of hunting are specified in the permit<sup>12</sup>. Nepal is also one of the popular destinations for trophy hunting for international tourists. There are several packages for trophy hunting in Nepal for foreign nationals, the trophy animals being blue sheep and Himalayan thar<sup>13</sup>.

Most accidental gunshot injuries inflicted while hunting occur in the chest. The injuries are usually a result of a two-party accident and the victim is a relative or friend of the shooter<sup>14</sup>. Gun handling by children is a well-known risk factor for such unintentional accidents<sup>15</sup>. Young children residing in rural areas are the most affected group<sup>16</sup>.

The most common weapon responsible for accidental injuries is a shotgun and the shots are of close range<sup>14</sup>. Such shots are so dangerous that they cause extensive multisystem damage and produce long-term sequelae in survivors<sup>17</sup>.

A study in the US showed that unintentional firearm injuries most commonly involve a combination of home guns and the young male population. The study also suggested a majority of injuries could be prevented by avoiding children's access to guns<sup>18</sup>. Another study suggests keeping guns locked and

unloaded as a preventive measure<sup>19</sup>. Guns are usually recovered from the house of the victim, relative, or friend<sup>20</sup>. Those who acquire firearms are at increased risk of not only accidental but also suicidal deaths as a consequence of the impulsive act<sup>21</sup>.

## Conclusions

In the present case, a dead male barking deer was recovered. Shooting on target and precise knowledge of handling the musket and muzzle loading technique point towards the fact that the hunting activities were common in the family and neighborhood. Although the deceased's father said that he was not aware that his son had gone hunting, it is obvious that any of the four adolescent boys didn't take permission from their families for the hunting trip. Furthermore, a gun is not a toy or a souvenir to be kept open and within the reach of the children. The gun was kept illegally without a gun license. The gun law in Nepal is stringent, however, this case highlights the fact that the law is defied, and firearms are kept in possession for trophy hunting in rural mountains. Illegal activity has negative consequences sooner or later, in this case, it was a life lost.

The victim in the present case succumbed to death before he reached to the hospital. Monitoring of the vitals and providing basic life support would have prolonged the life of the victim in the present case. The authors also would like to bring to attention of the stake holders and policy makers on the issue in which the ambulance service in rural Nepal lack a paramedic. No intervention in the form of life support and prompt resuscitation is a reason for more life lost on the way to the hospital.

## Data availability

All data underlying the results are available as part of the article and no additional source data are required.

## Consent

Written informed consent for publication of their clinical details and/or clinical images was obtained from the deceased boy's father.

## Acknowledgements

The authors acknowledge Mr. Umesh Khanal for the graphical illustration of the scene of the incident.

## References

1. Puri P, Kumar Shukla S, Kumar Sarin R, et al.: **Celebratory firing leads to serious injuries - a case report.** *Med Leg J.* 2019; **87**(1): 41-44. [PubMed Abstract](#) | [Publisher Full Text](#)
2. Saunders NR, Moore Hepburn C, Huang A, et al.: **Firearm injury epidemiology in children and youth in Ontario, Canada: a population-based study.** *BMJ Open.* 2021; **11**(11): e053859. [PubMed Abstract](#) | [Publisher Full Text](#) | [Free Full Text](#)
3. Atreya A, Menezes RG, Timalisina A, et al.: **Case Report: Penetrating Thoracic Trauma by A Gunshot Involving the Heart [version 2; peer review: 2 approved].** *F1000Res.* 2021; **10**: 532. [PubMed Abstract](#) | [Publisher Full Text](#) | [Free Full Text](#)
4. **Nepal Police.** Accessed: August 25, 2021. [Reference Source](#)
5. **Central Bureau of Statistics, National Planning Commission, Government of Nepal.** Accessed: February 19, 2022. [Reference Source](#)
6. **Nepal Medical Council.** Accessed: February 19, 2022. [Reference Source](#)

7. **Annual Report- 2076/77 (2019/20).** Department of Health Services, Ministry of Health and Population, Government of Nepal. Accessed: February 19, 2022.  
[Reference Source](#)
8. Mock C, Lormand JD, Goosen J, *et al.*: **Guidelines for essential trauma care.** Geneva, World Health Organization, 2004; Accessed August 25, 2021.  
[Reference Source](#)
9. Eaton G, Wong G, Tierney S, *et al.*: **Understanding the role of the paramedic in primary care: a realist review.** *BMC Med.* 2021; **19**(1): 145.  
[PubMed Abstract](#) | [Publisher Full Text](#) | [Free Full Text](#)
10. Lewis SR, Pritchard MW, Evans DJ, *et al.*: **Colloids versus crystalloids for fluid resuscitation in critically ill people.** *Cochrane Database Syst Rev.* 2018; **8**(8): CD000567.  
[PubMed Abstract](#) | [Publisher Full Text](#) | [Free Full Text](#)
11. **Arms and Ammunition Act, 1962.** 2019; Accessed: February 15, 2021.  
[Reference Source](#)
12. **National Parks and Wildlife Conservation Rules, 2030.** 1974; Accessed: February 15, 2021.  
[Reference Source](#)
13. **Book your hunt.** Accessed: February 15, 2021.  
[Reference Source](#)
14. Carter GL: **Accidental firearm fatalities and injuries among recreational hunters.** *Ann Emerg Med.* 1989; **18**(4): 406-9.  
[PubMed Abstract](#) | [Publisher Full Text](#)
15. Fowler KA, Dahlberg LL, Haileyesus T, *et al.*: **Childhood firearm injuries in the United States.** *Pediatrics.* 2017; **140**(1): e20163486.  
[PubMed Abstract](#) | [Publisher Full Text](#) | [Free Full Text](#)
16. Choi PM, Dekonenko C, Aguayo P, *et al.*: **Pediatric firearm injuries: A Midwest experience.** *J Pediatr Surg.* 2020; **55**(10): 2140-3.  
[PubMed Abstract](#) | [Publisher Full Text](#)
17. Golladay ES, Murphy KE Jr, Wagner CW: **Shotgun injuries in pediatric patients.** *South Med J.* 1991; **84**(7): 886-8.  
[PubMed Abstract](#) | [Publisher Full Text](#)
18. Faulkenberry JG, Schaechter J: **Reporting on pediatric unintentional firearm injury--who's responsible.** *J Trauma Acute Care Surg.* 2015; **79**(3 Suppl 1): S2-8.  
[PubMed Abstract](#) | [Publisher Full Text](#)
19. Grossman DC, Mueller BA, Riedy C, *et al.*: **Gun storage practices and risk of youth suicide and unintentional firearm injuries.** *JAMA.* 2005; **293**(6): 707-14.  
[PubMed Abstract](#) | [Publisher Full Text](#)
20. Grossman DC, Reay DT, Baker SA: **Self-inflicted and unintentional firearm injuries among children and adolescents: the source of the firearm.** *Arch Pediatr Adolesc Med.* 1999; **153**(8): 875-8.  
[PubMed Abstract](#) | [Publisher Full Text](#)
21. Anestis MD, Daruwala S, Capron DW: **Firearm ownership, means safety, and suicidality.** *Suicide Life Threat Behav.* 2019; **49**(4): 1044-57.  
[PubMed Abstract](#) | [Publisher Full Text](#)

# Open Peer Review

Current Peer Review Status:   

---

## Version 2

Reviewer Report 07 March 2022

<https://doi.org/10.5256/f1000research.121535.r126278>

© 2022 Koome G. This is an open access peer review report distributed under the terms of the [Creative Commons Attribution License](#), which permits unrestricted use, distribution, and reproduction in any medium, provided the original work is properly cited.



**Gilbert Koome** 

Mount Kenya University, Nairobi, Kenya

Changes are incorporated.

**Competing Interests:** No competing interests were disclosed.

**Reviewer Expertise:** Public health and emergency care

**I confirm that I have read this submission and believe that I have an appropriate level of expertise to confirm that it is of an acceptable scientific standard.**

---

## Version 1

Reviewer Report 17 February 2022

<https://doi.org/10.5256/f1000research.59253.r123821>

© 2022 Leite Cavalcanti A. This is an open access peer review report distributed under the terms of the [Creative Commons Attribution License](#), which permits unrestricted use, distribution, and reproduction in any medium, provided the original work is properly cited.



**Alessandro Leite Cavalcanti** 

Department of Dentistry, School of Dentistry, State University of Paraíba, Campina Grande, Brazil

The manuscript is well written and presents a detailed case report of a hunting accident.

1) I am suggesting that the authors replace keywords with terms contained in MESH/PubMed. I even offer some suggestions:

- Wounds, Gunshot
- Accidental Injuries
- Wounds, Penetrating

2) Regarding the introduction, despite bringing relevant information, I would like to suggest to the authors that they include some epidemiological data on the prevalence of firearm accidents. It can be in Nepal or in another country.

**Is the background of the case's history and progression described in sufficient detail?**

Yes

**Are enough details provided of any physical examination and diagnostic tests, treatment given and outcomes?**

Yes

**Is sufficient discussion included of the importance of the findings and their relevance to future understanding of disease processes, diagnosis or treatment?**

Yes

**Is the case presented with sufficient detail to be useful for other practitioners?**

Yes

**Competing Interests:** No competing interests were disclosed.

**Reviewer Expertise:** Epidemiology and Public Health

**I confirm that I have read this submission and believe that I have an appropriate level of expertise to confirm that it is of an acceptable scientific standard, however I have significant reservations, as outlined above.**

Author Response 19 Feb 2022

**Alok Atreya**, Lumbini Medical College, Palpa, Nepal

*We wish to thank you all for your constructive comments in this review. Your comments provided valuable insights to refine its contents.*

The manuscript is well written and presents a detailed case report of a hunting accident.

1) I am suggesting that the authors replace keywords with terms contained in MESH/PubMed. I even offer some suggestions:

- Wounds, Gunshot
- Accidental Injuries
- Wounds, Penetrating

*Response: The keywords are replaced as suggested.*

2) Regarding the introduction, despite bringing relevant information, I would like to suggest to the authors that they include some epidemiological data on the prevalence of firearm



accidents. It can be in Nepal or in another country.

*Response: As the prevalence of firearm accidents from Nepal is lacking we did include the prevalence of such accidents from Canada.*

**Competing Interests:** We do not have any competing interests to disclose.

Reviewer Report 09 February 2022

<https://doi.org/10.5256/f1000research.59253.r121895>

© 2022 Koome G. This is an open access peer review report distributed under the terms of the [Creative Commons Attribution License](#), which permits unrestricted use, distribution, and reproduction in any medium, provided the original work is properly cited.



**Gilbert Koome** 

Mount Kenya University, Nairobi, Kenya

While the case doesn't present new knowledge in the field, it offers valuable insight on accidental fire-arm fatality in Nepal while underscoring possible driving factors for the potentially avoidable fatality. While the article makes a strong case for strengthening access to EMS at the prehospital care, the following aspects can be added or improved:

**Title** – The authors have substantially incorporated information around access to paramedic or EMS as gap and driver for the avoidable fatality from firearm accident. These aspects can be captured in the title of the article.

**Background** - The information is relevant and concise. However, it fails to provide a good picture of the EMS in Nepal, especially at the prehospital level or out of hospital settings in which this case study happened. This literature can be captured to provide a logical link to the discussions and conclusion that ensues around this issue.

**Findings and Discussions** - It would have been more valuable to add information on what led to the fatality in this case to help build the case for EMS or paramedics. In other words, based on autopsy findings, what led to death such as Exsanguination or combination of various factors? What role could EMS or paramedics play in avoiding this case fatality in respect to their professional roles?

**Conclusion:** Review and align with the key findings especially on the aspect of EMS which has been alluded to. The conclusion also fails to make a logical conclusion on the accidental firearm fatality and possible reasons, instead, it provides additional information around the case (both contextual information such as illegality of owning a firearm without license, defiance to law, parental law in safeguarding children safety etc).

**Is the background of the case's history and progression described in sufficient detail?**

Partly

**Are enough details provided of any physical examination and diagnostic tests, treatment given and outcomes?**

Partly

**Is sufficient discussion included of the importance of the findings and their relevance to future understanding of disease processes, diagnosis or treatment?**

Partly

**Is the case presented with sufficient detail to be useful for other practitioners?**

Partly

**Competing Interests:** No competing interests were disclosed.

**Reviewer Expertise:** Public health and emergency care

**I confirm that I have read this submission and believe that I have an appropriate level of expertise to confirm that it is of an acceptable scientific standard, however I have significant reservations, as outlined above.**

Author Response 19 Feb 2022

**Alok Atreya**, Lumbini Medical College, Palpa, Nepal

We wish to thank you all for your constructive comments in this review. Your comments provided valuable insights to refine its contents.

Comments: While the case doesn't present new knowledge in the field, it offers valuable insight on accidental fire-arm fatality in Nepal while underscoring possible driving factors for the potentially avoidable fatality. While the article makes a strong case for strengthening access to EMS at the prehospital care, the following aspects can be added or improved.

**Title** - The authors have substantially incorporated information around access to paramedic or

EMS as gap and driver for the avoidable fatality from firearm accident. These aspects can be captured in the title of the article.

*Response: The title has been changed.*

**Background** - The information is relevant and concise. However, it fails to provide a good picture

of the EMS in Nepal, especially at the prehospital level or out of hospital settings in which this case

study happened. This literature can be captured to provide a logical link to the discussions and

conclusion that ensues around this issue.

*Response: The information is incorporated.*

**Findings and Discussions** - It would have been more valuable to add information on what led to the fatality in this case to help build the case for EMS or paramedics. In other words, based on autopsy findings, what led to death such as Exsanguination or combination of various factors? What role could EMS or paramedics play in avoiding this case fatality in respect to their professional roles?  
*Response: We have added the probable cause of death and have discussed the role of paramedics in managing such cases.*

**Conclusion:** Review and align with the key findings especially on the aspect of EMS which has been alluded to. The conclusion also fails to make a logical conclusion on the accidental firearm fatality and possible reasons, instead, it provides additional information around the case (both contextual information such as illegality of owning a firearm without license, defiance to law, parental law in safeguarding children safety etc).  
*Response: We have now incorporated the findings on the aspect of EMS.*

**Competing Interests:** We do not have any competing interests to disclose.

Reviewer Report 20 September 2021

<https://doi.org/10.5256/f1000research.59253.r94127>

© 2021 Meshram V. This is an open access peer review report distributed under the terms of the [Creative Commons Attribution License](#), which permits unrestricted use, distribution, and reproduction in any medium, provided the original work is properly cited.



**Vikash P. Meshram**

Department of Forensic Medicine and Toxicology, All India Institute of Medical Sciences, Jodhpur, Rajasthan, India

This article describes the circumstances of accidental firearm fatality involving a schoolboy with an illegal firearm, despite stringent Arms and Ammunition laws in Nepal. The authors have emphasized the need for the mandatory presence of medical personnel in the ambulance and the significance of emergency care in a golden hour. Overall, the article is well written. Graphical representation nicely depicts the circumstances of the incident. Information about the examination of clothes, cause of death and a possible range of the firearm injury are to be added in the manuscript. 'Emergency care' can be added in the keywords. Please clarify about the presence of tattooing in the injury. I could appreciate sparsely visible tattooing in the left upper part of the injury. The article can be approved for indexing after minor revision.

**Is the background of the case's history and progression described in sufficient detail?**

Yes

**Are enough details provided of any physical examination and diagnostic tests, treatment given and outcomes?**

Yes

**Is sufficient discussion included of the importance of the findings and their relevance to future understanding of disease processes, diagnosis or treatment?**

Yes

**Is the case presented with sufficient detail to be useful for other practitioners?**

Yes

**Competing Interests:** No competing interests were disclosed.

**Reviewer Expertise:** Forensic Pathology, Sexual Jurisprudence, Forensic Anthropology, Clinical Forensic Medicine, Toxicology

**I confirm that I have read this submission and believe that I have an appropriate level of expertise to confirm that it is of an acceptable scientific standard.**

Author Response 19 Feb 2022

**Alok Atreya**, Lumbini Medical College, Palpa, Nepal

We wish to thank you all for your constructive comments in this review. Your comments provided valuable insights to refine its contents.

**Competing Interests:** We do not have any competing interests to disclose.

The benefits of publishing with F1000Research:

- Your article is published within days, with no editorial bias
- You can publish traditional articles, null/negative results, case reports, data notes and more
- The peer review process is transparent and collaborative
- Your article is indexed in PubMed after passing peer review
- Dedicated customer support at every stage

For pre-submission enquiries, contact [research@f1000.com](mailto:research@f1000.com)

**F1000Research**