

# Isolated cutaneous *Pseudallescheria boydii* abscess in an immunocompetent man



Connor J. Stonesifer, BA,<sup>a</sup> Alexandra E. Khaleel, BA,<sup>a</sup> Tiffany J. Garcia-Saleem, MD,<sup>b</sup> Sameera Husain, MD,<sup>b</sup> and Larisa J. Geskin, MD<sup>b</sup>  
*New York, New York*

**Key words:** abscess; antifungal; fungus; immunocompetent; infection; infectious disease; mycology; *Pseudallescheria boydii*; therapy.

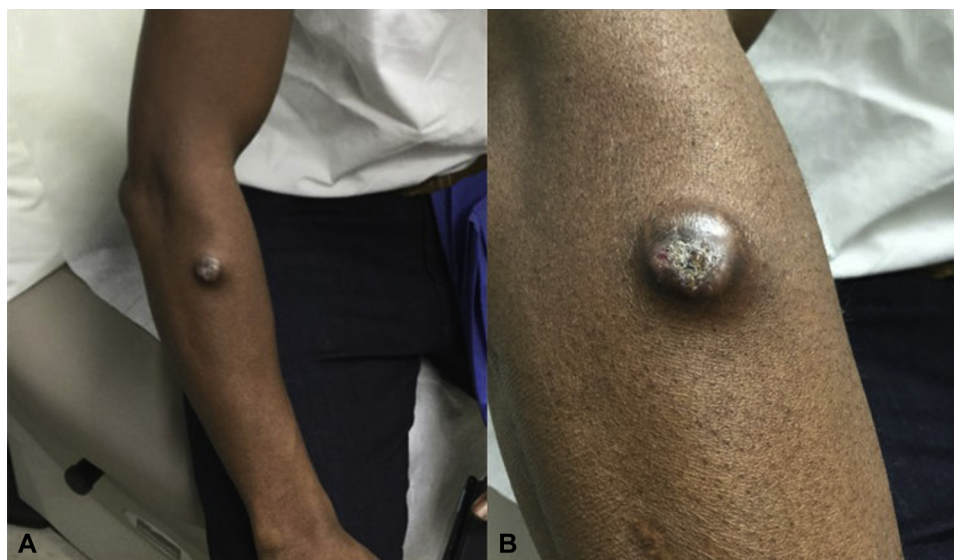## INTRODUCTION

*Pseudallescheria boydii* is increasingly recognized as a source of infection in the immunocompromised. It has rarely been reported as a pathogen in immunocompetent patients, especially as a single cutaneous abscess. We present the case of a solitary *P boydii* abscess presenting in an immunocompetent man.

## CASE REPORT

A 51-year-old man presented to the Columbia University Irving Medical Center in January 2021 for

evaluation of an abscess on his right forearm. One year before presentation, he had cut his forearm while cleaning a broken fluorescent light bulb. The lacerated area initially healed without cause for concern, but over the following 6 months, the patient noticed that the affected area beneath the involved area began to swell, elicit pain when palpated, and express purulent discharge. In January 2021, he visited a local dermatologist, who cultured the abscess, revealing *P boydii* species complex. He was then referred to the



**Fig 1.** **A**, Clinical photograph of the indurated pustular nodule with a central, crusted ulcer. **B**, Closer view of the same image.

From the Columbia University Vagelos College of Physicians and Surgeons, New York<sup>a</sup> and Department of Dermatology, Columbia University Irving Medical Center, New York.<sup>b</sup>

Funding sources: None.

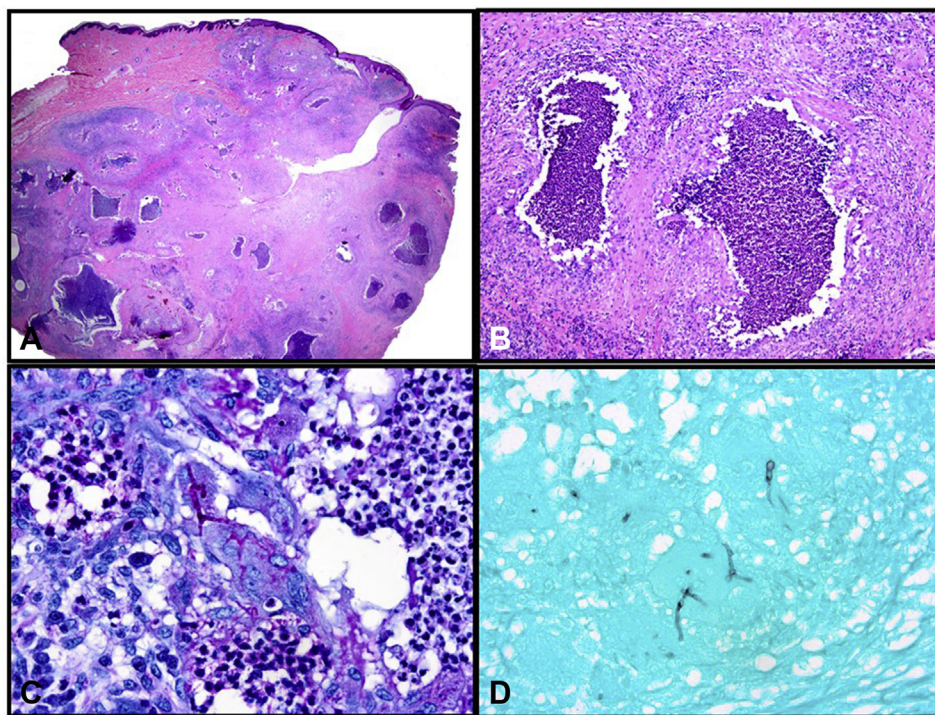
IRB approval status: Not applicable.

Correspondence to: Larisa J. Geskin, MD, Department of Dermatology, Herbert Irving Pavilion, 12th Floor, 161 Fort Washington Avenue, New York, NY 10032. E-mail: [ljpg2145@cumc.columbia.edu](mailto:ljpg2145@cumc.columbia.edu).

JAAD Case Reports 2022;21:160-4.  
 2352-5126

© 2022 Published by Elsevier on behalf of the American Academy of Dermatology, Inc. This is an open access article under the CC BY-NC-ND license (<http://creativecommons.org/licenses/by-nc-nd/4.0/>).

<https://doi.org/10.1016/j.jidcr.2021.12.034>



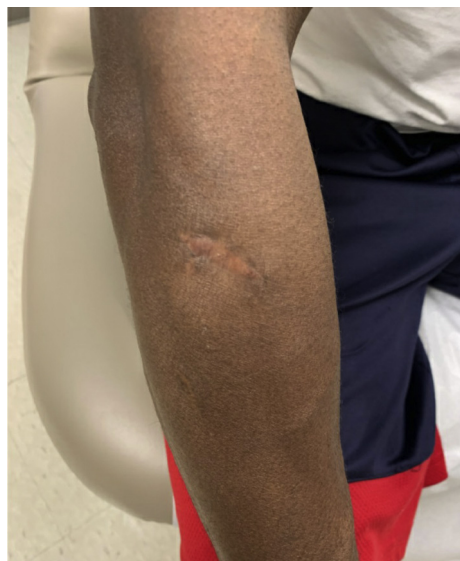**Fig 2.** Histologic section of the biopsy specimen showing (A) a mostly dermal-based nodule (hematoxylin-eosin stain; original magnification:  $\times 10.25$ ) composed of (B) multifocal neutrophilic aggregates and a mixed inflammatory infiltrate (hematoxylin-eosin stain; original magnification:  $\times 100$ ). (C) Periodic acid–Schiff and (D) Gomori methenamine silver stains show septate fungal hyphae with acute angle branching (original magnification:  $\times 400$ ).

Columbia University Irving Medical Center for further evaluation.

On presentation 3 weeks later, the patient reported that the nodule on his right forearm had continued to increase in size and express pus. The patient was a healthy male without a significant past medical history, including immunosuppressive conditions, and was not taking any immunosuppressive medications. He also denied a history of unusual environmental exposures, intravenous drug use, or recurrent infections. He denied fever, chills, night sweats, or recent weight loss; a complete metabolic panel and a complete blood cell count with differential were within normal limits. HIV qualitative polymerase chain reaction testing was negative.

Palpation of the right forearm revealed a 3.5 cm  $\times$  3.5 cm indurated nodule with central ulceration and purulent discharge (Fig 1, A and B). No other lesions were observed, and no lymphadenopathy was detected on examination. Wound cultures of the lesion grew *P boydii* species complex.

Excisional biopsy of the lesion on hematoxylin-eosin–stained histologic sections revealed a predominantly dermal-based nodule (Fig 2, A) composed of multifocal collections of neutrophils (Fig 2, B)



**Fig 3.** Clinical photograph of the affected area after 3 months of voriconazole therapy with only residual scarring at the site of the prior excision.

surrounded by epithelioid and multinucleated histiocytes, lymphocytes, plasma cells, and eosinophils. Periodic acid–Schiff (Fig 2, C) and Gomori

**Table I.** Primary Cutaneous Presentations of *P boydii* in Immunocompetent Patients

Age/Sex	Clinical Diagnosis	Immune Status	Clinical Features	Microbiologic Diagnosis	Therapy	Outcome
35 M	<i>P boydii</i> mycetoma with co-occurring <i>Madurella grisea</i> mycetoma	No significant past medical history Normal CBC with differential Normal immunoglobulin levels Normal CD4, CD8 cell counts HIV negative	8 cm × 5 cm firm, nonfluctuant, nontender nodule on right anterolateral ankle for months (exact number unknown) 6 cm × 5 cm nontender nodule on dorsal aspect of right hand for 8-10 mo	Ankle lesion: <i>P boydii</i> / <i>Scedosporium apiospermum</i> complex ( <i>S. apiospermum sensu stricto</i> ) Hand lesion: <i>Madurella grisea</i>	Voriconazole (dosing not provided) for 6 mo	Complete resolution of the <i>Scedosporium</i> ankle lesion; minimal improvement of <i>Madurella</i> hand lesion
25 F	<i>Scedosporium apiospermum</i> lymphadenitis	No significant past medical history Normal CBC with differential Normal lymphocyte subsets (T cells, B cells, and NK cells) Normal immunoglobulin and complement levels Normal phagocytic activity and burst activity of neutrophils and monocytes	Mobile and nontender lymph nodes (0.5-2 cm) in the anterior and posterior cervical chains for 10 y; posttraumatic scar on right hemiface secondary to laceration 12 y prior	<i>Scedosporium apiospermum</i>	Itraconazole, 200 mg 3 times daily for 1 y	Complete resolution after 1 y
73 F	<i>P angusta</i> soft tissue infection	No significant past medical history Additional labs not reported	Multiple painful 1- to 3-mm erythematous papulopustules on the dorsum of the left hand for 4 mo	<i>P angusta</i>	Oral itraconazole 200 mg/day for 4 wk with transition to oral voriconazole 400 mg/day for 3 mo	Slight improvement after oral itraconazole Complete resolution after 3 mo of oral voriconazole
16 M	Multiple subcutaneous mycetomas	No significant past medical history CBC with mild anemia, mild leukocytosis (WBC 13), and mild eosinophilia Normal bone marrow aspirate	Numerous subcutaneous nodules involving the neck, trunk, arms, and thighs ranging from 2 to 15 cm for 8 y	<i>P boydii</i> / <i>Scedosporium apiospermum</i> complex (no speciation reported)	Initially treated with oral itraconazole with periodic needle aspirations for 4 wk Switched to potassium iodide saturated solution 1 mL 3 times a day, subsequently increased to 6 mL each dose due to financial difficulties	Complete resolution of lesions after 2 y

58 M	<i>P boydii</i> / <i>Scedosporium apiospermum</i> species complex and <i>Neisseria</i> spp. soft tissue infection of the forearm	No significant past medical history Normal CBC	Numerous pustules and woody induration of left forearm for 5 y following dog bite	<i>P boydii</i> / <i>Scedosporium apiospermum</i> complex <i>Neisseria</i> spp.	Oral voriconazole 200 mg twice daily for 6 mo Amoxicillin/clavulanate for 6 wk	Significant improvement after 6 mo
------	--	---	---	--	---	------------------------------------

CBC, Complete blood cell count; NK, natural killer; WBC, white blood cell.

methenamine silver (Fig 2, D) stains showed several septate fungal hyphae with acute angle branching, resembling *Aspergillus* spp. Gram stain was negative for bacteria. Fite stain was negative for acid-fast bacilli.

The patient was treated with wide local excision of the abscess and prescribed voriconazole 300 mg twice a day. The patient delayed initiation of voriconazole for 2 months, during which time small papules developed along the scar that were concerning for recurrent infection. He subsequently completed 3 months of voriconazole therapy. At the time of last follow-up, the area had healed well and showed no signs of recurrent infection (Fig 3).

### DISCUSSION

*P boydii* is a ubiquitous saprobic fungus known to grow in saltwater, sewage, soil, swamps, coastal tidelands, poultry manure, cattle manure, and bat feces.<sup>1</sup> *P boydii* thrives in environments high in agricultural and industrial pollution, as the species is able to use nitrogen-containing compounds, such as fertilizers, and aromatic hydrocarbons found in oil and gas as nutrient sources.<sup>2</sup> *P boydii* is the name of the teleomorph, or sexual state, of the fungal species, and *Scedosporium apiospermum* describes its anamorph, or asexual state.<sup>1,2</sup> Although the names are interchangeable, *P boydii* commonly takes precedence in clinical descriptions.

*P boydii* is an opportunistic pathogen, responsible for a wide variety of clinical presentations. *P boydii* has become an increasingly recognized source of life-threatening infections in immunocompromised hosts with a high risk of progressing to disseminated disease.<sup>1</sup> Cases of septic arthritis, endocarditis, and meningoencephalitis, among many other infectious complications, have been reported in immunocompromised individuals.<sup>1</sup> Infection in immunocompetent patients is rare. The classic pathology attributed to *P boydii* in immunocompetent patients is mycetoma, a chronic, granulomatous infection of subcutaneous tissues and contiguous bone characterized by suppurative sinus tracts and expression of fungal “grains” representing organized mycelial aggregates.<sup>3,4</sup> Pneumonia, bone and joint infections, otitis media, otitis externa, keratitis, endophthalmitis, and brain abscesses have also been reported in immunocompetent patients.<sup>1,5</sup> Primary cutaneous infections in immunocompetent patients have been infrequently reported in the literature. A literature review of existing cases is presented in Table I.<sup>6-10</sup> In the currently reported case, the infection was isolated to a single abscess on the forearm of an immunocompetent host, which lacked the typical grains seen in *P boydii* mycetoma.

*P boydii* infection requires extended treatment, with some patients requiring years of antifungal therapy

due to frequent recurrence. Recent DNA studies have shown that *P boydii* is likely not a single species but rather a “species complex” including at least 6 known species (*P boydii*, *P angusta*, *P ellipsoidea*, *P fusioidea*, *P minutispora*, and *Scedosporium aurantiacum*) and 2 recently reported species (*P minutispora* and *S aurantiacum*).<sup>11,12</sup> This phylogenetic diversity may explain the difficulty in treating these infections. Gilgado et al<sup>11</sup> tested 84 isolates belonging to 8 species that constitute the *P boydii* species complex against 11 antifungal agents. Among the antifungal agents tested, voriconazole had a fungicidal effect in the most species.<sup>11</sup> A long course (at least 3 months) is usually required due to the recalcitrant nature of the infection.

This report highlights a rare case in which *P boydii* presented as a solitary abscess on the right forearm of an immunocompetent man. This underscores the need to maintain a broad differential diagnosis and to include deep fungal infections in the assessment of nodules associated with transcutaneous trauma. In addition to a routine workup, including biopsy and bacterial cultures, fungal cultures should always be considered. Sensitivity testing is important, as *P boydii* may be resistant to numerous antifungal agents due to the organismal diversity of the *P* species complex. Treatment requires aggressive management with debridement and long-term antifungal therapy.

#### Conflicts of interest

None disclosed.

#### REFERENCES

1. Cortez KJ, Roilides E, Quiroz-Telles F, et al. Infections caused by *Scedosporium* spp. *Clin Microbiol Rev*. 2008;21(1):157-197.
2. Guarro J, Kantarcioglu AS, Horré R, et al. *Scedosporium apiospermum*: changing clinical spectrum of a therapy-refractory opportunist. *Med Mycol*. 2006;44(4):295-327.
3. Lichon V, Khachemoune A. Mycetoma : a review. *Am J Clin Dermatol*. 2006;7(5):315-321.
4. Horré R, Schumacher G, Marklein G, et al. Mycetoma due to *Pseudallescheria boydii* and co-isolation of *Nocardia abscessus* in a patient injured in road accident. *Med Mycol*. 2002;40(5):525-527.
5. Bhally HS, Shields C, Lin SY, Merz WG. Otitis caused by *Scedosporium apiospermum* in an immunocompetent child. *Int J Pediatr Otorhinolaryngol*. 2004;68(7):975-978.
6. Gulati V, Bakare S, Tibrewal S, Ismail N, Sayani J, Baghla DPS. A rare presentation of concurrent *Scedosporium apiospermum* and *Madurella grisea* eumycetoma in an immunocompetent host. *Case Rep Pathol*. 2012;2012:154201.
7. Kiraz N, Gülbaz Z, Akgün Y, Ö Uzun. Lymphadenitis caused by *Scedosporium apiospermum* in an immunocompetent patient. *Clin Infect Dis*. 2001;32(3):e59-e61.
8. Choi H, Kim YI, Na CH, Kim MS, Shin BS. Primary cutaneous *Pseudallescheria angusta* infection successfully treated with voriconazole in an immunocompetent patient. *J Dermatol*. 2019;46(11):e420-e421.
9. Khan FA, Hashmi S, Sarwari AR. Multiple subcutaneous mycetomas caused by *Pseudallescheria boydii*: response to therapy with oral potassium iodide solution. *J Infect*. 2010;60(2):178-181.
10. Kollu VS, Auerbach J, Ritter AS. Soft tissue infection of the forearm with *Scedosporium apiospermum* complex and *Neisseria* spp. following a dog bite. *Cureus*. 2021;13(3):e14140.
11. Gilgado F, Serena C, Cano J, Gené J, Guarro J. Antifungal susceptibilities of the species of the *Pseudallescheria boydii* complex. *Antimicrob Agents Chemother*. 2006;50(12):4211-4213.
12. Gilgado F, Cano J, Gené J, Guarro J. Molecular phylogeny of the *Pseudallescheria boydii* species complex: proposal of two new species. *J Clin Microbiol*. 2005;43(10):4930-4942.