

ADC Histogram Analysis of Pediatric Low-Grade Glioma Treated with Selumetinib: A Report from the Pediatric Brain Tumor Consortium

S. Vajapeyam, D. Brown, A. Ziaei, S. Wu, G. Vezina, J.S. Stern, A. Panigrahy, Z. Patay, B. Tamrazi, J.Y. Jones, S.S. Haque, D.S. Enterline, S. Cha, B.V. Jones, K.W. Yeom, A. Onar-Thomas, I.J. Dunkel, M. Fouladi, J.R. Fangusaro, and T.Y. Poussaint



ABSTRACT

BACKGROUND AND PURPOSE: Selumetinib is a promising MAP (mitogen-activated protein) kinase (MEK) 1/2 inhibitor treatment for pediatric low-grade gliomas. We hypothesized that MR imaging–derived ADC histogram metrics would be associated with survival and response to treatment with selumetinib.

MATERIALS AND METHODS: Children with recurrent, refractory, or progressive pediatric low-grade gliomas who had World Health Organization grade I pilocytic astrocytoma with *KIAA1549–BRAF* fusion or the *BRAF* V600E mutation (stratum 1), neurofibromatosis type 1–associated pediatric low-grade gliomas (stratum 3), or sporadic non-neurofibromatosis type 1 optic pathway and hypothalamic glioma (OPHG) (stratum 4) were treated with selumetinib for up to 2 years. Quantitative ADC histogram metrics were analyzed for total and enhancing tumor volumes at baseline and during treatment.

RESULTS: Each stratum comprised 25 patients. Stratum 1 responders showed lower values of SD of baseline ADC_{total} as well as a larger decrease with time on treatment in ADC_{total} mean, mode, and median compared with nonresponders. Stratum 3 responders showed a greater longitudinal decrease in ADC_{total}. In stratum 4, higher baseline ADC_{total} skewness and kurtosis were associated with shorter progression-free survival. When all 3 strata were combined, responders showed a greater decrease with time in ADC_{total} mode and median. Compared with sporadic OPHG, neurofibromatosis type 1–associated OPHG had lower values of ADC_{total} mean, mode, and median as well as ADC_{enhancement} mean and median and higher values of ADC_{total} skewness and kurtosis at baseline. The longitudinal decrease in ADC_{total} median during treatment was significantly greater in sporadic OPHG compared with neurofibromatosis type 1–associated OPHG.

CONCLUSIONS: ADC histogram metrics are associated with progression-free survival and response to treatment with selumetinib in pediatric low-grade gliomas.

ABBREVIATIONS: MEK = MAP (mitogen-activated protein) kinase; *NF1* = neurofibromatosis type 1; OPHG = optic pathway and hypothalamic glioma; PBTC = Pediatric Brain Tumor Consortium; PFS = progression-free survival; pLGG = pediatric low-grade glioma; WHO = World Health Organization

Pediatric low-grade gliomas (pLGGs) are the most commonly occurring childhood brain tumor and comprise 40%–50% of all childhood CNS tumors.^{1,2} World Health Organization

(WHO) grade I pilocytic astrocytoma is the most frequent primary brain tumor in individuals 0–19 years of age, accounting for 15% of children's and adolescents' (0–19 years) and 17.8% of

Received August 10, 2021; accepted after revision January 1, 2022.

From the Department of Radiology (S.V., T.Y.P.), Boston Children's Hospital, Harvard Medical School, Boston, Massachusetts; Department of Radiology (D.B.), Massachusetts General Hospital, Boston, Massachusetts; Department of Radiology (A.Z.), Boston Children's Hospital, Boston, Massachusetts; Department of Biostatistics (S.W., A.O.-T.), St Jude Children's Research Hospital, Memphis, Tennessee; Department of Radiology (G.V.), Children's National Medical Center, Washington, DC; Department of Radiology (J.S.S.), Ann and Robert H Lurie Children's Hospital of Chicago, Chicago, Illinois; Department of Radiology (A.P.), Children's Hospital of Pittsburgh, Pittsburgh, Pennsylvania; Department of Diagnostic Imaging (Z.P.), St Jude Children's Research Hospital, Memphis, Tennessee; Department of Radiology (B.T.), Children's Hospital Los Angeles, Los Angeles, California; Department of Radiology (J.Y.J., M.F.), Nationwide Children's Hospital, Columbus, Ohio; Department of Radiology (S.S.H., I.J.D.), Memorial Sloan Kettering Cancer Center, New York, New York; Department of Radiology (D.S.E.), Duke University School of Medicine, Durham, North Carolina; Department of Radiology (S.C.), University of California San Francisco, San Francisco, California; Department of Radiology (B.V.J.), Cincinnati Children's Hospital Medical Center, Cincinnati, Ohio;

Department of Radiology (K.W.Y.), Stanford University School of Medicine, Stanford, California; and Department of Hematology, Oncology, and Stem Cell Transplantation (J.R.F.), Children's Healthcare of Atlanta and Emory University, Atlanta, Georgia.

This work was supported by the American Lebanese Syrian Associated Charities, AstraZeneca, US Department of Health and Human Services, National Institutes of Health, National Cancer Institute, National Cancer Institute Cancer Therapy Evaluation Program, National Institutes of Health/National Cancer Institute Cancer Center Support Grant P30 CA008748, UMICA081457.

Please address correspondence to Sridhar Vajapeyam, MD, Children's Hospital Boston, Radiology, 300 Longwood Ave, Boston, MA 02115; e-mail: sridhar.vajapeyam@childrens.harvard.edu

Indicates open access to non-subscribers at www.ajnr.org

Indicates article with online supplemental data.

<http://dx.doi.org/10.3174/ajnr.A7433>

primary childhood (0–14 years) brain tumors.¹ pLGGs are biologically distinct from their adult counterparts.³ Unlike adult low-grade gliomas that occur mostly in the cerebral hemispheres and transform into higher-grade gliomas, pLGGs can occur throughout the central nervous system, are molecularly distinct, rarely undergo malignant transformation,^{3,4} and require different therapies.

Total surgical resection is the first-line of treatment for pLGGs and can be curative.² However, this is not always feasible due to tumor location, particularly in the brain stem or optic pathway and hypothalamic gliomas (OPHG), and other therapies are required. Radiation therapy can be effective but may cause considerable neurocognitive deficits in young children and may increase the risk of developing a secondary malignancy, particularly in children with neurofibromatosis type 1 (*NF1*).⁵ Several chemotherapy regimens have shown promise in pLGGs, with 5-year progression-free survival (PFS) and overall survival rates of 35%–45% and 85%–100%, respectively, in sporadic pLGG and 5-year 60%–70% PFS and 90%–100% overall survival rates in *NF1*-associated pLGG.⁶ Selumetinib is a potent orally available MAP (mitogen-activated protein) kinase (MEK) 1/2 inhibitor that has recently shown great efficacy in refractory, recurrent, and progressive pLGGs.^{7,8} We explored the associations of advanced diffusion MR imaging metrics with response and survival in pLGGs treated with selumetinib in a large prospective Phase II Pediatric Brain Tumor Consortium (PBTC) trial, PBTC029B.

MATERIALS AND METHODS

Subjects

This was a multicenter, National Cancer Institute–sponsored Phase II study conducted by the PBTC using the MEK 1/2 inhibitor selumetinib in patients with pediatric low-grade gliomas treated at 11 PBTC member hospitals.^{8,9} Patients 3–21 years of age with a Lansky/Karnofsky Performance Status score of >60 and the presence of recurrent, refractory, or progressive pediatric low-grade glioma after at least 1 standard therapy, including chemotherapy and radiation therapy, were eligible for inclusion. Patients were assigned to 6 unique strata according to histology, tumor location, *NF1* status, and *BRAF* aberration status.^{8,9} Clinical analyses of strata 1, 3, and 4 have been completed,^{8,9} and the imaging data were used in this study. Stratum 1 comprised patients with WHO grade I pilocytic astrocytoma with either *KIAA1549-BRAF* fusion or the *BRAF* V600E (Val600Glu) mutation. Stratum 3 comprised patients with imaging- or biopsy-proved pLGGs and a clinical or genetic diagnosis of *NF1*. Stratum 4 comprised OPHG pLGGs not associated with *NF1*.

Selumetinib was provided as capsules given orally at a dose of 25 mg/m² twice daily in 28-day courses for up to 26 courses. The primary end point was the proportion of patients with a stratum-specific objective response (partial response or complete response), as assessed by the local site and sustained for at least 8 weeks. All responses were confirmed by central review.^{8,9}

The protocol was approved by the Cancer Therapy Evaluation Program (CTEP) as well as each site's institutional review board. All patients or legal guardians provided written, informed consent when applicable based on institutional guidelines.

Imaging and Image Analysis

Standard MR Imaging Evaluation. Standard MR imaging, which included T2-FLAIR and axial pre- and postcontrast T1-weighted images, as well as DTI, was performed primarily on 3T scanners at the start of treatment followed by every 2 months during the first year of therapy and then every 3 months thereafter. Additionally, high-resolution MR imaging of the orbits and optic pathway was performed for optic pathway tumors.

Patients whose tumors achieved an MR imaging response (complete or partial response) assessed locally underwent central radiographic review at the PBTC Neuroimaging Center. A complete response was defined as complete tumor disappearance on T2-FLAIR images, no new lesions, and disappearance of all enhancement on T1 postcontrast imaging. A partial response was defined as at least 50% tumor reduction (in a 2D area calculated as a product of 2 perpendicular linear measurements) on T2-FLAIR. Stable disease was defined as neither a sufficient increase nor a reduction to qualify as a partial response or progressive disease. Progressive disease was a >25% increase or the development of new lesions. These response criteria, while similar to the latest Response Assessment in Pediatric Neuro-Oncology recommendations,¹⁰ were developed earlier by a PBTC consensus panel and used both for local and central imaging response assessments.

DTI Acquisition and ADC Histogram Analysis. DTI data were acquired with the following acquisition parameters on a 3T scanner: section thickness = 2.2 mm, TR = 8800 ms, TE = 88 ms, FOV = 220 mm, b-value = 1000 s/mm², 35 directions. By means of the mutual information algorithm in FSL (<http://www.fmrib.ox.ac.uk/fsl>),¹¹ ADC and postcontrast T1 volumes were registered to FLAIR volume as described previously.¹² 3D ROIs comprising the total tumor volume from the FLAIR images and the enhancing tumor volume from postcontrast T1 were automatically generated using the thresholding feature in Fiji (<https://fiji.sc>),¹³ and the corresponding ADC was used to generate the ADC_{total} and ADC_{enhancement} volumes, respectively. These volumes were thresholded using a uniform range of 600–2600 × 10⁻⁶ mm²/s to automatically exclude cysts, necrosis, and hemorrhage; corresponding ADC_{total} and ADC_{enhancement} histograms were generated.¹²

Histogram metrics used for statistical analysis were the mean, SD, mode, median, skewness, and kurtosis of these histograms at baseline and 6, 12, 18, and 24 months into treatment and also at progression. In studies with multiple lesions, the primary target lesion was evaluated for all analyses.

For each of the imaging metrics, the baseline value and the time-dependent longitudinal change in the metrics during the course of treatment were examined for associations with tumor volume, response, and PFS.

Statistical Methods

The Wilcoxon rank-sum test was used to test the differences in ADC parameters at baseline between 2 groups. Subjects with at least 1 follow-up MR imaging after baseline were eligible for time-dependent longitudinal analyses. Tumor volumes were correlated within the patients because the measures were longitudinal. The mixed model was used to investigate the correlation between tumor volume and ADC metrics, taking intrapatient

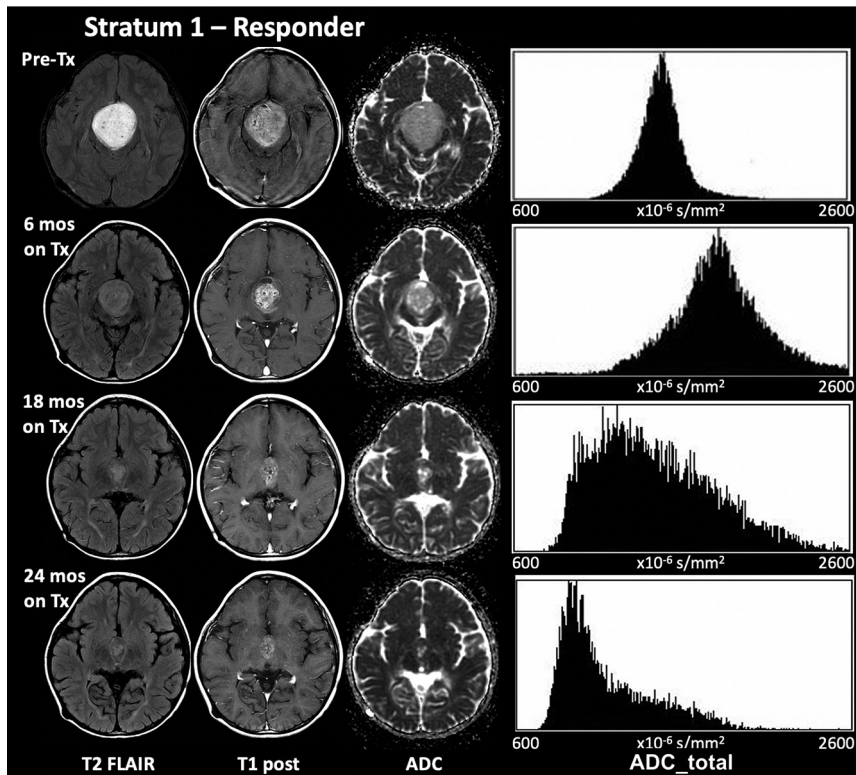


FIG 1. The decrease at 24 months in the mean, median, and mode of ADC_{total} with treatment in a 6-year-old boy with a WHO grade I glioma with a *BRAF* aberration who responded to selumetinib. The initial transient increase in these metrics seen here was observed in 5 of the 8 responders in stratum 1 and is possibly linked to increased water mobility due to early cell death, followed by tissue consolidation later in treatment. Tx indicates treatment.

correlation into account. Mixed-effects models were used to estimate trends across time in the ADC parameters as well as differences in longitudinal changes between groups. Cox models were used to investigate the association between PFS and ADC parameters at baseline as well as with time. The latter incorporated time-dependent ADC parameters. Q values were calculated within each stratum for PFS and response-based analyses separately to adjust for multiplicity via the false discovery rate if >1 parameter was significant.¹⁴ A *q*-value of 10% (0.1) was considered significant. Similarly, *q*-values were also used for cross-strata comparisons.

RESULTS

Stratum 1

Twenty-five patients (mean age at study entry, 9.2 years; range, 3.9–20.8 years; 12 males and 13 females) with WHO grade I pilocytic astrocytoma with either 1 of the 2 most common *BRAF* aberrations (*KIAA1549-BRAF* fusion or the *BRAF* V600E [Val600Glu] mutation) were enrolled. Eighteen of these had a *KIAA1549-BRAF* fusion, and the remaining 7 had the *BRAFV* 600E mutation. Nine patients showed sustained partial response, 9 had stable disease, and 7 showed progressive disease. Two-year PFS in stratum 1 was 70%. These results were reported previously.⁸

None of the baseline ADC_{total} histogram parameters were associated with PFS. Only the SD of ADC_{total} at baseline was

significantly associated with response ($P = .009$, $q = 0.04$), with responders showing lower values than nonresponders. The best response achieved was used in all analyses. There were significant associations of response with longitudinal change across time on treatment in the ADC_{total} mean ($P = .02$, $q = 0.05$), ADC_{total} mode ($P = .02$, $q = 0.07$), and ADC_{total} median ($P = .03$, $q = 0.1$), with responders showing a larger decrease in these parameters across time than nonresponders. Five of the 8 responders showed a transient increase in ADC followed by a decrease by 24 months as seen in Fig 1. Of the 21 enhancing tumors in stratum 1, sixteen were eligible for longitudinal analysis and 8 of these showed a response to selumetinib. None of the histogram metrics of ADC_{enhancement} were associated with a response in the longitudinal analyses.

No group differences were found in ADC histogram metrics between the *BRAF* fusion and the *BRAF* mutation groups either at baseline or in the longitudinal analysis.

Stratum 3

Twenty-five patients (mean age at study entry, 10.2 years; range, 3.5–16.6 years; 15 males and 10 females) with any *NFI*-associated pediatric low-grade glioma (WHO grades I and II) were enrolled in stratum 3. Nine patients showed sustained partial response, 15 had stable disease, and 1 showed progressive disease. The 2-year PFS in stratum 3 was 96%. These results were reported previously.⁸

None of the baseline ADC histogram metrics were associated with response or PFS. Longitudinal change with time on treatment of ADC_{total} mode was significantly associated with response ($P = .03$, $q = 0.07$), with responders showing a greater decrease across time than nonresponders. Five of 10 responders showed a transient increase in the ADC followed by a decrease by 24 months.

Stratum 4

Twenty-five patients (mean age at study entry, 9.4 years; range, 3.7–17.6 years; 12 males and 13 females) with sporadic non-*NFI* pediatric optic pathway and hypothalamic low-grade gliomas (WHO grades I and II) were enrolled in stratum 4. Six patients showed sustained partial response, 14 had stable disease, and 5 showed progressive disease. The 2-year PFS in stratum 4 was 73.8% (SD 9.3%) as reported previously.⁹

At baseline, there were statistically significant associations of ADC_{total} skewness ($P = .02$, $q = 0.06$) and ADC_{total} kurtosis ($P = .02$, $q = 0.06$) with PFS in stratum 4. Patients in stratum 4 with higher baseline skewness or kurtosis of ADC_{total} had

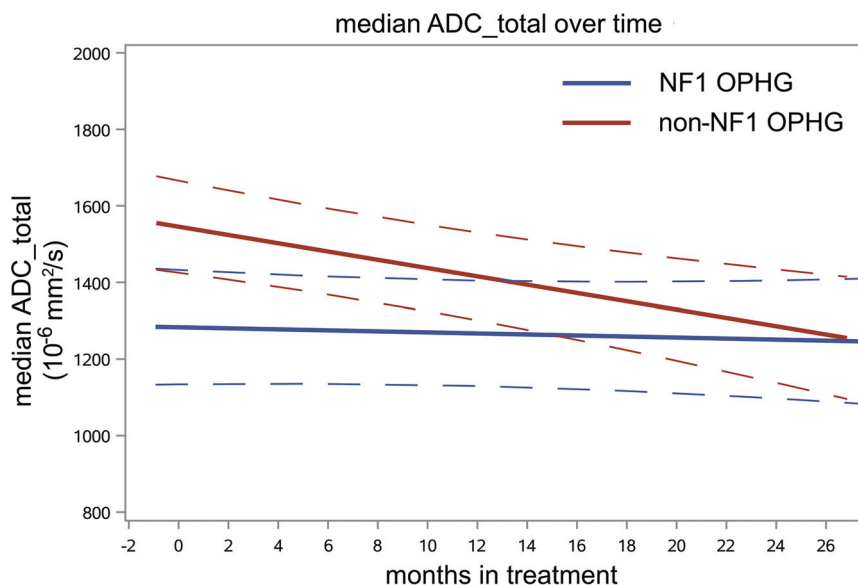


FIG 2. The longitudinal trend of median ADC of the total tumor volumes for the cohort of 25 sporadic non-*NF1* OPHGs from stratum 4 shown in red, compared with the 15 *NF1*-associated OPHGs shown in blue. Mixed-effects models were used to estimate trends with time in ADC parameters as well as differences in longitudinal changes between groups. Sporadic OPHG values are higher at baseline ($P = .002$, $q = 0.003$) and show a greater decrease with time ($P = .02$, $q = 0.06$) compared with *NF1*-associated OPHG.

shorter PFS (Online Supplemental Data). None of the longitudinal ADC_{total} histogram metrics were associated with response or PFS. Of the 23 enhancing tumors in stratum 4, twenty were eligible for longitudinal analysis with only 4 responders in this group. While the entire cohort showed a decrease with time in ADC_{enhancement} mean ($P = .02$, $q = 0.05$), mode ($P = .01$, $q = 0.04$), and median ($P = .008$, $q = 0.02$), there was no difference between responders and nonresponders.

Combined Strata

None of the baseline ADC histogram metrics were associated with response or PFS when all strata were combined ($n = 75$). Response was still significantly associated with longitudinal change with time in treatment for ADC_{total} mode ($P = .02$, $q = 0.06$) and ADC_{total} median ($P = .03$, $q = 0.09$). A greater decrease in these metrics was found in patients showing a response to the study drug. Of the 64 enhancing tumors in the combined strata, 48 were eligible for longitudinal analysis, with 19 responders. The entire cohort showed a decrease with time for the mean ($P = .01$, $q = 0.04$), mode ($P = .009$, $q = 0.03$), and median ($P = .009$, $q = 0.03$) of ADC_{enhancement} in the longitudinal analysis, but there was no difference between responders and nonresponders. There were no group differences in ADC histogram metrics of tumors that progressed and those that showed no progression in the 24-month study period. Total tumor volume was found to be negatively associated with the SD of ADC_{total} ($P = .008$).

Optic Pathway and Hypothalamic Glioma: *NF1* versus Sporadic

Twenty-five subjects with sporadic OPHGs in stratum 4 were compared with the cohort with 15 *NF1*-associated low-grade

OPHGs from stratum 3. No difference was found in PFS between the 2 groups.⁹ Enhancing tumor volume and cyst volume at baseline were both significantly lower in the *NF1*-associated OPHG in stratum 3 compared with stratum 4 ($P < .001$), while there was no difference in FLAIR tumor volume between the groups.

Significant differences between the groups were found in baseline values of ADC_{total} mean ($P = .005$, $q = 0.01$), mode ($P = .005$, $q = 0.01$), median ($P = .002$, $q = 0.003$), skewness ($P < .001$, $q < 0.001$), and kurtosis ($P = .01$, $q = 0.02$). The sporadic stratum 4 cohort had higher values of ADC_{total} mean, mode, and median and lower values of skewness and kurtosis. Similarly, ADC_{enhancement} showed higher values in sporadic OPHG for mean ($P = .045$, $q = 0.09$) and median ($P = .04$, $q = 0.09$) compared with *NF1*-associated OPHG. In the longitudinal analysis of change with time on treatment, the ADC_{total}

median decreased significantly more in the sporadic cohort in stratum 4 compared with *NF1*-associated stratum 3 OPHG ($P = .02$, $q = 0.06$) as shown in Fig 2, with the ADC_{total} mean similarly approaching significance ($P = .04$, $q = 0.11$).

DISCUSSION

The past decade has seen an explosion of molecular data showing that most pLGGs upregulate the RAS–mitogen-activated protein kinase pathway,^{15,16} most commonly including *BRAF* fusion or mutation of the *BRAF* gene^{17,18} and *NF1* mutation.¹⁶ More than 80% of pilocytic astrocytomas have gene alterations in some component of the MEK signaling pathway;³ therefore, several therapies have been developed to target this pathway. *BRAF* resistance and tumor progression have been reported in some therapies such as sorafenib targeting non-V600e aberrations,^{19,20} leading to therapies targeting downstream pathway components like MEK. Selumetinib is one such potent orally available MEK 1/2 inhibitor that has shown promise in pLGG.⁷⁻⁹

Pilocytic astrocytoma is the most frequent primary brain tumor in children and can occur anywhere in the central nervous system, with the most common locations being the cerebellum (40%), followed by supratentorial locations (35%), the optic pathway and hypothalamus (11%), and the brain stem (9%).²¹ Histopathologically, pilocytic astrocytoma is a tumor of low-to-moderate cellularity with compact, densely fibrillated areas rich in Rosenthal fibers, as well as spongy loosely textured areas composed of multipolar cells that have varying degrees of mucoid background material, often with microcysts.²² Most OPHGs, including those associated with *NF1*, are pilocytic astrocytomas.²³ The pathology of these tumors makes it highly likely that the

extracellular matrix is an important contributor to the ADC of these tumors.

ADC maps derived from diffusion-weighted images measure the diffusivity of water molecules in tissue. In the context of brain tumors, ADC is influenced by tumor cellularity and the extracellular matrix, as well as the presence of edema, cystic components, and necrosis. Several studies have reported an inverse relationship between ADC and cellularity in a variety of pediatric brain tumors.^{24,25} As cellularity increases, there is less extracellular space for water diffusion, leading to a lower ADC. Jost et al²⁶ examined the ADC in a cohort of 14 *NFI*-associated OPHGs and 13 sporadic OPHGs and found that ADC was not associated with either *NFI* status or clinical aggressiveness. Yeom et al,²⁷ however, found that in a retrospective study of a cohort of 5 patients with *NFI* and 7 with sporadic pediatric OPHG, a higher baseline ADC was predictive of tumor progression and that ADC then declined following subsequent chemotherapy with a standard combination of carboplatin and vincristine. Similarly, Hsu et al²⁸ reported that the ADC declined during the response to bevacizumab in a cohort of 8 patients with progressive pLGG. Whereas all the above studies used the mean ADC of the tumor volume, we used ADC histogram analyses to better characterize the ADC distribution in the tumors.

ADC histograms derived from the ADC of all voxels in a tumor volume are particularly well-suited to characterize the diffusion properties of the entire tumor volume in brain tumors and have been used to differentiate pediatric brain tumors by histologic type²⁹ and tumor grade.³⁰ ADC histogram parameters have also been associated with molecular subtype³¹ and response to therapy^{12,32} in diffuse intrinsic pontine gliomas in children. Herein, we report the use of ADC histogram metrics to identify prognosis and response criteria in refractory, recurrent, or progressive pLGGs treated with selumetinib.

Pilocytic astrocytomas in stratum 1 that responded to selumetinib had a smaller SD of baseline ADC_{total}, suggesting that more homogeneous tumors responded better. In addition, the mean, median, and mode of ADC_{total} all decreased more during the course of treatment for responders compared with non-responders. This decrease is similar to that found by Hsu et al²⁸ in a small sample of recurrent or progressive pLGGs treated with bevacizumab. The transient increase in these ADC metrics seen in the first few months of treatment is possibly due to increased water mobility due to cell death, followed by tissue consolidation leading to a stable decrease in these values. Patients in stratum 1 with tumors that had the *KIAA1549-BRAF* fusion had a longer PFS than those with the *BRAF* V600E mutation, but there was no difference in the response rate between the groups.⁸ However, our analyses of ADC histogram metrics showed no difference between the *BRAF* fusion and *BRAF* mutation either at baseline or across time, possibly due to small sample size.

NF-1 associated pLGG in stratum 3 showed no association between baseline ADC histogram metrics and either PFS or overall survival. ADC_{total} mode decreased more with time during therapy in responders in stratum 3, similar to our findings in stratum 1.

Among the patients with sporadic OPHGs in stratum 4, higher baseline skewness and kurtosis of ADC_{total} were

associated with shorter PFS, a finding similar to those in previous reports in pediatric diffuse intrinsic pontine glioma (DIPG).¹² Higher skewness and kurtosis signify more homogeneous tumors with lower ADC and are usually associated with higher cellularity in high-grade tumors, but in these low-grade OPHGs, they may be indicative of a lower fraction of extracellular matrix. Longitudinal ADC_{total} histogram metrics were not associated with response or PFS.

When data from all 3 strata were combined, there were no associations between baseline ADC histogram metrics, and PFS or response, suggesting that strata-specific analyses may be more useful. In a study of newly diagnosed OPHGs treated with carboplatin and vincristine, Yeom et al²⁷ found that tumors with a higher baseline mean had a shorter PFS. Our study comprised previously treated pLGGs not limited to OPHGs, which may explain why we found no baseline associations. However, a greater longitudinal decrease in mode and median ADC_{total} with time in treatment was seen in responders, similar to our findings in the individual strata. Tumors with smaller total tumor volume were found to have a higher SD of ADC_{total}, probably due to the higher proportion of cells on the tumor periphery in smaller tumors.

When the longitudinal trends in the individual and combined strata are considered as a whole, a consistent overall picture emerges, suggesting that a steeper drop in ADC_{total} values during treatment with selumetinib occurs in patients who respond to selumetinib. This finding confirms earlier reports in the literature from Yeom et al²⁷ and Hsu et al,²⁸ who saw similar trends in smaller samples of patients with pLGGs undergoing chemotherapy. This suggests that monitoring ADC during the course of treatment may provide some clinical value in assessing the response in pLGGs. A lower ADC has long been shown to be indicative of higher cellularity,³³ and an increase in ADC has been shown to be a biomarker of cell death in response to treatment in high-grade gliomas in adults.³⁴ Our longitudinal results linking a decrease in ADC with response is not consistent with the opposite behavior in high-grade gliomas because these are low-grade gliomas with a more extensive extracellular matrix. Tumor response with selumetinib in pLGGs may be the result of a decrease in extracellular space,^{27,35} leading to the decrease in ADC seen in responders in our study. The impressive response to selumetinib reported recently in plexiform neurofibromas,³⁶ which are known to have high extracellular matrix content,³⁷ may also be due to changes in the extracellular matrix.

Patients with OPHGs associated with *NFI* are known to have longer PFS compared with those with sporadic OPHGs.³⁸ When we compared the 25 sporadic OPHGs in stratum 4 with 15 *NFI*-associated OPHGs in stratum 3, no significant difference in PFS was seen, possibly due to the small sample size or the relatively short period of time of 24 months used in this analysis. Enhancing tumor volume as well as the volume of cysts were significantly higher in sporadic OPHGs compared with *NFI*-associated OPHGs, whereas there was no difference in overall tumor volume. The baseline mean, median, and mode of ADC_{total} as well as baseline mean and median of ADC_{enhancement} were higher in sporadic OPHGs compared with *NFI*-associated OPHGs. This result may be explained by the higher incidence of cystic components in sporadic OPHGs that we report, consistent

with previous reports.³⁹ The greater decrease with time in median ADC_{total} we report in sporadic OPHGs in stratum 4 compared with *NFI*-associated OPHG in stratum 3 (Fig 2) may also be associated with a decrease in cystic components of the tumor.

Although ours was larger than prior studies in the literature, the relatively small sample size and diverse prior treatment histories are limitations of this study.

Machine learning methods have shown promise in differentiating *BRAF* fusion and mutation⁴⁰ and could be useful in predicting response to therapy. This study was an observational and exploratory analysis and is the first study, to our knowledge, to look for any associations between treatment response and changes in ADC in pLGGs. Our population was heterogeneous with respect to molecular type as well as tumor location, and response to selumetinib varies by molecular type and tumor location. Future studies with the large homogeneous samples of each tumor type required for artificial intelligence and machine learning algorithms may definitively identify ADC histogram metrics as markers to identify response to selumetinib. Future work may also include exploring associations between ADC histogram metrics and standardized measures of visual outcomes in OPHGs as recommended by Response Assessment in Pediatric Neuro-Oncology.¹⁰

CONCLUSIONS

We hypothesized that ADC histogram metrics would be associated with response in pLGGs treated with selumetinib. ADC values in pLGGs decreased with time in treatment with selumetinib in responders compared with nonresponders. Compared with *NFI*-associated OPHG, ADC decreased with selumetinib treatment in sporadic OPHG. ADC histogram metrics were found to be associated with response of pLGG to selumetinib.

Disclosure forms provided by the authors are available with the full text and PDF of this article at www.ajnr.org.

REFERENCES

- Ostrom QT, Cioffi G, Gittleman H, et al. **CBTRUS Statistical Report: primary brain and other central nervous system tumors diagnosed in the United States in 2012-2016.** *Neuro Oncol* 2019;21:v1-100 [CrossRef Medline](#)
- Ryall S, Tabori U, Hawkins C. **Pediatric low-grade glioma in the era of molecular diagnostics.** *Acta Neuropathol Commun* 2020;8:30 [CrossRef Medline](#)
- Collins KL, Pollack IF. **Pediatric low-grade gliomas.** *Cancers* 2020;12:1152 [CrossRef](#)
- Broniscer A, Baker SJ, West AN, et al. **Clinical and molecular characteristics of malignant transformation of low-grade glioma in children.** *J Clin Oncol* 2007;25:682-89 [CrossRef Medline](#)
- Sharif S, Ferner R, Birch JM, et al. **Second primary tumors in neurofibromatosis 1 patients treated for optic glioma: substantial risks after radiotherapy.** *J Clin Oncol* 2006;24:2570-75 [CrossRef Medline](#)
- Jones DTW, Kieran MW, Bouffet E, et al. **Pediatric low-grade gliomas: next biologically driven steps.** *Neuro Oncol* 2018;20:160-73 [CrossRef Medline](#)
- Banerjee A, Jakacki RI, Onar-Thomas A, et al. **A phase I trial of the MEK inhibitor selumetinib (AZD6244) in pediatric patients with recurrent or refractory low-grade glioma: a Pediatric Brain Tumor Consortium (PBTC) study.** *Neuro Oncol* 2017;19:1135-44 [CrossRef Medline](#)
- Fangusaro J, Onar-Thomas A, Young Poussaint T, et al. **Selumetinib in paediatric patients with BRAF-aberrant or neurofibromatosis type 1-associated recurrent, refractory, or progressive low-grade glioma: a multicentre, phase 2 trial.** *Lancet Oncol* 2019;20:1011-22 [CrossRef Medline](#)
- Fangusaro J, Onar-Thomas A, Poussaint TY, et al. **A phase 2 trial of selumetinib in children with recurrent optic pathway and hypothalamic low-grade glioma without NF1: a Pediatric Brain Tumor Consortium Study.** *Neuro Oncol* 2021;23:1777-88 [CrossRef Medline](#)
- Fangusaro J, Witt O, Hernáiz Driever P, et al. **Response assessment in paediatric low-grade glioma: recommendations from the Response Assessment in Pediatric Neuro-Oncology (RAPNO) working group.** *Lancet Oncol* 2020;21:e305-16 [CrossRef Medline](#)
- Jenkinson M, Beckmann CF, Behrens TE, et al. **FSL.** *Neuroimage* 2012;62:782-90 [CrossRef Medline](#)
- Poussaint TY, Vajapeyam S, Ricci KI, et al. **Apparent diffusion coefficient histogram metrics correlate with survival in diffuse intrinsic pontine glioma: a report from the Pediatric Brain Tumor Consortium.** *Neuro Oncol* 2016;18:725-34 [CrossRef Medline](#)
- Schindelin J, Arganda-Carreras I, Frise E, et al. **Fiji: an open-source platform for biological-image analysis.** *Nat Methods* 2012;9:676-82 [CrossRef Medline](#)
- Strimmer K. **fdrtool: a versatile R package for estimating local and tail area-based false discovery rates.** *Bioinformatics* 2008;24:1461-62 [CrossRef Medline](#)
- Packer RJ, Pfister S, Bouffet E, et al. **Pediatric low-grade gliomas: implications of the biologic era.** *Neuro Oncol* 2017;19:750-61 [CrossRef Medline](#)
- Ryall S, Zapotocky M, Fukuoka K, et al. **Integrated molecular and clinical analysis of 1,000 pediatric low-grade gliomas.** *Cancer Cell* 2020;37:569-83 [CrossRef Medline](#)
- Jones DT, Kocalkowski S, Liu L, et al. **Oncogenic RAF1 rearrangement and a novel BRAF mutation as alternatives to KIAA1549: BRAF fusion in activating the MAPK pathway in pilocytic astrocytoma.** *Oncogene* 2009;28:2119-23 [CrossRef Medline](#)
- Lassaletta A, Zapotocky M, Mistry M, et al. **Therapeutic and prognostic implications of BRAF V600E in pediatric low-grade gliomas.** *J Clin Oncol* 2017;35:2934-41 [CrossRef Medline](#)
- Karajannis MA, Legault G, Fisher MJ, et al. **Phase II study of sorafenib in children with recurrent or progressive low-grade astrocytomas.** *Neuro Oncol* 2014;16:1408-16 [CrossRef Medline](#)
- Sievert AJ, Lang SS, Boucher KL, et al. **Paradoxical activation and RAF inhibitor resistance of BRAF protein kinase fusions characterizing pediatric astrocytomas.** *Proc Natl Acad Sci U S A* 2013;110:5957-62 [CrossRef Medline](#)
- Burkhard C, Di Patre PL, Schüler D, et al. **A population-based study of the incidence and survival rates in patients with pilocytic astrocytoma.** *J Neurosurg* 2003;98:1170-74 [CrossRef Medline](#)
- Collins VP, Jones DT, Giannini C. **Pilocytic astrocytoma: pathology, molecular mechanisms and markers.** *Acta Neuropathol* 2015;129:775-78 [CrossRef Medline](#)
- Listernick R, Louis DN, Packer RJ, et al. **Optic pathway gliomas in children with neurofibromatosis 1: consensus statement from the NF1 Optic Pathway Glioma Task Force.** *Ann Neurol* 1997;41:143-49 [CrossRef Medline](#)
- Gauvain KM, McKinstry RC, Mukherjee P, et al. **Evaluating pediatric brain tumor cellularity with diffusion-tensor imaging.** *AJR Am J Roentgenol* 2001;177:449-54 [CrossRef Medline](#)
- Koral K, Mathis D, Gimi B, et al. **Common pediatric cerebellar tumors: correlation between cell densities and apparent diffusion coefficient metrics.** *Radiology* 2013;268:532-37 [CrossRef Medline](#)
- Jost SC, Ackerman JW, Garbow JR, et al. **Diffusion-weighted and dynamic contrast-enhanced imaging as markers of clinical behavior in children with optic pathway glioma.** *Pediatr Radiol* 2008;38:1293-99 [CrossRef Medline](#)
- Yeom KW, Lober RM, Andre JB, et al. **Prognostic role for diffusion-weighted imaging of pediatric optic pathway glioma.** *J Neurooncol* 2013;113:479-83 [CrossRef Medline](#)

28. Hsu CH, Lober RM, Li MD, et al. **Decreased tumor apparent diffusion coefficient correlates with objective response of pediatric low-grade glioma to bevacizumab.** *J Neurooncol* 2015;122:491–96 [CrossRef Medline](#)
29. Payabvash S, Aboian M, Tihan T, et al. **Machine learning decision tree models for differentiation of posterior fossa tumors using diffusion histogram analysis and structural MRI findings.** *Front Oncol* 2020;10:71 [CrossRef Medline](#)
30. Vajapeyam S, Brown D, Johnston PR, et al. **Multiparametric analysis of permeability and ADC histogram metrics for classification of pediatric brain tumors by tumor grade.** *AJNR Am J Neuroradiol* 2018;39:552–57 [CrossRef Medline](#)
31. Jaimes C, Vajapeyam S, Brown D, et al. **MR imaging correlates for molecular and mutational analyses in children with diffuse intrinsic pontine glioma.** *AJNR Am J Neuroradiol* 2020;41:874–81 [CrossRef Medline](#)
32. Vajapeyam S, Brown D, Billups C, et al. **Advanced ADC histogram, perfusion, and permeability metrics show an association with survival and pseudoproggression in newly diagnosed diffuse intrinsic pontine glioma: a report from the Pediatric Brain Tumor Consortium.** *AJNR Am J Neuroradiol* 2020;41:718–24 [CrossRef Medline](#)
33. Sugahara T, Korogi Y, Kochi M, et al. **Usefulness of diffusion-weighted MRI with echo-planar technique in the evaluation of cellularity in gliomas.** *J Magn Reson Imaging* 1999;9:53–60 [CrossRef Medline](#)
34. Chenevert TL, Stegman LD, Taylor JM, et al. **Diffusion magnetic resonance imaging: an early surrogate marker of therapeutic efficacy in brain tumors.** *J Natl Cancer Inst* 2000;92:2029–36 [CrossRef Medline](#)
35. Hoyt WF, Baghdassarian SA. **Optic glioma of childhood: natural history and rationale for conservative management.** *Br J Ophthalmol* 1969;53:793–98 [CrossRef Medline](#)
36. Gross AM, Wolters PL, Dombi E, et al. **Selumetinib in children with inoperable plexiform neurofibromas.** *N Engl J Med* 2020;382:1430–42 [CrossRef Medline](#)
37. Lévy P, Bièche I, Leroy K, et al. **Molecular profiles of neurofibromatosis type 1-associated plexiform neurofibromas: identification of a gene expression signature of poor prognosis.** *Clin Cancer Res* 2004;10:3763–71 [CrossRef Medline](#)
38. Deliganis AV, Geyer JR, Berger MS. **Prognostic significance of type 1 neurofibromatosis (von Recklinghausen Disease) in childhood optic glioma.** *Neurosurgery* 1996;38:1114–18; discussion 1118–19 [CrossRef Medline](#)
39. Kornreich L, Blaser S, Schwarz M, et al. **Optic pathway glioma: correlation of imaging findings with the presence of neurofibromatosis.** *AJNR Am J Neuroradiol* 2001;22:1963–69 [Medline](#)
40. Wagner MW, Hainc N, Khalvati F, et al. **Radiomics of pediatric low-grade gliomas: toward a pretherapeutic differentiation of BRAF-mutated and BRAF-fused tumors.** *AJNR Am J Neuroradiol* 2021;42:759–65 [CrossRef Medline](#)