



# Current diagnosis and treatment of vestibular neuritis: a narrative review

Chang Hoon Bae, Hyung Gyun Na, Yoon Seok Choi

Department of Otorhinolaryngology-Head and Neck Surgery, Yeungnam University College of Medicine, Daegu, Korea

Vertigo is the sensation of self-motion of the head or body when no self-motion is occurring or the sensation of distorted self-motion during an otherwise normal head movement. Representative peripheral vertigo disorders include benign paroxysmal positional vertigo, Ménière disease, and vestibular neuritis. Vestibular neuritis, also known as vestibular neuronitis, is the third most common peripheral vestibular disorder after benign paroxysmal positional vertigo and Ménière disease. The cause of vestibular neuritis remains unclear. However, a viral infection of the vestibular nerve or ischemia of the anterior vestibular artery is known to cause vestibular neuritis. In addition, recent studies on immune-mediated mechanisms as the cause of vestibular neuritis have been reported. The characteristic clinical features of vestibular neuritis are abrupt true-whirling vertigo lasting for more than 24 hours, and no presence of cochlear symptoms and other neurological symptoms and signs. To accurately diagnose vestibular neuritis, various diagnostic tests such as the head impulse test, bithermal caloric test, and vestibular-evoked myogenic potential test are conducted. Various treatments for vestibular neuritis have been reported, which are largely divided into symptomatic therapy, specific drug therapy, and vestibular rehabilitation therapy. Symptomatic therapies include generalized supportive care and administration of vestibular suppressants and antiemetics. Specific drug therapies include steroid therapy, antiviral therapy, and vasodilator therapy. Vestibular rehabilitation therapies include generalized vestibular and customized vestibular exercises.

**Keywords:** Diagnosis; Treatment; Vertigo; Vestibular neuritis

## Introduction

Vertigo is the sensation of self-motion of the head or body when no self-motion is occurring or the sensation of distorted self-motion during an otherwise normal head movement [1]. The occurrence of vertigo can be divided into peripheral disorders that originate in the vestibular organs and central disorders that originate in the brain. Representative peripheral vertigo disorders include benign paroxysmal positional vertigo, Ménière disease, and vestibular neuritis.

Benign paroxysmal positional vertigo is one of the most preva-

lent vestibular disorders and is characterized by recurrent positional vertigo without hearing loss [2]. According to a widely accepted theory, benign paroxysmal positional vertigo is usually caused by otoconia that are dislodged from the otolith macula beds and are trapped in the semicircular canal. The otoconia move under the influence of gravity after changes in head position in the plane of the affected semicircular canal; the resulting inappropriate endolymph flow deflects the cupula and thus modulates the activity of the vestibular afferents of the affected canal, causing attacks of positional vertigo and nystagmus (canalolithiasis) [3]. The definitive diagnosis of benign paroxysmal positional vertigo requires diagnostic po-

Received: June 14, 2021 • Revised: July 16, 2021 • Accepted: July 22, 2021

Corresponding author: Chang Hoon Bae, MD, PhD

Department of Otorhinolaryngology-Head and Neck Surgery, Yeungnam University College of Medicine, 170 Hyeonchung-ro, Nam-gu, Daegu 42415, Korea  
Tel: +82-53-620-3784 • Fax: +82-53-628-7884 • E-mail: baich@med.yu.ac.kr

Copyright © 2022 Yeungnam University College of Medicine, Yeungnam University Institute of Medical Science

This is an Open Access article distributed under the terms of the Creative Commons Attribution Non-Commercial License (<http://creativecommons.org/licenses/by-nc/4.0/>) which permits unrestricted non-commercial use, distribution, and reproduction in any medium, provided the original work is properly cited.

sitional maneuvers that involve the provocation of vertigo and nystagmus in each semicircular canal, and the effective treatment of benign paroxysmal positional vertigo includes therapeutic positional maneuvers such as the Epley, Semont, and Gufoni maneuvers [2,3].

Ménière disease is characterized by recurrent spontaneous vertigo, fluctuating hearing loss, tinnitus, and aural fullness. The pathophysiological findings of Ménière disease are associated with an accumulation of endolymph in the cochlear duct, which occurs at the expense of the perilymphatic space, and inadequate absorption of the endolymph by the endolymphatic sac [2,4]. The diagnosis of Ménière disease is based on the 2015 clinical criteria proposed by the International Classification Committee for Vestibular Disorders of the Bárány Society [5]. Ménière disease is treated with dietary modification; administration of beta-histidine, diuretics, intratympanic steroids, and intratympanic gentamicin; endolymphatic sac surgery, labyrinthectomy, and vestibular neurectomy [2].

Vestibular neuritis is characterized by acute spontaneous vertigo without hearing loss and is the third most common peripheral vestibular disorder, after benign paroxysmal positional vertigo and Ménière disease [2]. Vestibular neuritis is classified as an acute vestibular syndrome, like vestibular migraine, multiple sclerosis, and stroke [1]. Although vestibular neuritis is considered to be triggered by viral inflammation or reactivation of latent viruses in the ganglion of the vestibular nerve [2,6], the exact etiology of vestibular neuritis is not yet clear. Therefore, various treatments have been used for vestibular neuritis, such as corticosteroids, antivirals, and vestibular rehabilitation exercises [6]. This study aimed to review the etiology, epidemiology, diagnosis, and treatment of vestibular neuritis, focusing on the current diagnosis and treatment of vestibular neuritis.

## Terminology

Vestibular neuritis is an acute peripheral vestibulopathy, also known as vestibular neuronitis. The clinical features of vestibular neuritis were first reported by Eric Ruttin in 1909 and later by Carl-Olof Nylén in 1924 [7,8]. The term “vestibular neuronitis” was first described by Charles Skinner Hallpike in 1949 and Margaret Ruth Dix and Charles Skinner Hallpike in 1952 [9]. Vestibular neuronitis was replaced by the term “vestibular neuritis,” because there is strong evidence that the vestibular ganglion cells themselves are not inflamed, but rather parts of the vestibular nerve [7]. Recently, it has been recommended to consider vestibular neuritis as an acute unilateral vestibulopathy according to the International Classification of Vestibular Disorders [10].

## Epidemiology

Peripheral vertigo is most common in benign paroxysmal positional vertigo, followed by Ménière disease, and vestibular neuritis [2,10]. The annual incidence of vestibular neuritis has been reported to range from 3.5% to 15.5% per 100,000 persons [10-13], and approximately 4% to 9.8% of adult patients and 3.3% of pediatric patients are treated for acute unilateral vestibular loss [14]. Although vestibular neuritis has been reported to occur more frequently in women than in men, there is no statistically significant difference in the incidence between men and women [11,15]. Vestibular neuritis occurs mainly in patients aged 30 to 60 years and most often occurs in those aged 40 to 50 years. According to a recent study, vestibular neuritis has been reported to occur even more frequently in those over the age of 70 years [10,15].

## Etiology

The exact etiology of vestibular neuritis remains unclear. However, viral infection of the vestibular nerve or ischemia of the anterior vestibular artery is thought to cause vestibular neuritis. In addition, recent studies on immune-mediated mechanisms as the cause of vestibular neuritis have been reported [16-18].

Regarding viral infection of the vestibular nerve, it is considered that viruses causing infections of the upper respiratory tract, such as influenza virus, adenovirus, herpes simplex virus, cytomegalovirus, Epstein-Barr virus, and parainfluenza virus are related to vestibular neuritis, because associations with preceding or concurrent viral infection in the upper respiratory tract occur in 43% to 46% of vestibular neuritis [16]. Among them, herpes simplex virus type 1 is the most common cause of viral infection of the vestibular nerve and ganglion; the deoxyribonucleic acid of herpes simplex virus type 1 is detected on autopsy in about two of three human vestibular ganglia along with the expression of CD8-positive T lymphocytes, cytokines, and chemokines [17], and inoculation of herpes simplex virus type 1 into a mouse model induces vestibular dysfunction in infected vestibular ganglion cells, such as vestibular neuritis [17,18].

As a result of ischemia of the anterior vestibular artery, the inflammatory response of peripheral blood mononuclear cells and the percentage of CD40-positive monocytes and macrophages are significantly elevated in patients with vestibular neuritis compared to healthy individuals [16]. The pro-inflammatory activation of peripheral blood mononuclear cells, CD40-positive monocytes, CD40-positive macrophages, and cytokines such as tumor necrosis factor alpha, cellular adhesion molecule, and cyclooxygenase 2, leads to reduced microvascular perfusion of the vestibular organ

caused by an increase in thrombotic events, which causes a loss of function of the vestibular organ secondary to reduced perfusion and/or infarction [16,18].

Vestibular neuritis occurs mainly in the superior vestibular nerve, which innervates the anterior semicircular canal, lateral semicircular canal, and utricle, rather than the inferior vestibular nerve [10,16,17]. Swelling due to viral infection or ischemia mainly occurs in the superior vestibular nerve because of anatomical differences between the superior and inferior vestibular nerves; the bony canal of the superior vestibular nerve and arteriole is a relatively narrower passage and seven times longer than the bony canal of the singular nerve [10,17].

Regarding immune-mediated mechanisms, an immunological imbalance between T-helper and T-suppressor cells is associated with vestibular neuritis, similar to that observed in multiple sclerosis [16,18].

## Diagnosis

The characteristic clinical features of vestibular neuritis are abrupt true-whirling vertigo lasting for more than 24 hours with nausea and vomiting in middle age, and no presence of cochlear symptoms and other neurological symptoms and signs, such as hearing loss, tinnitus, stuttering, and paresthesia of the ipsilateral face and contralateral upper and lower extremities. Prodromal dizziness lasting a few minutes, in the few days just before the full onset of symptoms, may precede the prolonged spontaneous vertigo in as many as a quarter of patients with vestibular neuritis, who mostly experience non-vertiginous dizziness attacks, often accompanied by nausea or unsteadiness, which may develop abruptly or gradually [19]. The vertigo of vestibular neuritis increases gradually over several hours, peaking on the first day. It is usually described as rotational and is significantly increased by head movements. Patients with vestibular neuritis usually prefer lying down in bed with their eyes closed in a side position with the healthy ear down. Most vertiginous patients experience severe nausea and vomiting, which improve significantly over a period of 1 to 3 days [17,19].

Patients with vestibular neuritis can walk alone in the acute stage, usually the first 3 days after the onset of symptoms, but most are supported by a caregiver because the body tilts toward the lesioned side or tends to fall. During the acute stage of vestibular neuritis, horizontal-torsional spontaneous nystagmus beating away from the lesioned side is observed, which is of a unidirectional type and obeys Alexander's law: the horizontal nystagmus typically increases during gaze in the direction of the quick phases and decreases when looking in the opposite direction [17,19,20]. In addition, the ocular tilt reaction comprises head tilt, ocular torsion, and

skew deviation. However, the full picture of the ocular tilt reaction is not very often seen clinically [21]. In the recovery stage of vestibular neuritis, the horizontal-torsional spontaneous nystagmus beating toward the lesioned side is observed [17,19,20].

The head impulse test is a simple bedside test of the higher frequency vestibulo-ocular reflex, which is based on Ewald's second law. It is performed by grasping the patient's head and applying a brief, small-amplitude, high-acceleration head turn, first to one side and then to the other. The patient fixates on the examiner's nose, and the examiner watches for corrective rapid movement of the eye (saccades), which is a sign of decreased vestibular response. The "catch-up" saccades after a head impulse in one direction indicate a peripheral vestibular lesion on that side [22]. The bedside head impulse test has an acceptable sensitivity, but may appear negative when the vestibular deficits are mild or the corrective saccades that only occur during head impulses and cannot be seen on simple visual inspection. In these instances, a video head impulse test is necessary; the findings of the video head impulse test in vestibular neuritis show decreased gain and corrective overt and covert saccades [19,22,23].

Head shaking nystagmus is generated by an asymmetric peripheral vestibular input and a central velocity storage mechanism, which may cause perseveration of the peripheral vestibular signals, with the subsequent reversal phase indicating adaptation of primary vestibular afferent activity [24]. The head-shaking nystagmus test is performed by rotating the patient's head vigorously 20 times at 2 Hertz with the patient's head inclined at 30° while sitting. The findings of head-shaking nystagmus test in vestibular neuritis show monophasic or biphasic type: the monophasic type is characterized by a slow-phase component toward the lesioned side, and the biphasic type is characterized by an initial slow-phase component toward the lesioned side, followed by a prolonged reversal phase toward the opposite side [24,25].

The smooth pursuit test measures the slow movement of the eye to stabilize the image of an object on or near the fovea for optimal visual acuity during the slow movement of the object or body, while the optokinetic nystagmus test measures rapid eye movement in the physiological response induced by a series of displays moving rapidly across the visual field [26,27]. The findings of the smooth pursuit test and optokinetic test in vestibular neuritis show abnormal findings, such as corrective catch-up saccades, decreased gain, and asymmetry, which must be used to differentiate between vestibular neuritis and central nervous system disease [28].

The subjective visual vertical/horizontal test measures otolith dysfunction without complex equipment: the ipsilesional deviation of the subjective visual vertical and horizontal senses [29]. The findings of the subjective visual vertical/horizontal test show a

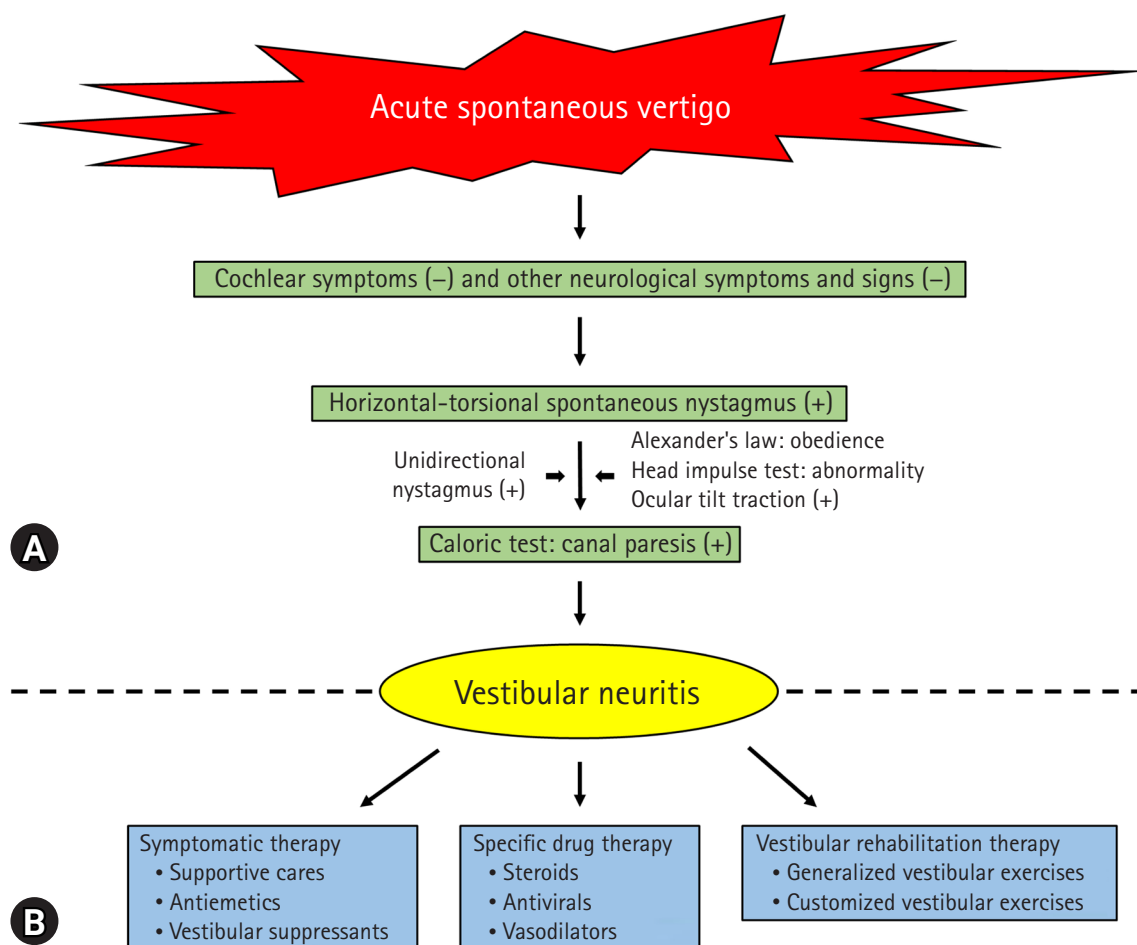
significant deviation of the tilting bar at least 2.5° toward the lesioned side [17,29].

The caloric test involves stimulation of the horizontal semicircular canal by alternating heating and cooling of the external auditory canal with water or air. Although the caloric test can only evaluate the function of the horizontal semicircular canal in the lower frequency range of stimulation, the bithermal caloric test provides the most characteristic and consistent results in vestibular neuritis. The findings of the caloric test show more than 20% to 30% of canal paresis on the affected side and directional preponderance on the healthy side in superior vestibular neuritis, but normal results in inferior vestibular neuritis (Fig. 1A) [17,30].

Vestibular-evoked myogenic potentials are short-latency, vestibular-dependent reflexes that are recorded from the sternocleidomastoid muscles in the anterior neck (cervical vestibular-evoked myogenic potentials) and inferior oblique extraocular muscles (ocular vestibular-evoked myogenic potentials). They are evoked by

short bursts of sound delivered through headphones or vibrations applied to the skull. These stimuli have been shown to preferentially activate the saccule and utricle [31]. The findings of vestibular-evoked myogenic potential tests in vestibular neuritis show decreased or absent responses of vestibular-evoked myogenic potentials during stimulation of the affected ear [17]. Furthermore, the dissociated patterns of abnormalities in cervical and ocular vestibular-evoked myogenic potentials may provide important clues for determining the involved vestibular division in vestibular neuritis: abnormal ocular vestibular-evoked myogenic potentials but normal cervical vestibular-evoked myogenic potentials in response to air-conducted sound in superior vestibular neuritis, whereas normal ocular vestibular-evoked myogenic potentials but abnormal cervical vestibular-evoked myogenic potentials in response to air-conducted sound are seen in inferior vestibular neuritis [17,31].

Posturography is used to quantify the relative contributions of



**Fig. 1.** Diagnostic evaluation and treatment of vestibular neuritis. (A) Characteristic clinical features of vestibular neuritis include acute spontaneous vertigo and no presence of cochlear symptoms and other neurological symptoms and signs. Horizontal-torsional spontaneous nystagmus is observed with canal paresis on the affected side. (B) Various treatments of vestibular neuritis include symptomatic therapy, specific drug therapy, and vestibular rehabilitation therapy. -, negative; +, positive.

sensory systems to postural control in the upright stance under either static or dynamic conditions, and can provide insight into the presence of postural instability and help identify which sensory system is involved, although it does not provide a topographic diagnosis [32]. The findings of computerized dynamic posturography in vestibular neuritis show abnormal results for conditions 5 and/or 6 of the sensory organization test [32,33].

In contrast to the caloric test, the rotational test provides physiological stimuli and quantitative evaluation of the vestibulo-ocular reflex function of the horizontal semicircular canals, and expands the ability to investigate the peripheral vestibular system beyond the very low-frequency region [34]. The findings of the rotational chair test show decreased gain, asymmetry, and phase lead in the sinusoidal harmonic acceleration test, and a decreased time constant in the step-velocity test [34,35].

Magnetic resonance imaging is usually performed to distinguish lesions of the central nervous system in acute vestibular syndromes, such as vestibular migraine, multiple sclerosis, and stroke. Gadolinium-enhanced 3 T magnetic resonance imaging in vestibular neuritis allows direct visualization of the affected vestibular nerve [17,36].

Diseases that should be distinguished from vestibular neuritis include vestibular migraine, benign paroxysmal positional vertigo, Ménière disease, multiple sclerosis, stroke, and transient ischemic attack. A definite diagnosis of benign paroxysmal positional vertigo requires diagnostic positional maneuvers that involve the provocation of vertigo and nystagmus in each semicircular canal. To diagnose posterior or anterior semicircular canal benign paroxysmal positional vertigo, the Dix-Hallpike maneuver is conducted by turning the head of a sitting patient 45° toward the side to be tested and then laid back quickly into a head-hanging position; the side-lying maneuver is conducted so that the sitting patient is tilted quickly to the side to be tested with the head turned 45° to the opposite side [2,3]. To diagnose horizontal semicircular canal benign paroxysmal positional vertigo, the head roll test is conducted in which the head of the patient in the supine position is elevated by about 30° and then turned quickly to either side [3]. The diagnosis of Ménière disease is based on the 2015 clinical criteria proposed by the International Classification Committee for Vestibular Disorders of the Bárány Society: (1) two or more spontaneous episodes of vertigo, each lasting 20 minutes to 12 hours; (2) audiometrically documented low- to medium-frequency sensorineural hearing loss in the affected ear on at least one occasion before, during, or after one of the episodes of vertigo; (3) fluctuating aural symptoms (hearing, tinnitus, or fullness) in the affected ear; and (4) not better accounted for by another vestibular diagnosis [2,4,5]. In stroke, central nystagmus is pure vertical nystagmus or rotational nystag-

mus. The direction of the nystagmus also changes according to the direction of the gaze; fixation has little to no effect. In addition, it is often difficult to walk or stand due to severe body sway. It may be accompanied by central nervous system-related symptoms, such as stuttering and paresthesia of the ipsilateral face and contralateral upper and lower extremities [17]. Vestibular pseudoneuritis caused by an isolated infarction of the labyrinthine, pontomedullary brainstem, or cerebellum requires a more meticulous differential diagnosis [1,19]. It is not always easy to distinguish between isolated vascular vertigo and acute peripheral vestibulopathy at the bedside. However, a rather simple neuro-otological examination, including a normal horizontal head impulse test, direction-changing nystagmus, and skew deviation can reliably detect central vertigo with high sensitivity and specificity. Even these neuro-otological examinations are more sensitive to stroke than early magnetic resonance imaging [17].

## Treatment

Various treatments for vestibular neuritis have been reported, which can be largely divided into symptomatic therapy, specific drug therapy, and vestibular rehabilitation therapy (Fig. 1B). Symptomatic therapy reduces anxiety by explaining in detail the cause, treatment, and prognosis of vestibular neuritis in patients, and provides psychological support by explaining that daily life is possible in a short period of time. It also ensures that the patient is in the most comfortable position and that secondary damage from falls does not occur. In the acute stage of vestibular neuritis, nausea and vomiting are common. Therefore, if food intake is difficult, appropriate fluid therapy is needed, and vestibular suppressants and antiemetics should be administered [19,37].

Vestibular suppressants are widely used because they are effective against dizziness, nausea, and vomiting. Although the exact mechanism of action of vestibular suppressants is unclear, they act at the level of the neurotransmitters involved in the propagation of impulses from primary to secondary vestibular neurons and in the maintenance of tone in the vestibular nuclei. They also act on areas of the nervous system that control vomiting, including central components in the emetic center of the brain and peripheral components in the gastrointestinal tract [38]. Representative vestibular suppressants include antihistamines such as dimenhydrinate and meclizine; anticholinergics such as scopolamine and atropine; antidopaminergics such as haloperidol and droperidol;  $\gamma$ -aminobutyric acid receptor agonists such as diazepam, lorazepam, and clonazepam, and calcium channel blockers such as flunarizine. Representative antiemetics include antidopaminergics such as domperidone and metoclopramide, and serotonin receptor antag-

onists, such as ondansetron [17,18]. During the acute stage of vestibular neuritis, an intramuscular or intravenous route for vestibular suppressants and antiemetics is usually preferable because of severe nausea and decreased gastric motility. The response is clearly dose-dependent; therefore, if the initial dose is not effective, higher doses should be administered [38]. However, most vestibular suppressants can have sedative effects, so they should not be used when patients are engaged in activities that require a high level of alertness, such as driving, operating machinery, or participating in athletic activities; long-term use of vestibular suppressants, which should be used carefully while monitoring the patient's recovery progress, is known to delay the central compensation of vestibular neuritis [19,38].

Regarding specific drug therapy, steroid therapy has been reported to relieve dizziness and promote vestibular compensation in vestibular neuritis; methylprednisolone is much more effective than placebo in reducing vertiginous symptoms in patients with acute vestibular vertigo [39], and early treatment of acute vestibular neuritis with high doses of glucocorticoids accelerates and improves the recovery of vestibular function [40]. However, some reports have shown that steroid therapy has no beneficial effects on the long-term prognosis of vestibular neuritis [41,42]. Therefore, steroid therapy for vestibular neuritis has yet to be clarified and is provided on an individual basis [18,40]. Antiviral therapy based on the etiology of viral infection of vestibular neuritis has also been reported. However, administration of antivirals alone or in combination with steroids has no therapeutic effect on vestibular neuritis [17,43]. In addition, vasodilator therapy based on the etiology of ischemia of vestibular neuritis has not yet been proven to have a therapeutic effect in vestibular neuritis [44].

In vestibular rehabilitation therapy, the goals are to improve vertigo, gaze stability, postural stability, and daily living activities through vestibular compensation and central neuroplasticity [45,46]. Vestibular compensation can be divided into static and dynamic compensation [47]. Static compensation is usually attributed to the restoration of symmetry in the resting discharge rates of secondary neurons on the two sides of the brainstem. The rebalancing of resting discharges in the vestibular nuclei may involve a decrease in the efficacy of both  $\gamma$ -aminobutyric acid type A and type B receptors and an increase in neuronal excitability on the damaged side [47,48]. Dynamic compensation refers to the compensation of vestibular reflexes that are activated by movement and is composed of adaptation, habituation, and substitution [17,45, 47,49]. It is achieved through vestibular rehabilitation exercises that are safe, highly therapeutic, and highly cost-effective for patients with vestibular neuritis [49-51].

Vestibular rehabilitation exercises are mainly divided into gener-

alized and customized vestibular exercises. A representative generalized vestibular exercise is the Cawthorne-Cooksey exercise, and representative customized vestibular exercises include adaptation exercises, habituation exercises, balance and gait exercises, and general conditioning exercises, which are more effective than generalized vestibular exercises [46,52]. Vestibular exercises significantly hasten vestibulospinal compensation in patients with acute vestibular neuritis [17]. Balance and gait exercises significantly reduce the time required for vestibulospinal compensation [19]. Voluntary eye movements, active head movements, goal-directed movements, and walking should be encouraged to restore postural control and balance as soon as possible. Patients with vestibular neuritis should exercise for at least 30 minutes three times a day [17,19].

Regarding the prognosis, most patients with vestibular neuritis have subacute or acute spontaneous vertigo that gradually aggravates over several hours and reaches a peak within the first day. Severe vertigo improves markedly within a day or two, with residual symptoms gradually resolving over the following weeks [17]. The symptoms and signs of static vestibular imbalances, such as spontaneous nystagmus, ocular torsion, and ipsilesional subjective visual vertical tilt, are mostly resolved by 3 months after the onset of vestibular neuritis, while the signs of dynamic vestibular imbalances, such as corrective saccades of head impulse test, head shaking nystagmus, vibration-induced nystagmus, and caloric paresis, persist over 1 year in more than 30% of patients with vestibular neuritis [19]. The persistent imbalance that some patients experience after acute vestibular neuritis may be due to many factors, including inadequate central compensation, incomplete peripheral recovery, and psychophysiological and psychological features. Vestibular neuritis is known to recur in only 2% to 11% of cases [17,19].

## Conclusion

Vestibular neuritis, also known as vestibular neuronitis, is a representative peripheral vertigo. The causes of vestibular neuritis are not yet clear, but mainly viral infection, ischemia, and immune-mediated mechanisms. The characteristic clinical features of vestibular neuritis are abrupt true-whirling vertigo lasting for more than 24 hours, and no presence of cochlear symptoms and other neurological symptoms and signs. To accurately diagnose vestibular neuritis, various diagnostic tests such as the head impulse test, bithermal caloric test, and vestibular-evoked myogenic potential test are conducted. Symptomatic therapy, specific drug therapy, and vestibular rehabilitation therapy have been studied and implemented for the treatment of vestibular neuritis. Nevertheless, additional studies are needed to clarify the cause, diagnosis, and treatment of vestibular neuritis in the future, and this review is expected to pro-

vide more information on the diagnosis and treatment of patients with acute spontaneous vertigo.

## Notes

### Conflicts of interest

No potential conflicts of interest relevant to this article was reported.

### Funding

None.

### Author contributions

Conceptualization: CHB, HGN, YSC; Formal analysis, Supervision: CHB, HGN; Writing - original draft: CHB; Writing - review & editing: CHB, YSC.

### ORCID

Chang Hoon Bae, <https://orcid.org/0000-0002-0835-4060>

Hyung Gyun Na, <https://orcid.org/0000-0003-4017-4796>

Yoon Seok Choi, <https://orcid.org/0000-0002-0616-7122>

## References

- Bisdorff AR, Staab JP, Newman-Toker DE. Overview of the International Classification of Vestibular Disorders. *Neurol Clin* 2015;33:541–50.
- Strupp M, Mandalà M, López-Escámez JA. Peripheral vestibular disorders: an update. *Curr Opin Neurol* 2019;32:165–73.
- von Brevern M, Bertholon P, Brandt T, Fife T, Imai T, Nuti D, et al. Benign paroxysmal positional vertigo: diagnostic criteria. *J Vestib Res* 2015;25:105–17.
- Tabet P, Saliba I. Meniere's disease and vestibular migraine: updates and review of the literature. *J Clin Med Res* 2017;9:733–44.
- Lopez-Escamez JA, Carey J, Chung WH, Goebel JA, Magnusson M, Mandalà M, et al. Diagnostic criteria for Menière's disease. *J Vestib Res* 2015;25:1–7.
- Whitman GT. Dizziness. *Am J Med* 2018;131:1431–7.
- Brandt T. Vestibular neuritis. In: Brandt T. *Vertigo: its multisensory syndrome*. 2nd ed. London: Springer-Verlag; 2003. p. 67–81.
- Nylén CO. Some cases of ocular nystagmus due to certain positions of the head. *Acta Otolaryngol (Stockholm)* 1924;6:106–37.
- Lumio JS, Aho J. Vestibular neuronitis. *Ann Otol Rhinol Laryngol* 1965;74:264–70.
- Strupp M, Magnusson M. Acute unilateral vestibulopathy. *Neurol Clin* 2015;33:669–85.
- Adamec I, Krbot Skorić M, Handžić J, Habek M. Incidence, seasonality and comorbidity in vestibular neuritis. *Neurol Sci* 2015;36:91–5.
- Strupp M, Brandt T. Vestibular neuritis. In: Bronstein AM, editor. *Oxford textbook of vertigo and imbalance*. Oxford: Oxford University Press; 2013. p. 207–16.
- Neuhauser HK. Epidemiology of vertigo. *Curr Opin Neurol* 2007;20:40–6.
- Wiener-Vacher SR, Quarez J, Priol AL. Epidemiology of vestibular impairments in a pediatric population. *Semin Hear* 2018;39:229–42.
- Hülse R, Biesdorf A, Hörmann K, Stuck B, Erhart M, Hülse M, et al. Peripheral vestibular disorders: an epidemiologic survey in 70 million individuals. *Otol Neurotol* 2019;40:88–95.
- Greco A, Macri GF, Gallo A, Fusconi M, De Virgilio A, Pagliuca G, et al. Is vestibular neuritis an immune related vestibular neuropathy inducing vertigo? *J Immunol Res* 2014;2014:459048.
- Jeong SH, Kim HJ, Kim JS. Vestibular neuritis. *Semin Neurol* 2013;33:185–94.
- Le TN, Westerberg BD, Lea J. Vestibular neuritis: recent advances in etiology, diagnostic evaluation, and treatment. *Adv Otorhinolaryngol* 2019;82:87–92.
- Kim JS. When the room is spinning: experience of vestibular neuritis by a neurologist. *Front Neurol* 2020;11:157.
- Shikino K, Ikusaka M. Alexander's law in vestibular neuritis. *BMJ Case Rep* 2021;14:e239705.
- Halmagyi GM, Gresty MA, Gibson WP. Ocular tilt reaction with peripheral vestibular lesion. *Ann Neurol* 1979;6:80–3.
- Choi KD, Oh SY, Kim JS. Head thrust test. *Ann Clin Neurophysiol* 2006;8:1–5.
- Kattah JC. Use of HINTS in the acute vestibular syndrome. An overview. *Stroke Vasc Neurol* 2018;3:190–6.
- Lee YJ, Shin JE, Park MS, Kim JM, Na BR, Kim CH, et al. Comprehensive analysis of head-shaking nystagmus in patients with vestibular neuritis. *Audiol Neurootol* 2012;17:228–34.
- Hain TC, Fetter M, Zee DS. Head-shaking nystagmus in patients with unilateral peripheral vestibular lesions. *Am J Otolaryngol* 1987;8:36–47.
- Sharpe JA. Neurophysiology and neuroanatomy of smooth pursuit: lesion studies. *Brain Cogn* 2008;68:241–54.
- Han SB, Yang HK, Hyon JY, Seo JM, Lee JH, Lee IB, et al. Efficacy of a computerized optokinetic nystagmus test in prediction of visual acuity of better than 20/200. *Invest Ophthalmol Vis Sci* 2011;52:7492–7.
- Choi YS, Na HG, Song SY, Kim YD, Bae CH. Clinical signifi-

- cance of saccade test, smooth pursuit test, and optokinetic nystagmus test in nystagmography. *Yeungnam Univ J Med* 2017; 34:29–36.
29. Min KK, Ha JS, Kim MJ, Cho CH, Cha HE, Lee JH. Clinical use of subjective visual horizontal and vertical in patients of unilateral vestibular neuritis. *Otol Neurotol* 2007;28:520–5.
  30. Okinaka Y, Sekitani T, Okazaki H, Miura M, Tahara T. Progress of caloric response of vestibular neuronitis. *Acta Otolaryngol Suppl* 1993;503:18–22.
  31. Rosengren SM, Colebatch JG, Young AS, Govender S, Welgampola MS. Vestibular evoked myogenic potentials in practice: methods, pitfalls and clinical applications. *Clin Neurophysiol Pract* 2019;4:47–68.
  32. Shim DB, Song MH, Park HJ. Typical sensory organization test findings and clinical implication in acute vestibular neuritis. *Auris Nasus Larynx* 2018;45:916–21.
  33. Hong HR, Shim DB, Kim TS, Shim BS, Ahn JH, Chung JW, et al. Results of caloric and sensory organization testing of dynamic posturography in migrainous vertigo: comparison with Meniere's disease and vestibular neuritis. *Acta Otolaryngol* 2013; 133:1236–41.
  34. Ahmed ME, Goebel JA, Sinks BC. Caloric test versus rotational sinusoidal harmonic acceleration and step-velocity tests in patients with and without suspected peripheral vestibulopathy. *Otol Neurotol* 2009;30:800–5.
  35. Hamid MA. Clinical value of sinusoidal harmonic acceleration test results. Site of lesion and side of lesion. *Neurol Clin* 1990; 8:287–95.
  36. Karlberg M, Annertz M, Magnusson M. Acute vestibular neuritis visualized by 3-T magnetic resonance imaging with high-dose gadolinium. *Arch Otolaryngol Head Neck Surg* 2004;130: 229–32.
  37. Linstrom CJ. Office management of the dizzy patient. *Otolaryngol Clin North Am* 1992;25:745–80.
  38. Baloh RW. Clinical practice. Vestibular neuritis. *N Engl J Med* 2003;348:1027–32.
  39. Ariyasu L, Byl FM, Sprague MS, Adour KK. The beneficial effect of methylprednisolone in acute vestibular vertigo. *Arch Otolaryngol Head Neck Surg* 1990;116:700–3.
  40. Sjögren J, Magnusson M, Tjernström F, Karlberg M. Steroids for acute vestibular neuronitis—the earlier the treatment, the better the outcome? *Otol Neurotol* 2019;40:372–4.
  41. Shupak A, Issa A, Golz A, Margalit Kaminer, Braverman I. Prednisone treatment for vestibular neuritis. *Otol Neurotol* 2008; 29:368–74.
  42. Goudakos JK, Markou KD, Psillas G, Vital V, Tsaligopoulos M. Corticosteroids and vestibular exercises in vestibular neuritis. Single-blind randomized clinical trial. *JAMA Otolaryngol Head Neck Surg* 2014;140:434–40.
  43. Strupp M, Zingler VC, Arbusow V, Niklas D, Maag KP, Dieterich M, et al. Methylprednisolone, valacyclovir, or the combination for vestibular neuritis. *N Engl J Med* 2004;351:354–61.
  44. Ramos Alcocer R, Ledezma Rodríguez JG, Navas Romero A, Cardenas Nuñez JL, Rodríguez Montoya V, Deschamps JJ, et al. Use of betahistine in the treatment of peripheral vertigo. *Acta Otolaryngol* 2015;135:1205–11.
  45. Lacour M, Helmchen C, Vidal PP. Vestibular compensation: the neuro-otologist's best friend. *J Neurol* 2016;263(Suppl 1):S54–64.
  46. McDonnell MN, Hillier SL. Vestibular rehabilitation for unilateral peripheral vestibular dysfunction. *Cochrane Database Syst Rev* 2015;1:CD005397.
  47. Heskin-Sweezie R, Titley HK, Baizer JS, Broussard DM. Type B GABA receptors contribute to the restoration of balance during vestibular compensation in mice. *Neuroscience* 2010;169:302–14.
  48. Igarashi M. Vestibular compensation. An overview. *Acta Otolaryngol Suppl* 1984;406:78–82.
  49. Rossi-Izquierdo M, Santos-Pérez S, Soto-Varela A. What is the most effective vestibular rehabilitation technique in patients with unilateral peripheral vestibular disorders? *Eur Arch Otorhinolaryngol* 2011;268:1569–74.
  50. Hillier S, McDonnell M. Is vestibular rehabilitation effective in improving dizziness and function after unilateral peripheral vestibular hypofunction? An abridged version of a Cochrane Review. *Eur J Phys Rehabil Med* 2016;52:541–56.
  51. Han BI, Song HS, Kim JS. Vestibular rehabilitation therapy: review of indications, mechanisms, and key exercises. *J Clin Neurol* 2011;7:184–96.
  52. Eleftheriadou A, Skalidi N, Velegrakis GA. Vestibular rehabilitation strategies and factors that affect the outcome. *Eur Arch Otorhinolaryngol* 2012;269:2309–16.