

C1q Nephropathy in Children with Nephrotic Syndrome: Treatment Strategies and Outcomes

Abstract

Introduction: There is a paucity of clinical data on C1q nephropathy (C1qN) in children in India and Southeast Asia. This is the first detailed analysis conducted to elucidate the prevalence, clinicopathological profile, and response to different immunosuppressives in children with C1qN in India. **Materials and Methods:** Detailed demographic profile, clinical features, urine and blood chemistries, kidney biopsy, and response to different immunosuppressives of the study participants were analyzed between August 2015 and October 2020 for steroid-dependent/-resistant nephrotic syndrome (NS). **Results:** C1qN was diagnosed in 16 (14.13%) of 113 children who underwent biopsy for steroid-dependent/-resistant NS. The mean age was 44 months (range 18–99 months) and male and female number was 12 (75%) and four (25%), respectively, and mean follow-up was 3.5 years. Eight (50%) had coexistent minimal-change nephrotic syndrome (MCNS) pattern, seven (43.7%) had focal segmental glomerulosclerosis (FSGS), and one (6.2%) had diffuse mesangial hypercellularity. Thirteen children had complete follow-up, of which eight (61.5%) and four (30.7%) cases presented as steroid-dependent and primary steroid-resistant NS, respectively, whereas one (7.6%) had joint pain with rashes. At presentation, seven (53.8%) had hypertension, 12 (92.3%) had nephrotic range proteinuria, and six cases (46.1%) had hematuria. Nine (75%) of 12 cases achieved complete remission with calcineurin inhibitor (CNI) therapy, and two were non responders, one was a partial responder, and one responded to mycophenolate. Of six FSGS cases, four had complete remission, one had partial remission, and one was in non-remission. Of six cases with MCNS, five had complete remission and one was in non-remission. Renal functions remained normal in all except one case who had progression to chronic kidney disease Stage 3. **Conclusion:** One out of seven children with difficult NS can have underlying C1qN. CNIs are most beneficial to attain and maintain remission. Renal functions remain normal in the majority. Along with C1q deposits, MCNS and FSGS patterns are seen equally and respond almost similarly to CNIs.

Keywords: C1q nephropathy, calcineurin inhibitors, FSGS, minimal-change disease

Introduction

C1q nephropathy (C1qN) is a type of glomerular injury characterized by predominant mesangial deposition of C1q, and the most common presentation in children is with nephrotic syndrome (NS). The incidence of C1qN is 0.2% to 2.5% in adult studies and an increased incidence of up to 16% in pediatric studies.^[1] The clinical presentation and response to treatment are varied and the patients present from being steroid responders to non-responders. To our knowledge, there is no prior descriptive study published among Indian children with this condition. The light microscopic (LM) findings and patterns of injury are heterogeneous ranging from

focal segmental glomerulosclerosis (FSGS) to minimal-change disease (MCD) and even diffuse mesangial hypercellularity. This study aims to analyze the patterns of clinical profile, histopathological features, and response to treatment in children diagnosed with C1qN.

Materials and Methods

This is a retrospective case series analysis done at a tertiary referral pediatric hospital conducted over a period of 5 years from June 2015 to November 2020. This is the first descriptive study on this condition in Indian children across all states and even various Southeast Asian countries.

During the study period, 113 kidney biopsies conducted in children with steroid-dependent or steroid-resistant

This is an open access journal, and articles are distributed under the terms of the Creative Commons Attribution-NonCommercial-ShareAlike 4.0 License, which allows others to remix, tweak, and build upon the work non-commercially, as long as appropriate credit is given and the new creations are licensed under the identical terms.

For reprints contact: WKHLRPMedknow_reprints@wolterskluwer.com

How to cite this article: Gaur S, Patrick R, Vankalakunti M, Phadke K. C1q nephropathy in children with nephrotic syndrome: Treatment strategies and outcomes. Indian J Nephrol 2022;32:54-9.

Saumil Gaur,
Reeba Patrick,
Mahesha Vankalakunti¹,
Kishore Phadke¹

Division of Paediatric
Nephrology, Rainbow Children's
Hospital, Marathahalli,
¹Department of Pathology,
Manipal Hospitals, Old Airport
Road, Bangalore, Karnataka,
India

Received: 20-12-2020

Revised: 15-03-2021

Accepted: 10-05-2021

Published: 13-11-2021

Address for correspondence:

Dr. Saumil Gaur,
Division of Paediatric
Nephrology, Rainbow Children's
Hospital, Marathahalli,
Bangalore, Karnataka, India.
E-mail: saumil.gaur@gmail.com

Access this article online

Website: www.indianj nephrol.org

DOI: 10.4103/ijn.IJN_578_20

Quick Response Code:



NS were analyzed. Clinical data were collected from electronic records facility available at the institution. Data included age, sex, clinical presentation, urinalysis, serum creatinine, renal biopsy findings, and response to various immunosuppressive medications. Appropriate clearance from Institutional Ethical Board (RCHEC/03/2020) was obtained for the study and was reviewed at the onset and at completion by the Board.

Standard definitions were followed to define the cases and were subsequently used for the analysis. NS was defined as edema with nephrotic range proteinuria (urine protein: creatinine ratio >2), hypoalbuminemia, and hypercholesterolemia. Steroid dependence was defined as the condition when there was a relapse on alternate day prednisolone or a relapse within 2 weeks after stopping the prednisolone, and when this happened on two consecutive occasions. Steroid resistance was defined as non-remission after 6 weeks of treatment with 60 mg/m²/day or 2 mg/kg of prednisolone.

Diagnosis of C1qN was considered and the participants were enrolled for analysis as per the criteria given by Jennette and Hipp.^[2] The presence of dominant or codominant C1q staining on immunofluorescence (IF) in kidney biopsy in a child with mesangial or paramesangial deposits was diagnostic of C1qN. All patients who had clinical or biochemical evidence of lupus nephritis, C3 glomerulonephritis, hypocomplementemia, and IgA nephropathy were excluded. A clinicopathological correlation was performed using the light LM and IF findings. As the institutional practice was to conduct electron microscopy (EM) for only cases with “steroid resistance,” it could be conducted only for four cases among the study population, which had steroid-resistant course.

Of the 13 children with biopsy-proven C1qN, complete clinical and treatment data were available for 10 children who remained under regular follow-up. Three children were lost to follow-up owing to their inability for follow-up, and hence their response and outcome to therapy are not included in this descriptive study. The mean duration of follow-up was 3.5 years (range 6 months to 4.5 years) with regular time-bound outdoor patient visits along with urine and blood chemistries.

Results

The percentage of C1qN in our study population was noted to be 14.13% ($n = 16$) out of 113 biopsies conducted. The age of onset of NS ranged from 18 months to 99 months (mean age was 44 months). There were 12 males and 4 females, out of total 16 cases. The presentation of C1qN among 13 described cases was varied as four (30.7%) participants presented with primary steroid resistance, eight (61.5%) presented as steroid-dependent NS, and one participant had NS with joint involvement

and purpuric rash [Table 1]. One case had progressive renal dysfunction and progression to chronic kidney disease (CKD) Stage 3, whereas the rest had normal serum creatinine for age for entire duration of follow-up. Seven out of 13 (53.8%) participants had hypertension on presentation and six (46.1%) had hematuria.

In accordance with the inclusion criteria, all the 16 patients had C1q deposits in the mesangium [Figure 1]. LM and IF examination revealed that eight (50%) patients had minimal-change pattern, seven (43.7%) had FSGS, and one patient had diffuse mesangial hypercellularity [Table 2], and full house pattern was present in seven patients (43.75%). EM was conducted in four steroid-resistant patients, which revealed near-similar diffuse effacement of visceral epithelial cell foot processes with mesangial and paramesangial electron-dense deposits [Figure 2]. The ultrastructural features suggested a primary podocytopathy/diffuse podocyte injury accompanied by conventional immune complex-type electron-dense deposits, correlating with the LM/IF findings. The subepithelial spherular microparticles (30–80 nm) aggregates seen in three out of four EM cases represent a degenerative phenomenon in the present context. An interesting observation was the transformation from minimal-change biopsy pattern to C1qN with minimal-change pattern in a single patient during repeat biopsy 3 years later while being on tacrolimus. In view of the non-availability of clinical data of three participants, which included two minimal-change nephrotic syndrome (MCNS) and one FSGS, they are not described in the subsequent discussion.

The gross outcomes on the basis of histopathological diagnosis, namely, C1qN+FSGS and C1qN+MCNS are quite comparable mutually in this pediatric cohort. Among six FSGS cases, four (66.66%) had complete remission, one (16.67%) had partial remission, and one (16.67%) was in non-remission, whereas among six cases with MCNS,

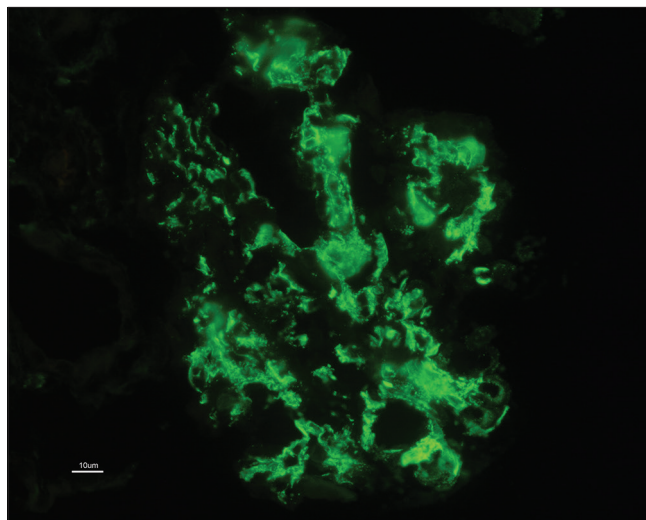


Figure 1: High-power resolution image of mesangial C1q deposits

Table 1: Distribution of clinical presentation

Case No.	Age at onset (months)/Sex	Hematuria/Urine Spot PCR	Serum Creatinine (mg/dL)	Presentation/Hypertension
1	29/Female	Nil/>2	0.3	SD
2	27/Female	Nil/>2	0.3	SD
3	49/Male	Nil/>2	0.3	SD + HT
4	72/Male	Nil/>2	0.4	SR + HT
5	99/Male	Present/<0.2	0.4	Swelling, rash, and joint pain
6	25/Female	Present/>2	0.3	SR + HT
7	136/Male	Nil/>2	1	SD + HT
8	25/Male	Nil/>2	0.2	SR
9	24/Male	Nil/>2	0.2	SD + HT
10	17/Male	Present/>2	0.2	SD + HT
11	12/Male	Present/>2	0.2	SRNS
12	38/Male	Present/>2	0.2	SDNS
13	144/Female	Present/>2	0.3	SRNS + HT

SD=steroid dependent, SR=steroid resistant, PCR=Protein creatinine ratio, HT=Hypertension, SRNS=steroid-resistant nephrotic syndrome, SDNS=steroid-dependent nephrotic syndrome. Thirteen out of 16 cases are represented here which were under follow-up

Table 2: Distribution of renal histopathology among 13 cases that had prolonged follow-up

Case No.	Presentation	Light Microscopy	Immunofluorescence
1	SD	Minimal change	C1q 2+, IgG 2+
2	SD	Minimal change	C1q 2+, IgG 1-2 +, IgM 1-2+
3	SD	FSGS	C1q 2+, IgG 2+
4	SR	FSGS	C1q 3+, IgG 2+
5	Swelling, rash, and joint pain	Minimal change	C1q 2+, IgG 2+, IgM 2+
6	SR	Diffuse mesangial hypercellularity	C1q 2+, IgG 2 +
7	SD	FSGS	C1q 2+, IgG 2+, IgM 1+, C3 1+,
8	SR	Minimal change	C1q 3+, IgG 3+, IgM 1+, C3 1+
9	SD	FSGS	C1q 2+, IgG 2+, IgA1+, IgM2+, C3 2+
10	SD	FSGS	C1q2+, IgG 2+, IgM +, C3+,
11	SR	Minimal change	C1q2+, IgG2+, IgM1+, C3+
12	SD	Minimal change	C1q2+, IgG 2+, IgM+, C3+,
13	SR	FSGS	C1q2+, IgG 3+, IgM 1+C3 2+,

Distribution of the remaining three cases with no follow-up : Minimal change - 2; FSGS - 1. SD=steroid dependent, SR=steroid resistant, FSGS=focal segmental glomerulosclerosis

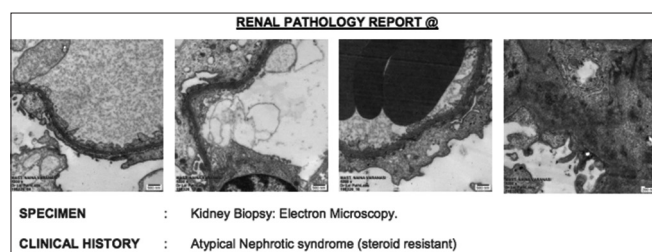


Figure 2: High-resolution electron microscopy image of mesangial and paramesangial deposits

five (83.33%) had complete remission and one (16.67%) was in non-remission with preserved renal function, and one (16.67%) patient with FSGS in this cohort had progressed to CKD Stage 3 during the study duration.

Apart from prednisolone, calcineurin-inhibiting agents such as tacrolimus/cyclosporine, mycophenolate, and rituximab were different immunosuppressive agents administered to maintain remission with varied responses [Table 3], and none of the children were administered cyclophosphamide.

Nine of 12 participants showed a good response with prolonged usage (more than 6 months) of calcineurin inhibitors (CNIs; tacrolimus/cyclosporine). One child who presented with rashes and joint pains exhibited a good response with MMF. Among two children who failed to have a response to any medications and continued to be proteinuric in the nephrotic range, each had diffuse mesangial cellularity and FSGS as a concomitant histopathological pattern.

It was interesting to note that majority of the participants (4/6 25%) with C1q and FSGS pattern showed response with CNIs except two. Five participants continued to relapse while being on MMF and hence were shifted to CNI therapy after biopsy, which suggested lower therapeutic efficacy of MMF in C1qN. A solitary patient with C1qN with diffuse mesangial cellularity has been refractory to multiple immunosuppressives, such as CNIs, MMF, and rituximab, and continues to remain as non-responder.

Table 3: Distribution of treatment given and response noted

Case No.	Light Microscopy	Therapy	Duration of Follow-Up (Months)	Serum Creatinine (mg/dL)	Urine PCR	Outcome
1	Minimal change	Tacrolimus	51	0.3	0.3	CR
2	Minimal change	Tacrolimus	29	0.3	0.23	CR
3	FSGS	Mycophenolate, tacrolimus	25	0.4	0.3	CR
4	FSGS	Tacrolimus, cyclosporine	22	0.3	0.2	CR
5	Minimal change	Mycophenolate	12	0.4	0.2	CR
6	Diffuse mesangial hypercellularity	Cyclosporine, mycophenolate, rituximab, tacrolimus	11	0.3	0.38	NR
7	FSGS	Tacrolimus	18	1	1.4	PR CKD 3
8	Minimal change	Cyclosporine	7	0.2	0.34	CR
9	FSGS	Mycophenolate, tacrolimus	7	0.2	0.23	CR
10	FSGS	Mycophenolate, cyclosporine	6	0.2	0.18	CR
11	MCNS	Cyclosporine	5	0.3	0.2	CR
12	MCNS	Cyclosporine	6	0.2	0.18	CR
13	FSGS	Tacrolimus	4	0.3	3	NR

FSGS=focal segmental glomerulosclerosis, MCNS=minimal-change nephrotic syndrome, CR=Complete remission; NR=No remission, PR=Partial remission

Discussion

C1qN was first described in 1985 by Jennette and Hipp.^[2] It has been earlier described to be a variant of FSGS but later was noted to have an immune component.^[3] C1q is a complement component consisting of three polypeptide chains – A, B, and C.^[4] C1q is the regulating factor for the complement system. It plays a role in the C1-dependent classical pathway, where IgM and IgG bind to the Fc portion of the C1q and activate the C1r and C1s esterase.^[5] C1qN is characterized by mesangial deposition of C1q seen on IF. It has a varied presentation on LM comprising of MCD, FSGS, and proliferative glomerulonephritis.^[6] The spectrum of presentation of C1qN appears to be quite varied. Analysis by Iskandar *et al.*^[1] described a series of 15 pediatric patients among which were steroid-dependent, frequent relapser, and steroid-resistant patients. They also had noted a nephritic onset with persistent proteinuria as was seen with our patient.^[1]

Based on LM, C1qN can be classified into two subtypes: one group comprising of MCD/FSGS picture and another with proliferative glomerulonephritis.^[7] There are authors who describe C1qN and report that it appears more similar to FSGS. IF is the mainstay of diagnosis of C1qN. Radiolabeled antisera specific for C1q stains deposit in the mesangium. Even multiple patterns of staining have been noted. IgG, IgA, and C3 have also been noted as codominant stains, and full house patterns have been isolated.^[1,6,8] Similar pattern of presentation was noted in the present case series – steroid-resistant and steroid-dependent course.

C1qN in adults usually presents as NS with diffuse mesangial proliferative (MePGN) changes in histopathology reported by adult case series from the western part of India.^[7] In this series of 11 patients, five (41%) had MePGN

followed by FSGS in three (25%), and one case each of MCNS, Acute Tubulointerstitial Interstitial Nephritis ATIN, and segmental endocapillary proliferation.^[7] The histopathology pattern among another series from the southern part of India ($n = 13$) was predominantly diffuse proliferative glomerular nephritis (12 out of 13 cases), and almost all were females.^[9] Our observation in the pediatric cohort was much equitably distributed as seven (43.7%) had FSGS, eight (50%) had MCNS, and one had diffuse proliferation among the 16 biopsies, which was relatively quite different when compared with the adult population. This was reasonably closer to the Japanese pediatric cohort, where 76% had MCNS,^[10] and FSGS was quite lower in prevalence. This could be explained by the ethnic differences between the Japanese and Indian populations.

There have been reports of C1q deposits detected in asymptomatic individuals and has been even described in post-renal transplant biopsies in donor kidneys.^[11] Nishida *et al.*^[12] have described an incidental pick up of urinary abnormalities in asymptomatic children during a school screening program. There were four asymptomatic children who were noted to have proteinuria (non-nephrotic range) and one child with gross hematuria. In biopsy, all children fulfilled the criteria for C1q. Among adults with C1qN, almost all had hypertension and microscopic hematuria, although nephrotic range proteinuria was found only in 75%,^[9] whereas in this pediatric cohort, seven out of 13 (53.8%) participants had hypertension on presentation and six (46.1%) had hematuria on presentation, and 12 (92.3%) presented with NS.

Response to individual therapeutic agents

Treatment guidelines for C1qN have not been laid down in children and adults as there is a paucity of randomized controlled trials on C1qN among both subsets.

Immunosuppressants constitute the mainstay of treatment, and corticosteroids are first line of therapy along with alternate immunosuppressives in nonresponsive cases.^[13]

We feel that CNIs appear to be the most beneficial in C1qN as nine of 12 (75%) patients remained in sustained remission. MMF was found to be inferior in the majority of cases as five cases had to be shifted to CNIs who remained in sustained remission after the shift, and the solitary child continues to be in sustained remission while being on it. Rituximab, a monoclonal antibody against CD20, has been used previously in two cases who responded as per the published case report from the northern part of India.^[14] However, in this case series, rituximab was administered to patient who could not achieve complete remission and continues to remain as a partial responder. Further analysis would be required to draw conclusions on the outcome of C1qN in relation with underlying histology subtype (MCNS/FSGS). Another interesting presentation was a single child with generalized swelling, NS along with joint pains with purpuric rashes whose skin biopsy was suggestive of leukocytoclastic vasculitis; however, renal biopsy suggested C1qN with MCNS morphology. This particular patient remains in complete remission with MMF and remains as the sole responder to MMF in this case series. This presentation is not described in the medical literature and needs further understanding in similar cases across the globe.

The overall general outcome of C1qN in children was noted to be more favorable compared with adults as five among 13 (39%) cases in the case series by Bhaba *et al.*^[9] did not respond to steroids and cyclophosphamide. It is noteworthy to observe that patients in this series were not given CNIs, mycophenolate mofetil, or rituximab, hence significant conclusions cannot be drawn.

It was also evident in our cohort that histopathological diagnosis such as MCNS/FSGS along with C1q deposits had a reasonably comparable response to similar immunosuppressants used in both groups. Of six FSGS cases, four (66.66%) had complete remission, one (16.67%) had partial remission, and one (16.67%) was in non-remission, whereas among six cases with MCNS, five (83.33%) had complete remission and one was in non-remission (16.67%). Analytical statistical tools such as Chi-square test for comparison and assessment of response in both groups were not contemplated due to the lesser number of cases in both groups. Concomitantly, there is a paucity of data on the appropriate choice of immunosuppressives such as CNIs, MMF, and rituximab in cases with C1qN among adults, and this can be better delineated with appropriate trials in the future. Our observational analysis in children with present data is a stepping stone for future research in children and adults alike.

Conclusion

C1qN should be suspected in steroid-resistant/-dependent forms of NS in children. MCNS and FSGS are common histopathological patterns seen almost equally and both have near-equal propensity to respond to alternate immunosuppressants. Microscopic hematuria and hypertension are common associations. C1qN does not present with or lead to renal dysfunction in the immediate period of presentation. It can be suggested by the observations of the present study that CNIs can be used as first-line therapy along with prednisolone.

Declaration of patient consent

The authors certify that they have obtained all appropriate patient consent forms. In the form, the patient (s) has/have given his/her/their consent for his/her/their images and other clinical information to be reported in the journal. The patients understand that their names and initials will not be published and due efforts will be made to conceal their identity, but anonymity cannot be guaranteed.

Financial support and sponsorship

Nil.

Conflicts of interest

There are no conflicts of interest.

References

1. Iskandar S, Browning M, Lorentz W. C1q nephropathy: A pediatric clinicopathologic study. *Am J Kidney Dis* 1991;18:459-65.
2. Jennette J, Hipp C. C1q nephropathy: A distinct pathologic entity usually causing nephrotic syndrome. *Am J Kidney Dis* 1985;6:103-10.
3. Yang Y-H, Lee W-S, Cheng C-Y. C1q nephropathy in a patient complicated with nephrotic syndrome and refractory to steroid therapy. *J Microbiol Immunol Infect* 2020;53:183-5.
4. Barnum S, Schein T, Morley B. *The Complement Facts Book*. 2017. Academic Press, Cambridge, USA
5. Yehuda Shoenfeld. *Autoantibodies*. 3rd ed. 2013. Elsevier USA
6. Devasahayam J, Erode-Singaravelu G, Bhat Z, Oliver T, Chandran A, Zeng X. C1q nephropathy: The unique underrecognized pathological entity. *Anal Cell Pathol (Amst)* 2015;2015:490413.
7. Kanodia K, Vanikar A, Patel R, Suthar K, Patel H, Gumber M. C1q nephropathy in India: A single-center study. *Saudi J Kidney Dis Transpl* 2015;26:398-403.
8. Markowitz G, Schwimmer J, Stokes M, Nasr S, Seigle R, Valeri A. C1q nephropathy: A variant of focal segmental glomerulosclerosis. *Kidney Int* 2003;64:1232-40.
9. Bhaba V, Gopalakrishnan N, Ilango C, Kumar P. Clinical outcomes and presentation in C1q nephropathy- A single centre prospective study. *Int J Sci Res* 2018;6:100-4.
10. Fukuma Y, Hisano S, Segawa Y, Niimi K, Tsuru N, Kaku Y. Clinicopathologic correlation of C1q nephropathy in children. *Am J Kidney Dis* 2006;47:412-8.
11. Vizjak A, Ferluga D, Rožič M, Hvala A, Lindič J, Levart T. Pathology, clinical presentations, and outcomes of C1q nephropathy. *J Am Soc Nephrol* 2008;19:2237-44.

12. Nishida M, Kawakatsu H, Okumura Y, Hamaoka K. C1q nephropathy with asymptomatic urine abnormalities. *Pediatr Nephrol* 2005;20:1669-70.
13. Levart TK, Kenda RB, Cavić MA, Ferluga D, Hvala A, Vizjak A. C1q nephropathy in children. *Pediatr Nephrol* 2005;20:1756-61.
14. Sinha A, Nast C, Hristea I, Vo A, Jordan S. Resolution of clinical and pathologic features of C1q nephropathy after rituximab therapy. *Clin Exp Nephrol* 2010;15:164-70.