

Multimodal treatment in oligometastatic gastric cancer

Mickael Chevally, Charles-Henri Wassmer, Pouya Iranmanesh, Minoa K Jung, Stefan P Mönig

ORCID number: Mickael Chevally 0000-0002-0056-2674; Charles-Henri Wassmer 0000-0002-9018-7088; Pouya Iranmanesh 0000-0002-6963-1164; Minoa K Jung 0000-0003-2352-4774; Stefan P Mönig 0000-0002-1256-7755.

Author contributions: Chevally M designed the manuscript structure; Chevally M and Wassmer CH performed the research; Chevally M, Wassmer CH, Iranmanesh P, Jung MK and Mönig SP analyzed the data and wrote the manuscript; all authors have read and approved the final manuscript.

Conflict-of-interest statement: The authors declare that there is no conflict of interest.

Country/Territory of origin: Switzerland

Specialty type: Oncology

Provenance and peer review: Invited article; Externally peer reviewed.

Peer-review model: Single blind

Peer-review report's scientific quality classification

Grade A (Excellent): 0
Grade B (Very good): 0
Grade C (Good): C, C
Grade D (Fair): 0
Grade E (Poor): 0

Open-Access: This article is an open-access article that was

Mickael Chevally, Charles-Henri Wassmer, Pouya Iranmanesh, Minoa K Jung, Stefan P Mönig, Division of Digestive Surgery, Geneva University Hospital and Faculty of Medicine, Geneva 1205, Genève, Switzerland

Corresponding author: Stefan P Mönig, MD, Surgeon, Division of Visceral Surgery, Department of Surgery, University of Geneva Hospitals, Rue Gabrielle-Perret-Gentil 4, Geneva 1205, Genève, Switzerland. stefan.moenig@hcuge.ch

Abstract

Gastric cancer is generally diagnosed at an advanced stage, especially in countries without screening programs. Previously, the metastatic stage was synonymous with palliative management, and surgical indications were only for symptomatic relief. However, this therapeutic option is associated with poor prognosis. A subgroup of patients with limited metastatic disease could benefit from intensive treatment. A combination of chemotherapy, immunotherapy, and targeted therapy could help either maintain a resectable state for oligometastatic disease or diminish the metastasis size to obtain a complete resection configuration. This latter strategy is known as conversion therapy and has growing evidence with favorable outcomes. Oncosurgical approach of metastatic disease could prolong survival in selected patients. The challenge for the surgeon and oncologist is to identify these specific patients to offer the best multimodal management. We review in this article the actual evidence for the treatment of oligometastatic gastric cancer with curative intent.

Key Words: Gastric cancer; Radiotherapy; Chemotherapy; Multimodal treatment; Oligometastasis; Immunotherapy

©The Author(s) 2022. Published by Baishideng Publishing Group Inc. All rights reserved.

Core Tip: Oligometastatic gastric cancer is an increasingly recognized clinical entity characterized by limited metastatic spread. With the development of multimodal treatment, curative treatment with complete surgical resection can be achieved. In our review, we have shown evidence that chemotherapy, immunotherapy, and targeted therapy could control the expansion of the tumor or decrease the size of the metastasis to achieve a resectable configuration. Surgery is not only a palliative option for metastatic disease but could be offered with curative intent in selected patients.

selected by an in-house editor and fully peer-reviewed by external reviewers. It is distributed in accordance with the Creative Commons Attribution NonCommercial (CC BY-NC 4.0) license, which permits others to distribute, remix, adapt, build upon this work non-commercially, and license their derivative works on different terms, provided the original work is properly cited and the use is non-commercial. See: <https://creativecommons.org/licenses/by-nc/4.0/>

Received: May 10, 2021

Peer-review started: May 10, 2021

First decision: June 16, 2021

Revised: August 2, 2021

Accepted: December 28, 2021

Article in press: December 28, 2021

Published online: February 15, 2022

P-Reviewer: Chen LJ, Yelamanchi R

S-Editor: Wang LL

L-Editor: Filipodia

P-Editor: Wang LL



Citation: Chevallay M, Wassmer CH, Iranmanesh P, Jung MK, Mönig SP. Multimodal treatment in oligometastatic gastric cancer. *World J Gastrointest Oncol* 2022; 14(2): 434-449

URL: <https://www.wjgnet.com/1948-5204/full/v14/i2/434.htm>

DOI: <https://dx.doi.org/10.4251/wjgo.v14.i2.434>

INTRODUCTION

Gastric cancer is the fourth most frequent cause of cancer-associated death worldwide [1]. The abundant vascularization and the rich lymphatic drainage explain the tendency of gastric cancer to spread quickly [2]. Gastric cancer can be divided into four stages: early, when the tumor involves only the stomach; locally advanced, when it involves the serosa or the regional lymph nodes; oligometastatic, when distant organs are involved but limited in number and size; and metastatic, when numerous distant organs are affected. Almost half of gastric cancers are diagnosed at an advanced stage in Western countries [2]. The most frequent organs concerned by metastasis at diagnosis presentation are the liver, the peritoneum, and distant lymph nodes [3].

Predominantly because of late-onset symptoms and lack of active screening programs, one-third of patients have distant metastases at presentation [4]. This late diagnosis implies poor prognosis. Although the median survival time has improved with the development of new chemotherapy regimens, it is still unsatisfactory in metastatic disease, ranging from 9 to 16 mo [5,6]. There is an urgent need to develop better treatment strategies. Surgery could be an option as the only definitive curative treatment. However, according to actual recommendations, patients with metastatic disease are ineligible for surgery and should receive systemic chemotherapy [7-9]. According to the TNM Classification of Malignant Tumors (TNM), single- and multiple-site metastases share the same M1 staging. However, tumors with a single-site metastasis could have, in theory, less aggressive behavior. A subclassification for metastatic disease was therefore required. The notion of oligometastatic disease was first introduced in 1995 by Hellman and Weichselbaum [10]. Initially, oligometastatic disease was characterized by the presence of fewer than five metastases. This definition has evolved and been challenged by expert groups. There is still a debate between two definitions: three to five synchronous metastatic foci in a single organ or metastatic disease affecting one or two organs with one or two foci per organ [11]. The size cutoffs accepted for oligometastatic foci is 3 cm [12]. Patients with this disease configuration could benefit from aggressive multimodal treatment with oncological treatment followed by surgery. We reviewed the actual evidence for each modality of treatment (surgical and oncological) for oligometastatic gastric cancer.

SURGERY FOR OLIGOMETASTATIC GASTRIC CANCER

Surgery for early or locally advanced gastric cancer with adequate lymphadenectomy is the only definitive curative treatment [13]. For metastatic gastric cancer, no actual guidelines recommend a curative surgical approach [14,15]. Inspired by compelling evidence in favor of surgery in patients with colorectal metastatic disease, the role of surgery in metastatic gastric cancer was questioned.

The liver is frequently involved in metastatic gastric cancer. Synchronous liver metastasis can be found in 5% to 10% of all diagnosed gastric cancer [16]. Hepatic resections for liver metastasis of gastric cancer are described in numerous studies with favorable long-term outcomes and acceptable morbidity. Surgical resection in selected patients has been shown to improve survival from several reports of 5-year survival between 0% and 42% [17-19].

A nationwide retrospective study from England showed that patients with gastric cancer and synchronous hepatic metastasis had better long-term survival when a gastrectomy combined with hepatectomy was performed compared with patients with gastrectomy with no liver resection (1-year survival: 50% for gastric and liver resection *vs* 35.9% for only gastrectomy; 5-year survival: 75.5% *vs* 61.7%, respectively) [20]. There was no difference in 30-d and 90-d morbidity and mortality between the two groups in their results. In particular, there was no difference in reoperation rates, readmission, postoperative pneumonia, and thromboembolic events between the two groups. These results suggest that the addition of hepatectomy to the primary tumor resection does not seem to affect the postoperative course in selected patients.

In their retrospective study, Takemura *et al*[21] showed that serosal invasion of the primary gastric cancer and hepatic metastasis larger than 5 cm in diameter was found to be independent indicators of poor prognosis. Some authors proposed criteria according to which hepatic metastasis would be potentially resectable: Number of metastases inferior to three, unilobar involvement, and diameter inferior of 5 cm[22]. Surgical treatment could be proposed in expert centers when these criteria are fulfilled with strict patient selection.

The only randomized trial that analyzed the role of surgery for metastatic gastric cancer is the REGATTA trial[23]. This multicentric, randomized Asian trial included patients with advanced gastric cancer and single-site metastasis. The authors compared the chemotherapy-only group with the gastrectomy-plus-adjuvant-chemotherapy group. The 2-year overall survival rate was 31.7% in the chemotherapy-only group and 25.1% in the gastrectomy-and-chemotherapy group, with a median overall survival of 16.6 mo and 14.3 mo, respectively. The authors concluded that surgical resection of the primary tumor did not offer a survival advantage and should not be recommended. However, some critique can be expressed about this trial. First, the metastatic lesions were not resected. Second, the patients did not receive chemotherapy before the surgical resection. Therefore, the REGATTA trial did not define the role of radical surgery in oligometastatic gastric cancer. A retrospective analysis including 5,185 cases from the U.S. Surveillance, Epidemiology, and End Results (SEER) database initially diagnosed with gastric cancer and distant metastases showed that the resection of the primary tumor and the combined resection of the metastasis were independent prognostic factors for survival improvement[24].

An observational study of the German Arbeitsgemeinschaft Internistische Onkologie (AIO) group, the FLOT-3 trial, analyzed the feasibility and efficacy of using induction chemotherapy followed by surgical resection with curative intent for selected patients with limited metastatic gastric and esophagogastric junction cancer [25]. This study had a three-armed design (locally advanced tumors, tumors with limited metastases, numerous metastatic tumors). The results showed favorable survival in the group of patients with limited metastatic disease who received neoadjuvant chemotherapy and subsequently underwent surgery with both primary tumor and metastatic location resection. In the limited metastatic group, the median overall survival was 31.3 mo for patients who proceeded with surgical resection and 15.9 mo for patient's ineligible for surgery (Figure 1). The FLOT-3 trial showed that surgery could have a potential survival benefit when primary and metastatic lesions were resected.

This was the justification for the concept of the ongoing FLOT 5-RENAISSANCE trial[26]. This multicenter randomized trial is recruiting patients with limited metastatic gastric and esophagogastric junction adenocarcinoma. Limited metastatic disease is defined as retroperitoneal lymph node metastases or one organ site that is resectable. Patients are to receive four cycles of chemotherapy alone or with trastuzumab if HER-2 positive. After four cycles, the patients without disease progression are randomized to receive additional chemotherapy cycles or surgical resection of the primary tumor and the metastases. These patients will receive subsequent postoperative chemotherapy (Figure 2).

Another ongoing randomized study is questioning the advantage of surgical resection compared to systemic therapy in oligometastatic stage IV metastatic gastric adenocarcinoma. The SURGIGAST study is an ongoing French multicentric randomized trial comparing the continuation of chemotherapy *vs* surgical removal of the primary tumor and the metastatic site in oligometastatic gastric cancer. The primary outcome is the overall survival with a follow-up of 2 years (*ClinicalTrials.gov identifier*: NCT03042169)[27]. The results of these two studies should determine the exact role of surgery in limited metastatic gastric cancer and set a new standard of therapy.

For incurable advanced gastric cancer, palliative resection is generally indicated in the presence of significant symptoms such as bleeding or obstruction whereas the usefulness of gastrectomy aimed at reducing tumor volume in asymptomatic patients remains unclear. With the improvement of the chemotherapy regimen, median overall survival has progressively increased, and surgery is now reserved for palliative situations.

In a curative intent, surgical treatment is in vain if the complete resection of the primary tumor and the metastatic site cannot be offered. A wrongful indication with R1 resection will add potential postoperative morbidity. This could delay chemotherapy treatment with a significant impact on patient survival. Surgical management of oligometastatic gastric cancer should be proposed to selected patients with controlled disease when there is a technical possibility of complete surgical

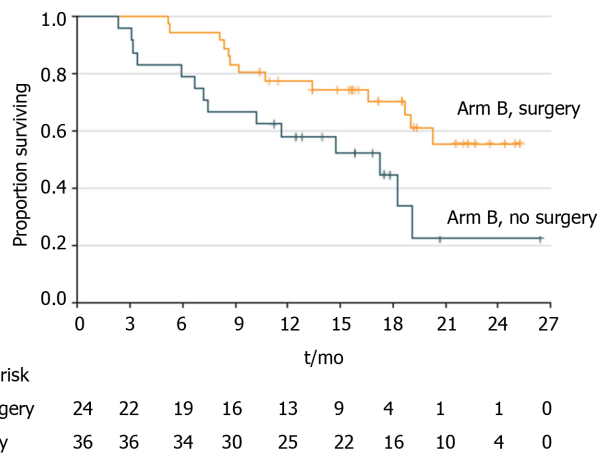


Figure 1 Kaplan-Meier analysis of overall survival in patients with limited metastatic disease (arm B) who underwent surgery and no surgery. (Adapted from Al-Batran *et al*[25] with permission from the American Medical Association. Citation: Al-Batran SE, Homann N, Pauligk C. Effect of Neoadjuvant Chemotherapy Followed by Surgical Resection on Survival in Patients With Limited Metastatic Gastric or Gastroesophageal Junction Cancer: The AIO-FLOT3 Trial. *JAMA Oncol* 2017; 3: 1237-1244. Copyright © American Medical Association.

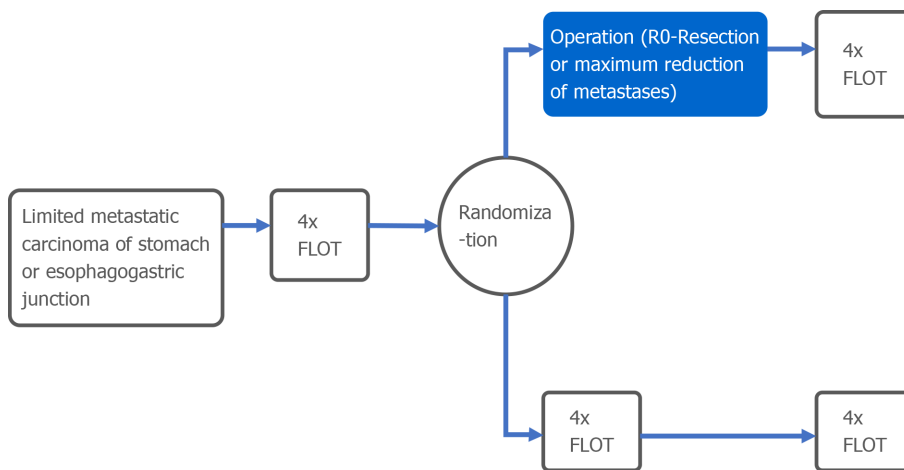


Figure 2 Diagram of the FLOT-5 RENAISSANCE Trial comparing chemotherapy alone vs surgical resection for oligometastatic gastric cancer. FLOT: Fluorouracil, leucovorin, oxaliplatin and docetaxel.

resection. The actual therapeutic options are still insufficient to significantly control both the primary tumor and the distant lesion.

In summary, surgery aims to ensure adequate local clearance, appropriate lymphadenectomy, and uncomplicated anastomosis with low morbidity. An R0 resection, defined by en-bloc resection of the primary tumor without microscopic or macroscopic residual disease for both the primary and metastatic sites, should be the objective of every surgery. Figure 3 summarizes the multidisciplinary management of a patient with metastatic gastric cancer. Because of the current lack of high-grade evidence, radical surgical resection of metastatic gastric cancer cannot be recommended at this time.

CHEMOTHERAPY FOR OLIGOMETASTATIC GASTRIC CANCER

Systemic chemotherapy

Significant advances in the multimodal treatment strategy for gastric cancer have changed the clinical management of the disease over the last 15 years[28]. The first study that revolutionized the oncological treatment of gastric cancer was the Medical Research Council Adjuvant Gastric Infusional Chemotherapy (MAGIC) trial in 2006 [29], followed by the French Action Clinique Coordonnees en Cancerologie Digestive (ACCORD-07) study[30]. These two randomized trials paved the way for the periop-

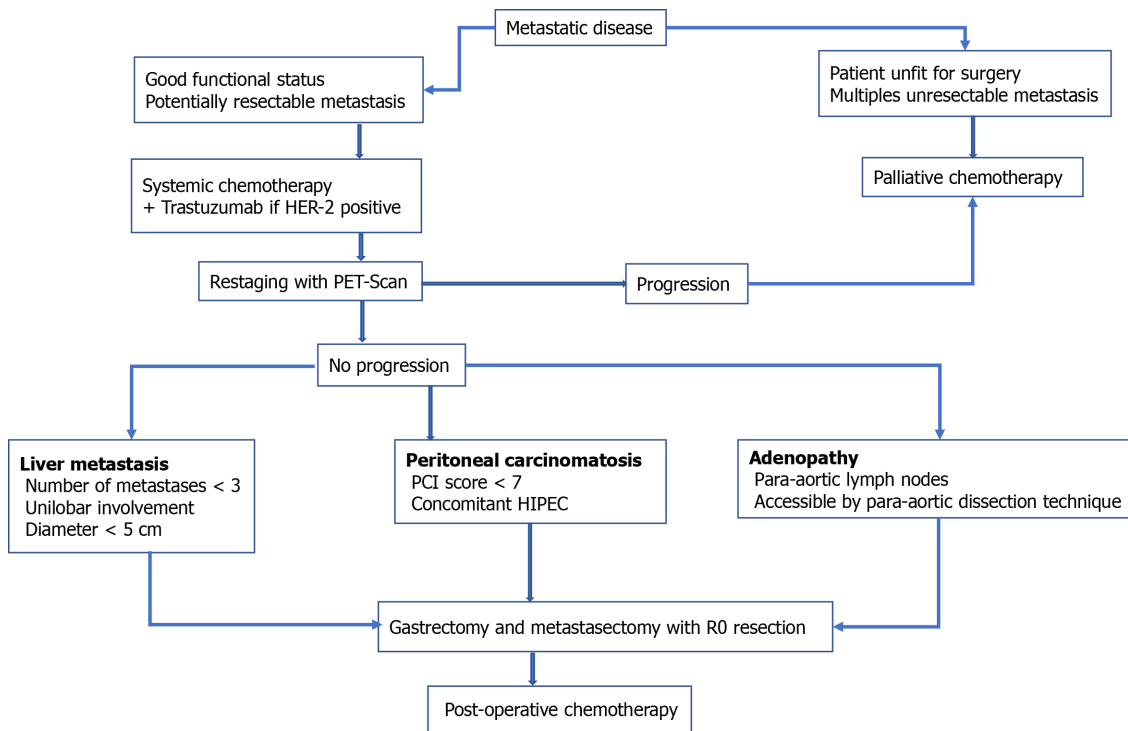


Figure 3 Diagram for the actual therapeutic strategy for patients with oligometastatic gastric cancer. HIPEC: Hyperthermic intraperitoneal chemotherapy.

erative chemotherapy treatment strategy to emerge as the new standard of care. It has been shown to be successful in treating stage IV esophageal, esophagogastric junction (GEJ) and gastric cancer. Chemotherapy regimens are continuously evolving, intending to combine the highest response and lowest possible toxicity rates. The toxicity of the FLOT regimen appears moderate, with good tolerance even in the elderly population[31]. Subsequent studies have shown similar results, with the recent FLOT-4 trial reporting an advantage in survival and the complete pathological response of a docetaxel-based regimen over the established regimens used in the MAGIC trial[32]. Based on this data, the FLOT regimen is the new standard in the perioperative therapy of gastric or esophagogastric adenocarcinomas. In Eastern regions, adjuvant treatment, particularly S-1 (an oral fluoropyrimidine), is the preferred chemotherapy regimen.

These regimens for resectable gastric cancer are well accepted and used.

In contrast, despite the development of newer and more active chemotherapy agents, gastric cancer with metastatic disease remains associated with a poor prognosis, with a 5-year overall survival rate of only 4%[33]. The approach was traditionally palliative chemotherapy with systemic treatment for metastatic disease, including cisplatin and fluorouracil or epirubicin, cisplatin, and fluorouracil regimens.

In a retrospective study, Oyama *et al*[34] examined outcomes of patients with gastric cancer and para-aortic lymph node metastasis. All patients underwent surgical resection, but the systemic regimen was either neoadjuvant or adjuvant. The neoadjuvant treatment was docetaxel, cisplatin, and S-1 for 4 wk, and surgery was performed 2 wk to 4 wk after the last chemotherapy course. The adjuvant treatment was either oral or intravenous 5-FU. Out of a total of 44 patients, 16 underwent surgery after neoadjuvant treatment. The authors reported a low morbidity rate in the neoadjuvant group. Two patients could not finish the neoadjuvant treatment due to toxicity. In the neoadjuvant treatment group, patients had a pathological response ratio of resected specimens of 87.5%. The overall survival ratio was 93.8% 2 years after surgery, and relapse-free survival was 75.0%. The authors showed that preoperative chemotherapy was the only independent prognostic factor in multivariate analysis for overall survival.

Over the last decade, an increasing number of metastatic patients responded to palliative regimens and were able to proceed to surgery with curative intent. This therapeutic concept, conversion therapy, is defined as a patient becoming eligible for curative surgery after systemic chemotherapy while the initial tumor was reported unresectable. From initially unresectable gastric cancer, medical therapy could help

convert patients into curable cancer. The presence of only one site of metastasis is one of the most important prognostic factors.

This “conversion” to curative surgery was first described by Nakajima *et al*[35] in 1997.

With the improvement and development of new therapeutic agents, several conversion therapies have been proposed for stage IV gastric cancer. The most efficient chemotherapeutic regimen to obtain an R0 resection state has been discussed in many trials.

In Japan, the standard treatment for metastatic disease was developed from the SPIRIT trial. According to the Japanese guidelines, S-1 plus cisplatin is the first-line chemotherapy in HER-2 negative patients[36]. For HER-2 positive patients, capecitabine plus cisplatin and trastuzumab are the recommended regimens.

In Europe, one Western series reported favorable results, with 74.2% of patients with unresectable disease converted to surgical management with R0 resection after epirubicin, cisplatin, and 5-FU regimen[37]. Table 1 summarizes the significant studies on conversion therapy.

Another well-studied regimen in the neoadjuvant setting for oligometastatic disease is the FLOT regimen. It has proven its efficacy in the FLOT-3 trial and is currently used in the RENAISSANCE trial. It is recognized as the standard regimen for the neoadjuvant treatment of oligometastatic gastric cancer.

A novel oral cytotoxic chemotherapy, trifluridine/tipiracil, has shown efficacy in patients with chemotherapy refractory advanced gastric cancer. The TAGS study randomized patients with metastatic gastric adenocarcinoma who had received two chemotherapy regimens with disease progression[38]. Patients were randomized to receive a placebo or oral trifluridine/tipiracil. Overall survival improved in the trifluridine/tipiracil group from 3.6 to 5.7 mo (hazard ratio 0.69, $P < 0.001$) with low chemotherapy toxicity. This regimen could be part of the treatment for refractory advanced gastric cancer.

In conclusion, in marginally resectable metastatic tumors, the patient should be treated with neoadjuvant chemotherapy. Restaging with a CT scan or PET scan imaging will assess the response of the tumor and metastases to systemic treatment. This assessment is usually made using the Response Evaluation Criteria in Solid Tumors (RECIST v1.1)[39]. These criteria standardize the measurement of the response to systemic treatment. The pathology can be subsequently classified into complete response, partial response, progressive disease, or stable disease.

If the tumor becomes resectable, surgery should be offered. In patients with tumor progression after neoadjuvant chemotherapy, palliative chemotherapy should be proposed.

INTRAPERITONEAL CHEMOTHERAPY

The peritoneal cavity is a common site for metastasis in advanced gastric cancer and carries the poorest prognosis.

Gastric cancer cells diffuse mainly through lymphatic flow and *via* cell seeding after serosa invasion. About 53%-60% of patients affected by advanced gastric cancer present with peritoneal carcinosis (PC) (stage III-IV), which is more than the 40% of patients with liver metastasis[40].

During intraoperative abdominal examination, peritoneal seeding is found in 10%-20% of patients scheduled for potentially curative resection[41]. In contrast to lymphatic and hematogenous dissemination, the peritoneal spread is a locoregional extension. Preoperative recognition of peritoneal involvement is complex since all imaging techniques have significant limitations because of the low-volume density of peritoneal nodules[42].

Similar to distant metastases, peritoneal carcinomatosis can have different grades of severity. The peritoneal carcinomatosis index (PCI) developed by Sugarbaker helps assess the extent of intraperitoneal disease by observing the implant size and distribution throughout 13 regions with a maximum score of 39[43]. A low PCI score can be parallel to an oligometastatic state. For peritoneal carcinomatosis, intraperitoneal chemotherapy was proposed as an alternative to systemic chemotherapy. It allows for high concentrations of intraperitoneal drugs to act on free tumor cells and peritoneal nodules directly. This direct intraoperative instillation of chemotherapy into the abdominal cavity is heated as hyperthermia extends the locoregional effects with increased penetration into malignant nodules and an increased antimetabolic effect[44].

Table 1 Largest series with conversion therapy for initially unresectable gastric cancer

Study	Period	Total of patient with initial unresectable gastric cancer	Number of conversion to surgery	Number of R0 resection
Nakajima <i>et al</i> [35]	1989-1995	30	19	9 (30%)
Yamaguchi <i>et al</i> [79]	2001-2013	259	84	43 (51%)
Sato <i>et al</i> [80]	2002-2014	100	33	28 (85%)
Fukuchi <i>et al</i> [81]	2003-2013	151	40 (26%)	32 (80%)
Nakamura <i>et al</i> [82]	2005-2014	59	15 (%)	12 (100%)
Morgagni <i>et al</i> [37]	2005-2016	73	22	22 (100%)
Yasufuku <i>et al</i> [83]	2009-2015	39	13	10 (77%)

For patients with gross peritoneal carcinomatosis, the efficacy of hyperthermic intraperitoneal chemotherapy (HIPEC) depends on the possibility of achieving complete cytoreduction, as drug action is limited for residual tumors larger than 2.5 mm[45].

The use of HIPEC in gastric cancer was studied in a retrospective multicentric French study between February 1989 and August 2007. Glehen *et al*[46] evaluated 159 patients who underwent cytoreductive surgery and HIPEC and showed 1-, 3-, and 5-year survival rates of 43%, 18%, and 13%, respectively. These results increased to 61%, 30%, and 23%, respectively, in patients with complete cytoreduction. The authors reported the completeness of cytoreduction as being the principal independent prognostic factor. The study showed that if cytoreductive surgery does not allow enough downstaging, survival rates are low, with a median survival of 6-8 mo.

The completeness of cytoreductive surgery is a critical prognostic factor for survival.

A meta-analysis of 10 studies showed a median survival benefit of 4 mo in favor of cytoreductive surgery plus HIPEC with significant systemic toxicity for patients with peritoneal carcinomatosis treatment. In this category, HIPEC is related to a high risk of developing respiratory failure (RR = 3.67, 95%CI: 2.02-6.67, $P < 0.001$) and renal dysfunction (RR = 4.46, 95%CI: 1.42-13.99, $P = 0.01$). Patient selection plays a crucial role in the potential benefit of HIPEC use. Patients should have an excellent preoperative functional status and no evidence of extraperitoneal metastases.

Patients with signet-ring cell cancer are at higher risk of peritoneal seeding. The currently starting German FLOT9 trial evaluates the place for a prophylactic HIPEC for this aggressive tumor[47]. This multicentric trial includes patients with signet-ring-cell cancer in a curative stage without metastases. Patients receive neoadjuvant FLOT cycles and are subsequently randomized into curative surgery with adjuvant FLOT or curative surgery combined with intraoperative prophylactic HIPEC and adjuvant FLOT. The results of this study will provide evidence of the role of prophylactic intraoperative chemotherapy.

Surgery combined with intraperitoneal chemotherapy could improve survival and reduce recurrences compared with only surgery in selected cases. Intraperitoneal chemotherapy could be proposed for peritoneal carcinomatosis with a peritoneal cancer index (PCI) < 7 [48]. However, safety outcomes should be further evaluated by larger samples, and this specific technique is currently used in the framework of trial protocols exclusively.

The ongoing GASTRIPEC trial should help further define the role of HIPEC[49]. This randomized trial compares sole cytoreductive surgery with cytoreductive surgery plus HIPEC for advanced gastric cancer with peritoneal carcinomatosis.

RADIOTHERAPY

Radiotherapy is commonly used to control the local spread of tumors and has been a significant advancement in the oncological field. Gastric cancer has an aggressive local

spread, and radiotherapy has been employed for its local control. In gastric cancer, the history of radiotherapy began with the comparison of adjuvant chemotherapy *vs* radiotherapy following surgical resection. The results of the British Stomach Cancer Group failed to demonstrate an overall survival benefit[50]. Outcomes were generally disappointing with a 5-year overall survival of 17% in any treatment group. This preliminary study opposed adjuvant chemotherapy and radiotherapy. The conclusion was that surgery remains the standard treatment for this condition, and the role of adjuvant treatment was minimal. Four years later, a study from China compared 370 patients who underwent surgery only or received preoperative radiotherapy to the gastric cardia region, gastroesophageal junction, and limited regional lymph nodes [51]. A significant overall survival advantage (absolute risk reduction of approximately 10% at 5 years) was noted in the group receiving neoadjuvant radiotherapy. This survival benefit set the basis for the potential benefit of radiotherapy in gastric cancer. Adjuvant chemoradiotherapy is the standard care in the United States, according to the Intergroup 0116 trial despite methodological flaws. In other countries, the adjunction of radiotherapy to chemotherapy can be considered in patients with positive margins or gross residual disease[52].

In contrast to data for patients with resectable gastric cancer, evidence for patients with unresectable gastric cancers is scarce. Nonetheless, chemoradiotherapy may have a role in achieving durable palliation and conversion to resectable disease. A Japanese study that employed chemoradiotherapy for patients with unresectable locally advanced gastric cancer found a resection rate of 33.3% and an overall pathological complete response rate of 13.3% [53]. In this study, 40 Gray were delivered to the primary tumor and regional lymph nodes with concurrent S-1 and cisplatin. The conclusion was that radiotherapy could prevent the local spread of the tumor and lead to resectability. Randomized studies on the use of preoperative radiotherapy are generally of poor quality with limited information on the quality of the surgery, adequacy of nodal dissection, and extent of tumor involvement. A meta-analysis of these studies from Pang *et al*[54] did not show a survival benefit of preoperative radiotherapy on 5-year overall survival (hazard ratio, 0.68; 95% CI: 0.45-1.01).

For metastatic gastric cancer, radiotherapy plays a limited role. The adjunction of radiotherapy to chemotherapy in metastatic gastric cancer does not seem to improve overall or disease-free survival[55]. The benefit of radiotherapy in the management of oligometastatic gastric cancer is more focused on palliative treatment for the symptoms caused by the primary lesion with reduced pain and bleeding[56]. An ongoing U.S. randomized trial addresses the matters of adding radiotherapy to the usual chemotherapy in oligometastatic esophageal and gastric cancer (*ClinicalTrials.gov* identifier: NCT04248452)[57].

TARGETED THERAPY

The poor results of conventional treatment in advanced gastric cancer stimulated research teams to explore alternative solutions. Targeted therapy is an oncological treatment that targets specific genes and proteins involved in tumor expansion. The erythroblastic leukemia viral oncogene homolog 2 (ErbB2, also known as HER2) belongs to the epidermal growth factor (EGF) receptor tyrosine kinases. This receptor is overexpressed in 10%-20% of gastric cancer[58,59]. It is an adverse prognostic factor in breast cancer, showing more aggressive biological behavior and higher recurrence rate. In gastric cancer, HER2 is only a predictive marker. Molecular targeted therapy against HER2 was developed to improve the prognosis of this tumor subtype. The mechanism is to administrate antibodies against HER2 or one of its ligands to force its internalization and antagonize its recycling.

Trastuzumab was the first treatment developed for HER2-positive carcinomas. Its efficacy was first described in patients with breast cancer and demonstrated responses both as a single agent or in combination with chemotherapy regimens[60,61]. Given the success in metastatic and adjuvant settings for breast cancer, evaluation of trastuzumab in gastric and esophageal cancers was necessary.

The randomized international Trastuzumab for Gastric Cancer ToGA trial evaluated trastuzumab combined with standard platinum/fluoropyrimidine combination *vs* platinum/fluoropyrimidine chemotherapy only in inoperable locally advanced, recurrent, or metastatic HER2-positive GEJ or gastric adenocarcinoma[6]. The addition of trastuzumab to chemotherapy improved median overall survival (13.8 mo with the combination *vs* 11.1 mo for chemotherapy only, hazard ratio [HR]: 0.74; *P* = 0.0046). Patients with higher HER2 expression seem to obtain an even greater survival

advantage (16.0 *vs* 11.8 mo; HR: 0.65). Notably, patients on the trastuzumab treatment arm received more chemotherapy, with a median of six cycles. The complete response rate was 5% in the trastuzumab group *vs* chemotherapy alone, almost reaching statistical significance ($P = 0.059$). Based on these results, the adjunction of molecular targeted therapy seems to improve systemic control. Kurokawa *et al*[62] also showed promising efficacy and safety combined with S-1 and cisplatin in combination for patients with HER2-positive unresectable gastric cancer. They recruited 56 patients and found a response rate of 68% (95%CI: 54%-80%), with a disease control rate of 94% (95%CI: 84%-99%). The median overall survival was 16 mo. Since the publication of these trials, the use of trastuzumab has become a standard option for patients with inoperable HER2-positive gastric cancer.

The clinical utility of continuing Trastuzumab beyond progression is still a research question that deserves further study. A study conducted in China in patients with advanced HER2-positive gastric cancer showed slightly better survival with trastuzumab beyond progression (3 mo *vs* 2 mo without trastuzumab)[63]. This low advantage of second-line therapy can be partly due to the heterogeneity of gastroesophageal cancers, which have a less uniform expression of HER2 than breast cancer cells. Discordance in HER2 status between primary tumors and metastatic lesions may also bias the efficacy of HER2-directed agents[64]. HER2 expression can change at the time of disease progression, and cancerous cells can lose HER2 expression, becoming resistant to monoclonal antibodies. Retesting of HER2 expression is justified if trastuzumab is to be considered after progression despite first-line chemotherapy.

Despite HER2 copy number and high expression predicting the benefit of trastuzumab in clinical trials in breast and esophagogastric cancers, only a minority of tumors respond to HER2 blockade with trastuzumab monotherapy. Other monoclonal antibodies have been studied, such as pertuzumab, which recognizes a different epitope of HER2 than trastuzumab. The early clinical testing of pertuzumab showed minimal activity as a single agent, but its combination with trastuzumab showed promising results[65]. For metastatic disease, the JACOB trial recruited patients with HER2-positive metastatic GEJ or gastric cancer and randomized them to pertuzumab in combination with trastuzumab, fluoropyrimidine, and cisplatin *vs* placebo, trastuzumab, and fluoropyrimidine[66]. The overall results from JACOB were negative. Despite a 3.3 mo absolute benefit in overall survival, the addition of pertuzumab did not show any statistically significant benefit.

The addition of targeted therapy to traditional chemotherapy can improve the systemic control of oligometastatic gastric cancer. If the tumor displays a positive HER-2 status, this treatment should be part of a first-line therapy.

However, if the patient has already received trastuzumab, continuing it during second-line therapy does not improve response or survival[67]. A novel HER2-targeted agent, trastuzumab deruxtecan, achieved significant response and survival benefit in patients previously treated with trastuzumab in HER-2 positive breast cancer patients[68]. Trastuzumab deruxtecan is an antibody-drug conjugate composed of an anti-HER2 antibody, a cleavable tetrapeptide-based linker, and a cytotoxic topoisomerase I inhibitor. This molecule enables the delivery of chemotherapy directly to the cancerous cell *via* binding to the HER2 receptor.

In a phase II trial, investigators reported the results of a randomized trial comparing trastuzumab deruxtecan *vs* chemotherapy in patients with HER2-positive gastric cancer previously treated with chemotherapy, including trastuzumab[69]. The group which received trastuzumab deruxtecan showed better overall survival (12.5 *vs* 8.4 mo, $P = 0.01$) and progression-free survival (5.6 *vs* 3.5 mo, $P = 0.03$).

The most common adverse events with trastuzumab deruxtecan were neutropenia (51%), followed by anemia (38%) and anorexia (17%). Trastuzumab deruxtecan could be an option with efficacy in previously treated gastric and EGJ metastatic cancer.

Vascular endothelial growth factor receptor (VEGFR) is another target for specific therapy. This pathway promotes angiogenesis and can contribute to the progression of gastric cancer. An anti-VEGFR-2-directed antibody, ramucirumab, antagonizes the VEGFR pathway. A phase III study (REGARD) showed an improvement of overall survival (5.2 mo *vs* 3.8 mo) in the ramucirumab group compared to the placebo group in patients with disease progression after first-line chemotherapy[70]. The survival improvement was confirmed in the RAINBOW study[71]. This randomized trial compared ramucirumab plus paclitaxel *vs* paclitaxel plus placebo for second-line therapy in advanced gastric cancer. The combination of ramucirumab with paclitaxel significantly increases overall survival compared with placebo plus paclitaxel. There was also a significantly greater proportion of patients with an objective pathological response in the ramucirumab-plus-paclitaxel group than in the placebo-plus-paclitaxel group (28% *vs* 16%, respectively, $P = 0.0001$).

The RAMSES FLOT-7 was a randomized multicentric German and Italian trial[72]. Patients with resectable gastric or GEJ adenocarcinoma were randomized to FLOT plus ramucirumab (a VEGF-R2 inhibitor) or FLOT only in the perioperative period. A higher R0-resection was achieved in the FLOT-RAM group (97% *vs* 83% in the FLOT alone, $P = 0.0049$). However, the mortality was higher in the FLOT-RAM group (5.9%) than in the FLOT-only group (2.5%). The addition of immunotherapy to resectable tumors seems to improve R0 resection rates but with a higher mortality rate.

IMMUNOTHERAPY

Immunotherapy was initially developed as a third-line treatment option. The disappointing results after several regimens of chemotherapy prompted the development of additional treatment. The first target for the immunotherapy was the programmed cell death 1 protein (PD-1) and its ligand. This surface protein is expressed by tumor cells. The binding of this protein by monoclonal antibodies allows the immune system to recognize tumor cells and respond against them.

Two trials studied the role of immunotherapy as a third-line treatment for inoperable gastric cancer. The Asian ATTRACTION-2 study included patients with advanced gastric or GEJ cancer who received two or more chemotherapy regimens [73]. They randomized patients into nivolumab (immunotherapy targeting PD-1) or placebo groups. The median overall survival was significantly increased in the nivolumab compared to the placebo group (5.3 mo *vs* 4.1 mo, respectively; HR 0.63, $P < 0.001$). These results were confirmed in a population that also included non-Asian patients in the KEYNOTE-059 study[74]. This single-arm multicohort study included 259 patients from 16 countries with metastatic gastric cancer who received pembrolizumab, another monoclonal antibody against PD-1. The objective response rate was observed at 11.6%. In tumors with PD-L1 (programmed cell death ligand 1) expression, the response duration was longer (16.3 mo *vs* 7 mo in negative PD-L1 tumor).

Another study about the immunotherapy molecule pembrolizumab is KEYNOTE 062[75]. This study compared three groups of patients with metastatic GEJ or gastric cancer. Patients were randomized into three groups: chemotherapy only, chemotherapy plus pembrolizumab, or pembrolizumab only. The study included 763 patients. There were no overall survival differences between chemotherapy only and pembrolizumab plus chemotherapy. However, in the pembrolizumab-only group, response rates were inferior (14.8%) than in the chemotherapy-only group (37.2%). Combining pembrolizumab with chemotherapy failed to improve outcomes over chemotherapy only and should be reserved for treating chemotherapy refractory advanced gastric cancer.

The adjunction of PD-1 antibody combined with a modified FLOT regimen is the subject of an ongoing randomized trial (ClinicalTrials.gov Identifier: NCT04510064) [76].

This Chinese study evaluates the efficacy and safety of camrelizumab for injection, combined with fluorouracil plus leucovorin, oxaliplatin, and albumin-bound paclitaxel (modified FLOT, mFLOT) regimen in the treatment of patients with unresectable locally advanced or limited metastatic gastric cancer. The primary efficacy endpoint is R0 resection rate. After six cycles, surgical experts evaluated the resectability of the tumor, and the patients who were confirmed to be resectable received surgery within 3 wk to 6 wk. The patients with good postoperative recovery continued to receive the same immunochemotherapy at most 12 cycles.

The DANTE FLOT-8 is an ongoing randomized trial studying the effect of atezolizumab, a PD-L1 inhibitor, in patients with advanced gastric and GEJ cancer[77]. Patients are separated into two groups: FLOT plus atezolizumab or FLOT only in perioperative treatment. The results of this study will identify the role of PD-L1 inhibitors in addition to chemotherapy in the perioperative period.

The randomized, multicentric MOONLIGHT trial is currently recruiting patients to evaluate the role of immunotherapy in metastatic disease specifically[78]. Patients must have an HER-2 negative, inoperable, or metastatic gastric or GEJ cancer to be eligible, and they are subsequently randomized to receive either FOLFOX only or FOLFOX plus nivolumab and ipilimumab. The progression-free survival is the primary endpoint, and completion of the study is expected for 2022.

Immunotherapy seems to prolong survival in third-line therapy and improve pathological response in patients with resectable disease. Further studies are needed to define its role as a downstaging modality with the potential to increase surgical

resection rates in metastatic disease.

CONCLUSION

Gastric cancer is an aggressive tumor often discovered at an advanced stage. Its management by one unique specialist is impossible, and the expertise of different specialists is mandatory for the patient. Every case must be evaluated by a multidisciplinary team including at least surgeons, oncologists, and radiotherapists. The challenge of metastatic disease management is to offer the appropriate treatment without futility. Surgery in an aggressive tumor will accelerate propagation by delaying systemic treatment. However, if surgery can control all metastatic foci with low morbidity and allow the systemic treatment to be started quickly, it could offer a survival advantage. A better understanding of gastric cancer biology has permitted the addition of antibodies that target a specific oncological pathway to the gastric cancer therapeutic arsenal. Immunotherapy is another promising field, with several new molecules being currently evaluated in randomized trials to assess their impact and indications in patients with advanced gastric cancer. The increased efficiency and better tolerance of chemotherapy allow some patients who were initially ineligible for surgery to benefit from surgical resection in second intention. The results of the RENAISSANCE trial comparing chemotherapy only *vs* chemotherapy and surgery for oligometastatic disease will probably change the management of advanced gastric cancer.

REFERENCES

- 1 **Stiekema J**, Cats A, Kuijpers A, van Coevorden F, Boot H, Jansen EP, Verheij M, Balague Ponz O, Hauptmann M, van Sandick JW. Surgical treatment results of intestinal and diffuse type gastric cancer. Implications for a differentiated therapeutic approach? *Eur J Surg Oncol* 2013; **39**: 686-693 [PMID: 23498364 DOI: 10.1016/j.ejso.2013.02.026]
- 2 **Bernards N**, Creemers GJ, Nieuwenhuijzen GA, Bosscha K, Pruijt JF, Lemmens VE. No improvement in median survival for patients with metastatic gastric cancer despite increased use of chemotherapy. *Ann Oncol* 2013; **24**: 3056-3060 [PMID: 24121120 DOI: 10.1093/annonc/mdt401]
- 3 **Riihimäki M**, Hemminki A, Sundquist K, Sundquist J, Hemminki K. Metastatic spread in patients with gastric cancer. *Oncotarget* 2016; **7**: 52307-52316 [PMID: 27447571 DOI: 10.18632/oncotarget.10740]
- 4 **SEER Cancer Stat Facts: Stomach Cancer**. National Cancer Institute. In: Bethesda editor
- 5 **Wagner AD**, Syn NL, Moehler M, Grothe W, Yong WP, Tai BC, Ho J, Unverzagt S. Chemotherapy for advanced gastric cancer. *Cochrane Database Syst Rev* 2017; **8**: CD004064 [PMID: 28850174 DOI: 10.1002/14651858.CD004064.pub4]
- 6 **Bang YJ**, Van Cutsem E, Feyereislova A, Chung HC, Shen L, Sawaki A, Lordick F, Ohtsu A, Omuro Y, Satoh T, Aprile G, Kulikov E, Hill J, Lehle M, Rüschoff J, Kang YK; ToGA Trial Investigators. Trastuzumab in combination with chemotherapy *vs* chemotherapy alone for treatment of HER2-positive advanced gastric or gastro-oesophageal junction cancer (ToGA): a phase 3, open-label, randomised controlled trial. *Lancet* 2010; **376**: 687-697 [PMID: 20728210 DOI: 10.1016/S0140-6736(10)61121-X]
- 7 **Gupta S**, Li D, El Serag HB, Davitkov P, Altayar O, Sultan S, Falck-Ytter Y, Mustafa RA. AGA Clinical Practice Guidelines on Management of Gastric Intestinal Metaplasia. *Gastroenterology* 2020; **158**: 693-702 [PMID: 31816298 DOI: 10.1053/j.gastro.2019.12.003]
- 8 **Smyth EC**, Verheij M, Allum W, Cunningham D, Cervantes A, Arnold D; ESMO Guidelines Committee. Gastric cancer: ESMO Clinical Practice Guidelines for diagnosis, treatment and follow-up. *Ann Oncol* 2016; **27**: v38-v49 [PMID: 27664260 DOI: 10.1093/annonc/mdw350]
- 9 **Broomfield JA**, Greenspoon JN, Swaminath A. Utilization of stereotactic ablative radiotherapy in the management of oligometastatic disease. *Curr Oncol* 2014; **21**: 115-117 [PMID: 24940091 DOI: 10.3747/co.21.1988]
- 10 **Hellman S**, Weichselbaum RR. Oligometastases. *J Clin Oncol* 1995; **13**: 8-10 [PMID: 7799047 DOI: 10.1200/JCO.1995.13.1.8]
- 11 **Carmona-Bayonas A**, Jiménez-Fonseca P, Echavarría I, Sánchez Cánovas M, Aguado G, Gallego J, Custodio A, Hernández R, Viudez A, Cano JM, Martínez de Castro E, Macías I, Martín Carnicero A, Garrido M, Mangas M, Álvarez Manceñido F, Visa L, Azkarate A, Ramchandani A, Fernández Montes A, Longo F, Sánchez A, Pimentel P, Limón ML, Arias D, Cacho Lavin D, Sánchez Bayona R, Cerdá P, García Alfonso P; AGAMENON Study Group. Surgery for metastases for esophageal-gastric cancer in the real world: Data from the AGAMENON national registry. *Eur J Surg Oncol* 2018; **44**: 1191-1198 [PMID: 29685755 DOI: 10.1016/j.ejso.2018.03.019]
- 12 **Procopio F**, Marano S, Gentile D, Da Roit A, Basato S, Riva P, De Vita F, Torzilli G, Castoro C. Management of Liver Oligometastatic Esophageal Cancer: Overview and Critical Analysis of the

- Different Loco-Regional Treatments. *Cancers (Basel)* 2019; **12** [PMID: 31861604 DOI: 10.3390/cancers12010020]
- 13 **Mönig S**, Ott K, Gockel I, Lorenz D, Ludwig K, Messmann H, Moehler M, Piso P, Weimann A, Meyer HJ. [S3 guidelines on gastric cancer-diagnosis and treatment of adenocarcinoma of the stomach and esophagogastric junction : Version 2.0-August 2019. AWMF register number: 032/009OL]. *Chirurg* 2020; **91**: 37-40 [PMID: 31950198 DOI: 10.1007/s00104-020-01112-y]
 - 14 **Moehler M**, Baltin CT, Ebert M, Fischbach W, Gockel I, Grenacher L, Hölscher AH, Lordick F, Malfertheiner P, Messmann H, Meyer HJ, Palmqvist A, Röcken C, Schuhmacher C, Stahl M, Stuschke M, Vieth M, Wittekind C, Wagner D, Mönig SP. International comparison of the German evidence-based S3-guidelines on the diagnosis and multimodal treatment of early and locally advanced gastric cancer, including adenocarcinoma of the lower esophagus. *Gastric Cancer* 2015; **18**: 550-563 [PMID: 25192931 DOI: 10.1007/s10120-014-0403-x]
 - 15 **Schmidt T**, Mönig SP. [Therapeutic approach in oligometastatic gastric and esophageal cancer]. *Chirurg* 2017; **88**: 1024-1032 [PMID: 29098307 DOI: 10.1007/s00104-017-0548-3]
 - 16 **Li Z**, Fan B, Shan F, Tang L, Bu Z, Wu A, Zhang L, Wu X, Zong X, Li S, Ren H, Ji J. Gastrectomy in comprehensive treatment of advanced gastric cancer with synchronous liver metastasis: a prospectively comparative study. *World J Surg Oncol* 2015; **13**: 212 [PMID: 26126412 DOI: 10.1186/s12957-015-0627-1]
 - 17 **Thelen A**, Jonas S, Benckert C, Lopez-Hänninen E, Neumann U, Rudolph B, Schumacher G, Neuhaus P. Liver resection for metastatic gastric cancer. *Eur J Surg Oncol* 2008; **34**: 1328-1334 [PMID: 18329229 DOI: 10.1016/j.ejso.2008.01.022]
 - 18 **Nishi M**, Shimada M, Yoshikawa K, Higashijima J, Tokunaga T, Kashiara H, Takasu C, Ishikawa D, Wada Y, Eto S. Results of Hepatic Resection for Liver Metastasis of Gastric Cancer. *J Med Invest* 2018; **65**: 27-31 [PMID: 29593189 DOI: 10.2152/jmi.65.27]
 - 19 **Ryu T**, Takami Y, Wada Y, Tateishi M, Matsushima H, Yoshitomi M, Saitsu H. Oncological outcomes after hepatic resection and/or surgical microwave ablation for liver metastasis from gastric cancer. *Asian J Surg* 2019; **42**: 100-105 [PMID: 29254868 DOI: 10.1016/j.asjsur.2017.09.005]
 - 20 **Markar SR**, Mackenzie H, Mikhail S, Mughal M, Preston SR, Maynard ND, Faiz O, Hanna GB. Surgical resection of hepatic metastases from gastric cancer: outcomes from national series in England. *Gastric Cancer* 2017; **20**: 379-386 [PMID: 26939792 DOI: 10.1007/s10120-016-0604-6]
 - 21 **Takemura N**, Saiura A, Koga R, Arita J, Yoshioka R, Ono Y, Hiki N, Sano T, Yamamoto J, Kokudo N, Yamaguchi T. Long-term outcomes after surgical resection for gastric cancer liver metastasis: an analysis of 64 macroscopically complete resections. *Langenbecks Arch Surg* 2012; **397**: 951-957 [PMID: 22615045 DOI: 10.1007/s00423-012-0959-z]
 - 22 **Montagnani F**, Crivelli F, Aprile G, Vivaldi C, Pecora I, De Vivo R, Clerico MA, Fornaro L. Long-term survival after liver metastasectomy in gastric cancer: Systematic review and meta-analysis of prognostic factors. *Cancer Treat Rev* 2018; **69**: 11-20 [PMID: 29860024 DOI: 10.1016/j.ctrv.2018.05.010]
 - 23 **Fujitani K**, Yang HK, Mizusawa J, Kim YW, Terashima M, Han SU, Iwasaki Y, Hyung WJ, Takagane A, Park DJ, Yoshikawa T, Hahn S, Nakamura K, Park CH, Kurokawa Y, Bang YJ, Park BJ, Sasako M, Tsujinaka T; REGATTA study investigators. Gastrectomy plus chemotherapy vs chemotherapy alone for advanced gastric cancer with a single non-curable factor (REGATTA): a phase 3, randomised controlled trial. *Lancet Oncol* 2016; **17**: 309-318 [PMID: 26822397 DOI: 10.1016/S1470-2045(15)00553-7]
 - 24 **Chen J**, Kong Y, Weng S, Dong C, Zhu L, Yang Z, Zhong J, Yuan Y. Outcomes of surgery for gastric cancer with distant metastases: a retrospective study from the SEER database. *Oncotarget* 2017; **8**: 4342-4351 [PMID: 28008147 DOI: 10.18632/oncotarget.14027]
 - 25 **Al-Batran SE**, Homann N, Pauligk C, Illerhaus G, Martens UM, Stoehlmacher J, Schmalenberg H, Luley KB, Prasnikaer N, Egger M, Probst S, Messmann H, Moehler M, Fischbach W, Hartmann JT, Mayer F, Höffkes HG, Koenigsmann M, Arnold D, Kraus TW, Grimm K, Berkhoff S, Post S, Jäger E, Bechstein W, Ronellenfitch U, Mönig S, Hofheinz RD. Effect of Neoadjuvant Chemotherapy Followed by Surgical Resection on Survival in Patients With Limited Metastatic Gastric or Gastroesophageal Junction Cancer: The AIO-FLOT3 Trial. *JAMA Oncol* 2017; **3**: 1237-1244 [PMID: 28448662 DOI: 10.1001/jamaoncol.2017.0515]
 - 26 **Al-Batran SE**, Goetze TO, Mueller DW, Vogel A, Winkler M, Lorenzen S, Novotny A, Pauligk C, Homann N, Jungbluth T, Reissfelder C, Caca K, Retter S, Horndasch E, Gump J, Bolling C, Fuchs KH, Blau W, Padberg W, Pohl M, Wunsch A, Michl P, Mannes F, Schwarzbach M, Schmalenberg H, Hohaus M, Scholz C, Benckert C, Knorrenschild JR, Kanngießner V, Zander T, Alakus H, Hofheinz RD, Roedel C, Shah MA, Sasako M, Lorenz D, Izbicki J, Bechstein WO, Lang H, Moenig SP. The RENAISSANCE (AIO-FLOT5) trial: effect of chemotherapy alone vs. chemotherapy followed by surgical resection on survival and quality of life in patients with limited-metastatic adenocarcinoma of the stomach or esophagogastric junction - a phase III trial of the German AIO/CAO-V/CAOGI. *BMC Cancer* 2017; **17**: 893 [PMID: 29282088 DOI: 10.1186/s12885-017-3918-9]
 - 27 **Piessen G**. Identifier: NCT03042169, Surgical Resection Plus Chemotherapy Versus Chemotherapy Alone in Oligometastatic Stage IV Gastric Cancer (SURGIGAST). ClinicalTrialsgov [Internet] Bethesda (MD): National Library of Medicine (US)
 - 28 **Goetze OT**, Al-Batran SE, Chevallay M, Mönig SP. Multimodal treatment in locally advanced gastric cancer. *Updates Surg* 2018; **70**: 173-179 [PMID: 29946806 DOI: 10.1007/s13304-018-0539-z]
 - 29 **Cunningham D**, Allum WH, Stenning SP, Thompson JN, Van de Velde CJ, Nicolson M, Scarffe JH,

- Lofts FJ, Falk SJ, Iveson TJ, Smith DB, Langley RE, Verma M, Weeden S, Chua YJ, MAGIC Trial Participants. Perioperative chemotherapy vs surgery alone for resectable gastroesophageal cancer. *N Engl J Med* 2006; **355**: 11-20 [PMID: 16822992 DOI: 10.1056/NEJMoa055531]
- 30 **Ychou M**, Boige V, Pignon JP, Conroy T, Bouché O, Lebreton G, Ducourtieux M, Bedenne L, Fabre JM, Saint-Aubert B, Genève J, Lasser P, Rougier P. Perioperative chemotherapy compared with surgery alone for resectable gastroesophageal adenocarcinoma: an FNCLCC and FFCD multicenter phase III trial. *J Clin Oncol* 2011; **29**: 1715-1721 [PMID: 21444866 DOI: 10.1200/JCO.2010.33.0597]
- 31 **Al-Batran SE**, Hartmann JT, Hofheinz R, Homann N, Rethwisch V, Probst S, Stoehlmacher J, Clemens MR, Mahlberg R, Fritz M, Seipelt G, Sievert M, Pauligk C, Atmaca A, Jäger E. Biweekly fluorouracil, leucovorin, oxaliplatin, and docetaxel (FLOT) for patients with metastatic adenocarcinoma of the stomach or esophagogastric junction: a phase II trial of the Arbeitsgemeinschaft Internistische Onkologie. *Ann Oncol* 2008; **19**: 1882-1887 [PMID: 18669868 DOI: 10.1093/annonc/mdn403]
- 32 **Al-Batran SE**, Homann N, Pauligk C, Goetze TO, Meiler J, Kasper S, Kopp HG, Mayer F, Haag GM, Luley K, Lindig U, Schmiegel W, Pohl M, Stoehlmacher J, Folprecht G, Probst S, Prasnikař N, Fischbach W, Mahlberg R, Trojan J, Koenigsmann M, Martens UM, Thuss-Patience P, Egger M, Block A, Heinemann V, Illerhaus G, Moehler M, Schenk M, Kullmann F, Behringer DM, Heike M, Pink D, Teschendorf C, Löhr C, Bernhard H, Schuch G, Rethwisch V, von Weikersthal LF, Hartmann JT, Kneba M, Daum S, Schulmann K, Weniger J, Belle S, Gaiser T, Oduncu FS, Güntner M, Hozaeel W, Reichart A, Jäger E, Kraus T, Mönig S, Bechstein WO, Schuler M, Schmalenberg H, Hofheinz RD; FLOT4-AIO Investigators. Perioperative chemotherapy with fluorouracil plus leucovorin, oxaliplatin, and docetaxel vs fluorouracil or capecitabine plus cisplatin and epirubicin for locally advanced, resectable gastric or gastro-oesophageal junction adenocarcinoma (FLOT4): a randomised, phase 2/3 trial. *Lancet* 2019; **393**: 1948-1957 [PMID: 30982686 DOI: 10.1016/S0140-6736(18)32557-1]
- 33 **Stomach Cot.** Cancer Stat Facts, 2020
- 34 **Oyama K**, Fushida S, Kinoshita J, Makino I, Nakamura K, Hayashi H, Nakagawara H, Tajima H, Fujita H, Takamura H, Ninomiya I, Kitagawa H, Tani T, Fujimura T, Ohta T. Efficacy of pre-operative chemotherapy with docetaxel, cisplatin, and S-1 (DCS therapy) and curative resection for gastric cancer with pathologically positive para-aortic lymph nodes. *J Surg Oncol* 2012; **105**: 535-541 [PMID: 22006649 DOI: 10.1002/jso.22125]
- 35 **Nakajima T**, Ota K, Ishihara S, Oyama S, Nishi M, Ohashi Y, Yanagisawa A. Combined intensive chemotherapy and radical surgery for incurable gastric cancer. *Ann Surg Oncol* 1997; **4**: 203-208 [PMID: 9142380 DOI: 10.1007/BF02306611]
- 36 **Japanese Gastric Cancer Association.** Japanese gastric cancer treatment guidelines 2018 (5th edition). *Gastric Cancer* 2021; **24**: 1-21 [PMID: 32060757 DOI: 10.1007/s10120-020-01042-y]
- 37 **Morgagni P**, Solaini L, Framarini M, Vittimberga G, Gardini A, Tringali D, Valgiusti M, Monti M, Ercolani G. Conversion surgery for gastric cancer: A cohort study from a western center. *Int J Surg* 2018; **53**: 360-365 [PMID: 29654967 DOI: 10.1016/j.ijssu.2018.04.016]
- 38 **Shitara K**, Doi T, Dvorkin M, Mansoor W, Arkenau HT, Prokharau A, Alsina M, Ghidini M, Faustino C, Gorbunova V, Zhavrid E, Nishikawa K, Hosokawa A, Yalçın Ş, Fujitani K, Beretta GD, Cutsem EV, Winkler RE, Makris L, Ilson DH, Tabernero J. Trifluridine/tipiracil vs placebo in patients with heavily pretreated metastatic gastric cancer (TAGS): a randomised, double-blind, placebo-controlled, phase 3 trial. *Lancet Oncol* 2018; **19**: 1437-1448 [PMID: 30355453 DOI: 10.1016/S1470-2045(18)30739-3]
- 39 **Eisenhauer EA**, Therasse P, Bogaerts J, Schwartz LH, Sargent D, Ford R, Dancy J, Arbuck S, Gwyther S, Mooney M, Rubinstein L, Shankar L, Dodd L, Kaplan R, Lacombe D, Verweij J. New response evaluation criteria in solid tumours: revised RECIST guideline (version 1.1). *Eur J Cancer* 2009; **45**: 228-247 [PMID: 19097774 DOI: 10.1016/j.ejca.2008.10.026]
- 40 **Roviello F**, Caruso S, Marrelli D, Pedrazzani C, Neri A, De Stefano A, Pinto E. Treatment of peritoneal carcinomatosis with cytoreductive surgery and hyperthermic intraperitoneal chemotherapy: state of the art and future developments. *Surg Oncol* 2011; **20**: e38-e54 [PMID: 20888755 DOI: 10.1016/j.suronc.2010.09.002]
- 41 **Hioki M**, Gotohda N, Konishi M, Nakagohri T, Takahashi S, Kinoshita T. Predictive factors improving survival after gastrectomy in gastric cancer patients with peritoneal carcinomatosis. *World J Surg* 2010; **34**: 555-562 [PMID: 20082194 DOI: 10.1007/s00268-010-0396-5]
- 42 **McMullen JRW**, Selleck M, Wall NR, Senthil M. Peritoneal carcinomatosis: limits of diagnosis and the case for liquid biopsy. *Oncotarget* 2017; **8**: 43481-43490 [PMID: 28415645 DOI: 10.18632/oncotarget.16480]
- 43 **Sugarbaker P.** Peritoneal carcinomatosis: principles of management. Boston, MA: Kluwer Academic Publishers, 1996
- 44 **Feingold PL**, Kwong ML, Sabesan A, Sorber R, Rudloff U. Cytoreductive surgery and hyperthermic intraperitoneal chemotherapy for gastric cancer and other less common disease histologies: is it time? *J Gastrointest Oncol* 2016; **7**: 87-98 [PMID: 26941987 DOI: 10.3978/j.issn.2078-6891.2015.098]
- 45 **Sugarbaker PH**, Landy D, Jaffe G, Pascal R. Histologic changes induced by intraperitoneal chemotherapy with 5-fluorouracil and mitomycin C in patients with peritoneal carcinomatosis from cystadenocarcinoma of the colon or appendix. *Cancer* 1990; **65**: 1495-1501 [PMID: 2107021 DOI: 10.1002/1097-0142(19900401)65:7<1495:aid-cnrcr2820650708>3.0.co;2-1]

- 46 **Glehen O**, Gilly FN, Arvieux C, Cotte E, Boutitie F, Mansvelt B, Bereder JM, Lorimier G, Quenet F, Elias D; Association Française de Chirurgie. Peritoneal carcinomatosis from gastric cancer: a multi-institutional study of 159 patients treated by cytoreductive surgery combined with perioperative intraperitoneal chemotherapy. *Ann Surg Oncol* 2010; **17**: 2370-2377 [PMID: [20336386](#) DOI: [10.1245/s10434-010-1039-7](#)]
- 47 **TG**. HIPEC + FLOT vs FLOT Alone in Patients With Gastric Cancer and GEJ (PREVENT), 2020
- 48 **Seshadri RA**, Glehen O. Cytoreductive surgery and hyperthermic intraperitoneal chemotherapy in gastric cancer. *World J Gastroenterol* 2016; **22**: 1114-1130 [PMID: [26811651](#) DOI: [10.3748/wjg.v22.i3.1114](#)]
- 49 **Rau B**, M Loeffler, H Rau. Perioperative chemotherapy and cytoreductive surgery with vs without HIPEC in gastric cancer with limited peritoneal metastases: a randomised phase III study (GASTRIPEC). *J Clin Oncol* 2015; **33**: TPS4132
- 50 **Hallsley MT**, Dunn JA, Ward LC, Allum WH. The second British Stomach Cancer Group trial of adjuvant radiotherapy or chemotherapy in resectable gastric cancer: five-year follow-up. *Lancet* 1994; **343**: 1309-1312 [PMID: [7910321](#) DOI: [10.1016/s0140-6736\(94\)92464-3](#)]
- 51 **Zhang ZX GX**, Yin WB. Randomised clinical trial on the combination of preoperative irradiation and surgery in the treatment of adenocarcinoma of gastric cardia (AGC)--report on 370 patients. *Int J Radiat Oncol Biol Phys* 1998; **42**: 929-934
- 52 **Macdonald JS**, Smalley SR, Benedetti J, Hundahl SA, Estes NC, Stemmermann GN, Haller DG, Ajani JA, Gunderson LL, Jessup JM, Martenson JA. Chemoradiotherapy after surgery compared with surgery alone for adenocarcinoma of the stomach or gastroesophageal junction. *N Engl J Med* 2001; **345**: 725-730 [PMID: [11547741](#) DOI: [10.1056/NEJMoa010187](#)]
- 53 **Saikawa Y**, Kubota T, Kumagai K, Nakamura R, Kumai K, Shigematsu N, Kubo A, Kitajima M, Kitagawa Y. Phase II study of chemoradiotherapy with S-1 and low-dose cisplatin for inoperable advanced gastric cancer. *Int J Radiat Oncol Biol Phys* 2008; **71**: 173-179 [PMID: [17996385](#) DOI: [10.1016/j.ijrobp.2007.09.010](#)]
- 54 **Pang X**, Wei W, Leng W, Chen Q, Xia H, Chen L, Li R. Radiotherapy for gastric cancer: a systematic review and meta-analysis. *Tumour Biol* 2014; **35**: 387-396 [PMID: [23929390](#) DOI: [10.1007/s13277-013-1054-y](#)]
- 55 **Liang X**, Zhu J, Li Y, Xu Y, Chen K, Lv L, Mao W. Treatment strategies for metastatic gastric cancer: chemotherapy, palliative surgery or radiotherapy? *Future Oncol* 2020; **16**: 91-102 [PMID: [31868545](#) DOI: [10.2217/fon-2019-0495](#)]
- 56 **Hiramoto S**, Kikuchi A, Tetsuso H, Yoshioka A, Kohigashi Y, Maeda I. Efficacy of palliative radiotherapy and chemo-radiotherapy for unresectable gastric cancer demonstrating bleeding and obstruction. *Int J Clin Oncol* 2018; **23**: 1090-1094 [PMID: [30019177](#) DOI: [10.1007/s10147-018-1317-0](#)]
- 57 **N. U.** Identifier: NCT04248452. Testing the Addition of Radiotherapy to the Usual Treatment (Chemotherapy) for Patients With Esophageal and Gastric Cancer That Has Spread to a Limited Number of Other Places in the Body. ClinicalTrialsgov [Internet]. Bethesda (MD): National Library of Medicine (US) January 30, 2020
- 58 **He C**, Bian XY, Ni XZ, Shen DP, Shen YY, Liu H, Shen ZY, Liu Q. Correlation of human epidermal growth factor receptor 2 expression with clinicopathological characteristics and prognosis in gastric cancer. *World J Gastroenterol* 2013; **19**: 2171-2178 [PMID: [23599643](#) DOI: [10.3748/wjg.v19.i14.2171](#)]
- 59 **Jørgensen JT**, Hersom M. HER2 as a Prognostic Marker in Gastric Cancer - A Systematic Analysis of Data from the Literature. *J Cancer* 2012; **3**: 137-144 [PMID: [22481979](#) DOI: [10.7150/jca.4090](#)]
- 60 **Slamon D**, Eiermann W, Robert N, Pienkowski T, Martin M, Press M, Mackey J, Glaspy J, Chan A, Pawlicki M, Pinter T, Valero V, Liu MC, Sauter G, von Minckwitz G, Visco F, Bee V, Buyse M, Bendahmane B, Tabah-Fisch I, Lindsay MA, Riva A, Crown J; Breast Cancer International Research Group. Adjuvant trastuzumab in HER2-positive breast cancer. *N Engl J Med* 2011; **365**: 1273-1283 [PMID: [21991949](#) DOI: [10.1056/NEJMoa0910383](#)]
- 61 **Kast K**, Schoffer O, Link T, Forberger A, Petzold A, Niedostatek A, Werner C, Klug SJ, Werner A, Gatzweiler A, Richter B, Baretton G, Wimberger P. Trastuzumab and survival of patients with metastatic breast cancer. *Arch Gynecol Obstet* 2017; **296**: 303-312 [PMID: [28616827](#) DOI: [10.1007/s00404-017-4421-x](#)]
- 62 **Kurokawa Y**, Sugimoto N, Miwa H, Tsuda M, Nishina S, Okuda H, Imamura H, Gamoh M, Sakai D, Shimokawa T, Komatsu Y, Doki Y, Tsujinaka T, Furukawa H. Phase II study of trastuzumab in combination with S-1 plus cisplatin in HER2-positive gastric cancer (HERBIS-1). *Br J Cancer* 2014; **110**: 1163-1168 [PMID: [24473399](#) DOI: [10.1038/bjc.2014.18](#)]
- 63 **Li Q**, Jiang H, Li H, Xu R, Shen L, Yu Y, Wang Y, Cui Y, Li W, Yu S, Liu T. Efficacy of trastuzumab beyond progression in HER2 positive advanced gastric cancer: a multicenter prospective observational cohort study. *Oncotarget* 2016; **7**: 50656-50665 [PMID: [27409420](#) DOI: [10.18632/oncotarget.10456](#)]
- 64 **Gumusay O**, Benekli M, Ekinci O, Baykara M, Ozet A, Coskun U, Demirci U, Uner A, Dursun A, Atak EY, Buyukberber S. Discordances in HER2 status between primary gastric cancer and corresponding metastatic sites. *Jpn J Clin Oncol* 2015; **45**: 416-421 [PMID: [25732909](#) DOI: [10.1093/jjco/hyv020](#)]
- 65 **Gianni L**, Lladó A, Bianchi G, Cortes J, Kellokumpu-Lehtinen PL, Cameron DA, Miles D, Salvagni S, Wardley A, Goeminne JC, Hersberger V, Baselga J. Open-label, phase II, multicenter, randomized

- study of the efficacy and safety of two dose levels of Pertuzumab, a human epidermal growth factor receptor 2 dimerization inhibitor, in patients with human epidermal growth factor receptor 2-negative metastatic breast cancer. *J Clin Oncol* 2010; **28**: 1131-1137 [PMID: 20124183 DOI: 10.1200/JCO.2009.24.1661]
- 66 **Liu T**, Qin Y, Li J, Xu R, Xu J, Yang S, Qin S, Bai Y, Wu C, Mao Y, Wu H, Ge Y, Shen L. Pertuzumab in combination with trastuzumab and chemotherapy for Chinese patients with HER2-positive metastatic gastric or gastroesophageal junction cancer: a subpopulation analysis of the JACOB trial. *Cancer Commun (Lond)* 2019; **39**: 38 [PMID: 31234927 DOI: 10.1186/s40880-019-0384-6]
- 67 **Makiyama A**, Sukawa Y, Kashiwada T, Kawada J, Hosokawa A, Horie Y, Tsuji A, Moriwaki T, Tanioka H, Shinozaki K, Uchino K, Yasui H, Tsukuda H, Nishikawa K, Ishida H, Yamanaka T, Yamazaki K, Hironaka S, Esaki T, Boku N, Hyodo I, Muro K. Randomized, Phase II Study of Trastuzumab Beyond Progression in Patients With HER2-Positive Advanced Gastric or Gastroesophageal Junction Cancer: WJOG7112G (T-ACT Study). *J Clin Oncol* 2020; **38**: 1919-1927 [PMID: 32208960 DOI: 10.1200/JCO.19.03077]
- 68 **Perez J**, Garrigós L, Gion M, Jänne PA, Shitara K, Siena S, Cortés J. Trastuzumab deruxtecan in HER2-positive metastatic breast cancer and beyond. *Expert Opin Biol Ther* 2021; **21**: 811-824 [PMID: 33759669 DOI: 10.1080/14712598.2021.1890710]
- 69 **Shitara K**, Bang YJ, Iwasa S, Sugimoto N, Ryu MH, Sakai D, Chung HC, Kawakami H, Yabusaki H, Lee J, Saito K, Kawaguchi Y, Kamio T, Kojima A, Sugihara M, Yamaguchi K; DESTINY-Gastric01 Investigators. Trastuzumab Deruxtecan in Previously Treated HER2-Positive Gastric Cancer. *N Engl J Med* 2020; **382**: 2419-2430 [PMID: 32469182 DOI: 10.1056/NEJMoa2004413]
- 70 **Fuchs CS**, Tomasek J, Yong CJ, Dumitru F, Passalacqua R, Goswami C, Safran H, Dos Santos LV, Aprile G, Ferry DR, Melichar B, Tehfe M, Topuzov E, Zalcborg JR, Chau I, Campbell W, Sivanandan C, Pikiel J, Koshiji M, Hsu Y, Liepa AM, Gao L, Schwartz JD, Taberero J; REGARD Trial Investigators. Ramucirumab monotherapy for previously treated advanced gastric or gastro-oesophageal junction adenocarcinoma (REGARD): an international, randomised, multicentre, placebo-controlled, phase 3 trial. *Lancet* 2014; **383**: 31-39 [PMID: 24094768 DOI: 10.1016/S0140-6736(13)61719-5]
- 71 **Wilke H**, Muro K, Van Cutsem E, Oh SC, Bodoky G, Shimada Y, Hironaka S, Sugimoto N, Lipatov O, Kim TY, Cunningham D, Rougier P, Komatsu Y, Ajani J, Emig M, Carlesi R, Ferry D, Chandrawansa K, Schwartz JD, Ohtsu A; RAINBOW Study Group. Ramucirumab plus paclitaxel vs placebo plus paclitaxel in patients with previously treated advanced gastric or gastro-oesophageal junction adenocarcinoma (RAINBOW): a double-blind, randomised phase 3 trial. *Lancet Oncol* 2014; **15**: 1224-1235 [PMID: 25240821 DOI: 10.1016/S1470-2045(14)70420-6]
- 72 **Al-Batran SE**, Hofheinz RD, Schmalenberg H. Perioperative ramucirumab in combination with FLOT vs FLOT alone for resectable esophagogastric adenocarcinoma (RAMSES/FLOT7): results of the phase II-portion—a multicenter, randomised phase II/III trial of the German AIO and Italian GOIM. *J Clin Oncol* 2020; **38**
- 73 **Kang YK**, Boku N, Satoh T, Ryu MH, Chao Y, Kato K, Chung HC, Chen JS, Muro K, Kang WK, Yeh KH, Yoshikawa T, Oh SC, Bai LY, Tamura T, Lee KW, Hamamoto Y, Kim JG, Chin K, Oh DY, Minashi K, Cho JY, Tsuda M, Chen LT. Nivolumab in patients with advanced gastric or gastro-oesophageal junction cancer refractory to, or intolerant of, at least two previous chemotherapy regimens (ONO-4538-12, ATTRACTION-2): a randomised, double-blind, placebo-controlled, phase 3 trial. *Lancet* 2017; **390**: 2461-2471 [PMID: 28993052 DOI: 10.1016/S0140-6736(17)31827-5]
- 74 **Fuchs CS**, Doi T, Jang RW, Muro K, Satoh T, Machado M, Sun W, Jalal SI, Shah MA, Metges JP, Garrido M, Golan T, Mandala M, Wainberg ZA, Catenacci DV, Ohtsu A, Shitara K, Geva R, Bleeker J, Ko AH, Ku G, Philip P, Enzinger PC, Bang YJ, Levitan D, Wang J, Rosales M, Dalal RP, Yoon HH. Safety and Efficacy of Pembrolizumab Monotherapy in Patients With Previously Treated Advanced Gastric and Gastroesophageal Junction Cancer: Phase 2 Clinical KEYNOTE-059 Trial. *JAMA Oncol* 2018; **4**: e180013 [PMID: 29543932 DOI: 10.1001/jamaoncol.2018.0013]
- 75 **Shitara K**, Van Cutsem E, Bang YJ, Fuchs C, Wyrwicz L, Lee KW, Kudaba I, Garrido M, Chung HC, Lee J, Castro HR, Mansoor W, Braghiroli MI, Karaseva N, Caglevic C, Villanueva L, Goekkurt E, Satake H, Enzinger P, Alsina M, Benson A, Chao J, Ko AH, Wainberg ZA, Kher U, Shah S, Kang SP, Taberero J. Efficacy and Safety of Pembrolizumab or Pembrolizumab Plus Chemotherapy vs Chemotherapy Alone for Patients With First-line, Advanced Gastric Cancer: The KEYNOTE-062 Phase 3 Randomized Clinical Trial. *JAMA Oncol* 2020; **6**: 1571-1580 [PMID: 32880601 DOI: 10.1001/jamaoncol.2020.3370]
- 76 W. G. Identifier: NCT04510064, PD-1 Antibody Combined With Modified FLOT Regimen in the Treatment of Unresectable Locally Advanced or Limited Metastatic Gastric Cancer. ClinicalTrials.gov [Internet]. Bethesda (MD): National Library of Medicine (US) August 12, 2020
- 77 **Al-Batran SPC**, Hofheinz R. Perioperative atezolizumab in combination with FLOT vs FLOT alone in patients with resectable esophagogastric adenocarcinoma: DANTE, a randomised, open-label phase II trial of the German Gastric Group of the AIO and the SAKK. *J Clin Oncol* 2019; **37**
- 78 **Lorenzen S**, Pauligk C, Goetze TO, Knorrenschild JR, Goekkurt E, Kullmann F, Pink D, Ettrich TJ, Homann N, Angermeier S, Thuss-Patience PC, Lindig U, Bitzer M, Dechow T, Schuch G, Schmalenberg H, Junge S, Hofheinz RD, Al-Batran S-E. Modified FOLFOX vs modified FOLFOX plus nivolumab and ipilimumab in patients with previously untreated advanced or metastatic adenocarcinoma of the stomach or gastroesophageal junction - Safety Results from AIO-STO-0417:

- A randomized phase II trial of the German Gastric Group of the AIO. *Annals of Oncology* 2020; **31** [DOI: [10.1016/j.annonc.2020.08.1949](https://doi.org/10.1016/j.annonc.2020.08.1949)]
- 79 **Yamaguchi K**, Yoshida K, Tanahashi T, Takahashi T, Matsuhashi N, Tanaka Y, Tanabe K, Ohdan H. The long-term survival of stage IV gastric cancer patients with conversion therapy. *Gastric Cancer* 2018; **21**: 315-323 [PMID: [28616743](https://pubmed.ncbi.nlm.nih.gov/28616743/) DOI: [10.1007/s10120-017-0738-1](https://doi.org/10.1007/s10120-017-0738-1)]
- 80 **Sato Y**, Ohnuma H, Nobuoka T, Hirakawa M, Sagawa T, Fujikawa K, Takahashi Y, Shinya M, Katsuki S, Takahashi M, Maeda M, Okagawa Y, Naoki U, Kikuch S, Okamoto K, Miyamoto H, Shimada M, Takemasa I, Kato J, Takayama T. Conversion therapy for inoperable advanced gastric cancer patients by docetaxel, cisplatin, and S-1 (DCS) chemotherapy: a multi-institutional retrospective study. *Gastric Cancer* 2017; **20**: 517-526 [PMID: [27553665](https://pubmed.ncbi.nlm.nih.gov/27553665/) DOI: [10.1007/s10120-016-0633-1](https://doi.org/10.1007/s10120-016-0633-1)]
- 81 **Fukuchi M**, Ishiguro T, Ogata K, Suzuki O, Kumagai Y, Ishibashi K, Ishida H, Kuwano H, Mochiki E. Prognostic Role of Conversion Surgery for Unresectable Gastric Cancer. *Ann Surg Oncol* 2015; **22**: 3618-3624 [PMID: [25663597](https://pubmed.ncbi.nlm.nih.gov/25663597/) DOI: [10.1245/s10434-015-4422-6](https://doi.org/10.1245/s10434-015-4422-6)]
- 82 **Nakamura M**, Ojima T, Nakamori M, Katsuda M, Tsuji T, Hayata K, Kato T, Yamaue H. Conversion Surgery for Gastric Cancer with Peritoneal Metastasis Based on the Diagnosis of Second-Look Staging Laparoscopy. *J Gastrointest Surg* 2019; **23**: 1758-1766 [PMID: [30264385](https://pubmed.ncbi.nlm.nih.gov/30264385/) DOI: [10.1007/s11605-018-3983-7](https://doi.org/10.1007/s11605-018-3983-7)]
- 83 **Yasufuku I**, Nunobe S, Ida S, Kumagai K, Ohashi M, Hiki N, Sano T. Conversion therapy for peritoneal lavage cytology-positive type 4 and large type 3 gastric cancer patients selected as candidates for R0 resection by diagnostic staging laparoscopy. *Gastric Cancer* 2020; **23**: 319-327 [PMID: [31350702](https://pubmed.ncbi.nlm.nih.gov/31350702/) DOI: [10.1007/s10120-019-00994-0](https://doi.org/10.1007/s10120-019-00994-0)]



Published by **Baishideng Publishing Group Inc**
7041 Koll Center Parkway, Suite 160, Pleasanton, CA 94566, USA
Telephone: +1-925-3991568
E-mail: bpgoffice@wjgnet.com
Help Desk: <https://www.f6publishing.com/helpdesk>
<https://www.wjgnet.com>

