



Teprotumumab in advanced reactivated thyroid eye disease

Olivia T. Cheng^a, Dianne M. Schlachter^{a,b,*}

^a Beaumont Eye Institute, 3535 West 13 Mile Road #555, Royal Oak, MI, USA

^b Consultants in Ophthalmic and Facial Plastic Surgery, 29201 Telegraph Road, Suite 324, Southfield, MI, USA

ARTICLE INFO

Keywords:

Thyroid eye disease (TED)
Teprotumumab
Proptosis
Clinical activity score (CAS)
Disease recurrence
Dysthyroid optic neuropathy (DON)

ABSTRACT

Purpose: To report the case of a patient with reactivated, refractory thyroid eye disease (TED) treated with teprotumumab.

Observations: A 51-year-old female with a 16-year history of thyroid eye disease previously treated with orbital decompression and multiple eyelid surgeries presented in a recurrent flare of the disease. The disease recurrence was refractory to intravenous steroid therapy and only partially responsive to oral steroid therapy, and the patient developed dysthyroid optic neuropathy in the right eye with decreased visual acuity and color vision. Clinical activity score was 8/10 and proptosis measurements were 27 mm OD and 26 mm OS. The patient underwent treatment with eight infusions of teprotumumab coinciding with a low taper of oral prednisone and experienced resolution of dysthyroid optic neuropathy, decrease of clinical activity score to 1, and dramatic improvement in proptosis (17 mm OD, 17 mm OS) and extraocular muscle size on imaging. Thirty weeks after completion of teprotumumab and 2 weeks after the second dose of the COVID vaccine, she experienced another flare and subsequently underwent bilateral orbital decompressions.

Conclusion: This case report suggests teprotumumab may be used in patients with reactivation of longstanding thyroid eye disease. Reduction of extraocular muscle size and improvement in proptosis suggest teprotumumab may be disease-modifying even in advanced cases.

1. Introduction

Thyroid eye disease (TED) is a complex autoimmune condition that is debilitating, disfiguring, and potentially vision-threatening. In 1945, Rundle described the natural history of TED as a period of active disease typically lasting 1–3 years followed by a static, inactive phase.¹ Treatment options have included glucocorticoids, orbital radiotherapy (ORT), and monoclonal antibodies including tocilizumab and rituximab² for moderate to severe active disease. Surgical decompression is generally reserved for inactive disease with persistent orbitopathy or active disease that is vision-threatening due to compressive optic neuropathy³ or severe surface disease.⁴ Recently, the FDA approved teprotumumab, a monoclonal antibody inhibitor of the insulin-like growth factor-1 receptor, for the treatment of TED. In the phase 3 clinical trials, only patients with onset of TED within 9 months were included, and key exclusion criteria included history of TED treatment with ORT, surgery, or glucocorticoids (cumulative dose \leq 1 g methylprednisolone) and evidence of optic neuropathy within the previous 6 months (including decreased visual acuity, color vision defect, or visual field defect).^{5,6} As

such, it has not been established whether teprotumumab is effective or indicated in advanced and refractory cases. Herein we present our experience with teprotumumab for a patient with a 16-year history of TED who had previously undergone right orbital decompression and multiple eyelid surgeries who presented with disease reactivation and subsequently developed dysthyroid optic neuropathy (DON) refractory to intravenous (IV) steroid therapy and only partially responsive to oral steroid therapy. Written consent was obtained from the patient for publication of identifiable photographs.

2. Case report

A 51-year-old female presented for evaluation of worsening protrusion and irritation of the right eye for the past year. She had a history of Graves' disease and a distant history of smoking. She had been diagnosed with TED over a decade prior and had undergone right orbital floor and medial wall decompression and right upper and lower eyelid retraction repair with other physicians. Her visual acuity was 20/20 in both eyes with normal color vision and no relative afferent pupillary

* Corresponding author. Consultants in Ophthalmic and Facial Plastic Surgery, 29201 Telegraph Road, Suite 324, Southfield, MI, 48034, USA.

E-mail address: dschlachter@facialworks.com (D.M. Schlachter).

<https://doi.org/10.1016/j.ajoc.2022.101484>

Received 18 April 2021; Received in revised form 6 March 2022; Accepted 7 March 2022

Available online 15 March 2022

2451-9936/© 2022 The Authors. Published by Elsevier Inc. This is an open access article under the CC BY-NC-ND license (<http://creativecommons.org/licenses/by-nc-nd/4.0/>).

defect (RAPD). External exam was notable for restriction of abduction (−2) OD, resistance to retropulsion OD, and asymmetric proptosis measuring 24 mm OD and 22 mm OS. Intraocular pressures, fundus exam, and recent Humphrey visual field were all normal. Clinical activity score (CAS) was 1, attributed to chemosis. A computed tomography scan was ordered and demonstrated bilateral enlargement of extraocular muscles, right more than left, crowding of the right orbital apex, and evidence of previous right orbital decompression surgery.

The patient's presentation gradually worsened on the right side over the next two months with an increase in CAS to 5/10 and an increase in proptosis OD by 2 mm. She was started on a course of oral prednisone at 40 mg per day (0.75mg/kg) to taper by 10 mg every four days, and a course of intravenous (IV) methylprednisolone at 500 mg IV weekly for six weeks followed by 250 mg IV weekly for six weeks was ordered. Prior to the start of IV therapy, despite treatment with oral prednisone, she began to show signs of dysthyroid optic neuropathy (DON), with decrease in visual acuity on the right side to 20/100, depressed Ishihara color plates (8/11) OD, and progressive restriction in extraocular motility on the right in adduction (−1) and infraduction (−1). CAS was 7/10. At that time, the patient was offered further orbital decompression surgery which she declined.

While on IV steroid therapy, the patient's visual acuity initially improved to 20/40 OD and CAS improved to 3/10 while extraocular movements remained decreased and exophthalmos unchanged. Despite early improvements however, her exam worsened significantly 2 weeks after completing the 12-week treatment regimen with proptosis increasing to 27 mm OD and 24 mm OS and CAS of 8/10. Her visual acuity dropped to 20/80 OD, and she had severely depressed Ishihara color plates (1.5/11) OD. Repeat CT scan demonstrated further enlargement of extraocular muscles, right more than left, with compression at the right orbital apex (Fig. 1 B & C). At that point, teprotumumab had recently been approved by the Food and Drug Administration for treatment of active TED. The patient was interested in starting the medication with the understanding that clinical trials had only evaluated response in patients with recent diagnosis of TED, no

evidence of optic neuropathy, and no previous treatment except for much smaller cumulative doses of steroids than she had received. Given the severity of her clinical picture and a likely delay in starting teprotumumab, a decision was made to simultaneously order teprotumumab and schedule relatively urgent bilateral orbital decompression surgery. The patient was also started on a second taper of oral prednisone beginning at 40 mg/day and tapering by 10 mg every four days. On follow-up exam two weeks later, just prior to her scheduled decompression surgery in March 2019, the patient's visual acuity had improved to 20/40 OD and color vision had improved (10/11) OD on her second course of oral prednisone, but her CAS remained at 8/10 with worsened proptosis OS (27 OD and 26 OS).

Unfortunately, her surgery was canceled due to restrictions related to the start of the COVID-19 pandemic. The patient followed via telehealth visits over the next few weeks as her appearance and symptoms continued to worsen. She was restarted on a low taper of oral prednisone at 10 mg/day for 1 week followed by 5 mg/day for 1 week (she was off oral prednisone for 5 weeks prior). One week into this taper, and two months after her last dose of IV steroids, an eight-cycle treatment of teprotumumab infusions was started at three-week intervals. No further oral prednisone was used after 1 week into teprotumumab infusions. The patient began to experience significant improvement in symptoms within one week of the first infusion. While following via telehealth visits, she documented the appearance of her eyes by taking her own photographs, which demonstrated dramatic improvement in proptosis and orbital congestion after the first two infusions (Fig. 1A and D). After four infusions, she presented for her first in-person evaluation since starting teprotumumab. Snellen visual acuity was 20/20 OU, color vision was 11/11 OU, Hertel measurements had improved to 19 mm OD and 19.5 mm OS, and CAS was 2/10. CT scan was repeated after five teprotumumab infusions, three months after completion of the low taper of oral prednisone, and demonstrated markedly decreased extraocular muscle size and improved proptosis (Fig. 1E and F). Clinical presentation continued to improve through the end of treatment. Four months after completion of teprotumumab, the patient had CAS 1/10, attributed to mild injection OU, and Hertel measurements 17 mm OD and 17 mm OS. During teprotumumab infusions, she experienced loose stools approximately three times per week, and in the last two months of treatment, she had muscle spasms in her lower extremities which improved with magnesium and potassium supplementation. She found these adverse effects to be overall mild and tolerable.

Thirty weeks after completion of teprotumumab, two weeks after her second dose of the mRNA-1273 (Moderna) COVID vaccine, our patient experienced another flare of her TED. CAS was 9/10 and Hertel measurements were 22 mm OD and 23 OS. At that time, she was put back on oral prednisone which temporized but did not resolve the flare. She was offered a second round of teprotumumab infusions versus further decompression surgery, and she opted to undergo bilateral lateral and medial orbital wall decompressions. CT scan was repeated prior to surgery and demonstrated significant re-enlargement of the extraocular muscles (Fig. 2). At the time of this report, thirteen months after completion of teprotumumab, and two months after her surgeries, she is healing very well with no signs of active TED, visual acuity 20/20 OU, and Hertel measurements of 17 and 18.

3. Discussion

TED is a challenging and heterogenous autoimmune condition that can significantly impair functioning and quality of life.^{7,8} Until recently, medical therapy options have included glucocorticoids, orbital radiotherapy, and monoclonal antibodies for disease in the active phase. These options have been known to be less than optimal, with variable treatment benefit, frequent association with serious side effects, and questionable impact on ultimate disease outcome.^{4,9,10} When active disease is severe enough to cause dysthyroid optic neuropathy (DON), urgent surgical decompression is also considered. Teprotumumab was

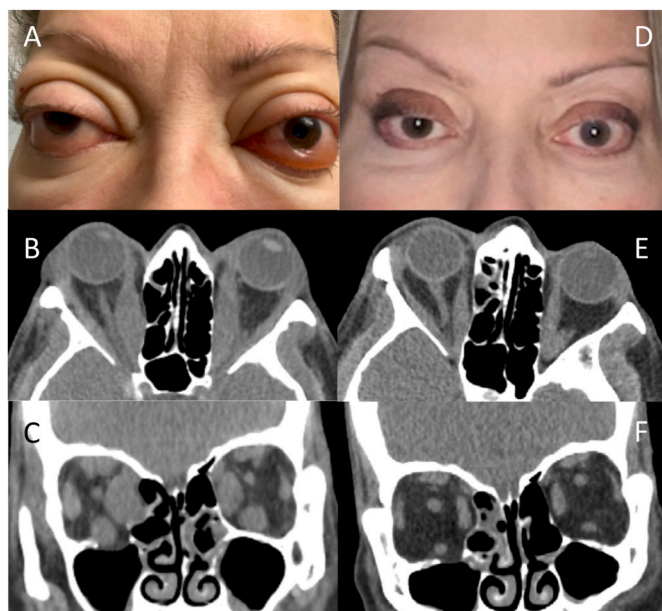


Fig. 1. A. External photograph taken by patient immediately prior to treatment. B & C. Computed tomography of the orbits showing proptosis and extraocular muscle enlargement before treatment. D. External photograph taken by patient after two weeks of low-dose oral prednisone and two infusions of teprotumumab. E & F. Computed tomography of the orbits showing reduction of proptosis and extraocular muscle size after two weeks of low-dose oral prednisone and five infusions of teprotumumab.

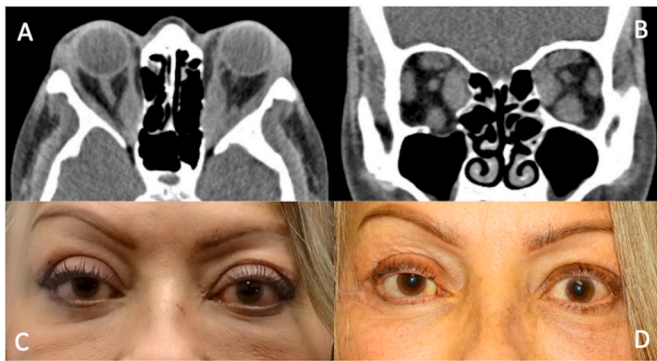


Fig. 2. A & B. Computed tomography of the orbits 42 weeks after completion of teprotumumab demonstrating recurrence of extraocular muscle enlargement and proptosis. C. External photograph taken at 33 weeks after completion of teprotumumab, when the patient presented with disease recurrence. D. External photograph taken 1 week after bilateral medial and lateral wall decompression surgeries.

approved by the FDA for TED in January of 2020, and thus far clinical trials have demonstrated its efficacy for recent-onset TED in the active phase that does not show evidence of DON.^{5,6} To date, there have been a few individual reports of DON responsive to teprotumumab,^{11,12} and only one previous report of reactivation-stage disease treated with teprotumumab.¹² In that report, a patient who had undergone left orbital decompression 15 years prior presented with disease recurrence with DON. The patient experienced improvement in CAS, proptosis, VA, color vision, and perimetry after three infusions of teprotumumab, but treatment was discontinued due to multiple side effects. In this report we presented a patient with a 16-year history of TED, previously treated with right orbital decompression surgery and multiple eyelid surgeries, who presented with disease reactivation with DON and underwent 8 infusions of teprotumumab with one week of overlap with a two-week course of low-dose oral prednisone.

The patient reported significant improvement in pain and discomfort after only one infusion. This rapid response is consistent with the early clinical improvement seen in the clinical trials.^{5,6} With the full course of treatment, our patient had proptosis improvements of -10 mm OD and -9 mm OS from prior to infusions. These observations suggest her dramatic improvement was a direct result of teprotumumab and oral steroids rather than spontaneous remission due to natural disease course. Of note, teprotumumab improved the high CAS and proptosis that were refractory to oral steroids. Her marked response is also consistent with previous observations that patients with greater baseline disease burden experience greater improvement with teprotumumab.¹²

Our patient's response to teprotumumab is particularly notable in light of her disease history. Though the natural course of TED has long been thought to follow Rundle's curve, some patients are known to have recurrent flares of disease well after they have reached the "inactive" phase. It is not known whether in these cases the pathophysiology of disease differs from that of the initial flare. In disease recurrence, is the fibrotic orbital tissue somehow reverted into active inflammatory tissue? Does some fibrotic orbital tissue remain stable while other tissues become inflamed? Indeed, the case of stable, inactive TED with low CAS responsive to teprotumumab reported by Ozzello et al.¹³ suggests the "fibrotic, inactive" phase of TED may very well be active at the cellular level even if clinically inactive. These are questions to be answered as progress is made in elucidating the pathophysiology of this complex disease.

Of note, our patient's presentation initially improved on IV corticosteroid treatment but significantly worsened shortly after completion of therapy. Recurrence of active disease is known to be common both during tapering of corticosteroids and after therapy completion.¹⁴ Corticosteroids do not alter the underlying pathophysiology of TED and

likely only mask the inflammatory effects of active TED without changing disease progression.¹⁵ Considering corticosteroids are known to induce hyperinsulinism,¹⁶ and insulin has been shown to stimulate hepatic synthesis of IGF-1,¹⁷ it is reasonable to hypothesize that corticosteroid use may have opposing effects to those of teprotumumab. Likewise, repeat orbital decompression was initially considered a sub-optimal choice in this case, as surgery is known to carry the risk of exacerbating disease.¹⁸ Moreover, decompression in the active phase and repeat decompression are both associated with more frequent complications including orbital hemorrhage, diplopia, enophthalmos, and hypoglobus.^{19,20,21}

Our patient experienced a rebound of her disease 30 weeks after completion of teprotumumab and two weeks after her second dose of the mRNA-1273 (Moderna) COVID vaccine. In the follow-up of patients included in the two pivotal randomized controlled trials of teprotumumab, durability of response at 51 weeks after treatment for proptosis, diplopia, and ophthalmic composite outcome ranged from 67 to 83%.²² To our knowledge, there has been one previously-reported case of new-onset TED following the COVID vaccine.²³ That case and the experience of our patient are in line with the increasing number of reports of various autoimmune phenomena following COVID vaccination.²⁴⁻²⁶ When our patient ultimately underwent repeat decompression surgery after her most recent flare, she responded very well to surgery without exacerbation of disease.

Our observation provides new insight and hope for the treatment of advanced, refractory TED. To our knowledge, this case is only the second report of disease reactivation in chronic TED responsive to teprotumumab. Our patient had undergone previous right orbital decompression, her condition was refractory to IV steroids and insufficiently controlled on oral steroids. Repeat surgical decompression was not an option at the time. She was able to tolerate 8 infusions with only mild side effects. As with all single case reports, it is difficult to extrapolate this experience to other patients with reactivated, longstanding, and/or refractory TED. Many questions remain to be addressed in future studies. Is teprotumumab an alternative to orbital decompression surgery in cases of DON or cases of inactive TED with persistent orbitopathy? What is the optimal dose and durability of treatment? What are the factors that lead to disease reactivation? These are scientifically interesting and clinically relevant questions for future study.

4. Conclusions

Teprotumumab may be a disease-altering treatment for reactivated TED. Further investigation into the efficacy of teprotumumab for reactivated, refractory, and/or advanced TED is warranted.

5. Patient consent

Consent to publish this case report has been obtained from the patient in writing.

Funding

No funding or grant support.

6. Authorship

All authors attest that they meet the current ICMJE criteria for Authorship.

Declaration of competing interest

DMS is a consultant and speaker for Horizon Therapeutics. OTC has no financial disclosures.

Acknowledgements

None.

References

- Rundle FF, Wilson CW. Development and course of exophthalmos and ophthalmoplegia in Graves' disease with special reference to the effect of thyroidectomy. *Clin Sci*. 1945;5(3-4):177–194.
- Strianese D. Efficacy and safety of immunosuppressive agents for thyroid eye disease. *Ophthalmic Plast Reconstr Surg*. 2018;34(4S Suppl 1):S56–S59.
- Choe CH, Cho RI, Elnor VM. Comparison of lateral and medial orbital decompression for the treatment of compressive optic neuropathy in thyroid eye disease. *Ophthalmic Plast Reconstr Surg*. 2011;27(1):4–11.
- Smith TJ, Hegedüs L. Graves' disease. *N Engl J Med*. 2016;375(16):1552–1565.
- Smith TJ, Kahaly GJ, Ezra DG, et al. Teprotumumab for thyroid-associated ophthalmopathy. *N Engl J Med*. 2017;376(18):1748–1761.
- Douglas RS, Kahaly GJ, Patel A, et al. Teprotumumab for the treatment of active thyroid eye disease. *N Engl J Med*. 2020;382(4):341–352.
- Ponto KA, Pitz S, Pfeiffer N, Hommel G, Weber MM, Kahaly GJ. Quality of life and occupational disability in endocrine orbitopathy. *Dtsch Arztebl Int*. 2009;106(17):283.
- Park JJ, Sullivan TJ, Mortimer RH, Wagenaar M, Perry-Keene DA. Assessing quality of life in Australian patients with Graves' ophthalmopathy. *Br J Ophthalmol*. 2004;88(1):75–78.
- Sandler HM, Rubenstein JH, Fowble BL, Sergott RC, Savino PJ, Bosley TM. Results of radiotherapy for thyroid ophthalmopathy. *Int J Radiat Oncol Biol Phys*. 1989;17(4):823–827.
- Bartalena L, Krassas GE, Wiersinga W, et al. Efficacy and safety of three different cumulative doses of intravenous methylprednisolone for moderate to severe and active Graves' orbitopathy. *J Clin Endocrinol Metab*. 2012;97(12):4454–4463.
- Sears CM, Azad AD, Dosiou C, Kossler AL. Teprotumumab for dysthyroid optic neuropathy: early response to therapy [published online ahead of print, 2020 Sep 22]. *Ophthalmic Plast Reconstr Surg*. 2020. <https://doi.org/10.1097/IOP.0000000000001831>.
- Diniz SB, Cohen LM, Roelofs KA, Rootman DB. Early experience with the clinical use of teprotumumab in a heterogenous thyroid eye disease population [published online ahead of print, 2021 mar 8]. *Ophthalmic Plast Reconstr Surg*. 2021. <https://doi.org/10.1097/IOP.0000000000001959>.
- Ozzello DJ, Kikkawa DO, Korn BS. Early experience with teprotumumab for chronic thyroid eye disease. *Am J Ophthalmol Case Rep*. 2020;100744.
- Godfrey KJ, Kazim M. Radiotherapy for active thyroid eye disease. *Ophthalmic Plast Reconstr Surg*. 2018;34(4S suppl 1):S98–S104.
- Douglas RS. Teprotumumab, an insulin-like growth factor-1 receptor antagonist antibody, in the treatment of active thyroid eye disease: a focus on proptosis. *Eye*. 2019;33(2):183–190.
- Tamez-Pérez HE, Quintanilla-Flores DL, Rodríguez-Gutiérrez R, González-González JG, Tamez-Peña AL. Steroid hyperglycemia: prevalence, early detection and therapeutic recommendations: a narrative review. *World J Diabetes*. 2015;6(8):1073–1081.
- Böni-Schnetzler M, Schmid C, Meier PJ, Froesch ER. Insulin regulates insulin-like growth factor I mRNA in rat hepatocytes. *Am J Physiol*. 1991;260(6 Pt 1):E846–E851.
- Baldeschi L, Lupetti A, Vu P, Wakelkamp IM, Prummel MF, Wiersinga WM. Reactivation of Graves' orbitopathy after rehabilitative orbital decompression. *Ophthalmology*. 2007;114(7):1395–1402.
- Zhang-Nunes SX, Dang S, Garneau HC, et al. Characterization and outcomes of repeat orbital decompression for thyroid-associated orbitopathy. *Orbit*. 2015;34:57–65.
- McNab AA. Orbital decompression for thyroid orbitopathy. *Aust N Z J Ophthalmol*. 1997;25:55–61.
- Dumont N, Bouletreau P, Guyot L. Reprises chirurgicales après décompression orbitaire pour ophtalmopathie dysthyroïdienne [Reoperation after orbital decompression for Graves' ophthalmopathy]. *Rev Stomatol Chir Maxillofac*. 2012;113(2):81–86.
- Kahaly GJ, Douglas RS, Holt RJ, Sile S, Smith TJ. Teprotumumab for patients with active thyroid eye disease: a pooled data analysis, subgroup analyses, and off-treatment follow-up results from two randomised, double-masked, placebo-controlled, multicentre trials. *Lancet Diabetes Endocrinol*. 2021;9(6):360–372.
- Rubinstein TJ. Thyroid eye disease following COVID-19 vaccine in a patient with a history Graves' disease: a case report. *Ophthalmic Plast Reconstr Surg*. 2021;37(6):e221–e223.
- Alam W. COVID-19 vaccine-induced immune thrombotic thrombocytopenia: a review of the potential mechanisms and proposed management. *Sci Prog*. 2021;104(2), 368504211025927.
- İremli BG, Şendur SN, Ünlütürk U. Three cases of subacute thyroiditis following SARS-CoV-2 vaccine: postvaccination ASIA syndrome. *J Clin Endocrinol Metab*. 2021;106(9):2600–2605.
- Chen Y, Xu Z, Wang P, et al. New-onset Autoimmune Phenomena Post-COVID-19 Vaccination. 2021. <https://doi.org/10.1111/imm.13443> [published online ahead of print, 2021 Dec 27]. *Immunology*.