

## Long-term follow-up of dental single implants under immediate orthodontic load

Lisiane Meira Palagi<sup>a</sup>; Carlos Eduardo Sabrosa<sup>b</sup>; Eveline C. B. Gava<sup>c</sup>; Tiziano Baccetti<sup>d</sup>; Jose Augusto M. Miguel<sup>e</sup>

### ABSTRACT

**Objective:** To evaluate the success of osseointegrated implants under immediate prosthetic and orthodontic forces after a follow-up period of at least 2 years.

**Materials and Methods:** The sample included 20 titanium implants which were used as orthodontic and prosthetic anchorage of immediately loaded single-crowns on a total of 13 patients. A 40 N initial torque was considered the minimum for inclusion in the sample. All implants received screwed provisional crowns immediately after surgery. The implants were randomly divided into two groups: the control group (9 implants) and the immediate orthodontic loading group (11 implants). A healing period of 4 months was observed before orthodontic loads were applied to the control group implants. For the immediate orthodontic loading group, orthodontic forces were applied within 24 hours. The maximum orthodontic force applied in both groups was 200 g. After 6 months of orthodontic movement, clinical and radiographic evaluations were obtained. Implants were considered successful when favorable results were obtained in all evaluations.

**Results:** After a 2-year follow-up, the success rates were 90.9% and 88.9%, respectively, in the orthodontic loading group and the control group. Each group had one failure.

**Conclusion:** Shortening the healing period for the application of orthodontic forces did not seem to affect the success of osseointegrated implants used as anchorage. (*Angle Orthod.* 2010;80:807–811.)

**KEY WORDS:** Orthodontic anchorage; Osseointegration

### INTRODUCTION

The need for orthodontic treatment has increased in the adult population. However, many adult or aging patients frequently require integrated multidisciplinary

treatment because of dental loss, which leads to difficulties or even impairment in solving biomechanical problems related to orthodontic anchorage. The use of osseointegrated implants has been a valid alternative in such cases. Besides promoting absolute anchorage during orthodontic movement, osseointegrated implants may also be used with no damage as a base for posterior oral fixed prosthetic rehabilitation, as they are considered a secure, predictable, and durable method.<sup>1</sup>

Although high success rates have been reported for immediate load applied to implants and for implants used for orthodontic anchorage, few studies have combined these two purposes to evaluate the possible use of immediate orthodontic load on osseointegrated implants used for anchorage.<sup>2–5</sup>

Considering the null hypothesis that there is no difference in the success rate of immediately loaded implant-supported crowns that are used as orthodontic anchorage immediately or after 4 months of healing, the present study aimed to evaluate the success rate after application of immediate orthodontic load to implants.

<sup>a</sup> Former Resident, Department of Orthodontics, Faculty of Dentistry, Rio de Janeiro State University, Rio de Janeiro, Brazil.

<sup>b</sup> Professor, Department of Restorative Dentistry, Faculty of Dentistry, Rio de Janeiro State University, Rio de Janeiro, Brazil.

<sup>c</sup> Student – Graduate (MS), Department of Orthodontics, Faculty of Dentistry, Rio de Janeiro State University, Rio de Janeiro, Brazil.

<sup>d</sup> Assistant Professor, Department of Orthodontics, University of Florence, Florence, Italy; Thomas M. Graber Visiting Scholar, Department of Orthodontics and Pediatric Dentistry, School of Dentistry, The University of Michigan, Ann Arbor, Mich.

<sup>e</sup> Professor, Department of Orthodontics, Faculty of Dentistry, Rio de Janeiro State University, Rio de Janeiro, Brazil.

Corresponding author: Dr Eveline Gava, Department of Orthodontics, Faculty of Dentistry, Rio de Janeiro State University, Av. Ataulfo de Paiva, 204 sl.506, Rio de Janeiro – RJ 22440-033 Brazil

(e-mail: evelinegava@gmail.com)

Accepted: March 2010. Submitted: February 2010.

© 2010 by The EH Angle Education and Research Foundation, Inc.

## MATERIALS AND METHODS

This is a prospective clinical study in which 20 implant sites were randomly allocated to two groups: immediate orthodontic load on provisional crowns (Group A) and delayed orthodontic load (Group B). Each sample was evaluated before and after orthodontic forces were applied to the prosthetic restorations performed on the implants of each group. This study had institutional approval.

Adult patients seeking orthodontic treatment at the Clinic for Orthodontic Graduate and Postgraduate Studies of Rio de Janeiro State University, Brazil, who were in need of corrective orthodontic therapy and prosthetic rehabilitation, including one or more single osseointegrated implants, were prospectively selected for this study. After exclusion criteria were applied for patients in this randomized controlled trial (RCT) (the same as described by Chiapasco and Gatti<sup>6</sup>), 13 patients were enrolled in the trial, seven men and six women. Patients' ages ranged from 22 to 56 years (mean, 35.7 years). A total of 20 edentulous areas were considered to be adequate sites for ultra self-tapping titanium implants. These implants were 4-mm wide and 13-mm long and had an enhanced surface treatment with double acid attack (SIN (Sistema de Implante), São Paulo, Brazil), which would receive further orthodontic loads on provisional crown restorations with a bracket embedded. None of the implants were the primary centric stop in occlusion in the segment, so the prosthetic load could be distributed among other posterior teeth.

As the primary purpose of implant positioning in the patients in the present study was related to the function of implants as orthodontic anchorage, the surgical guide filled with gutta-percha was built from a correctly made set-up diagnosis. Patients also used that guide during the computed tomography exam. As gutta-percha is a radiopaque material, the precise location for future implant placement was determined, thus allowing for quantitative and qualitative bone evaluation of the site.

The 20 implant sites were randomly assigned to Group A and Group B using Microsoft Office Excel 2003 software (Redmond, Wash). The group for each implant was determined at the day of surgery. Initially, anesthesia was performed for mandibular nerve block with lidocaine 1:100,000 (DFL Ind. e Com SA, Rio de Janeiro, Rio de Janeiro, Brazil). An incision for a mucoperiosteal flap was performed using a 15C scalpel blade (Benco Dental, Wilkes-Barre, Pa). The surgical guide was used to correctly position the implants. The last drill used was 0.7 mm smaller than the implant to be installed. All drills were used with an engine (Driller, São Paulo, São Paulo, Brazil) at

1200 rpm and a torque of 50 N/cm. After insertion of the implant, a prosthetic antirotational component (Connection, São Paulo, São Paulo, Brazil) was installed with a torque of 20 N/cm. The surgical procedure was completed with sutures of mononylon 5.0 (Ethicon, Johnson & Johnson Com, São Paulo, São Paulo, Brazil).

After surgery, oral hygiene instructions were given. Mouthwash with chlorhexidine gluconate 0.12% (Periogard, Colgate-Palmolive Industria e Comercio Ltda, São Paulo, São Paulo, Brazil) was recommended twice a day for 7 days after surgery. In addition, we prescribed 500 g of amoxicillin (Amoxil, GlaxoSmith Kline, Brentford, UK) every 8 hours for 7 days and 750 mg of acetaminophen (Tylenol, Johnson & Johnson Com, Sao Paulo, Sao Paulo, Brazil) every 6 hours in case of pain.

In Group A, the implants were immediately used as orthodontic anchorage under loads ranging from 60 to 200 g, as assessed with a dynamometer. Only implants assessed as presenting primary stability, that is, could support a load of 40 N,<sup>7-9</sup> were able to receive immediate load. In Group B, the traditional protocol was used of waiting 4 months before adding any orthodontic load over the implants,<sup>10</sup> although the provisional crown restorations had been already placed.

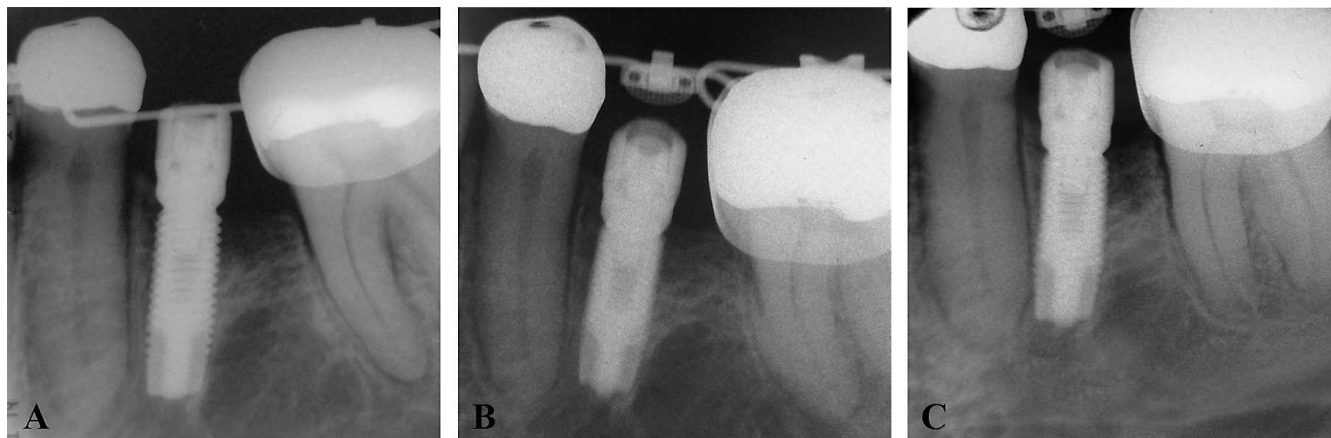
Group A consisted of 11 implants, placed in 5 female and 6 male patients ranging in age from 22 to 56 years (mean age, 35.9 years). Group B consisted of nine implants, placed in 3 female and 6 male patients ranging in age from 22 to 52 years (mean age, 35.3 years). Some patients received both types of implants and were assigned to Group A and Group B. The implants were evaluated clinically each six months after orthodontic load.

The following criteria was used to denote clinical success:<sup>6</sup>

- Absence of signs and symptoms of pain, infection, or discomfort;
- Absence of implant mobility, determined with the aid of the handles of two dental mirrors;
- Absence of peri-implantar radiolucency shown on periapical radiographs, indicating bone resorption.

## RESULTS

No dropouts were recorded. Of the 20 implants evaluated after 6 months of orthodontic load application on provisional crown restorations, 18 implants were not associated with any signs or symptoms of pain, infection, or neuropathy. Two implants were lost because of excess of mobility and lack of osseointegration: one in Group A (47 site) 2 months after the surgery and the other in Group B (46 site) 1 month



**Figure 1.** Radiographs taken (A) just after implant surgery, (B) 6 months after orthodontic and prosthetic loading, and (C) after 2 years and 7 months of follow-up. All the radiographs were taken using the paralleling method by means of radiographic positioners that standardized the distance (40 cm of focus/film distance) and angulation.

after the surgery. Both failures apparently happened because of poor hygiene with an excess of bacterial plaque in the cervical portion of the provisional crown.

Of the 11 implants in Group A, 10 were successful and only one failed (success rate of 90.9%). Of the nine implants in Group B, eight were successful and one failed (success rate of 88.9%).

After a minimum of 2 years of clinical and radiographic observation, no additional implants were found to be unsuccessful. Table 1 illustrates all the details of the 20 implants showing each implant site, movement type, and final result.

As for the radiographic evaluation, none of the successful cases in either group showed any radiolucent area indicating peri-implantar resorption. Bone ridge level appeared located above the second spiral ridge of the implant screw in all the successful implants of both groups (Figure 1).

## DISCUSSION

The posterior segments of the mandible were chosen as sites for the placement of single implants in this study as shown in Table 1. A recent systematic review revealed that those areas are the most well suited alveolar regions to receive immediately loaded implants.<sup>11</sup> Further, the posterior mandibular area is where edentulism is more frequent because of caries<sup>12</sup> or periodontal disease,<sup>13</sup> and it is a less esthetically demanding area compared with the anterior dentoalveolar regions. Also, a greater success rate of immediate occlusal load<sup>14,15</sup> has been reported for implants placed in the mandibular posterior area with respect to the posterior area of maxilla, which is more susceptible to failures.<sup>16–18</sup> The magnitude of force applied was the same described by several authors as being secure.<sup>2,5,19–27</sup> Moreover, a 200 g force is

considered appropriate to various orthodontic movements and potentially safe.

In this study, the handles of two dental mirrors were used to evaluate whether there was absence of implant mobility. Although this evaluation method is considered to have low sensitivity,<sup>28</sup> other evaluation methods, like the Periotest and resonance frequency analysis (RFA), have also shown poor quantitative information.<sup>29</sup> In addition, the RFA showed the same sensitivity as the manual test.<sup>30</sup>

In an extensive systematic review on reinforcement of anchorage during orthodontic treatment using implants and other surgical methods, Skeggs et al.<sup>1</sup> reported that evidence regarding the favorable outcomes of immediate orthodontic load in osseointegrated implants is reasonable, although they recommended further studies in adult human patients. The present RCT with 13 patients and 20 osseointegrated implants contributed to preliminary data about this issue in human subjects instead of animal or laboratory studies,<sup>2</sup> and it compared immediate vs delayed orthodontic and prosthetic load in single mandibular implants.

The present study found no difference in the success rate of implants immediately loaded with orthodontic forces and implants where the application of the orthodontic force was delayed after the recommended 4 months for osteointegration (91% vs 89%, respectively). Both clinical and radiographic assessments of successful implants in both groups revealed favorable outcomes. Therefore, the results of the present RCT confirm the observations reported in the systematic review by Skeggs and coworkers.<sup>1</sup> Nevertheless, the hazard of the occlusal force needs to be evaluated apart from the orthodontic force applied to the implants, and a follow-up study is

**Table 1.** Implant Survival: Results of the Immediate Load and Delayed Load Groups After a Minimum of 2 Years of Observation After Orthodontic Load

Group	Implant Site	Movement Type	Results	
Immediate load	1	47	Molar uprighting	Failure
	2	36	Dental arch aligning and leveling	Success
	3	46	Dental arch aligning and leveling	Success
	4	35	Molar intrusion and uprighting	Success
	5	36	Incisors intrusion plus dental arch aligning and leveling	Success
	6	35	Space closure plus dental arch aligning and leveling	Success
	7	36	Dental arch aligning and leveling	Success
	8	36	Space closure plus dental arch aligning and leveling	Success
	9	46	Molar uprighting plus dental arch aligning and leveling	Success
	10	36	Molar uprighting plus dental arch aligning and leveling	Success
	11	46	Molar uprighting plus dental arch aligning and leveling	Success
Delayed load	1	37	Dental arch aligning and leveling	Success
	2	46	Dental arch aligning and leveling	Failure
	3	45	Molar uprighting and mesial movement plus dental arch aligning and leveling	Success
	4	45	Space closure plus dental arch aligning and leveling	Success
	5	34	Mandibular incisors proclination plus space closure	Success
	6	46	Incisors retraction plus space closure	Success
	7	36	Molar uprighting	Success
	8	46	Molar uprighting plus dental arch aligning and leveling	Success
	9	36	Translation plus dental arch aligning and leveling	Success

needed using a large sample, according to a standardized magnitude of force.

Although the minimum follow-up time was 2 years, the sample was observed for a mean of 3.4 years (SD = 1.3) to validate the implants' stability for a longer period. All 18 implants that were successful at the first 6-month evaluation were still in perfect condition in terms of the aforementioned criteria.

Roberts et al.<sup>2</sup> reported the first observations about the use of immediate orthodontic load in osseointegrated implants. The success rate in that study was 0% within the four evaluated implants. In that study the implants were placed in rabbit femurs, so a comparison with the present study is not possible because the evaluation was performed in animals and not in humans. Moreover, the establishment of initial stability of implants of any magnitude was not determined, and this could have interfered with the results. Also, the comparison of the outcomes of the present study with those of previous investigations that used immediate orthodontic load in osseointegrated implants placed in human subjects is challenging because of the different methodologies used. The number of implants receiving immediate orthodontic load in the present study is greater than in previously reported studies,<sup>3,5</sup> and the present trial was conceived as a prospective randomized investigation. The utilization of implants not only for orthodontic anchorage but also as support for future prosthetic crowns represents another variable that distinguishes the present study from others that evaluated immediate orthodontic load. As a consequence, the treatment plan for each of the patients enrolled in the present study did not include implant

removal at the time the orthodontic treatment was accomplished.

Although the initial results from this study are encouraging, the long-term outcomes require further investigation with larger samples. The follow-up evaluation of the samples investigated here provides useful insights on the effects of continued orthodontic treatment, including immediately loaded implants. This result reinforces the findings of Chen et al.<sup>31</sup> They created finite element models of the human mandible and showed that typical orthodontic loads are several orders of magnitude lower than the peak occlusal loads of mastication. Thus, occlusal loading is much more likely to precipitate implant failure than a routine orthodontic load.

## CONCLUSIONS

- Of the 11 evaluated implants under immediate orthodontic load, 10 were successful after a minimum of 2 years of clinical and radiographic observation, resulting in a success rate of 91%.
- Of the nine implants that received orthodontic load after 4 months of healing, eight were successful, resulting in a success rate of 89%.
- The reduction in waiting time for application of orthodontic load may not negatively influence the success of osseointegrated implants bearing provisional crown restorations.

## REFERENCES

1. Skeggs RM, Benson PE, Dyer F. Reinforcement of anchorage during orthodontic brace treatment with implants



- or other surgical methods. *Cochrane Database Syst Rev*. 2007. Issue 3. Art. No.: CD005098. DOI:10.1002/14651858.CD005098.pub2.
2. Roberts WE, Smith RK, Zilberman Y, Mozsary PG, Smith RS. Osseous adaptation to continuous loading of rigid endosseous implants. *Am J Orthod*. 1984;86:95–111.
  3. Karaman AI, Basciftci FA, Polat O. Unilateral distal molar movement with an implant-supported distal jet appliance. *Angle Orthod*. 2002;72:167–174.
  4. Trisi P, Rebaudi A. Progressive bone adaptation of titanium implants during and after orthodontic load in humans. *Int J Periodontics Restorative Dent*. 2002;22:31–43.
  5. Trisi P, Rebaudi A. Peri-implant bone reaction to immediate, early, and delayed orthodontic loading in humans. *Int J Periodontics Restorative Dent*. 2005;25:317–329.
  6. Chiapasco M, Gatti C. Implant-retained mandibular overdentures with immediate loading: a 3- to 8-year prospective study on 328 implants. *Clin Oral Implants Res*. 2003;5:29–38.
  7. Hruska A, Borelli P, Bordanaro AC, Marzaduri E, Hruska KL. Immediate loading implants: a clinical report of 1301 implants. *J Oral Implantol*. 2002;28:200–209.
  8. Lorenzoni M, Pertl C, Zhang K, Wimmer G, Wegscheider WA. Immediate loading of single-tooth implants in the anterior maxilla. Preliminary results after one year. *Clin Oral Implants Res*. 2003;14:180–187.
  9. Calandriello R, Tomatis M, Vallone R, Rangert B, Gottlow J. Immediate occlusal loading of single lower molars using Brånemark System Wide-Platform TiUnite implants: an interim report of a prospective open-ended clinical multicenter study. *Clin Implant Dent Relat Res*. 2003;5(suppl 1):74–80.
  10. Shapiro PA, Kokich VG. Uses of implants in orthodontics. *Dent Clin North Am*. 1988;32:539–550.
  11. Nkenke E, Fenner M. Indications for immediate loading of implants and implant success. *Clin Oral Implants Res*. 2006;17(suppl 2):19–34.
  12. Carlos JP, Gittelsohn AM. Longitudinal studies of the natural history of caries II: a life-table studies of caries incidence in the permanent teeth. *Arch Oral Biol*. 1965;10:739–751.
  13. Wood WR, Greco GW, McFall WT. Tooth loss in patients with moderate periodontitis after treatment and long-term maintenance care. *J Periodontol*. 1989;60:516–520.
  14. Balleri P, Cozzolino A, Ghelli L, Momicchioli G, Varriale A. Stability measurements of osseointegrated implants using Osstell in partially edentulous jaws after one year of loading: a pilot study. *Clin Implant Dent Relat Res*. 2002;4:128–132.
  15. Finne K, Rompen E, Toljanic J. Clinical evaluation of a prospective multicenter study on 1-piece implants: part 1: marginal bone level evaluation after 1 year of follow-up. *Int J Oral Maxillofac Implants*. 2007;22:226–234.
  16. Jaffin RA, Berman CL. The excessive loss of Branemark fixtures in type IV bone: a 5-year analysis. *J Periodontol*. 1991;62:2–4.
  17. Glauser R, Réé A, Lundgren A, Gottlow J, Hämmerle CH, Schärer P. Immediate occlusal loading of Branemark implants applied in various jawbone regions: a prospective, 1-year clinical study. *Clin Implant Dent Relat Res*. 2001;3:204–213.
  18. Weng D, Jacobson Z, Tarnow D, Hürzeler MB, Faehn O, Sanavi F, Barkvoll P, Stach RM. A prospective multicenter clinical trial of 3i machined-surface implants: results after 6 years of follow-up. *Int J Oral Maxillofac Implants*. 2003;18:417–423.
  19. Gray JB, Steen ME, King GJ, Clark AE. Studies on the efficacy of implants as orthodontic anchorage. *Am J Orthod*. 1983;83:311–317.
  20. Linder-Aronson S, Nordenram A, Anneroth G. Titanium implant anchorage in orthodontic treatment: an experimental investigation in monkeys. *Eur J Orthod*. 1990;12:414–419.
  21. Wehrbein H, Diedrich P. Endosseous titanium implants during and after orthodontic—an experimental study in the dog. *Clin Oral Implants Res*. 1993;4:76–82.
  22. Southard TE, Buckley MJ, Spivey JD, Krizan KE, Casco JS. Intrusion anchorage potential of teeth versus rigid endosseous implants: a clinical and radiographic evaluation. *Am J Orthod Dentofacial Orthop*. 1995;107:115–120.
  23. Drago CJ. Use of osseointegrated implants in adult orthodontic treatment: a clinical report. *J Prosthet Dent*. 1999;82:504–509.
  24. Majzoub Z, Finotti M, Miotti F, Giardino R, Aldini NN, Cordioli G. Bone response to orthodontic loading of endosseous implants in the rabbit calvaria: early continuous distalizing forces. *Eur J Orthod*. 1999;21:223–230.
  25. Saito S, Sugimoto N, Morohashi T, et al. Endosseous titanium implants as anchors for mesiodistal tooth movement in beagle dog. *Am J Orthod Dentofacial Orthop*. 2000;118:601–607.
  26. Re S, Cardaropoli D, Corrente G, Abundo R. Bodily tooth movement through the maxillary sinus with implant anchorage for single tooth replacement. *Clin Orthod Res*. 2001;4:177–181.
  27. Aldikaçti M, Açıkgöz G, Türk T, Trisi P. Long-term evaluation of sandblasted and acid-etched implants used as orthodontic anchors in dogs. *Am J Orthod Dentofacial Orthop*. 2004;125:139–147.
  28. Romeo E, Chiapasco M, Lazza A, Casentini P, Ghisolfi M, Iorio M, Vogel G. Implant-retained mandibular overdentures with ITI implants. *Clin Oral Implants Res*. 2002;13:495–501.
  29. Cehreli MC, Akkocaoglu M, Comert A, Tekdemir I, Akca K. Human ex vivo bone tissue strains around natural teeth vs. immediate oral implants. *Clin Oral Implants Res*. 2005;16:540–548.
  30. Meredith N, Shagaldi F, Alleyne D, Sennerby L, Cawley P. The application of resonance frequency measurements to study the stability of titanium implants during healing in the rabbit tibia. *Clin Oral Implants Res*. 1997;8:234–243.
  31. Chen J, Chen K, Garetto L, Roberts WE. Mechanical response to functional and therapeutic loading of a retromolar endosseous implant used for orthodontic anchorage to mesially translate mandibular molars. *Implant Dent*. 1995;4:246–258.