

## Cystic teratoma of the parotid gland: A case report

Hong-Sheng Liu, Qiao-Ying Zhang, Jia-Feng Duan, Gang Li, Jia Zhang, Peng-Feng Sun

**Specialty type:** Oncology

**Provenance and peer review:**

Unsolicited article; Externally peer reviewed.

**Peer-review model:** Single blind

**Peer-review report's scientific quality classification**

Grade A (Excellent): A

Grade B (Very good): B

Grade C (Good): C

Grade D (Fair): D

Grade E (Poor): 0

**P-Reviewer:** Ankrah AO, Ata F, Boscarelli A, Malekzadegan A

**Received:** October 15, 2021

**Peer-review started:** October 15, 2021

**First decision:** November 17, 2021

**Revised:** December 1, 2021

**Accepted:** February 10, 2022

**Article in press:** February 10, 2022

**Published online:** March 16, 2022



**Hong-Sheng Liu, Qiao-Ying Zhang, Peng-Feng Sun**, Department of Radiology, Xi'an Central Hospital Affiliated to Xi'an Jiaotong University, Xi'an 710003, Shaanxi Province, China

**Jia-Feng Duan, Gang Li**, Department of Head & Neck Oncology Surgery, the Affiliated Stomatological Hospital of Medical School, Xi'an Jiaotong University, Xi'an 710003, Shaanxi Province, China

**Jia Zhang**, Department of Pathology, the Affiliated Stomatological Hospital of Medical School, Xi'an Jiaotong University, Xi'an 710003, Shaanxi Province, China

**Corresponding author:** Hong-Sheng Liu, MM, Deputy Director, Department of Radiology, Xi'an Central Hospital Affiliated to Xi'an Jiaotong University, Xi'an 710003, Shaanxi Province, China. [lhs841209@163.com](mailto:lhs841209@163.com)

### Abstract

#### BACKGROUND

Teratoma is a common tumor, but rarely occurs in the parotid region. Only nine cases have been reported in the current literature. Although it is generally detected in infancy or childhood, it is commonly asymptomatic. Computed tomography (CT) and magnetic resonance imaging (MRI) have important roles in the diagnosis of teratoma.

#### CASE SUMMARY

A 36-year-old man developed a lump located below the left auricular lobule 3 years ago. Physical examination revealed a nearly-circular tumor in the left parotid gland region with a defined border, firm texture, and significant movement. Calcification, fat, keratinized substances, and typical fat-liquid levels was observed on CT and MRI. A diagnosis of cystic teratoma of the parotid gland was established preoperatively and confirmed by postoperative pathology. Following surgery, the patient developed temporary facial paralysis. There was no recurrence of teratoma during the 15-mo follow-up period.

#### CONCLUSION

When an asymptomatic mass in the parotid region is identified, parotid gland teratoma should be included in the differential diagnosis. Imaging examinations are helpful in the diagnosis.

**Key Words:** Teratoma; Parotid gland cyst; Literature review; Computed tomography; Magnetic resonance imaging; Case report

**Core Tip:** We report an unusual case of teratoma in the parotid gland and review the related literature. The clinical characteristics and imaging features are described. Sufficient knowledge on teratoma, especially the computed tomography and magnetic resonance imaging characteristics, is essential for correct diagnosis and treatment.

**Citation:** Liu HS, Zhang QY, Duan JF, Li G, Zhang J, Sun PF. Cystic teratoma of the parotid gland: A case report. *World J Clin Cases* 2022; 10(8): 2622-2628

**URL:** <https://www.wjgnet.com/2307-8960/full/v10/i8/2622.htm>

**DOI:** <https://dx.doi.org/10.12998/wjcc.v10.i8.2622>

## INTRODUCTION

Teratoma is a kind of tumor that develops from germ cells and is most usually found in the coccyx, ovaries, and testicles. Teratoma of the parotid gland, on the other hand, is uncommon. Shadid *et al*[1] reported the first incidence of teratoma in the parotid gland in 1975. Most parotid gland teratomas develop slowly and have clinical characteristics comparable to other benign parotid gland tumors. We report an unusual case of a giant cystic teratoma, which was located in the deep lobe of the left parotid gland extending into the parapharyngeal space. The diagnosis was made preoperatively by computed tomography (CT) and magnetic resonance imaging (MRI) and was further confirmed by postoperative pathology. The clinical and imaging findings are described. In order to further understand teratoma of the parotid gland, we also review the current literature, hoping to provide a basis for preoperative imaging diagnosis and differential diagnosis, and provide a reliable reference for clinical treatment planning.

## CASE PRESENTATION

### Chief complaints

A 36-year-old man developed a lump that was accidentally found below the left auricular lobule 3 years ago.

### History of present illness

There was no sign of redness, swelling, suppuration, pain, or rupture. The patient had no fever or weight loss during this period. Ultrasonography suggested a cystic lesion of the parotid gland, while CT examination indicated a lipoma at a local hospital. The patient refused tumor excision recommended by the local hospital as the growth was not obvious. However, the lump had grown progressively over the last 6 mo and he occasionally experienced facial discomfort.

### History of past illness

The patient denied other medical history.

### Personal and family history

The patient denied any history of personal or familial diseases.

### Physical examination

A nearly-circular tumor with a clear boundary, hard texture, and high mobility was observed in the left parotid gland area. The temperature and color of the surface skin were normal. Facial nerve function was not weakened. No enlarged cervical lymph nodes were found.

### Laboratory examinations

No other abnormalities were found on laboratory examinations.

### Imaging examinations

A tumor measuring approximately 3.0 cm x 2.8 cm x 2.9 cm was observed in the deep lobe of the left parotid gland on CT. The tumor was well-bounded and cystic. It comprised variable densities of substances, including a substantial amount of fat and a tiny amount of soft tissue-like parts that were

perhaps keratinized. The medial part of the cyst wall was eggshell-like and extended into the parapharyngeal space (Figure 1). The mass on plain and enhanced MRI appeared as two "gourd"-like independent lesions, showing short T1 and long T2 signals, combined with medium T1 and T2 signals and line-like short T2 separation. In the fat saturation sequence, the mass had a complete capsule and a low signal. This was accompanied by lipid levels, which were not significantly enhanced (Figure 2A-C).

---

## FINAL DIAGNOSIS

---

The preoperative imaging features suggested a benign lesion, which was further diagnosed as a teratoma of the parotid gland. And it was confirmed by the postoperative pathology.

---

## TREATMENT

---

The patient underwent tumor resection and facial nerve decompression. The tumor was located in the deep lobe of the parotid gland. The cystic wall of the tumor was thick and tough and it was filled with yellow fat-like keratinized substances. As the cyst was very large, some of the contents were extracted. The upper part of the tumor was tightly linked to the cartilage of the external auditory canal. The medial portion of tumor expanded into the deep of styloid process and the lateral skull base. To protect the facial nerve from pressure caused by the tumor, the trunk of the facial nerve was discovered at the root of the mastoid process.

The tumor was completely removed after separation from the external auditory canal, facial nerve, and adjunct tissues. Neither the external auditory canal nor the facial nerve trunk was damaged. The tumor was then sent for pathological examination. In general, the tumor was comprised of sac liquid, and the thickness of the cystic wall was approximately 0.1 mm. The cyst was bordered with stratified squamous epithelium, superficial keratosis, and sebaceous gland cells under the microscope. The fibrous cyst wall contained sebaceous gland cells, cartilage, and adipose tissue. A small amount of keratinous material was found in the cyst cavity. There was no cellular atypia seen, and the surrounding parotid tissues were normal.

---

## OUTCOME AND FOLLOW-UP

---

The ultimate diagnosis was a mature parotid cystic teratoma (Figure 3A and B). The patient complained of moderate facial paralysis postoperatively which recovered well within 4 mo. There was no recurrence of the teratoma during the 15-mo follow-up period.

---

## DISCUSSION

---

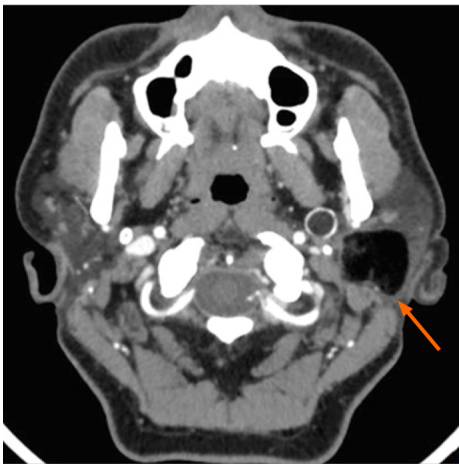
Teratoma is a common germ cell tumor that most commonly affects the gonads. It also presents in extragonadal sites, including the sacrococcygeal, retroperitoneal, mediastinal, and pineal regions. In addition, 3% to 5% of teratomas are located in the head and neck[2,3]. However, it rarely occurs in the parotid gland. By reviewing the relevant literature, Only nine individuals with parotid gland teratoma were reported globally between 1975 and 2019 (Table 1)[1,4-11]. Although we made substantial efforts, we failed to access the detailed information of patients 2 and 6. Finally, only eight cases (including the present case) of teratoma in the parotid gland with complete information were analyzed.

Teratomas occur more frequently in females[12]. Approximately 90% of teratomas of the head and neck develop during children or infancy[13], while few develop in adulthood. Of the eight patients, six were female (75.0%), and two were male (25.0%), with a ratio of 3:1. The mean age was 22.3 years (range, 9-36 years). The patient in this case was a 36-year-old male, the oldest of these individuals with parotid gland teratoma to date. All of the individuals had unilateral lesions, with four (50.0%) on the left and four (50.0%) on the right sides. In this case, the lesion was found in the deep lobe of the parotid gland and extended into the parapharyngeal region. However, the superficial lobe of the parotid gland was involved in most cases and extended into the deep lobe in only one case. The maximum diameter of the lesions ranged from 1.0 cm to 3.2 cm. Onset of the lesion ranged from 2 wk to 4 years, with an average of 11 mo. All patients visited the hospital with a painless mass and did not have symptoms such as restricted mouth opening, hearing impairment, or facial nerve paralysis.

Teratomas have the potential to differentiate into somatic cells. According to Batsakis *et al*[14], most teratomas involve ectoderm, mesoderm, and endoderm components and may differentiate into skin, nerve, bone, and fat tissues. In addition, Teratomas are also either cystic (containing fluids, sebum debris, hair, and fat) or solid (including more complicated tissues). They consist of mature and

**Table 1** Information of patients with teratoma in the parotid gland

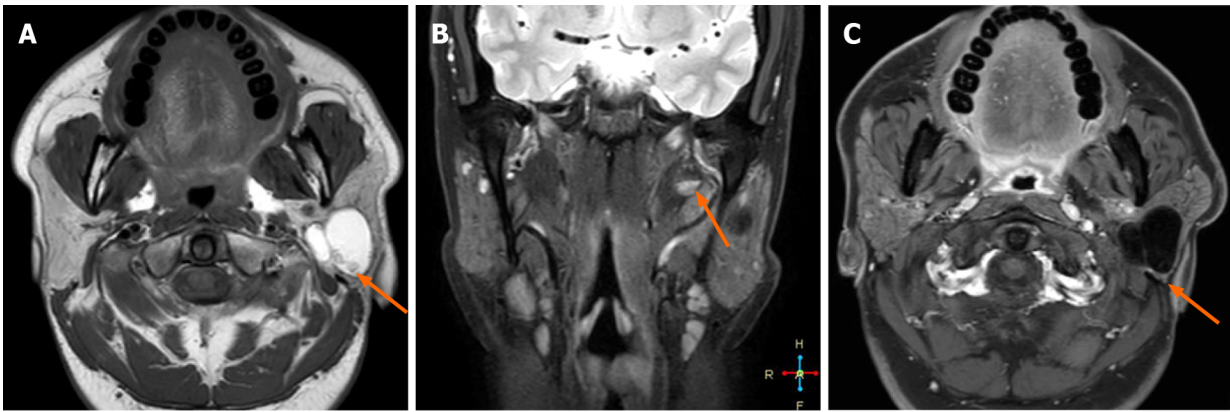Ref.	Gender	Age (year)	Side/site	Tumor	Preoperative imaging finding	Operation	Postoperative complication	Follow-up/recurrence
				Size (cm)				
Shadid EA <i>et al</i> [1], 1975	Female	24	Right, superficial lobe and involving the deep lobe	1.5	Cystic	Tumor resection, superficial lobectomy	NA	NA
Ayudhya NS <i>et al</i> [4], 1991	Female	35	Left	NA	NA	NA	NA	NA
Pirodda A <i>et al</i> [5], 2001	Female	18	Left, posteroinferior of the superficial lobe	1	Cystic	Parotidectomy	None	None
Wang G D <i>et al</i> [6], 2003	Female	21	Right, superficial lobe	3.0 × 2.0	NA	Tumor resection	NA	NA
Yang D R <i>et al</i> [7], 2004	Female	26	Right,  Superficial lobe, recurrent	2.0 × 1.5	Cystic and fat	Tumor resection, parotidectomy	NA	NA
Oudidi A <i>et al</i> [8], 2007	NA	NA	NA	NA	NA	NA	NA	NA
Ohta M <i>et al</i> [9], 2009	Female	17	Left, superficial lobe	3	Cystic and fat	Parotidectomy	NA	6 mo, none
Lenan SHAO <i>et al</i> [10], 2009	Male	28	Right, anterior of the superficial lobe	2	Cystic	Tumor resection, parotidectomy	None	2 years, none
Yin RJ <i>et al</i> [11], 2017	Female	9	Left, inferior of the superficial lobe	3.0 × 2.4 × 3.2	Cystic	Parotidectomy	NA	NA
This report	Male	36	Left, deep lobe, extending into the parapharyngeal space	3.0 × 2.8 × 2.9	Cystic, fat and calcification	Tumor resection, partial parotidectomy	Moderate facial paralysis, recovered within 4 mo	15 mo  None



DOI: 10.12998/wjcc.v10.i8.2622 Copyright © The Author(s) 2022.

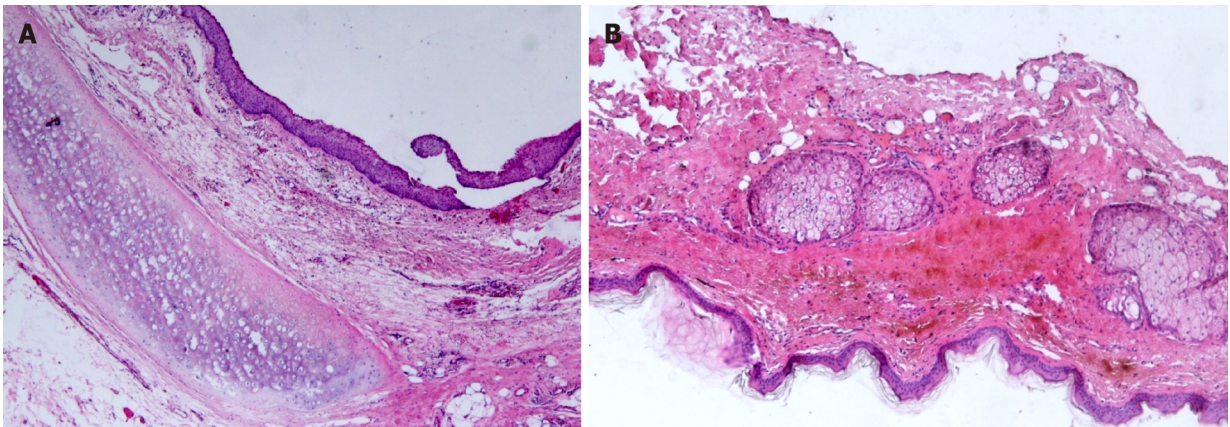
**Figure 1** Axial-view contrast-enhanced computed tomography image. The mass was located in the deep lobe of the left parotid gland. The medial part extended to the parapharyngeal space. Eggshell-like calcification was observed in the cyst wall. The cyst components were in different density, including a large amount of fat and a small number of keratinized substances.

immature components or both. This helps differentiate teratomas from epidermoid cysts and dermoid cysts. The majority of benign teratomas are cystic and are often referred to as mature cystic teratomas. Ohta *et al*[9] reported that a mature cystic teratoma might be identified by the presence of skin appendages and cartilage tissues in the cyst wall. In this case, the cyst wall featured a stratified squamous epithelial lining, sebaceous gland cells, hyaline cartilage, and well-differentiated fatty tissues, indicating that it was a mature cystic teratoma. The clinical manifestations of teratoma are usually not typical and the diagnosis mainly depends on imaging examinations, including ultrasonography, CT,



DOI: 10.12998/wjcc.v10.i8.2622 Copyright © The Author(s) 2022.

**Figure 2 Magnetic resonance imaging images.** A: T1WI axial view; B: Coronal view of fat-saturated sequence in T2WI; C: T1WI enhancement. The lesion had a complete capsule and presented as short T1 and long T2 signals, combined with medium T1 and T2 signals and line-like short T2 separation. It had a complete capsule showing low signal in the fat saturation sequence. It was accompanied by fat-liquid level, which was not significantly enhanced on enhanced magnetic resonance imaging.



DOI: 10.12998/wjcc.v10.i8.2622 Copyright © The Author(s) 2022.

**Figure 3 Histopathological analysis of the teratoma.** A and B: The cyst wall was lined with a stratified squamous epithelium. Hyaline cartilage, sebaceous glands, and fat tissue were seen in the fibrous capsule wall (HE × 50).

and MRI. Ultrasonography commonly shows heterogeneous hyperechoic signals containing multiple components and with an uneven echo. However, it has limitations regarding teratomas located deep in the tissues. CT and MRI are essential for preoperative diagnosis.

On CT, calcification and fat elements are visualized in mature teratomas and the appearance of hypoattenuating fat within the cyst and calcifications in the cyst wall are strongly predictive of teratoma [15]. In addition, the presence of teeth, tufts of hair, and a fat-fluid level is also helpful in the diagnosis of teratoma. MRI allows better observation of soft tissues and is specific for fat signals. As fat contains more hydrogen protons, it shows a high signal on T1WI and T2WI and a low signal in the MRI sequence of fat suppression [16]. This helps to enhance tissue contrast and decrease artifacts, which is important for teratoma detection. The use of CT and MRI can offer a qualitative diagnosis as well as a good view of the lesion's location and scope, as well as its connection to nearby tissues. Calcification, fat, keratinized substances, and the typical fat-liquid levels were observed on CT and MRI in the present study. The lesion looked like a gourd on CT and MRI because it protruded into the parapharyngeal space. Lipoma, dermoid cyst, epidermoid cyst, branchial cleft cyst, vascular tumor, and pleomorphic adenoma must all be separated from teratoma in the parotid gland with atypical imaging features.

Similar to other benign tumors in the parotid gland, surgery is preferred for parotid teratomas. Surgery usually involves partial parotidectomy or total parotidectomy with facial nerve preservation. The extent of parotid resection depends on the location and size of the lesion [10,17]. Studies on postoperative complications are rare, and there was no mention of postoperative complications among the patients observed in previous studies. In the present study, the superficial lobe of the parotid gland was not involved and it was retained during surgery. The patient suffered from temporary moderate facial paralysis (he was not able to completely close his left eyelid) after decompression of the facial nerve. This recovered well postoperatively within 4 mo. Teratoma recurrence in the parotid gland is

exceedingly rare. The teratoma recurred *in situ* in one case, according to the existing literature[7]. Incomplete resection of the tumor might lead to recurrence, which should be avoided. Our patient showed no sign of recurrence during the 15-mo follow-up period and is still being followed.

---

## CONCLUSION

In summary, teratoma located in the parotid gland is extremely rare. The differential diagnosis of fat in the parotid gland tumor should prompt consideration of the possibility of teratoma. The presence of calcification, fat, and a fat-liquid level on preoperative CT and MRI scans may aid in the diagnosis and localization of a teratoma in the parotid gland. However, histopathological examination is required to confirm the final diagnosis. Surgical removal of a teratoma of the parotid gland is the recommended and successful treatment, and facial nerve function should be preserved. Patients with a parotid teratoma have a fair prognosis, but they should be monitored closely.

---

## ACKNOWLEDGEMENTS

We are thankful to the patient and his family for their permission to publish this case report.

---

## FOOTNOTES

**Author contributions:** Liu HS and Zhang QY carried out the study, participated in collecting the data, and drafted the manuscript; Zhang J and Sun PF performed the data collection and participated in study design; Li G and Duan JF participated in data interpretation and manuscript revision; all authors have read and approved the final manuscript.

**Informed consent statement:** Written informed consent was obtained from the patient for publication of this case report.

**Conflict-of-interest statement:** The authors have no conflicts of interest to disclose.

**CARE Checklist (2016) statement:** The authors have read the CARE Checklist (2016). The manuscript was prepared and revised according to the CARE Checklist (2016).

**Open-Access:** This article is an open-access article that was selected by an in-house editor and fully peer-reviewed by external reviewers. It is distributed in accordance with the Creative Commons Attribution NonCommercial (CC BY-NC 4.0) license, which permits others to distribute, remix, adapt, build upon this work non-commercially, and license their derivative works on different terms, provided the original work is properly cited and the use is non-commercial. See: <https://creativecommons.org/licenses/by-nc/4.0/>

**Country/Territory of origin:** China

**ORCID number:** Hong-Sheng Liu 0000-0002-2476-7084; Qiao-Ying Zhang 0000-0003-1076-9561; Jia-Feng Duan 0000-0003-1803-3364; Gang Li 0000-0002-6166-9512; Jia Zhang 0000-0003-2052-2036; Peng-Feng Sun 0000-0001-5345-7731.

**S-Editor:** Ma YJ

**L-Editor:** Wang TQ

**P-Editor:** Ma YJ

---

## REFERENCES

- 1 **Shadid EA**, Engeron O, Glass RT. Benign teratoid tumor of the parotid; Case report. *Plast Reconstr Surg* 1975; **55**: 363-365 [PMID: 1118495]
- 2 **Bergé SJ**, von Lindern JJ, Appel T, Braumann B, Niederhagen B. Diagnosis and management of cervical teratomas. *Br J Oral Maxillofac Surg* 2004; 41-45 [DOI: 10.1016/s0266-4356(03)00174-8]
- 3 **Stricker TP**, Kumar V, Neoplasia In, Abbas AK, Fausto N, Ster JC. Robbins and Cotran pathologic basis of disease. 8th ed. Philadelphia (PA): Elsevier Saunders. 2010 [DOI: 10.1016/b978-1-4377-0792-2.50012-2]
- 4 **Ayudhya NS**, Parichatikanond P, Chinda K. Benign cystic teratoma of the parotid salivary gland: report of the first case in Thailand. *J Med Assoc Thai* 1991; **74**: 478-480 [PMID: 1797960]
- 5 **Pirodda A**, Ferri GG, Truzzi M, Cavicchi O. Benign cystic teratoma of the parotid gland. *Otolaryngol Head Neck Surg* 2001; **125**: 429-430 [PMID: 11593192 DOI: 10.1067/mhn.2001.117370]
- 6 **Wang GD**, He Y. Teratoma of the parotid gland: a case report. *Bengbu Yixueyuan Xuebao* 28: 470

- 7 **Yang DR**, Xu HM, Long QX. Mature cystic teratoma of the parotid gland: a case report. *Zhenduan Binglixue Zazhi* 2004; **11**: 237
- 8 **Ouididi A**, Alami MN. [Teratoma of the parotid gland: a case report]. *Rev Laryngol Otol Rhinol (Bord)* 2007; **128**: 125-127 [PMID: [17633683](#)]
- 9 **Ohta M**, Imamura Y, Mori M, Maegawa H, Kojima A, Fujieda S. Benign cystic teratoma of the parotid gland: a case report. *Acta Cytol* 2009; **53**: 427-430 [PMID: [19697729](#) DOI: [10.1159/000325345](#)]
- 10 **Shao L**, Guan H, Wan J. Mature cystic teratoma of the parotid gland: a case report and review of the literature. *Frontiers of Med* 2009; **3**: 503-506 [DOI: [10.1007/s11684-009-0076-8](#)]
- 11 **Yin RJ**, Zhao W, XJ S. A case of cystic teratoma in the parotid gland diagnosed by MRI. *J Clin Radiol* 2017; **36**: 446 [DOI: [10.21203/rs.3.rs-379849/v1](#)]
- 12 **Li H**, Zhao T, Wei Q, Yuan H, Cao D, Shen P, Liu L, Zeng H, Chen N. Laparoscopic resection of a huge mature cystic teratoma of the right adrenal gland through retroperitoneal approach: a case report and literature review. *World J Surg Oncol* 2015; **13**: 318 [PMID: [26582506](#) DOI: [10.1186/s12957-015-0734-z](#)]
- 13 **Jordan RB**, Gauderer MW. Cervical teratomas: an analysis. Literature review and proposed classification. *J Pediatr Surg* 1988; **23**: 583-591 [PMID: [3047360](#) DOI: [10.1016/s0022-3468\(88\)80373-7](#)]
- 14 **Batsakis JG**. Teratomas of the head and neck. In: Tumors of the head and neck: clinical and pathological considerations. 2nd ed. Baltimore: Williams & Wilkins. 1979: 226-232 [DOI: [10.1002/hed.2890030117](#)]
- 15 **Yang DM**, Jung DH, Kim H, Kang JH, Kim SH, Kim JH, Hwang HY. Retroperitoneal cystic masses: CT, clinical, and pathologic findings and literature review. *Radiographics* 2004; **24**: 1353-1365 [PMID: [15371613](#) DOI: [10.1148/rg.245045017](#)]
- 16 **Chai J**, Jin EH. Recent status on MRI chemical shift imaging in quantitative analysis of ectopic fat deposition in vivo. *J Clin Exp Med* 2013; **12**: 2027-2230 [DOI: [10.1016/j.mri.2013.02.002](#)]
- 17 **Tapper D**, Lack EE. Teratomas in infancy and childhood. A 54-year experience at the Children's Hospital Medical Center. *Ann Surg* 1983; **198**: 398-410 [PMID: [6684416](#) DOI: [10.1097/00000658-198309000-00016](#)]



Published by **Baishideng Publishing Group Inc**  
7041 Koll Center Parkway, Suite 160, Pleasanton, CA 94566, USA

**Telephone:** +1-925-3991568

**E-mail:** [bpgoffice@wjgnet.com](mailto:bpgoffice@wjgnet.com)

**Help Desk:** <https://www.f6publishing.com/helpdesk>

<https://www.wjgnet.com>

