

VEXAS syndrome in a female patient with constitutional 45,X (Turner syndrome)

VEXAS (vacuoles, E1 enzyme, X-linked, autoinflammatory, somatic) syndrome is a newly-defined autoinflammatory disorder that arises from somatic mutations affecting *UBA1*, a major E1 enzyme that initiates ubiquitylation and is important for the maturation of autophagic vacuoles.^{1,2} Specifically, these mutations occur in hematopoietic stem cells and in the erythroid and granulocyte precursors in the bone marrow.¹ This results in an autoinflammatory syndrome characterized by recurrent fevers, cytopenias, chondritis, vasculitis, pulmonary inflammation, and neutrophilic dermatoses. This inflammatory syndrome is typically treatment-refractory, with patients being persistently steroid-dependent, and is often fatal: 40% of patients were deceased at the time of inclusion in the original study.¹ There is also a strong association with hematologic malignancy. In the original series, 24% of patients developed a low-grade myelodysplastic syndrome (MDS) while 20% had multiple myeloma or a monoclonal gammopathy.¹ Patients who progress to MDS tend to have more prominent thrombocytopenia and neutropenia, and one of the most commonly co-occurring somatic mutations appears to be in *DNMT3A*.³⁻⁵ Interestingly, the bone marrow morphology demonstrates a characteristic cytoplasmic vacuolation restricted to the erythroid and granulocyte precursors.⁶

The *UBA1* gene lies on the X-chromosome, making VEXAS an X-linked syndrome. Consistent with this, the majority of reported cases have occurred in biological males. The presence of a second *UBA1* allele in females is thought to mitigate the impact of the presence of the mutant allele should it arise.¹ Part of the reason the second allele is protective against VEXAS in women is related to the fact that *UBA1* does not undergo X-inactivation; in contrast, other disease-causing mutations in genes on the X-chromosome that do undergo inactivation (e.g., *PIGA* mutations in Paroxysmal Nocturnal Haemoglobinuria) manifest disease at similar rates in males and females.^{7,8} However, VEXAS has been described in a small number of women (N=4).⁹⁻¹¹ These women were observed to have acquired monosomy X due to age-related mosaicism in the X chromosome.¹² In contrast to acquired mosaicism of the X chromosome, Turner syndrome refers to a constitutional loss of one X chromosome (i.e., 45,X karyotype). This occurs in between 1 in 2,000 to 1 in 2,500 live female births and

results in short stature, skeletal abnormalities, primary ovarian failure, and several other end-organ complications.¹³ As with acquired X chromosome mosaicism, constitutional loss of the X chromosome may also predispose to female VEXAS. In this case report, we present the first case of female VEXAS syndrome diagnosed in a patient with constitutional 45,X (Turner syndrome).

A 67 year-old female was referred with a diagnosis of myelodysplastic syndrome with multilineage dysplasia (MDS-MLD), originally low-risk by IPSS (score 0) and very low-risk by IPSS-R (score 1), which was diagnosed 36 months prior. Peripheral blood counts at relevant timepoints are demonstrated in Table 1. Her bone marrow cytogenetics demonstrated 45,X (20/20) and a targeted capture panel demonstrated variants of uncertain significance in *DNMT3A* (VAF 28.0%) and *SMC3* (48.0%). The patient's medical history was notable for relapsing polychondritis, diagnosed five years previous, and constitutional 45,X (Turner syndrome) that was diagnosed in her teenage years after a failure of pubertal development. Her relapsing polychondritis had presented with a migratory inflammatory arthritis and auricular inflammation. This was treated initially with prednisone; she had trialed multiple steroid-sparing agents (methotrexate, azathioprine, cyclosporine) but was unable to wean from steroids. She had remained dependent on a low dose of prednisone (10mg) from the time of her original diagnosis; her disease had remained stable with a combination of steroids and etanercept. In addition, she had recently been found to have a monoclonal gammopathy of unclear significance (MGUS), with a very faint (unquantifiable) IgG lambda monoclonal band on immunofixation.

Her low-risk MDS was observed until she developed transfusion dependence 24-months after her initial diagnosis. This was managed with erythropoietin injections, which reduced her transfusion requirements for eight months' time. After failing erythropoietin, a repeat bone marrow biopsy was performed (32 months); this marrow was hypercellular (95%) and demonstrated more prominent trilineage dysplasia than her previous diagnostic marrow. Interestingly, her bone marrow morphology demonstrated multiple vacuolated erythroid and granulocytic precursor cells (Figure 1A). The number of blast cells was unchanged (2% of total nucleated cells), hence her diagnosis was rendered as persistence of MDS-MLD. Her cytogenetics were unchanged (45,X [20/20]) (Figure 1B) and her targeted capture panel re-demonstrated variants

Table 1. Peripheral blood counts at relevant timepoints throughout the disease course of a female VEXAS patient with Myelodysplastic syndrome (MDS)

Parameter	MDS diagnosis	MDS progression	Transplant referral	On treatment (HMA)
Timepoint (months)	0	32	36	43
Hemoglobin (g/L)	107	101	92	188
Mean cell volume (fL)	109.1	101	99	100
Platelets (x10 ⁹ /L)	137	35	40	102
White blood cell (x10 ⁹ /L)	6.60	5.30	6.90	2.60
Neutrophils (x10 ⁹ /L)	5.60	3.98	5.10	1.50
Lymphocytes (x10 ⁹ /L)	0.80	1.06	0.90	1.00
Monocytes (x10 ⁹ /L)	0.10	0.05	0.30	0.10
Eosinophils (x10 ⁹ /L)	0.10	0.11	0.00	0.10
Basophils (x10 ⁹ /L)	0.00	0.00	0.10	0.00
BM blasts	1%	2%	NA	1%
Karyotype	45,X	45,X	NA	45,X

Abbreviations: VEXAS: vacuoles, E1 enzyme, X-linked, autoinflammatory, somatic; HMA: hypomethylating agent; BM: bone marrow.

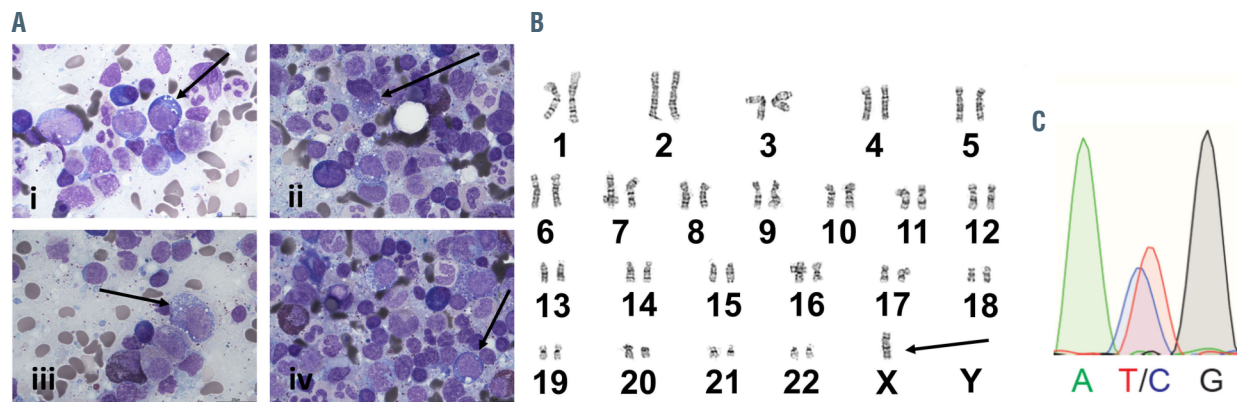


Figure 1. Representative diagnostic features of a female patient with constitutional 45,X and VEXAS syndrome (A) A diagnostic bone marrow aspirate was collected and stained with Giemsa-Wright. There is trilineage dysplasia, consistent with the known diagnosis of myelodysplastic syndrome with multilineage dysplasia. There is notable vacuolation of the erythroid and granulocytic precursors, indicated by the black arrows. (B) Karyotyping with G-banding demonstrated X monosomy, consistent with the patient's reported history of constitutional 45,X (Turner syndrome). No clonal evolution was identified. A single X-chromosome is indicated by the black arrow. (C) Sanger sequencing for the *UBA1* locus performed on peripheral blood demonstrated the presence of a somatic *UBA1* p.Met41Thr mutation (c.122T>C) with approximately equal allele frequency as the reference allele, confirming the diagnosis of VEXAS syndrome; the Sanger chromatogram is demonstrated.

of uncertain significance in *DNMT3A* (VAF 30.0%) and *SMC3* (VAF 43.8%). With the deterioration in her peripheral counts, her IPSS-R score was now intermediate-risk (score 3.5) and her IPSS score intermediate-1 (score 0.5).

Given the recently described association between low-risk MDS/MGUS, bone marrow vacuolation, and a steroid-dependent autoinflammatory syndrome resembling relapsing polychondritis (VEXAS syndrome) caused by somatic mutations in the X-linked E1 enzyme *UBA1*, further diagnostic testing was pursued by referral of this patient to the National Institutes of Health (NIH). Sanger sequencing was performed at the NIH; genomic DNA was prepared from peripheral blood using the Maxwell 16 Blood DNA purification kit (Promega). Coding exons of *UBA1* were sequenced using the BigDye Terminator v1.1 Cycle Sequencing Kit (Applied Biosystems), and sequencing data analyzed using Sequencher (Gene Codes) and 4Peaks (Mekentosj).

Sanger sequencing results were positive for the presence of a somatic *UBA1* p.Met41Thr mutation (c.122T>C) with approximately equal allele frequency as the reference allele, (Figure 1C) confirming the diagnosis of VEXAS given her X monosomy. With her transfusion dependence, the increase in IPSS-R score to intermediate, and the persistent steroid requirement due to VEXAS, it was recommended that the patient be initiated on hypomethylating agent therapy with 5-azacitidine. She tolerated 5-azacitidine well and achieved transfusion independence with an improvement in both hemoglobin and platelets (43 months). Human leukocyte antigen (HLA) typing was initiated for the patient and her siblings and an unrelated donor search activated. Given her relatively young age, a sibling-donor allogeneic hematopoietic stem cell transplant is planned as a definitive therapy for both her MDS and VEXAS syndrome.

Although VEXAS syndrome primarily affects males as an X-linked disease, it is important for the clinician to realize that there are several factors that can lead VEXAS (and other X-linked diseases) to manifest in females. Mosaicism of the X chromosome is an age-related phenomenon that primarily affects the inactivated X chromosome; it has been shown to occur in 0.11% of 50 year-old females, with this increasing to 0.45% of 75 year-olds.¹² This has been the most commonly reported reason

underlying a diagnosis of VEXAS in a female. In contrast, the underlying reason our patient was predisposed to developing VEXAS was the presence of a constitutional 45,X karyotype from birth, which was diagnosed in her teenage years after a failure of pubertal development. There are other mechanisms that can lead to the functional loss of one X chromosome, such as uniparental disomy and skewed X-inactivation; in the future we may see these reported as an underlying risk factor in female VEXAS patients.

While clinicians are increasingly aware of VEXAS syndrome as a diagnostic entity, it is still largely characterized as an X-linked disorder affecting only males. However, as our case demonstrates, it is important to be aware that VEXAS can affect females and further investigations should be pursued in the appropriate context for female patients. In our case, the diagnosis of Turner syndrome was established long before the development of her VEXAS syndrome. The underlying risk factor for female VEXAS may not always be obvious, however, as in patients with acquired X chromosome mosaicism. It is important to be alert for the presence of disorders that result in the inactivation of the X-chromosome when assessing female patients with a possible X-linked disorder, such as VEXAS syndrome.

Ryan J. Stubbins,^{1,2} Eric McGinnis,³ Bhupinder Johal,⁴ Luke YC Chen,² Lorena Wilson,⁵ Daniela Ospina Cardona⁵ and Thomas J. Nevill^{1,2}

¹Leukemia/BMT Program of BC, BC Cancer, Vancouver, BC, Canada; ²Division of Hematology, Department of Medicine, University of British Columbia, Vancouver, BC, Canada; ³Department of Pathology and Laboratory Medicine, University of British Columbia, Vancouver, BC, Canada; ⁴Department of Pathology, Kelowna General Hospital, Kelowna, BC, Canada and ⁵National Human Genome Research Institute, National Institutes of Health, Bethesda, MD, USA

Correspondence:

RYAN J. STUBBINS- ryan.stubbins1@bccancer.bc.ca

doi:10.3324/haematol.2021.280238

Received: October 25, 2021.

Accepted: December 3, 2021.

Pre-published: December 16, 2021.

Disclosures: no conflicts of interest to disclose.

Contributions: RJS and TJN conceived the study; RJS, EM, BJ, LW and DOC collected data and images; RJS wrote the manuscript. All authors read, critically assessed, and approved the final manuscript.

Acknowledgments: we thank Dr. David Beck and the National Institutes of Health for their collaboration and assistance with this manuscript.

Funding: RJS is supported by grants from the Leukaemia Lymphoma Society of Canada (20200LFC-439884), Canadian Institutes of Health Research, and the University of British Columbia Clinician Investigator Program.

Data-sharing statement: data is available, upon request, from the corresponding author.

Trial registration and ethics: informed consent was obtained from the patient for this case report.

References

1. Beck DB, Ferrada MA, Sikora KA, et al. Somatic mutations in UBA1 and severe adult-onset autoinflammatory disease. *N Engl J Med.* 2020;383(27):2628-2638.
2. Lenk SE, Dunn WA, Trausch JS, Ciechanover A, Schwartz AL. Ubiquitin-activating enzyme, E1, is associated with maturation of autophagic vacuoles. *J Cell Biol.* 1992;118(2):301-308.
3. Obiorah IE, Patel BA, Groarke EM, et al. Benign and malignant hematologic manifestations in patients with VEXAS syndrome due to somatic mutations in UBA1. *Blood Adv.* 2021;5(16):3203-3215.
4. Geogin-Lavialle S, Terrier B, Guedon AF, et al. Further characterization of clinical and laboratory features occurring in VEXAS syndrome in a large-scale analysis of multicenter case-series of 116 French patients. *Br J Dermatol.* October 10, 2021, <https://doi.org/10.1111/bjd.20805>, [Epub ahead of print].
5. van der Made CI, Potjewijd J, Hoogstins A, et al. Adult-onset autoinflammation caused by somatic mutations in UBA1: A Dutch case series of patients with VEXAS. *J Allergy Clin Immunol.* 2022;149(1):432-439.e4.
6. Dehghan N, Marcon KM, Sedlic T, Beck DB, Dutz JP, Chen LYC. Vacuoles, E1 enzyme, X-linked, autoinflammatory, somatic (VEXAS) syndrome: fevers, myalgia, arthralgia, auricular chondritis, and erythema nodosum. *Lancet.* 2021;398(10300):621.
7. Carrel L, Clemson CM, Dunn JM, et al. X inactivation analysis and DNA methylation studies of the ubiquitin activating enzyme E1 and PCTAIRE-1 genes in human and mouse. *Hum Mol Genet.* 1996;5(3):391-401.
8. Luzzatto L, Risitano AM, Notaro R. Mutant UBA1 and Severe Adult-Onset Autoinflammatory Disease. *N Engl J Med.* 2021;384(22):2164.
9. Arlet JB, Terrier B, Kosmider O. Mutant UBA1 and severe adult-onset autoinflammatory disease. *N Engl J Med.* 2021;384(22):2163.
10. Tsuchida N, Kunishita Y, Uchiyama Y, et al. Pathogenic UBA1 variants associated with VEXAS syndrome in Japanese patients with relapsing polychondritis. *Ann Rheum Dis.*, March 31, 2021, <https://doi.org/10.1136/annrheumdis-2021-220089> [Epub ahead of print].
11. Barba T, Jamilloux Y, Durel CA, et al. VEXAS syndrome in a woman. *Rheumatology (Oxford).* 2021;60(11):e402-e403.
12. Machiela MJ, Zhou W, Karlins E, et al. Female chromosome X mosaicism is age-related and preferentially affects the inactivated X chromosome. *Nat Commun.* 2016;7:11843.
13. Gravholt CH, Viuff MH, Brun S, Stochholm K, Andersen NH. Turner syndrome: mechanisms and management. *Nat Rev Endocrinol.* 2019;15(10):601-614.