

Retrospective analysis of outcomes and complications after Korus hemiarthroplasty in elderly patients with neck femur fractures

Pietro Maniscalco¹, Calogero Puma Pagliarello¹, Corrado Ciatti¹, Serena Gattoni¹, Valeria Burgio¹, Michele Cauteruccio¹, Giovanni Di Stefano¹, Fabrizio Quattrini¹, Giovanni Guerra², Federico Polidoro², Filippo Raggini², Alberto Belluati², Andrea Giolitti³, Fabrizio Rivera⁴

¹Department of Orthopedics and Traumatology, Guglielmo da Saliceto Hospital, Piacenza, Italy; ²Department of Orthopedics and Traumatology, Santa Maria delle Croci Hospital, Ravenna, Italy; ³Orthopedics and Traumatology Department, University of Turin, Torino, Italy; ⁴Orthopedics and Trauma Department, SS Annunziata Hospital, Savigliano (CN), Italy

Abstract. *Background:* Femoral neck fractures (FNF) is one of the most common traumatic events in elderly patients: the choice of an appropriate treatment is necessary to decrease the related mortality and to achieve the best possible outcomes. Nowadays, it is still debated whether or not to cement the stem in hemiarthroplasty and above all, which stem to use to best respect the integrity of the elderly bone. *Methods:* From January 2017 to December 2019, a bi-centric study utilizing prospectively collected databases of elderly patients with FNF treated with uncemented Korus stem hemiarthroplasty was performed. Patients were preoperatively classified according to ASA score. Patients' clinical and X-ray follow-up was at 1, 3, 6, 12 months. Harris Hip Score (HHS) was used for analyzed clinical improvement. On the X-rays, we analyzed iatrogenic fractures, osteolysis area and radiolucent lines in the stem region during follow up. *Results:* 233 patients were identified. Median follow-up was 12 months. Over time, 51 patients died (21.88%). Mean age was $89,56 \pm 6,25$. 75 patients had ASA score of 2 (32.3%), 102 patients a score of 3 (43.7%), 56 an ASA score of 4 (24,0%). The main Harris hip score was $68,66 \pm 8.53$ at 1 month of follow-up, $71,74 \pm 9.65$ after 3 months, $72,50 \pm 10.66$ at 6 months and $75,61 \pm 9.63$ at 12 months control. *Conclusions:* Hydroxyapatite coated stem with an accurate design guarantee early fixation, good clinical and radiographic results, low rate of re-intervention and mortality rate and a satisfying return to pre-injury activities. (www.actabiomedica.it)

Keywords: Femur fracture, hemiarthroplasty, Korus, Hydroxyapatite coating, uncemented stem

Introduction

Femur fracture is a traumatic event the Orthopaedic Surgeon daily deals with. In recent years, the progressive aging of the population has inevitably increased these types of traumas. After hip fracture, elderly people's quality life is often compromised and, in any case, it presents lower standard of living compared to non-fractured people of same age and gender (1). Furthermore, 30% of patients die during

the first year after trauma (2), showing percentages up to 50% at 5 years (3).

According to the accuracy of surgical techniques and the introduction of new implants, aims of orthopedic surgeons changed: if in the past it was fundamental to obtain a durable and free from complications implant over time as well as from pain, recently the restoration of normal joint function, normal muscle function and correct leg length were added to the main purposes of the procedure (4).

Lately, new design and materials have been developed to obtain more anatomical and functional implants (5).

Data suggests that implant longevity and mortality rate are both influenced by: primary press-fit stability, type of fixation and coating and morphological aspects of the components (6-8).

In our study we analyze clinical and radiographic outcomes of patients treated for intracapsular neck fractures using uncemented hemiarthroplasty with collarless stem and Hydroxyapatite coating.

Materials and Methods

In this three-Centers study, we analyze a group of 233 elderly patients treated for FNF with uncemented hemiarthroplasty (UCH) from January 2017 to December 2019 in Guglielmo da Saliceto Hospital, Piacenza, Italy, Santa Maria delle Croci, Hospital Ravenna, Italy and S.S. Annunziata, Hospital, Savigliano, Cuneo, Italy.

All surgical procedures were performed by the respective Heads of Prosthetic Surgery of the three Departments, leading experts in both total and partial hip arthroplasty (9). In 138 patients “Hardinge lateral approach” was used, with subject placed in supine position(10); instead the other 95 patients were operated using postero-lateral approach. A non-cemented collarless stem, with hydroxyapatite coating and 135° or 125° CCD angles (Korus®, Bioimpianti, Milan, Italy) was implanted in every patient (Figure 1).

We always applied subfascial surgical drain. After 48 hours the drain was removed and the patient began the rehabilitation process, maintaining the sitting position on the first day and on the following day starting with a walker-supported walking.

After surgery, X-ray of hip and pelvis was obtained. Patients' clinical and X-ray follow-up was at 1, 3, 6, 12 months and then for any complications or clinical problems. Radiographic evaluation was performed according Vresilovic criteria (11). Standard views were performed (antero-posterior and axial) in X-ray control. In particular, we analyzed iatrogenic fractures, osteolysis area and radiolucent lines in the stem region. Stem correct fitting, calcar resorption

and heterotopic ossification were also assessed. For the clinical evaluation we used the Harris Hip Score (HHS), which has a maximum value of 100. A score lower than 70 is considered poor outcome, 70–80 fair, 80–90 is good, and 90–100 is an excellent outcome.

Results

The cohort was composed by 233 patients, 149 females (63,9%) and 84 males (36,1%). Average age was 89,56 years \pm 6,25. Patients were classified in 5 groups according to the anaesthetic risk evaluation by using the ASA score (12). 75 patients had an ASA score of 2 (32,3%), 102 a score of 3 (43,7%), 56 a score of 4 (24,0%).

During the follow-up period 51 patients died (21,88%). Of these, 7 presented ASA 2 score (13.7% of dead, 9.3% of total ASA 2 patients); 23 presented ASA 3 score (45.1% of dead, 22.5% of total ASA 3 patients); 21 presented ASA 4 score (41.2% of dead, 37.5% of total ASA 4 patients);

The mean Harris Hip Score was 68,66 \pm 8.53 at 1 month follow-up, 71,74 \pm 9.65 after 3 months, 72,50 \pm 10.66 at 6 months and 75,61 \pm 9.63 at 12 months.

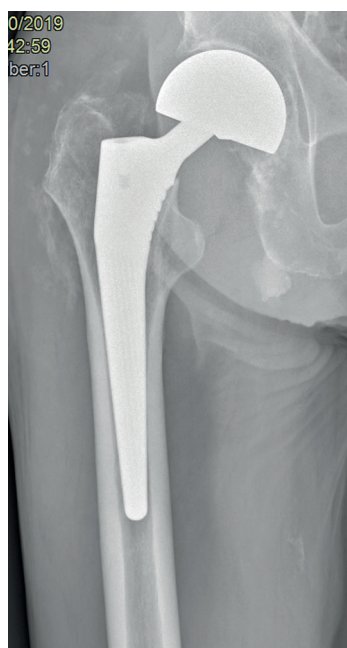


Figure 1. Korus® hemiarthroplasty, with non-cemented collarless stem and hydroxyapatite coating.

6 case of infections were reported (2,57%). 2 of them were treated with surgical washout and substitution of polyethylene components, 3 of them were treated with implant removal, antibiotic therapy and revision implant at infection-index normalization. The last one was treated with Gilderston procedure.

7 patients had prosthesis dislocation (3%), while 7 (3%) showed Trendelemburg limp.

We register 2 cases of periprosthetic fractures (1 A and 1 B1 according to Vancouver classification) treated with cerclage wire or plate and screws (Figure 2).

We noticed calcar resorption in 3 patients' X-ray controls (2,17%). A valgus stem alignment was found in 4 patients (2.89 %).

Discussion

Femur fracture in elderly people presents high risk of mortality at one-year follow-up. In a study conducted by Eiskjaer (13) the mortality rate after six months was 20% reaching value of 28% at 1 year follow-up. Many factors such as cardio-pulmonary comorbidities, serum creatinine level > 1.7 mg/100 ml,

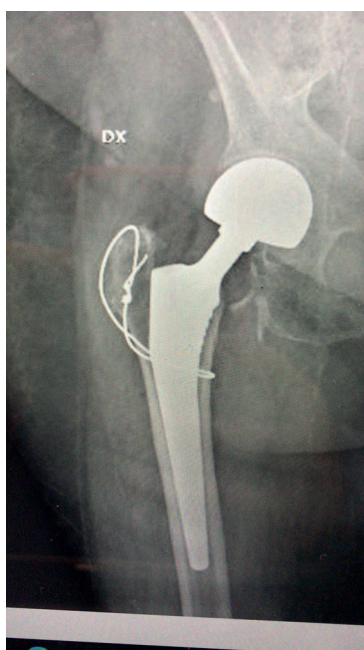

Figure 2. Periprosthetic fracture (A according to Vancouver classification) treated with cerclage wire.

duration of surgery and gender influence the survival rate of these patients. Kastanis showed how the ASA classification system is correlated with multiple factors, which can lead to the prediction of the postoperative status, and our data get along with this theory confirming that patients with higher ASA scores present an increased risk of mortality. In fact, 37.5% of ASA 4 patients died during follow-up, higher compared to patients with lower ASA score (mortality rate of 9.3% for ASA 2, 22.5% for ASA 3)(12).

The influence of fixation type in survival rate is very discussed in literature. Rivera underlines a higher mortality rate in patients treated with a cemented stem (6). Several possible complications are cited to explain this phenomenon: embolization of fat, bone marrow, and cement particles. Costan (14) shows that patients treated with cemented monoblock hemiarthroplasty had a 1.7 times higher day-1 mortality compared to uncemented monoblock components but higher mortality 1 week, 1 month, and 1 year after surgery.

For these reasons we decided to use an uncemented stem, with hydroxyapatite coating, tapered geometry for increased ROM, decreased risk of impingement and low trochanteric invasivity (Korus®, Bioimpianti).

The hydroxyapatite-coating (HA) could be an important factor for bone remodeling around the stem and for the subsequential early stabilization of the implant. According to Dorr, hydroxyapatite-stems have better stability, good clinical and radiographic results (10-15). The stems stabilized in 3 months due to the bioconductive capability of HA which provides earlier stability of the stem with more bone attachment. This type of stem had less risk of subsidence or migration than cemented stems. Other studies confirmed the higher degree and quality of osteointegration in the porous titanium alloy/HA type implants (16).

HA coating loss could be a long-term adverse event of HA coating- stems. According to Rivera, HA coating loss could have different causes: osteoclastic remodeling, delamination, chemical dissolution. It was demonstrated how in load area around the implant, osteolysis is followed by lamellar bone deposition that replace the coating and guarantees a long term osteointegration (6).

Geesink showed that there is no evidence of osteolysis associated with HA particles. Furthermore,

the study confirmed early pain relief and durable fixation of the stem, with an excellent periprosthetic bone quality and an increased bone mass (7).

Molli showed a higher rate of intraoperative complications with length-stems compared to shorter ones (8). In our experience we didn't register any case of intraoperative fractures: this could be explained by the lower trochanteric invasivity of Korus stems, which allows easier insertion and smaller incisions, leading to a lower risk of iatrogenic fractures.

Smaller incision lead in less risk of medium gluteus damaging, with a lower rate of limp and pain after surgery.

Our results showed a good return to daily activities for the majority of patients with only 7 cases of Trendelenburg limp.

Conclusions

Hydroxyapatite coated stem with less invasive design guarantee early fixation, good clinical / radiographical results and low rate of re-intervention.

Conflicts of interest: Each author declares that he or she has no commercial associations (e.g. consultancies, stock ownership, equity interest, patent/licensing arrangement etc.) that might pose a conflict of interest in connection with the submitted article

Ethical approval: All procedures performed in studies involving human participants were in accordance with the ethical standards of the institutional and/or national research committee and with the 1964 Helsinki declaration and its later amendments or comparable ethical standards.

References

1. Cranney AB, Coyle D, Hopman WM, Hum V, Power B, Tugwell PS. Prospective evaluation of preferences and quality of life in women with hip fractures. *J Rheumatol*. 2005 Dec;32(12):2393-9. PMID: 16331770.
2. Ehlinger M, Moser T, Adam P, et al. Early prediction of femoral head avascular necrosis following neck fracture. *Orthop Traumatol Surg Res*. 2011 Feb;97(1):79-88. doi: 10.1016/j.otsr.2010.06.014. Epub 2010 Nov 18. PMID: 21087905.
3. Min BW, Lee KJ, Bae KC, Lee SW, Lee SJ, Choi JH. Result of Internal Fixation for Stable Femoral Neck Fractures in Elderly Patients. *Hip Pelvis*. 2016 Mar;28(1):43-8. doi: 10.5371/hp.2016.28.1.43. Epub 2016 Mar 31. PMID: 27536643; PMCID: PMC4972878.
4. Antonios T, Bakti N, Nzeako O, Mohanlal P, Singh B. Outcomes following fixation for proximal humeral fractures. *J Clin Orthop Trauma*. 2019 May-Jun;10(3):468-473. doi: 10.1016/j.jcot.2019.01.029. Epub 2019 Feb 8. Erratum in: *J Clin Orthop Trauma*. 2020 Nov-Dec;11(6):1169-1171. Erratum in: *J Clin Orthop Trauma*. 2020 Nov-Dec;11(6):1172-1174. Erratum in: *J Clin Orthop Trauma*. 2021 Aug 05;21:101556. PMID: 31061571; PMCID: PMC6491912.
5. Maniscalco P, Quattrini F, Ciatti C, et al. A preliminary experience with a new intramedullary nail for trochanteric fractures. *Acta Biomed*. 2020 May 30;91(4-S):122-127. doi: 10.23750/abm.v91i4-S.9726. PMID: 32555087; PMCID: PMC7944840.
6. F. Rivera, F. Leonardi, and P. Maniscalco, "Uncemented fully hydroxyapatite-coated hip stem for intracapsular femoral neck fractures in osteoporotic elderly patients : a multicenter study," *arthroplasty today*, vol. 1, no. 3, 2015.
7. Geesink RG, Hoefnagels NH. Six-year results of hydroxyapatite-coated total hip replacement. *J Bone Joint Surg Br*. 1995 Jul;77(4):534-47. PMID: 7615595.
8. Molli RG, Lombardi AV Jr, Berend KR, Adams JB, Sneller MA. A short tapered stem reduces intraoperative complications in primary total hip arthroplasty. *Clin Orthop Relat Res*. 2012 Feb;470(2):450-61. doi: 10.1007/s11999-011-2068-7. PMID: 21971877; PMCID: PMC3254753.
9. Maniscalco P, Poggiali E, Quattrini F, et al. Proximal femur fractures in COVID-19 emergency: the experience of two Orthopedics and Traumatology Departments in the first eight weeks of the Italian epidemic. *Acta Biomed*. 2020 May 11;91(2):89-96. doi: 10.23750/abm.v91i2.9636. PMID: 32420932; PMCID: PMC7569630.
10. Maniscalco P, Quattrini F, Ciatti C, et al. Neck modularity in total hip arthroplasty: a retrospective study of nine hundred twenty-eight titanium neck implants with a maximum follow-up of eighteen years. *Int Orthop*. 2020 Nov;44(11):2261-2266. doi: 10.1007/s00264-020-04686-8. Epub 2020 Jun 29. PMID: 32601721.
11. Sessa G, Costarella L, Puma Pagliarello C, et al. Bone mineral density as a marker of hip implant longevity: a prospective assessment of a cementless stem with dual-energy X-ray absorptiometry at twenty years. *Int Orthop*. 2019 Jan;43(1):71-75. doi: 10.1007/s00264-018-4187-1. Epub 2018 Oct 3. PMID: 30284002.
12. Kastanis G, Topalidou A, Alpantaki K, Rosiadis M, Balalis K. Is the ASA Score in Geriatric Hip Fractures a Predictive Factor for Complications and Readmission? *Scientifica (Cairo)*. 2016;2016:7096245. doi: 10.1155/2016/7096245. Epub 2016 May 12. PMID: 27293978; PMCID: PMC4880678.

13. Eiskjaer S, Ostgård SE. Risk factors influencing mortality after bipolar hemiarthroplasty in the treatment of fracture of the femoral neck. *Clin Orthop Relat Res.* 1991 Sep;(270):295-300. PMID: 1884553.
14. Costain DJ, Whitehouse SL, Pratt NL, Graves SE, Ryan P, Crawford RW. Perioperative mortality after hemiarthroplasty related to fixation method. *Acta Orthop.* 2011 Jun;82(3): 275-81. doi: 10.3109/17453674.2011.584208. Epub 2011 May 11. PMID: 21561308; PMCID: PMC3235304.
15. Dorr LD, Wan Z, Song M, Ranawat A. Bilateral total hip arthroplasty comparing hydroxyapatite coating to porous-coated fixation. *J Arthroplasty.* 1998 Oct;13(7):729-36. doi: 10.1016/s0883-5403(98)90023-7. PMID: 9802657.
16. Landor I, Vavrik P, Sosna A, Jahoda D, Hahn H, Daniel M. Hydroxyapatite porous coating and the osteointegration of

the total hip replacement. *Arch Orthop Trauma Surg.* 2007 Feb;127(2):81-9. doi: 10.1007/s00402-006-0235-1. Epub 2006 Sep 30. PMID: 17013602.

Correspondence:

Received: 20 December 2020

Accepted: 23 January 2021

Pietro Maniscalco

Department of Orthopedics and Traumatology, Guglielmo da Saliceto Hospital, Piacenza, Italy

E-mail: P.Maniscalco@ausl.pc.it

