


CASE REPORT

Open Access



Autoimmune pulmonary alveolar proteinosis exacerbated by steroid therapy due to misdiagnosis as anti-aminoacyl-tRNA synthetase (ARS) antibody positive- interstitial pneumonia: a case report

Hiroshi Ishimoto¹, Noriho Sakamoto^{1*} , Hirokazu Yura^{1,2}, Atsuko Hara¹, Takashi Kido¹, Hiroyuki Yamaguchi¹, Kazuko Yamamoto¹, Yasushi Obase¹, Yuji Ishimatsu³, Minoru Satoh⁴ and Hiroshi Mukae¹

Abstract

Background: Anti-aminoacyl-tRNA synthetase (anti-ARS) antibodies are myositis-specific autoantibodies that have been identified in a subset of patients with interstitial pneumonia who do not present with dermatomyositis or polymyositis. Anti-ARS antibody-positive interstitial pneumonia is commonly treated with steroids or immunosuppressive agents and is usually responsive to these therapies. Here, we present in detail a case in which respiratory failure of a patient diagnosed with anti-ARS antibody-positive interstitial pneumonia was exacerbated by treatment with steroids and immunosuppressive agents. Further examination revealed misdiagnosis of this patient and a subsequent diagnosis of autoimmune pulmonary alveolar proteinosis.

Case presentation: A 66-year-old man presented to the hospital with dyspnea on exertion, which resulted in the detection of interstitial pneumonia. Serum anti-ARS antibodies were detected; however, there were no other findings suggestive of myositis. Pulmonary alveolar proteinosis (PAP) was suspected based on the marked increase in serum KL-6 and chest computed tomography findings. The bronchoalveolar lavage revealed no milky changes in the lavage fluid. After treatment with steroids and initiation of immunosuppressive agents for anti-ARS antibody-positive interstitial pneumonia, respiratory failure and chest imaging findings showed worsening of the condition. Bronchoscopy was repeated, and milk-like alveolar lavage fluid was collected; serum anti-granulocyte macrophage colony-stimulating factor antibody was identified. Steroids and immunosuppressive agents were gradually tapered and discontinued, and the patient's condition stabilized after repeated alveolar lavage under general anesthesia.

Conclusion: Due to similar presentation, PAP can be misdiagnosed as interstitial pneumonia. If pulmonary lesions due to interstitial pneumonia are exacerbated by immunosuppressive treatment, physicians should reconsider the diagnosis and include PAP in the differential diagnosis.

Keywords: Anti-ARS antibody, Anti-PL-7 antibody, Autoimmune alveolar proteinosis, Steroid, Case report

Background

Pulmonary alveolar proteinosis (PAP) is attributed to the accumulation of surfactant-derived lipoprotein compounds in the alveolar space owing to disturbed

*Correspondence: nsakamot@nagasaki-u.ac.jp

¹ Department of Respiratory Medicine, Nagasaki University Graduate School of Biomedical Sciences, 1-7-1 Sakamoto, Nagasaki 852-8501, Japan
Full list of author information is available at the end of the article



© The Author(s) 2022. **Open Access** This article is licensed under a Creative Commons Attribution 4.0 International License, which permits use, sharing, adaptation, distribution and reproduction in any medium or format, as long as you give appropriate credit to the original author(s) and the source, provide a link to the Creative Commons licence, and indicate if changes were made. The images or other third party material in this article are included in the article's Creative Commons licence, unless indicated otherwise in a credit line to the material. If material is not included in the article's Creative Commons licence and your intended use is not permitted by statutory regulation or exceeds the permitted use, you will need to obtain permission directly from the copyright holder. To view a copy of this licence, visit <http://creativecommons.org/licenses/by/4.0/>. The Creative Commons Public Domain Dedication waiver (<http://creativecommons.org/publicdomain/zero/1.0/>) applies to the data made available in this article, unless otherwise stated in a credit line to the data.

macrophage differentiation and function [1]. Approximately 90% of cases are autoimmune PAP (APAP), which is diagnosed by the detection of anti-granulocyte macrophage-colony stimulating factor (GM-CSF) antibodies in the serum [2, 3]. Anti-GM-CSF antibodies play a pivotal role in the disturbance of macrophage differentiation and function in the lungs of patients with APAP. The standard therapy is whole lung lavage [3], with inhaled GM-CSF therapy having potential as a future treatment [4].

Anti-aminoacyl-tRNA synthetase (anti-ARS) antibodies are myositis-specific autoantibodies that have been identified in a subset of patients with interstitial pneumonia who do not present with dermatomyositis or polymyositis [5, 6]. Interstitial pneumonia with anti-ARS antibody is commonly treated with steroids or immunosuppressive agents and is usually responsive to these therapies [7].

In this report, we describe the case of a patient with APAP who had been treated with steroids and immunosuppressive agents for interstitial pneumonia associated with anti-ARS antibody positivity.

Case presentation

A 66-year-old Japanese man presented with dyspnea on exertion for the previous 4 months and had visited a different hospital 2 months prior to his presentation at our hospital. His smoking history was 0.5 pack year. Chest radiography revealed small nodular and reticular shadows, predominantly in the lower lung fields, and a chest computed tomography scan revealed diffuse ground-glass shadows and partial interlobular septal thickening, known as crazy paving appearance (Fig. 1A). Serum KL-6 was markedly elevated at 10,513 U/mL; however, the bronchoalveolar lavage fluid (BALF) was not milky in appearance, and the BALF cell analysis revealed elevated lymphocytes (82%). In addition, anti-ARS antibody in the serum was detected; thus, a diagnosis of interstitial pneumonia with positive anti-ARS antibodies was made in the patient; prednisolone and cyclosporine treatment were initiated. Following treatment initiation, the patient rapidly developed respiratory failure, and he was transferred to our hospital 1 month after prednisolone and cyclosporine were initiated. Vital signs on admission were: body temperature, 37.1 °C; pulse, 88 beats per minute; blood pressure, 130/93 mmHg; and oxygen saturation (SpO₂), 93% with 15 L/min O₂ inhalation using a reservoir mask. On chest auscultation, fine crackles were heard in both lungs. There was no muscle grasp pain or weakness, and no skin findings suggestive of dermatomyositis, such as heliotrope rash or Gottron's sign, were noted. An arterial blood gas analysis (measured when

the patient was on 15 L/min of oxygen through a reservoir mask) showed a pH of 7.460, PaCO₂ of 36.1 mmHg, PaO₂ of 69.2 mmHg, and HCO₃ of 25.4 mmol/L. Laboratory findings are shown in Table 1. KL-6 and carcinoembryonic antigen levels were >5000 U/mL and 19.4 ng/mL, respectively. A commercial anti-ARS antibody assay (mixture of Jo-1, PL-7, PL-12, EJ, and KS antigens) was positive, but tests for anti-nuclear antibodies and other specific autoantibodies, including anti-Jo-1, were negative. Subsequently, the anti-ARS antibody was evaluated by immunoprecipitation and found to be an anti-PL-7 antibody. Chest radiography revealed an enlargement of diffuse reticular shadows, and chest computed tomography revealed a wide distribution of well-defined crazy-paving appearance (Fig. 1B). We suspected PAP and decided to perform a bronchoscopy. The patient's respiratory condition was poor; bronchoscopy was performed under ventilator control with tracheal intubation. Bronchoalveolar lavage revealed cloudy milk-like fluid. Serum anti-GM-CSF antibody level was 5.2 µg/mL (<1.0 µg/mL), and APAP was diagnosed. Thereafter, prednisolone and cyclosporine were tapered off. Total lung lavage under general anesthesia was performed twice for both lungs over a period of 6 months, resulting in resolution of respiratory failure. An arterial blood gas analysis (measured when the patient was on 1 L/min of oxygen through a nasal canula) showed a pH of 7.400, PaCO₂ of 43.5 mmHg, PaO₂ of 86.7 mmHg, and HCO₃ of 26.4 mmol/L and findings in radiographic images improved (Fig. 1C).

Discussion and Conclusions

The patient in the present case had both anti-GM-CSF and anti-ARS antibodies. The incidence of autoimmune diseases in patients with PAP is low, reportedly 1.4–1.7% of all PAP cases [2, 8]. Therefore, the coexistence of anti-GM-CSF and anti-ARS antibodies in the present case could be coincidental. In contrast, the prevalence of anti-GM-CSF antibodies in patients with autoimmune diseases including polymyositis is reportedly 9.6% [9]. In addition, a study of patients with anti-ARS antibody-positive interstitial pneumonia demonstrated that patients with progressive interstitial pneumonia had higher serum GM-CSF levels than those with stable interstitial pneumonia [10]. The exact mechanism of the production of anti-GM-CSF antibody in patients with APAP is unknown; however, it could be speculated that a chronic condition associated with production of anti-ARS antibodies could have resulted in an increase in GM-CSF, which in turn triggered the production of anti-GM-CSF antibodies.

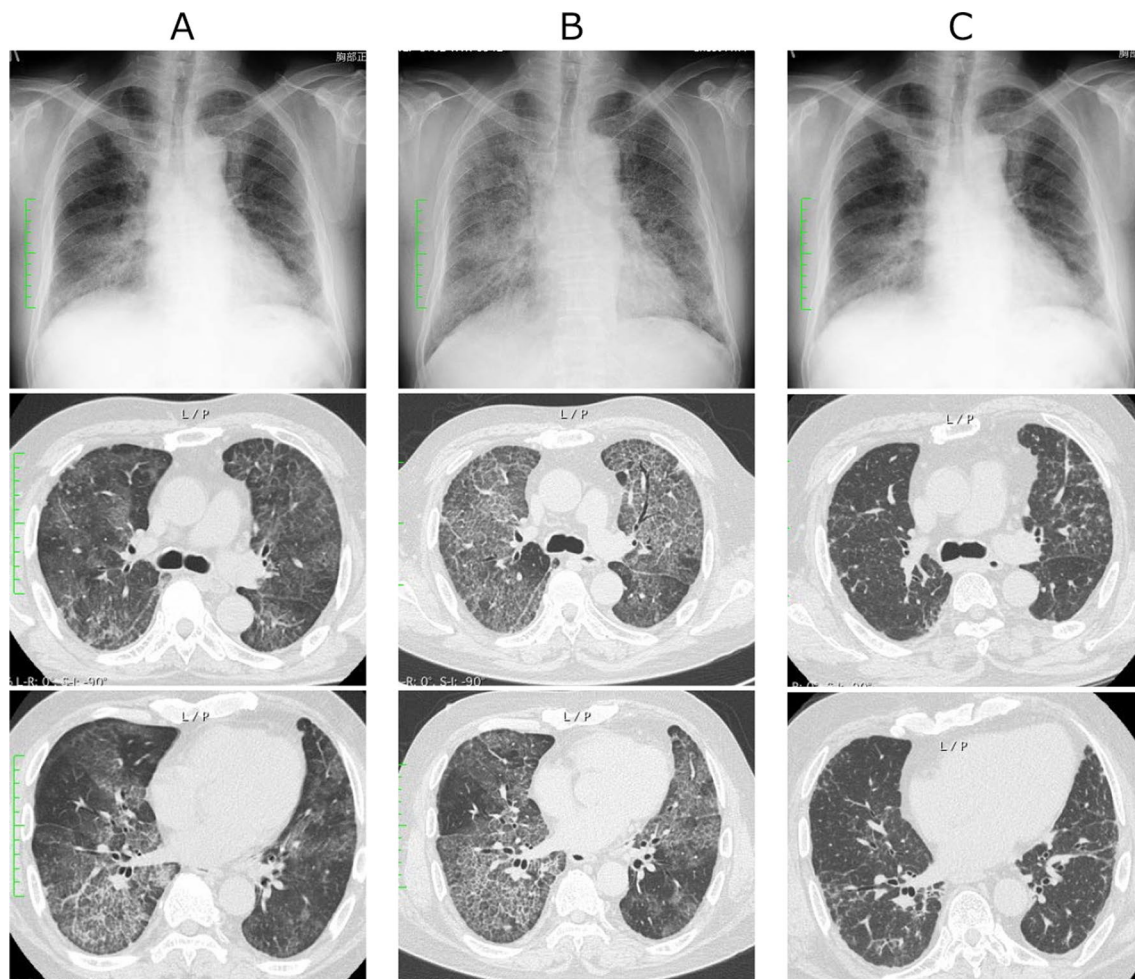


Fig. 1 Chest radiography and computed tomography findings. First visit to the previous hospital, 2 months before referral to our hospital (A). At the time of referral to our hospital, the reticular shadows were enlarged on chest radiography and the crazy paving appearance was enlarged and well-defined on chest computed tomography (B). One year later, the chest imaging findings have improved following the reduction and discontinuation of steroids and immunosuppressive agent and repeated total lung lavage under general anesthesia (C)

The pathophysiology of the coexistence of autoimmune diseases and PAP is not clear; however, the comorbidity of autoimmune diseases and PAP can cause serious therapeutic problems. APAP, which accounts for 90% of the PAP cases, is caused by the production of anti-GM-CSF antibodies, and inhaled GM-CSF therapy is expected to be beneficial for these patients [4]. Anti-ARS antibodies, known to be associated with dermatomyositis and polymyositis, are also detected in 6.0–7.6% of patients with idiopathic interstitial pneumonia [5, 6]. Among the anti-ARS antibodies detected in patients with idiopathic interstitial pneumonia, anti-PL-7 antibody is the second most common, after anti-Jo-1 [11]. Anti-ARS antibody-positive interstitial pneumonia is known to respond well to

treatment with steroid and immunosuppressive agents [12]. Conversely, a cohort study on APAP, wherein most steroid-using cases were initially diagnosed with interstitial lung disease and treated with steroids, demonstrated that steroid therapy exacerbated respiratory failure [13]. In some cases, PAP exacerbated during steroid treatment of interstitial pneumonia associated with dermatomyositis or polymyositis [14, 15].

In conclusion, PAP can be misdiagnosed as interstitial pneumonia due to similar presentation. If pulmonary lesions due to interstitial pneumonia are exacerbated by immunosuppressive treatment, physicians should reconsider the diagnosis and include PAP in the differential diagnosis.

Table 1 Laboratory findings on admission

Laboratory findings		Reference value
WBC ($\times 10^3/\mu\text{L}$)	15.2	3.3–8.6
RBC ($\times 10^6/\mu\text{L}$)	6.42	4.35–5.55
Hemoglobin (g/dL)	18.5	13.7–16.8
Hematocrit (%)	53.8	40.7–50.1
Platelet (μL)	174	158–348
TP (g/dL)	6.4	6.6–8.1
Albumin (g/dL)	3.3	4.1–5.1
AST (IU/L)	37	13–30
ALT (IU/L)	29	10–42
LDH (IU/L)	385	124–222
BUN (mg/dL)	21	8–20
Creatinine (mg/dL)	0.71	0.65–1.07
Creatine kinase (U/L)	21	59–248
Aldolase (U/L)	10.1	2.7–7.5
CRP (mg/dL)	0.07	0.00–0.14
KL-6 (U/mL)	> 5000	105.3–401.2
SP-A (ng/mL)	203.9	< 43.8
SP-D (ng/mL)	432	< 110
CEA (ng/mL)	19.4	< 5.0
Anti-nuclear antibodies (n times)	< 80	< 80
Anti-ARS antibody (INDEX)	157	< 25
Anti-CCP antibody (U/mL)	< 0.6	< 4.5
Anti-SS-A antibody (U/mL)	1.0	< 10
Anti-SS-B antibody (U/mL)	< 1.0	< 10
MPO-ANCA (U/mL)	< 1.0	< 3.5
PR3-ANCA (U/mL)	< 1.0	< 3.5

Abbreviations

APAP: Autoimmune pulmonary alveolar proteinosis; ARS: Aminoacyl-tRNA synthetase; BALF: Bronchoalveolar lavage fluid; GM-CSF: Granulocyte macrophage-colony stimulating factor; PAP: Pulmonary alveolar proteinosis.

Authors' information

None.

Acknowledgements

None.

Author contributions

HI and NS conceived, designed, and drafted the article. MS contributed to the identification of anti-aminoacyl-tRNA synthetase antibodies. HY, AH, TK, HY, KY, YO, YI and HM made critical revisions. All authors have read and agreed to the published version of the manuscript.

Funding

The preparation of this case report (payment for English editing and submission) was supported by the Non-profit Organization to Support Community Medicine Research in Nagasaki (to HI).

Availability of data and materials

Not applicable.

Declarations**Ethics approval and consent to participate**

Not applicable.

Consent for publication

We have received written consent for publication from the patient involved in the case.

Competing interests

The authors declare that they have no competing interests.

Author details

¹Department of Respiratory Medicine, Nagasaki University Graduate School of Biomedical Sciences, 1-7-1 Sakamoto, Nagasaki 852-8501, Japan. ²Department of Respiratory Medicine, National Hospital Organization Nagasaki Medical Center, 2-1001-1 Kubara, Ohmura, Nagasaki 856-8562, Japan. ³Department of Nursing, Nagasaki University Graduate School of Biomedical Sciences, 1-7-1 Sakamoto, Nagasaki 852-8520, Japan. ⁴Department of Clinical Nursing, School of Health Sciences, University of Occupational and Environmental Health, 1-1 Iseigaoka, Yahatanishi-ku, Kitakyushu, Fukuoka 807-0804, Japan.

Received: 12 November 2021 Accepted: 22 March 2022

Published online: 31 March 2022

References

- Uchida K, Nakata K, Trapnell BC, Terakawa T, Hamano E, Mikami A, et al. High-affinity autoantibodies specifically eliminate granulocyte-macrophage colony-stimulating factor activity in the lungs of patients with idiopathic pulmonary alveolar proteinosis. *Blood*. 2004;103:1089–98.
- Inoue Y, Trapnell BC, Tazawa R, Arai T, Takada T, Hizawa N, et al. Characteristics of a large cohort of patients with autoimmune pulmonary alveolar proteinosis in Japan. *Am J Respir Crit Care Med*. 2008;177:752–62.
- Jouneau S, Ménard C, Lederlin M. Pulmonary alveolar proteinosis. *Respirology*. 2020;25:816–26.
- Tazawa R, Ueda T, Abe M, Tatsumi K, Eda R, Kondoh S, et al. Inhaled GM-CSF for pulmonary alveolar proteinosis. *N Engl J Med*. 2019;381:923–32.
- Yura H, Sakamoto N, Satoh M, Ishimoto H, Hanaka T, Ito C, et al. Clinical characteristics of patients with anti-aminoacyl-tRNA synthetase antibody positive idiopathic interstitial pneumonia. *Respir Med*. 2017;132:189–94.
- Tanizawa K, Handa T, Nakashima R, Kubo T, Hosono Y, Watanabe K, et al. The long-term outcome of interstitial lung disease with anti-aminoacyl-tRNA synthetase antibodies. *Respir Med*. 2017;127:57–64.
- Hozumi H, Fujisawa T, Nakashima R, Yasui H, Suzuki Y, Kono M, et al. Efficacy of glucocorticoids and calcineurin inhibitors for anti-aminoacyl-tRNA synthetase antibody-positive polymyositis/dermatomyositis-associated interstitial lung disease: a propensity score-matched analysis. *J Rheumatol*. 2019;46:509–17.
- Seymour JF, Presneill JJ. Pulmonary alveolar proteinosis: progress in the first 44 years. *Am J Respir Crit Care Med*. 2002;166:215–35.
- Meager A, Wadhwa M, Bird C, Dilger P, Thorpe R, Newsom-Davis J, et al. Spontaneously occurring neutralizing antibodies against granulocyte-macrophage colony-stimulating factor in patients with autoimmune disease. *Immunology*. 1999;97:526–32.
- Ramos-Martinez E, Falfán-Valencia R, Pérez-Rubio G, Mejía M, Buendía-Roldán I, González-Pérez MI, et al. Anti-Aminoacyl transfer-RNA-synthetases (Anti-tRNA) autoantibodies associated with interstitial lung disease: pulmonary disease progression has a persistent elevation of the Th17 cytokine profile. *J Clin Med*. 2020;9:1356.
- Jiang M, Dong X, Zheng Y. Clinical characteristics of interstitial lung diseases positive to different anti-synthetase antibodies. *Medicine (Baltimore)*. 2021;100:e25816.
- Shioya S, Masuda T, Yamaguchi K, Sakamoto S, Horimasu Y, Nakashima T, et al. Comparison of anti-aminoacyl-tRNA synthetase antibody-related and idiopathic non-specific interstitial pneumonia. *Respir Med*. 2019;152:44–50.

13. Akasaka K, Tanaka T, Kitamura N, Ohkouchi S, Tazawa R, Takada T, et al. Outcome of corticosteroid administration in autoimmune pulmonary alveolar proteinosis: a retrospective cohort study. *BMC Pulm Med.* 2015;15:88.
14. Imura Y, Yukawa N, Handa T, Nakashima R, Murakami K, Yoshifuji H, et al. Two cases of autoimmune and secondary pulmonary alveolar proteinosis during immunosuppressive therapy in dermatomyositis with interstitial lung disease. *Mod Rheumatol.* 2018;28:724–9.
15. Sato S, Akasaka K, Ohta H, Tsukahara Y, Kida G, Tsumiyama E, et al. Autoimmune pulmonary alveolar proteinosis developed during immunosuppressive treatment in polymyositis with interstitial lung disease: a case report. *BMC Pulm Med.* 2020;20:84.

Publisher's Note

Springer Nature remains neutral with regard to jurisdictional claims in published maps and institutional affiliations.

Ready to submit your research? Choose BMC and benefit from:

- fast, convenient online submission
- thorough peer review by experienced researchers in your field
- rapid publication on acceptance
- support for research data, including large and complex data types
- gold Open Access which fosters wider collaboration and increased citations
- maximum visibility for your research: over 100M website views per year

At BMC, research is always in progress.

Learn more biomedcentral.com/submissions

