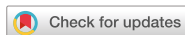



Case Report



Aseptic Meningitis Following Second Dose of an mRNA Coronavirus Disease 2019 Vaccine in a Healthy Male: Case Report and Literature Review

Han Sol Kang ¹, Ju Eun Kim ¹, Jeong Rae Yoo ¹, Hyunjoo Oh ¹, Misun Kim ¹, Young Ree Kim ², and Sang Taek Heo ¹

OPEN ACCESS

Received: Nov 21, 2021

Accepted: Jan 2, 2022

Published online: Jan 27, 2022

Corresponding Author:

Sang Taek Heo, MD

Division of Infectious Disease, Department of Internal Medicine, College of Medicine, Jeju National University, 15, Aran 13 gil, Jeju 63241, Jeju Special-Governing Province, Korea.

Tel: +82-64-754- 8151


Fax: +82-64-717-1131

Email: neosangtaek@naver.com


Copyright © 2022 by The Korean Society of Infectious Diseases, Korean Society for Antimicrobial Therapy, and The Korean Society for AIDS

This is an Open Access article distributed under the terms of the Creative Commons Attribution Non-Commercial License (<https://creativecommons.org/licenses/by-nc/4.0/>) which permits unrestricted non-commercial use, distribution, and reproduction in any medium, provided the original work is properly cited.

ORCID iDs

Han Sol Kang 

<https://orcid.org/0000-0002-0114-1433>

Ju Eun Kim 


<https://orcid.org/0000-0002-4977-1098>

Jeong Rae Yoo 

<https://orcid.org/0000-0002-5488-7925>

Hyunjoo Oh 

<https://orcid.org/0000-0003-4815-2743>

Misun Kim 

<https://orcid.org/0000-0003-3771-6101>

Young Ree Kim 

<https://orcid.org/0000-0001-8899-5708>

¹Department of Internal Medicine, College of Medicine, Jeju National University, Jeju, Korea

²Department of Laboratory Medicine, College of Medicine, Jeju National University, Jeju, Korea

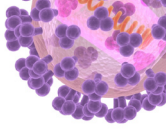
ABSTRACT

Vaccines are one of the most important strategies against pandemics or epidemics involving infectious diseases. With the spread of severe acute respiratory syndrome coronavirus 2 (SARS-CoV-2), there have been global efforts for rapid development of coronavirus disease 2019 (COVID-19) vaccine and vaccination is being performed globally on a massive scale. With rapid increase in vaccination, rare adverse events have been reported. Well-known neurological adverse events associated with COVID-19 vaccination include Guillain-Barré syndrome, myelitis, and encephalitis. However, COVID-19 vaccine-related aseptic meningitis has rarely been reported. A 32-year-old healthy man visited our hospital with a complaint of headache for 1 week. He had received the second dose of the BNT162b2 mRNA COVID-19 vaccine 2 weeks before the onset of headache. Since the initial cerebrospinal fluid (CSF) profile suggested viral meningitis, we started treatment with an antiviral agent. However, the symptoms and follow-up CSF profile on day 7 of hospitalization showed no improvement and SARS-CoV-2 IgG antibodies were detected in the CSF. We suspected aseptic meningitis associated with the vaccination and intravenous methylprednisolone (500 mg/day) was administered for 3 days. The symptoms improved and the patient was discharged on day 12 of hospitalization.

Keywords: COVID-19 vaccine; Aseptic meningitis; BNT162b2 mRNA vaccine; Adverse reaction

INTRODUCTION

Coronavirus disease 2019 (COVID-19) is rapidly spreading worldwide through human-to-human respiratory transmission. The World Health Organization declared COVID-19 a global pandemic on March 11, 2020 [1]. Vaccination is one of the most promising strategies for successfully overcoming the severe acute respiratory syndrome coronavirus 2 (SARS-CoV-2) infection. The BNT162b2 mRNA vaccine developed by Pfizer and BioNTech (Pfizer Inc., New York, NY, USA) showed an approximate efficacy of 94% in preventing COVID-19 [2]. The most common adverse events include pain at the injection site, fever, fatigue, chills, headache, and myalgia. The symptoms are mostly mild to moderate and resolved within a few days after vaccination. Although rare, serious side effects have also been reported [3]. In Korea, vaccination against COVID-19 began in March 2021, and approximately 76% of the total



Sang Taek Heo 
<https://orcid.org/0000-0001-8947-5069>

Funding

This work was supported by the 2022 education, research and student guidance grant funded by Jeju National University.

Ethics statement

The Institutional Review Board of Jeju National University Hospital approved this case report (2021-11-009) and written informed consent for the publication of this report was obtained from the patient.

Conflict of Interest

No conflict of interest.

Author Contributions

Conceptualization: JRY, STH. Formal analysis: STH. Investigation: STH. Methodology: HSK, JEK, YRK. Project administration: HSK. Supervision: JRY, HO, MK, STH. Writing - original draft: HSK, JEK. Writing - review & editing: JRY, HO, MK, YRK, STH.

population has received the second dose of one of the four COVID-19 vaccines [4]. Adverse reactions have been increasingly reported due to an increase in vaccination.

Aseptic meningitis is an inflammation of the serous of central nervous system such as the meninges and is accompanied by symptoms such as headache, fever, and signs of meningeal irritation. It usually results from infectious causes such as certain viruses, but can also result from other non-infectious causes. Headache and febrile sensation are common complaints after vaccination and these symptoms are usually ignored or managed with conservative therapy. Clinical suspicion and careful investigation off rare adverse events such as aseptic meningitis and lead to prompt and appropriate treatment. We report a case of a 32-year-old male patient who experienced aseptic meningitis after vaccination with the BNT162b2 mRNA COVID-19 vaccine.

CASE REPORT

A 32-year-old male patient who is currently working in an office job presented to our hospital with a complaint of headache for 1 week. He had stabbing pain at the back of his head. The pain lasted for approximately an hour and improved after taking a headache medication. Three days before admission, the medical clinic prescribed acetaminophen for 2 days for persistent headache. However, no improvement was observed. He was admitted to our hospital with persistent headache and fever. At the time of admission, he complained of chills, and nausea. He had received the second dose of a COVID-19 vaccine (BNT162b2 mRNA vaccine) 2 weeks before the initial onset of headache. He had no current or past disease. He did not drink or smoke and had no history of allergies. On physical examination, he had neck stiffness. Other neurological signs were negative.

His body temperature was 38.4°C, blood pressure was 138/81 mmHg, and pulse rate was 102 beats/min. He was mentally alert. Polymerase chain reaction (PCR) (BioSewoom, Seoul, Korea) test of the nasopharyngeal swab was negative for SARS-CoV-2. Laboratory findings revealed white blood cell (WBC) counts of 10,800/mm³ (reference range 4,000 - 10,000/mm³), C-reactive protein level of 0.03 mg/dL (reference range 0.0 - 0.3 mg/dL), erythrocyte sedimentation rate of 2 mm/h (reference range 0-20 mm/h), alkaline phosphatase level of 143 IU/L (reference range 104 - 338 IU/L), alanine aminotransferase level of 14 IU/L (reference range 4 - 44 IU/L), and aspartate aminotransferase level of 25 IU/L (reference range 8 - 38 IU/L). Serum creatinine level was within the normal range. Meningitis was suspected and a lumbar puncture was performed. In the cerebrospinal fluid (CSF) analysis, lymphocytes were predominant with WBC count of 480/mm³ (lymphocyte 90%, mononuclear cell 9%, and polymorphonuclear cell 1%), protein level was elevated, and glucose level was normal (Table 1). Brain magnetic resonance imaging revealed normal findings even after contrast enhancement. The patient continued to complain of severe headache and high fever, which did not respond well to antipyretic analgesics for several days after hospitalization. Viral meningitis was suspected and intravenous acyclovir (30 mg/kg/day) was initiated. Acyclovir was administered for 7 days. The patient complained of continuous fever and headache and aggravated general weakness and dizziness. Serological tests for autoimmune disorders including fluorescent antinuclear antibody test, and those for Epstein Barr virus (EBV), human immunodeficiency virus, syphilis, and tuberculosis were negative. PCR test of the patient's CSF for the detection of herpes simplex virus type 1 and 2, enterovirus, EBV, cytomegalovirus, varicella zoster virus, *Mycobacterium tuberculosis*, and non-tuberculous mycobacteria revealed

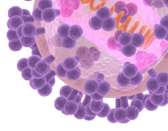


Table 1. Serial change of central nervous fluid analysis of the patient

Parameter	HD 1	HD 7	HD 14
WBC (/mm ³)	480	448	60
PMN (%)	1	0	0
Lymphocyte (%)	90	93	93
Mononuclear Cell (%)	9	5	7
Protein (mg/dL)	118	206	53
Glucose/Serum glucose (mg/dL)	56/91	46/107	52/90
LDH (U/L)	51	40	29
Amylase (U/L)	3	3	2
ADA	7	16	NA
COVID-19 IgG antibody (AU/mL) ^a	NA	Positive (52.5)	Negative (9.3)

^aCut-off: 0 - 50 AU/mL [chemiluminescent enzyme immunoassay using Alinity i SARS-CoV-2 IgG II Quant; Abbott, Chicago, IL, USA].

HD; hospital day, WBC; white blood cell, PMN; polymorphonuclear neutrophil, LDH; lactate dehydrogenase, ADA; adenosine deaminase, COVID-19; coronavirus disease 2019, NA; not available.

negative result. No strains were isolated from the blood, CSF, sputum, or urine cultures. On day 7, a second CSF analysis was performed. However, no improvement was observed (**Table 1**) and thus we stopped the administration of acyclovir. We considered the possibility of a vaccine-related cause rather than viruses or any other autoimmune disease. We evaluated the presence of spike-specific (Sp) SARS-CoV-2 IgG and IgM. The patient showed positive for the Sp SARS-CoV-2 IgG [52.5 AU/mL, cut-off: 0 - 50 AU/mL (chemiluminescent enzyme immunoassay using; Alinity i SARS-CoV-2 IgG II Quant; Abbott, Chicago, IL, USA)]. However, he was qualitatively negative for the Sp SARS-CoV-2 IgM. Fluorescent immunoassay (Standard F COVID-19 IgM/IgG Combo, SD BioSensor, Suwon, Gyeonggi-do, Korea) revealed a positive result for Sp SARS-CoV-2 IgG and a negative result for Sp SARS-CoV-2 IgM. We suspected vaccine-induced meningitis. Following intravenous administration of methylprednisolone (500 mg/day) for 3 days, his symptoms improved greatly and he was discharged on day 12 of hospitalization. After 4 days, he did not complain of any symptoms at the outpatient clinic and underwent CSF testing for the third time. The CSF analysis showed improvement (**Table 1**). He visited the outpatient clinic again in a fully recovered state and is currently doing well at his job. The patient was completely asymptomatic at 2 months after the therapy.

DISCUSSION

SARS-CoV-2 has been spreading worldwide since 2019. COVID-19 has caused significant medical and socioeconomic problems in every country. Vaccines are one of the most powerful weapons against this disease and vaccinations are rapidly increasing worldwide. However, there are concerns regarding the safety and adverse reactions of vaccines in addition to those regarding efficacy. Data regarding the safety or adverse reactions of vaccines are sparse since they have been manufactured and used recently.

Neurological adverse events following immunizations are not frequent. However, their occurrence is associated with significant morbidity and mortality [5]. Some cases of aseptic meningitis after mumps, measles, rubella, and influenza vaccination have been reported [6-8]. Identifying the biological mechanism can strongly support the causal relationship between vaccines and adverse events such as measles pneumonitis after measles vaccination or yellow fever vaccine-associated viscerotropic disease [9]. However, the exact causal relationship between these adverse events and vaccines is unclear. Similarly, the pathogenesis of COVID-19 remains unclear. It is generally assumed that the course of SARS-CoV-2 virus

infection involves invasion and replication, dysregulated immune response, and multiple organ damage and recovery [10]. Some cases of meningoencephalitis associated with COVID-19 have also been reported [11]. Various neurological manifestations of COVID-19 include anosmia/ageusia, headache, vertigo, encephalopathy, encephalitis, seizures, ataxia, and Guillain–Barré syndrome [12]. Injection of only the S1 full-length spike subunit into the tail vein of mice showed a pattern of microvascular encephalopathy similar to that observed in humans with COVID-19. This suggests that endocytosis of circulating viral S1 protein can cause cytokine storm and accompanying thrombotic and hypercoagulant conditions in various organs including the brain inducing inflammatory microvascular endothelial damage [13]. There have been reports of unspecified meningitis provoked by COVID-19 and the possible roles of the human virome in the pathophysiology of COVID-19 are being considered [12]. Mimicry molecules produced by vaccination might have disrupted the blood-brain barrier and induced aseptic meningitis in the present case. In addition, the present case can be classified as that of a drug-induced aseptic meningitis. Various types of drugs including antimicrobials, nonsteroidal anti-inflammatory drugs and vaccines can cause aseptic meningitis. The pathogenic mechanisms of drug-induced aseptic meningitis are diverse and type III or type IV hypersensitivity reactions can be considered possible mechanisms [14].

The present case is the fifth case of aseptic meningitis associated with the BNT162b2 mRNA COVID-19 vaccine (Table 2). The first case was a 42-year-old woman in Japan and the second case was an 18-year-old man in Korea [15, 16]. The third and fourth cases were adult women in Singapore and they were controlled conservative management [17]. Unlike other cases, our patient was a healthy male. His CSF analysis showed lymphocytic pleocytosis and he was treated with methylprednisolone for 3 days.

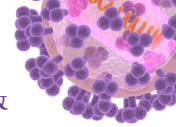
The diagnosis of aseptic meningitis induced of vaccine is not easy. The blood brain barrier is usually impermeable to circulating antibodies. The Sp SARS-CoV-2 IgG antibody was positive in the first case, but the test was not performed in the second case. In the fourth and fifth cases, the spike and nucleocapsid antibody of SARS-CoV-2 tests were performed at the same time. In this case, only the Sp antibody was tested and positive. Because two times SARS-CoV-2 PCR tests of a nasopharyngeal swab the patient had already performed were negative, could not be considered as a positive Sp antibody due to COVID-19 infection. Although it is difficult to explain the pathophysiology that antibodies of SARS-CoV-2 are positive in CSF, it is still considered to be of some help in diagnosing aseptic meningitis.

It may be difficult to argue that the BNT162b2 mRNA vaccine causes aseptic meningitis especially in young individuals based on the data from only three cases. However, if patients

Table 2. Summary of cases of aseptic meningitis after mRNA (BNT162b2) vaccination against COVID-19

Clinical characteristics	1st case [15]	2nd case [16]	3rd case [17]	4th case [17]	5th case (this case)
Age/Sex	42/female	18/male	43/female	38/female	32/male
Onset time of symptoms	1 week after 1st dose	3 weeks after 2nd dose	4 days after 2nd dose	10 days after 1st dose	2 weeks after 2nd dose
CSF analysis					
WBC	528/mm ³	115/mm ³	265/mm ³	340/mm ³	480/mm ³
Dominant cells	Monocyte (64.1%)	Monocyte (99.1%)	Lymphocyte (91.0%)	Lymphocyte (95.0%)	Lymphocyte (90.0%)
IgG antibody test	Positive	NA	Positive	Positive	Positive
Treatment					
Antibacterial/antiviral agents	Acyclovir	Vancomycin/cefotaxime	Ceftriaxone/Acyclovir	No	Acyclovir
Final management	Methylprednisolone 500 mg/day for 5 days	Conservative management	Conservative management	Conservative management	Methylprednisolone 500 mg/day for 3 days
Nationality	Japan	Korea	Singapore	Singapore	Korea

COVID-19, coronavirus disease 2019; CSF; cerebrospinal fluid, WBC; white blood cell, NA; not available.



visit the hospital with headaches or fever after vaccination, especially after vaccination with the BNT162b2 mRNA vaccine, aseptic meningitis may be suspected. Although less common, timely recognition and diagnosis of aseptic meningitis after vaccination is critical, as it can affect the treatment regimen and the next vaccination. Collection of more data from a greater number of cases may guide future preventive strategies against COVID-19 and vaccine-related adverse events.

REFERENCES

1. Wu F, Zhao S, Yu B, Chen YM, Wang W, Song ZG, Hu Y, Tao ZW, Tian JH, Pei YY, Yuan ML, Zhang YL, Dai FH, Liu Y, Wang QM, Zheng JJ, Xu L, Holmes EC, Zhang YZ. A new coronavirus associated with human respiratory disease in China. *Nature* 2020;579:265-9.
[PUBMED](#) | [CROSSREF](#)
2. Baden LR, El Sahly HM, Essink B, Kotloff K, Frey S, Novak R, Diemert D, Spector SA, Roupael N, Creech CB, McGettigan J, Khetan S, Segall N, Solis J, Brosz A, Fierro C, Schwartz H, Neuzil K, Corey L, Gilbert P, Janes H, Follmann D, Marovich M, Mascola J, Polakowski L, Ledgerwood J, Graham BS, Bennett H, Pajon R, Knightly C, Leav B, Deng W, Zhou H, Han S, Ivarsson M, Miller J, Zaks T; COVE study group. Efficacy and safety of the mRNA-1273 SARS-CoV-2 vaccine. *N Engl J Med* 2021;384:403-16.
[PUBMED](#) | [CROSSREF](#)
3. Polack FP, Thomas SJ, Kitchin N, Absalon J, Gurtman A, Lockhart S, Perez JL, Pérez Marc G, Moreira ED, Zerbini C, Bailey R, Swanson KA, Roychoudhury S, Koury K, Li P, Kalina WV, Cooper D, Frenck RW Jr, Hammitt LL, Türeci Ö, Nell H, Schaefer A, Ünal S, Tresnan DB, Mather S, Dormitzer PR, Şahin U, Jansen KU, Gruber WC; Clinical Trial Group. Safety and efficacy of the BNT162b2 mRNA Covid-19 vaccine. *N Engl J Med* 2020;383:2603-15.
[PUBMED](#) | [CROSSREF](#)
4. Korea Disease Control and Prevention Agency. Daily vaccination status by city and province. Available at: <https://ncv.kdca.go.kr/mainStatus.es?mid=a11702000000>. Accessed 8 March 2021.
5. Thakur KT, Epstein S, Bilski A, Balbi A, Boehme AK, Brannagan TH, Wesley SF, Riley CS. Neurologic safety monitoring of COVID-19 vaccines: Lessons from the past to inform the present. *Neurology* 2021;97:767-75.
[PUBMED](#) | [CROSSREF](#)
6. Di Pietrantonj C, Rivetti A, Marchione P, Debalini MG, Demicheli V. Vaccines for measles, mumps, rubella, and varicella in children. *Cochrane Database Syst Rev* 2020;4:CD004407.
[PUBMED](#)
7. Jorquera L A, Ugarte C D, Avilés L C, Delpiano M L. Aseptic meningitis due to mumps vaccine. Case report and review of the literature. *Rev Chilena Infectol* 2020;37:769-74.
[PUBMED](#)
8. González B, Fica A. Recurrent encephalitis following annual influenza vaccine. Case report. *Rev Chilena Infectol* 2016;33:226-8.
[PUBMED](#)
9. Dudley MZ, Halsey NA, Omer SB, Orenstein WA, O'Leary ST, Limaye RJ, Salmon DA. The state of vaccine safety science: systematic reviews of the evidence. *Lancet Infect Dis* 2020;20:e80-9.
[PUBMED](#) | [CROSSREF](#)
10. Weiss SR, Leibowitz JL. Coronavirus pathogenesis. *Adv Virus Res* 2011;81:85-164.
[PUBMED](#) | [CROSSREF](#)
11. Lv P, Peng F, Zhang Y, Zhang L, Li N, Sun L, Wang Y, Hou P, Huang T, Wang X. COVID-19-associated meningoencephalitis: A care report and literature review. *Exp Ther Med* 2021;21:362.
[PUBMED](#) | [CROSSREF](#)
12. Gromova OA, Torshin IY, Semenov VA, Putilina MV, Chuchalin AG. Direct and indirect neurological signs of COVID-19. *Neurosci Behav Physiol* 2021:1-11.
[PUBMED](#) | [CROSSREF](#)
13. Nuovo GJ, Magro C, Shaffer T, Awad H, Suster D, Mikhail S, He B, Michaille JJ, Liechty B, Tili E. Endothelial cell damage is the central part of COVID-19 and a mouse model induced by injection of the S1 subunit of the spike protein. *Ann Diagn Pathol* 2021;51:151682.
[PUBMED](#) | [CROSSREF](#)
14. Jolles S, Sewell WA, Leighton C. Drug-induced aseptic meningitis: diagnosis and management. *Drug Saf* 2000;22:215-26.
[PUBMED](#) | [CROSSREF](#)

15. Saito K, Shimizu T, Suzuki-Inoue K, Ishida T, Wada Y. Aseptic meningitis after vaccination of the BNT162b2 mRNA COVID-19 vaccine. *Neurol Sci* 2021;42:4433-5.
[PUBMED](#) | [CROSSREF](#)
16. Lee JK. Aseptic meningitis following the second dose of comirnaty vaccination in an adolescent patient: A case report. *Pediatr Infect Dis J* 2022;41:172-4.
[PUBMED](#) | [CROSSREF](#)
17. Chan AC, Tan BY, Goh Y, Tan SS, Tambyah PA. Aseptic meningitis after BNT-162b2 COVID-19 vaccination. *Brain Behav Immun Health* 2022;19:100406.
[PUBMED](#) | [CROSSREF](#)