

# Exfoliative Dermatitis as a Para-neoplastic Syndrome of Prostate Adenocarcinoma: A Rare Case Report With Literature Review

SAYED RESHAD GHAFOURI<sup>1</sup>, ABELARDO ESCRIBA-OMAR<sup>1</sup>, INAYATULLAH WAHDATYAR<sup>1</sup>, NOAH WHITED<sup>1</sup>, MOHAMMAD NAWAR HAKIM<sup>2</sup>, SUMIT GAUR<sup>3</sup> and FATMA DIHOWM<sup>1</sup>

<sup>1</sup>Department of Internal Medicine, Texas Tech University Health Sciences Center, El Paso, TX, U.S.A.;

<sup>2</sup>Department of Pathology, Texas Tech University Health Sciences Center, El Paso, TX, U.S.A.;

<sup>3</sup>Department of Haematology and Oncology, Texas Tech University Health Sciences Center, El Paso, TX, U.S.A.

**Abstract.** *Background/Aim* This study aimed to report a rare case of erythroderma or exfoliative dermatitis as a paraneoplastic syndrome of prostate adenocarcinoma. Exfoliative dermatitis is a rare inflammatory skin condition that is characterized by desquamation and erythema involving more than 90% of the body surface area. It is a clinical manifestation and usually associated with various underlying cutaneous disorders, drug induced reactions and malignancies. *Case Report:* Herein we report a case of 55-year-old male patient who presented with progressively diffuse scaling and erythematous rash of 3 months duration. He was diagnosed with untreated prostate adenocarcinoma about 2 months prior his admission. Skin biopsy confirmed exfoliative erythroderma diagnosis. He was investigated extensively for other pathologies, however all work up remained negative except a CT finding of large heterogeneous prostate gland with elevated PSA which was consistent with prostate cancer. Daily oral prednisone for one week and hydrocortisone cream provided partial clinical improvement. The patient was discharged on tapering steroid to follow-up with urology and oncology for further underlying prostate carcinoma management. *Conclusion:* We concluded that the ongoing erythroderma was a paraneoplastic syndrome of

prostate adenocarcinoma. Hence, early detailed history and routine screening of malignancy-related biomarkers is warranted on any individuals presenting with such symptoms.

Generalized exfoliative dermatitis or erythroderma is a rare skin condition characterized by erythema/scaling of greater than 90% of the skin surface area, lymphadenopathy, hypothermia, tachycardia and significant pruritus. It was first described by Ferdinand Von Hebra in 1868 as a generalized skin redness and scaling (1). Erythroderma is a syndrome or clinical manifestation which is usually associated with a variety of diseases including preexisting dermatosis, drug exposure, infections, herbal medicines, and rarely underlying malignancies (2). As a paraneoplastic syndrome of visceral malignancies, erythroderma has only been reported in 0.8-1% of total cases (3, 4). Based on expert analysis, erythroderma is usually benign and doesn't pose a significant risk of death, however if it is fulminant, it can be life-threatening and is associated with a high mortality risk specially in hospitalized patients (5, 6). Herein we present a case of exfoliative dermatitis associated with underlying prostate adenocarcinoma which by itself is a very rare presentation and has only been reported in few cases in the literature.

## Case Report

A 55-years-old male patient admitted at our Institution on November 2019 for progressively worsening diffuse scaling and erythematous rash associated with occasional itching, significant weight loss (about 40 lb), and night sweats. Three months prior to his admission, the skin rash had started on his arm and chest that progressively spread all over the body for which he visited the ER twice, prescribed topical steroid with antihistaminic but no significant improvement was achieved. His past medical history was remarkable for hypertension, and recently diagnosed prostate adenocarcinoma for one month

This article is freely accessible online.

*Correspondence to:* Sayed Reshad Ghafouri, MD, Department of Internal Medicine, Texas Tech University Health Science Center, 4800 Alberta Avenue, El Paso, TX 79912, U.S.A. Tel: +1 2017243609, Fax: +1 9155456635, e-mail: s.reshad.ghafouri@ttuhsc.edu

*Key Words:* Exfoliative dermatitis, erythroderma, prostate cancer, paraneoplastic syndrome.

©2021 International Institute of Anticancer Research  
www.iiar-anticancer.org

without treatment. Amlodipine was the only medication the patient has been taking at home. Family history was unremarkable for any dermatological disease or cancer history. He had no history of alcohol or tobacco use in the past. Clinically, the patient was hemodynamically stable. Skin examination demonstrated generalized scaling, flaking and erythema involving >90% of the body surface area including scalp, face, trunk and extremities with evident signs of scratching due to significant pruritus (Figure 1). Palms and soles along oral mucosa were spared. Bilateral non-tender axillary and inguinal lymphadenopathy were present. Envisioned differential diagnosis included paraneoplastic manifestation from prostate adenocarcinoma, cutaneous T cell lymphoma (CTCL) or new onset of inflammatory dermatosis. Laboratory examination including differential blood count, clinical chemistry, rheumatoid factors, antinuclear antibody, cyclic citrullinated peptide, bullous pemphigoid autoantibodies, hepatitis panel and HIV were unremarkable except elevated serum prostate specific antigen (PSA) of 21 ng/ml (1-1.5 ng/ml). A computerized tomography (CT) of abdomen with contrast showed a large heterogeneous prostate gland (Figure 2). CT thorax with contrast revealed bilateral axillary lymphadenopathy, measuring up to 2 cm. An excisional biopsy from right axillary lymph node demonstrated histological features of dermatopathic lymphadenopathy with florid proliferation of Langerhans cells in paracortical areas with HMB-45 negative immunostaining (Figure 3). Histopathological result of skin punch biopsy showed spongiosis, lichenoid infiltrates, parakeratosis, and psoriasiform hyperplasia with dermis contains histiocytes, lymphocytes, and rare eosinophils (Figure 4). Special stains (GMS, PAS, AFB) for fungal and acid-fast organisms were negative. No malignant infiltrating cells were detected. The patient's generalized pruritus was partially relieved with oral antihistaminics and topical corticosteroids. However, daily oral prednisone 1 mg/kg per day for a week along with corticosteroid cream did provide partial clinical improvement of exfoliative erythroderma. The patient was referred to the urology and oncology clinic for prompt initiation of underlying prostate carcinoma treatment. Per chart review of outpatient oncology notes, the patient has been reported to have significant improvement of erythroderma following surgical procedure and androgen deprivation therapy in six months of follow-up.

*Review of the literature.* To identify the published reports of erythroderma as a paraneoplastic phenomenon of prostate adenocarcinoma, a comprehensive review of literature using the search terms 'erythroderma, exfoliative dermatitis and prostate cancer' was performed. Only five cases of prostate cancer-associated erythroderma were found to have been previously reported in the literature. We included the relevant information such as age of diagnosis, associated malignancy, clinical presentation, treatment and outcome in the Table I. By creating such a table, we aimed to give the readers a

short overview of the published data in the literature in order to emphasize on the rarity of this phenomenon.

## Discussion and Conclusion

Erythroderma, or generalized exfoliative dermatitis, is a rare severe inflammatory skin condition (11). Epidemiologically, the overall incidence of erythroderma both in the USA and the world is unknown and has not yet been addressed, however, a recent retrospective study from Portugal reported an incidence of 9.4 cases/year and 11.9% in hospitalized patients. A different study from India recorded the incidence of erythroderma in outpatient dermatology offices as 35 per 100,000 patients (0.035%) (4, 5, 12). Studies have shown a male predominance with male-to-female ratio ranging from 2 and 4 to 1 and a mean age of onset between 40 to 60 years (13). The physiopathogenic mechanisms of erythroderma varies according to the underlying causes. Even though, the exact mechanism is not fully understood, however the proposed common pathogenesis is believed to be due to increased expression of adhesion molecules in epithelial cells (VCAM-1, ICAM-1, E-selectin, and P-selectin) which ultimately increases dermal inflammation and epidermal proliferation through an increase in mitosis that causes an increase in overall epidermal cells numbers, and increased cell turnover, with decreases in transit time through the epidermis (14, 15). There is a repeated turnover of epithelial cells in normal epidermis. Initially, cell division occurs near the basal layer and they move toward the periphery where they become well-keratinized in approximately 10-12 days. Subsequently, the cells are sloughed off after being remained in the stratum corneum for another 12-14 days. In contrast, the number of cells in the germinative layer and their mitotic rate is increased in exfoliative dermatitis. The transit time of cells through the epidermis is shortened. As a result, the exfoliated scales are incompletely keratinized and contain material normally retained by the skin which may result in a negative nitrogen balance and result in significant scale loss (7.2 g-22.6 g per day) (16). The other common pathophysiological mechanism of exfoliative erythroderma is increased blood flow to the skin, with impaired barrier function, which also results in increased insensible fluid loss through transpiration. Patients might experience dehydration and reflex tachycardia. In severe cases, high-output cardiac failure may occur (17, 18). The most common underlying etiology for erythroderma is preexisting dermatoses, drugs induced, and malignancies, whilst the rest of cases remain idiopathic (12). Based on several reports, about 1% of erythroderma cases have a neoplastic or paraneoplastic etiology (4). Malignancies that have a strong association with erythroderma, including but not limited to CTCL (cutaneous T-cell lymphoma), laryngeal, thyroid, breast, lung, esophageal, gastric, hepatocellular, tongue, gallbladder,

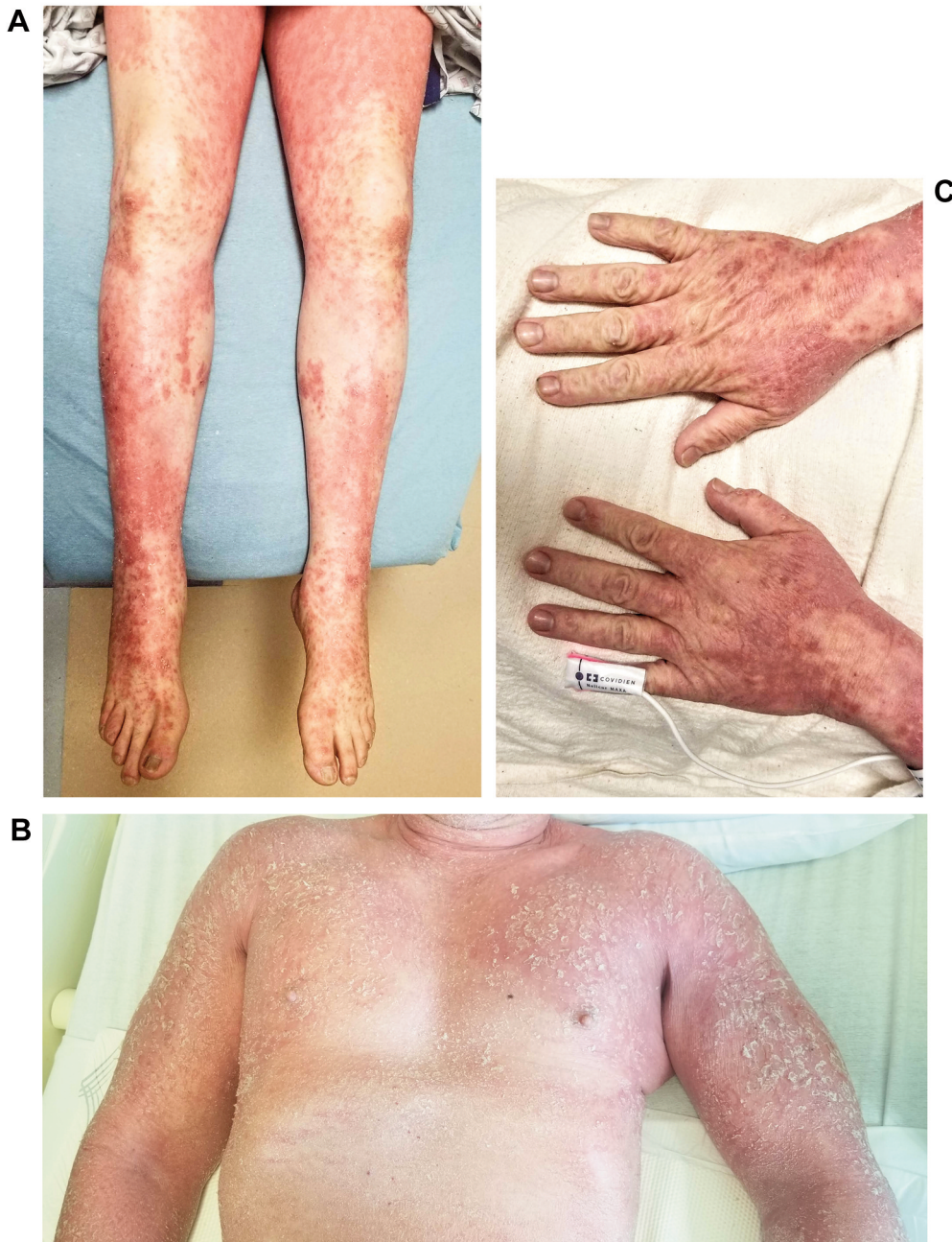

Figure 1. Clinical presentation of diffuse erythroderma on trunk and extremities. A: Diffuse erythematous rash of bilateral dorsal aspect of hands. B: Diffuse erythema and scaling rash over trunk, chest and arms. C: Scaling erythematous rash of lower extremity.

colon, fallopian tube and prostate cancers are reported (12, 19). Most of the time, it is difficult to determine the association of erythroderma and malignancies, however if erythroderma develops insidiously and progressively in the absence of previous skin disease and shows resistance to standard therapy, by that time, an underlying malignancy should be strongly considered (14, 20). After renal cell

carcinoma, prostate cancer is the second most common urological malignancy to be associated with paraneoplastic syndromes. It typically occurs in the setting of advanced prostate cancer with poor prognosis (3, 21). In the literature, more than one hundred cases of different paraneoplastic syndromes including those caused by endocrine or hormonal effects, immune mechanisms, and other neurological or



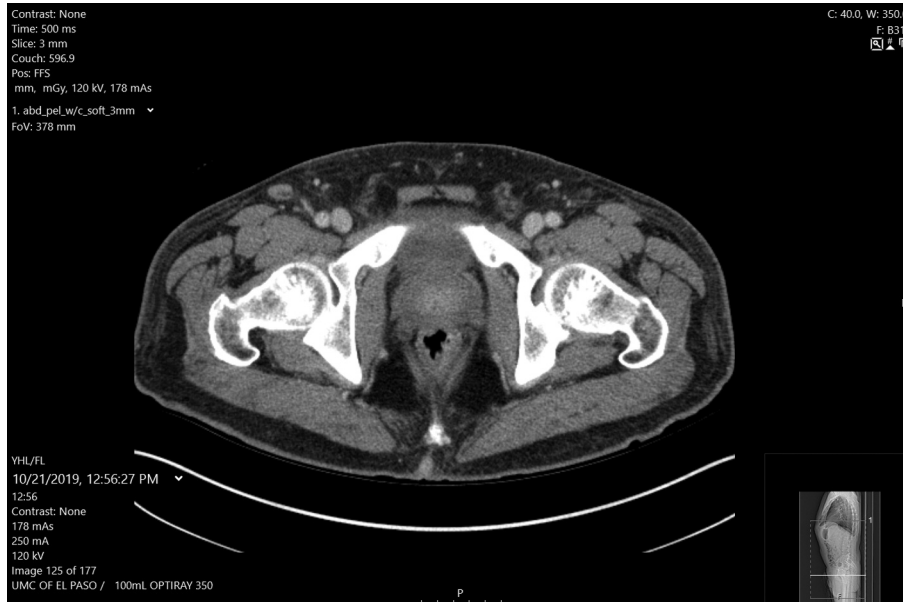

Figure 2. CT scan of abdomen and pelvis showing enlarged prostate gland.

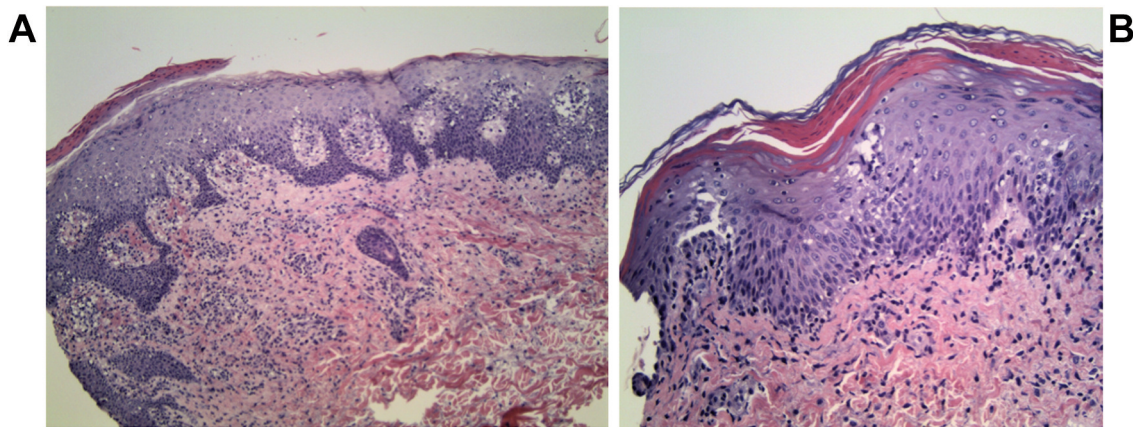


Figure 3. Histopathological examination of excisional lymph node biopsy. A: Intermediate power view of the axillary lymph node. The paracortical expansion by proliferating interdigitating dendritic cells, Langerhans, histiocytes and lymphocytes are predominant with a remnant of follicle in the center (H&E original magnification  $\times 200$ ). B: High power view shows proliferating interdigitating dendritic cells and Langerhans cells mixed with lymphocytes and melanin-containing macrophages (H&E original magnification  $\times 400$ ). C: Langerhans cells and interdigitating dendritic cells are accentuated by S100 immunohistochemical stain (original magnification  $\times 100$ ).

hematological effects associated with prostate cancer have been reported. Among those, only a few cases have been related to dermatological conditions such as dermatomyositis sweat syndrome and erythroderma. Although rare, erythroderma as a dermatological condition arising from prostate cancer is well documented in the literature (21, 22).

Clinically, erythroderma has a gradual and insidious onset in the setting of malignancies (9). The classical clinical

feature of erythroderma is bright red patches followed by the appearance of a white or yellow scale involving especially the head, trunk and genital region and tends to spread to most of the skin surface in a matter of days or weeks (23). It usually, but not always spares the palms, soles and the mucous membranes (24). Skin tightness, and pruritis occurs in nearly all patients, and more than half of the patients may present with fever as well. More than half of patients also

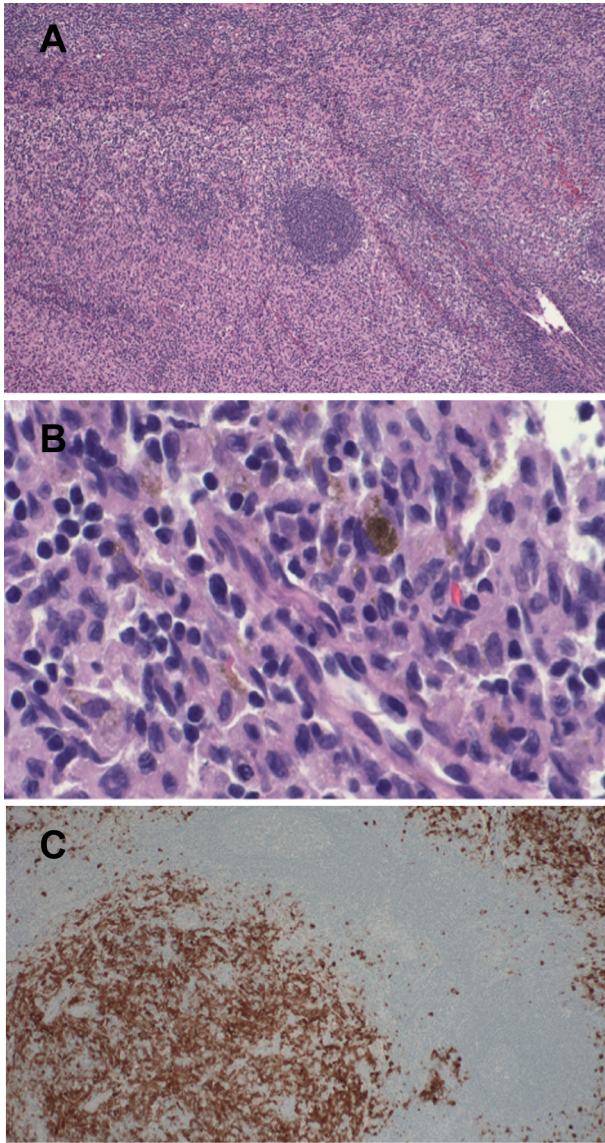


Figure 4. Histopathological examination of skin punched biopsy. A: Low power view of the skin punch biopsy shows acanthosis and parakeratosis in addition to derma inflammation and spongiosis (H&E original magnification  $\times 100$ ). B: High power view shows the lichenoid nature of inflammation in some areas.

develop lymphadenopathy, splenomegaly, and hepatomegaly that may suggest a drug hypersensitivity or malignancy (12). Other rare symptoms including hair loss and nail findings such as subungual hyperkeratosis, onycholysis, ridging, dry or brittle nails, or nail shedding may also be present (5, 14).

To diagnose erythroderma as an underlying cause of internal malignancy, there needs to be a history of insidious development, refractoriness to standard therapies, absence of preexisting dermatosis and progressive decompensation. Prostate cancer

should be highly suspected in male patients with erythroderma older than 45 years as the incidence of this malignancy increases with age old and have elevated PSA level (5, 9).

The majority of erythroderma cases can be diagnosed easily with the clinical finding of generalized erythema and desquamation involving  $\geq 90\%$  of the skin surface area, however due to variety of triggering causes, defining the exact underlying pathology is a challenge for physicians and a profound clinicopathological correlation should be established (17, 25). Therefore, a skin biopsy is a mandatory first step workup of erythrodermic cases, which requires a highly trained pathologist to provide a precise diagnosis (25). Several studies report that skin biopsies are helpful in diagnoses of 53-66% of erythroderma cases, however, a considerable number of cases (39.1%) still remain inconclusive as idiopathic not matching the final diagnosis (12, 26). Based on previous studies, the most frequent histopathological findings in erythroderma were hyperkeratosis, acanthosis, spongiosis, and perivascular inflammatory infiltrate (27).

In most cases, erythroderma can be severe or life-threatening which requires inpatient care for further investigation and treatment (28). Regardless of underlying etiology, supportive care is the initial management of all types of erythroderma that mainly involves nutrition assessment, monitoring, regulating environmental temperature, and ensuring metabolic and hemodynamic stability. Colloid baths and wet compresses can improve skin barrier functions along with emollient creams with low-potency topical corticosteroids (11). Additionally, sedation with antihistamines can alleviate scratching and relieve pruritus and anxiety, whilst preventing secondary skin infections (20). Erythroderma as a paraneoplastic syndrome of prostate cancer mostly resolves upon treatment of the underlying tumor, however some cases fail to respond and require further treatment with systemic corticosteroids or other immunosuppressant such as methotrexate and cyclosporine (20, 29). Chemotherapeutic agents can be considered for advanced prostate cancer where the paraneoplastic syndrome represents first manifestation of progression of the tumor (21).

In conclusion, although rare it is important to keep prostate cancer among our differential diagnosis in patients that present with unexplained dermatological findings like exfoliative dermatitis.

### Conflicts of Interest

None of the Authors have any financial or personal bias to declare. The Authors report no conflicts of interest.

### Authors' Contributions

SR Ghafouri completed the background research, drafted and edited the manuscript and the was the grantor of the publication. A.O. Escriba, I. Wahdayar, N. Whited, M.N. Hakim, S. Gaur and F. Dihowm edited and completed the manuscript.

Table I. Reported cases of exfoliative dermatitis in the literature.

Authors	Age at diagnosis	Clinical presentation	Associated malignancy	Treatment	Outcome
Swartz <i>et al.</i> (7)	65	Erythroderma and generalized vitiligo	Prostate adenocarcinoma	Triamcinolone acetate intramuscular (IM) 60 mg twice daily followed by <i>p.o.</i> prednisone 60-100 mg daily and topical fluorinated steroids due to recurrence. Transurethral resection of the prostate (TURP) with radiation therapy for underlying malignancy	Multiple long-term steroid effects including central obesity, subcapsular cataracts, and severe proximal myopathy complicate patient's care. At 4 month of follow up, patient developed severe exacerbation and placed on <i>po</i> prednisone again. The patient was gradually tapered off his oral Tapering dose of oral prednisone and whole-body applications of 0.1% triamcinolone.
Li <i>et al.</i> (8)	80s	Pruritic eruption, erythroderma	Prostate adenocarcinoma	<i>p.o.</i> methylprednisolone 24 mg daily. Androgen deprivation as single therapy for prostate cancer	The skin lesions and pruritus were resistant to corticosteroids but improved substantially after anticancer therapy. Four weeks after the initiation of therapy, the eruption and pruritus had nearly resolved.
Momm <i>et al.</i> (3)	71	Erythroderma	Prostate adenocarcinoma	Prednisolone 150 mg daily for 1 week without improvement of symptoms. Switched to Cyclosporine A 350 mg daily with complete remission of erythroderma. but several attempts to discontinue oral cyclosporine A resulted in an immediate recurrence of erythroderma. Palliative radiation therapy for prostate adenocarcinoma.	Cyclosporine A was tapered off stepwise and stopped completely at the end of radiation therapy without recurrence of erythroderma. This had not been possible a few days before the start of radiation therapy.
Rosen <i>et al.</i> (9)	63	Generalized exfoliative or erythroderma	Prostate adenocarcinoma	Gold implants and irradiation for treatment of prostate adenocarcinoma	Exfoliative dermatitis was able to be managed with only topical corticosteroids.
Danny <i>et al.</i> (10)	80	Erythroderma	Prostate adenocarcinoma	TURP with bilateral orchidectomy	Transurethral resection of the prostate with bilateral orchidectomy was employed with an uneventful postoperative period. The patient was discharged and followed up once every 3 months till reporting.

## References

- Balasubramaniam P and Berth-Jones J: Erythroderma: 90% skin failure. *Hosp Med* 65(2): 100-102, 2004. PMID: 14997777. DOI: 10.12968/hosp.2004.65.2.12068
- Miyashiro D and Sanches JA: Erythroderma: a prospective study of 309 patients followed for 12 years in a tertiary center. *Sci Rep* 10(1): 9774, 2020. PMID: 32555205. DOI: 10.1038/s41598-020-66040-7
- Momm F, Pflieger D and Lutterbach J: Paraneoplastic erythroderma in a prostate cancer patient. *Strahlenther Onkol* 178(7): 393-395, 2002. PMID: 12163994. DOI: 10.1007/s00066-002-0967-y
- Yuan XY, Guo JY, Dang YP, Qiao L and Liu W: Erythroderma: A clinical-etiological study of 82 cases. *Eur J Dermatol* 20(3): 373-377, 2010. PMID: 20400388. DOI: 10.1684/ejd.2010.0943
- Okoduwa C, Lambert WC, Schwartz RA, Kubeyinje E, Eitokpah A, Sinha S and Chen W: Erythroderma: review of a potentially life-threatening dermatosis. *Indian J Dermatol* 54(1): 1-6, 2009. PMID: 20049259. DOI: 10.4103/0019-5154.48976
- Akhyani M, Ghodsi ZS, Toosi S and Dabbaghian H: Erythroderma: a clinical study of 97 cases. *BMC Dermatol* 5: 5, 2005. PMID: 15882451. DOI: 10.1186/1471-5945-5-5



- 7 Schwartz RA and Trotter MG: Generalized vitiligo after erythroderma. *Dermatologica* 167(1): 42-46, 1983. PMID: 6226547. DOI: 10.1159/000249744
- 8 Li S, Yu X and Wang T: Papuloerythroderma of Ofuji. *JAMA Dermatol* 156(12): 1365, 2020. PMID: 33052383. DOI: 10.1001/jamadermatol.2020.2973
- 9 Rosen T, Chappell R and Drucker C: Exfoliative dermatitis: presenting sign of internal malignancy. *South Med J* 72(6): 652-653, 1979. PMID: 156398.
- 10 Danny GC, Swaminathan A, Rajesh G and Veeraraghavan M: Paraneoplastic erythroderma as a protean manifestation of adenocarcinoma prostate. *Indian J Dermatol* 65(1): 72-74, 2020. PMID: 32029949. DOI: 10.4103/ijd.IJD\_189\_18
- 11 Mistry N, Gupta A, Alavi A and Sibbald RG: A review of the diagnosis and management of erythroderma (generalized red skin). *Adv Skin Wound Care* 28(5): 228-36; quiz 237-8, 2015. PMID: 25882661. DOI: 10.1097/01.ASW.0000463573.40637.73
- 12 César A, Cruz M, Mota A and Azevedo F: Erythroderma. A clinical and etiological study of 103 patients. *J Dermatol Case Rep* 10(1): 1-9, 2016. PMID: 27119000. DOI: 10.3315/jdcr.2016.1222
- 13 Sehgal VN and Srivastava G: Exfoliative dermatitis. A prospective study of 80 patients. *Dermatologica* 173(6): 278-284, 1986. PMID: 2950005.
- 14 Austad SS and Athalye L: Exfoliative Dermatitis. 2021. PMID: 32119455.
- 15 Sigurdsson V, de Vries IJ, Toonstra J, Bihari IC, Thepen T, Bruijnzeel-Koomen CA and van Vloten WA: Expression of VCAM-1, ICAM-1, E-selectin, and P-selectin on endothelium *in situ* in patients with erythroderma, mycosis fungoides and atopic dermatitis. *J Cutan Pathol* 27(9): 436-440, 2000. PMID: 11028813. DOI: 10.1034/j.1600-0560.2000.027009436.x
- 16 Kanthraj GR, Srinivas CR, Devi PU, Ganasoundari A, Shenoi SD, Deshmukh RP, Suresh BJ and Pai SB: Quantitative estimation and recommendations for supplementation of protein lost through scaling in exfoliative dermatitis. *Int J Dermatol* 38(2): 91-95, 1999. PMID: 10192155. DOI: 10.1046/j.1365-4362.1999.00408.x
- 17 Salami TA, Enahoro Oziegbe O and Omeife H: Exfoliative dermatitis: patterns of clinical presentation in a tropical rural and suburban dermatology practice in Nigeria. *Int J Dermatol* 51(9): 1086-1089, 2012. PMID: 22909364. DOI: 10.1111/j.1365-4632.2011.05400.x
- 18 Banerjee S, Ghosh S and Mandal RK: A study of correlation between clinical and histopathological findings of erythroderma in North Bengal population. *Indian J Dermatol* 60(6): 549-555, 2015. PMID: 26677266. DOI: 10.4103/0019-5154.169124
- 19 Tan GF, Kong YL, Tan AS and Tey HL: Causes and features of erythroderma. *Ann Acad Med Singap* 43(8): 391-394, 2014. PMID: 25244987.
- 20 Karakayli G, Beckham G, Orengo I and Rosen T: Exfoliative dermatitis. *Am Fam Physician* 59(3): 625-630, 1999. PMID: 10029788.
- 21 Hong MK, Kong J, Namdarian B, Longano A, Grummet J, Hovens CM, Costello AJ and Corcoran NM: Paraneoplastic syndromes in prostate cancer. *Nat Rev Urol* 7(12): 681-692, 2010. PMID: 21139643. DOI: 10.1038/nrurol.2010.186
- 22 Matzkin H and Braf Z: Paraneoplastic syndromes associated with prostatic carcinoma. *J Urol* 138(5): 1129-1133, 1987. PMID: 3312637. DOI: 10.1016/s0022-5347(17)43524-5
- 23 Sehgal VN, Srivastava G and Sardana K: Erythroderma/exfoliative dermatitis: a synopsis. *Int J Dermatol* 43(1): 39-47, 2004. PMID: 14693020. DOI: 10.1111/j.1365-4632.2004.01975.x
- 24 Agarwal S, Khullar R, Kalla G and Malhotra YK: Nose sign of exfoliative dermatitis: a possible mechanism. *Arch Dermatol* 128(5): 704, 1992. PMID: 1533503.
- 25 Cuellar-barboza A, Ocampo-candiani J and Herz-ruelas M: A Practical approach to the diagnosis and treatment of adult erythroderma. *Actas Dermo-Sifiliográficas (English Edition)* 109(9): 777-790, 2020. DOI: 10.1016/j.adengl.2018.05.033
- 26 Megna M, Sidikov AA, Zaslavsky DV, Chuprov IN, Timoshchuk EA, Egorova U, Wenzel J and Nasyrov RA: The role of histological presentation in erythroderma. *Int J Dermatol* 56(4): 400-404, 2017. PMID: 28191631. DOI: 10.1111/ijd.13488
- 27 Tomasini C, Aloï F, Solaroli C and Pippione M: Psoriatic erythroderma: a histopathologic study of forty-five patients. *Dermatology* 194(2): 102-106, 1997. PMID: 9094455. DOI: 10.1159/000246075
- 28 Rothe MJ, Bernstein ML and Grant-Kels JM: Life-threatening erythroderma: diagnosing and treating the "red man". *Clin Dermatol* 23(2): 206-217, 2005. PMID: 15802214. DOI: 10.1016/j.clindermatol.2004.06.018
- 29 Masuda H, Urushibara M and Kihara K: Successful treatment of dermatomyositis associated with adenocarcinoma of the prostate after radical prostatectomy. *J Urol* 169(3): 1084, 2003. PMID: 12576853. DOI: 10.1097/01.ju.0000047281.73280.7e

Received May 6, 2021

Revised May 27, 2021

Accepted June 14, 2021