


Progressive choreodystonia in X-linked hyper-IgM immunodeficiency: a rare but recurrent presentation

Matej Škorvánek^{1,2}, Robert Jech³, Juliane Winkelmann^{4,5,6,7} & Michael Zech^{4,5} 

¹Department of Neurology, P.J. Safarik University, Kosice, Slovak Republic

²Department of Neurology, University Hospital of L. Pasteur, Kosice, Slovak Republic

³Department of Neurology, Charles University, 1st Faculty of Medicine and General University Hospital in Prague, Prague, Czech Republic

⁴Institute of Neurogenomics, Helmholtz Zentrum München, Munich, Germany

⁵Institute of Human Genetics, School of Medicine, Technical University of Munich, Munich, Germany

⁶Lehrstuhl für Neurogenetik, Technische Universität München, Munich, Germany

⁷Munich Cluster for Systems Neurology, SyNergy, Munich, Germany

Correspondence

Michael Zech, Institute of Neurogenomics, Helmholtz Zentrum München, Deutsches Forschungszentrum für Gesundheit und Umwelt (GmbH), Ingolstädter Landstraße 1, 85764 Neuherberg, Germany. Tel: 0049 89 3187 1884; Fax: 0049 89 3187 3297; E-mail: michael.zech@mri.tum.de

Received: 5 November 2021; Revised: 1 February 2022; Accepted: 25 February 2022

doi: 10.1002/acn3.51538

Funding Information

This study was funded by in-house institutional funding from Technische Universität München, Munich, Germany, Helmholtz Zentrum München, Munich, Germany, and Charles University, Prague, Czech Republic (PROGRES Q27). This study was also funded by the Czech Ministry of Education under grant AZV: NV19-04-00233 and under the frame of EJP RD, the European Joint Programme on Rare Diseases (EJP RD COFUND-EJP N° 825575), as well as the Slovak Grant and Development Agency under contract APVV-18-0547 and the Operational Programme Integrated Infrastructure, funded by the ERDF under No. ITMS2014+: 313011 V455. JW and MZ receive research support from the German Research Foundation (DFG 458949627; WI 1820/14-1; ZE 1213/2-1).

Introduction

Movement disorders with progressive courses can be caused either by alterations of normal neurodevelopment or by neurodegenerative processes.^{1,2} For both instances, a variety of underlying etiologic lesions have been described,

Abstract

An association between movement disorders and immune-system dysfunction has been described in the context of rare genetic diseases such as ataxia telangiectasia as well as infectious encephalopathies. We encountered a male patient who presented immunodeficiency of unknown etiology since childhood. A medication-refractory, progressive choreodystonic movement disorder emerged at the age of 42 years and prompted an exome-wide molecular testing approach. This revealed a pathogenic hemizygous variant in *CD40LG*, the gene implicated in X-linked hyper-IgM syndrome. Only two prior reports have specifically suggested a causal relationship between *CD40LG* mutations and involuntary hyperkinetic movements. Our findings thus confirm the existence of a particular *CD40LG*-related condition, combining features of compromised immunity with neurodegenerative movement abnormalities. Establishing the diagnosis is crucial because of potential life-threatening immunological complications.

including genetic and nongenetic factors.^{1,2} An intriguing but rare association represents the co-occurrence of neurodegeneration-related movement disorders and immunodeficiencies affecting cellular and/or humoral immunity.^{3,4} Ataxia telangiectasia (OMIM#208900) associated with biallelic variants in *ATM* has been identified as a

prototypical example of an orphan disease presenting with progressive neurodegeneration, diverse movement abnormalities (including dystonia and chorea), and immunological defects such as lymphocytopenia and reduced antibody levels.⁵ Over the last decades, anecdotal literature reports have suggested additional links between primary immunodeficiency disorders and the expression of abnormal hyper- and/or hypokinetic movements,⁶ but no particular entity has been defined. Herein, we establish confirmatory evidence for the existence of a clinical subtype of *CD40LG*-related X-linked hyper-immunoglobulin M (hyper-IgM) syndrome (XHIGM, OMIM#308230) in which XHIGM-characteristic immunological problems manifest in combination with medication-refractory choreo-dystonic/–dyskinetic movements.

Case Description

A 46-year-old male patient was referred to our tertiary movement-disorders center in Kosice (Slovakia) due to the manifestation of difficult-to-control involuntary movements; external differential diagnoses included a Huntington phenocopy, ataxia telangiectasia, and ataxia telangiectasia-like conditions. The patient suffered from an unexplained immunodeficiency syndrome with abnormal immunoglobulin profile since early childhood. There was no family history for neurological and immunological disorders and no relevant medication intake prior to the evolution of his movement disorder. During his first years of life, he had recurrent upper- and lower-respiratory tract infections, fungal dermatosis, and intestinal infectious complications. At the age of 9 years, he underwent thymus and fetal liver-cell transplantation and he has been on regular substitution therapy with intravenous immunoglobulins since the age of 17 years. Additionally, he was diagnosed with relapsing skin carcinoma. Otherwise, he was well and exhibited normal psychomotor development. He had not seen a neurologist until the age of 42 years, when he began to demonstrate memory deficits, changes in behavior, and paranoid thinking; psychiatric symptoms were accompanied by appearance of uncontrollable adventitious movements and postural abnormalities. He progressively experienced balance problems and generalized hyperkinetic movements, described mostly as choreatic, and he lost the ability to ride a bicycle. After the manifestation of movement-disorder and neuropsychiatric symptoms, antipsychotics including haloperidol and clozapine were administered, with partial effect on existing abnormal movements (haloperidol). In addition, the patient underwent treatment trials with risperidone and cariprazine, which proved useful in ameliorating his chorea to a certain extent; however, these interventions had no sustained effect. Since the age of

44 years, the patient reported significant weight loss, worsening of coordination deficits, and progressive dyskinesia. Based on his family's description, his dyskinesia markedly worsened during stress and when he was hungry, while symptoms improved after meals.

Neuroanatomical assessment with magnetic resonance imaging (MRI) revealed global brain atrophy, more prominent in the infratentorial space (Fig. 1); there were changes in cerebellar volume, although the spatial pattern of atrophy was not specific for a certain neurodegenerative disorder. Available blood and/or CSF laboratory tests documented the following: negative comprehensive screenings for autoimmune or paraneoplastic encephalitis (including unremarkable screenings for antiphospholipids and anti-DNA antibodies); negative testing for thyroid or parathyroid gland dysfunction, glycemia, vitamin deficits, Wilson's disease, and chronic infections; abnormal B-cell count and reduced IgG levels; repeat nondiagnostic CSF studies without evidence for infectious or autoimmune inflammation; and exclusion of triplet repeat mutation in *HTT*. An initial thorough variant scanning using a panel of 241 ataxia-linked genes was performed (see Data S1), which did not yield a causative sequence change; Friedrich ataxia (*FXN*) and Fragile-X tremor/ataxia syndrome (*FMR1*) were also ruled out. To investigate the presence of an underlying mutational lesion in an unbiased fashion, the patient was recruited into a research project focusing on the study of rare movement disorders.⁷ Genetic investigations were conducted under the ethical guidelines issued by the participating institutions and written informed consent was obtained from the patient for the publication of clinical and molecular data including videoed examinations. Whole-exome sequencing of the patient's blood cell-derived DNA using a custom-developed in-house pipeline (Munich, Germany) yielded 12 Gb of uniquely mapped sequence, with an average depth-of-coverage of 125× (98.6% of bases covered ≥20×). Analysis of single-nucleotide variants, insertions/deletions, copy number variants, and select repeat changes uncovered no clinically relevant variations in established movement disorder-associated genes, but revealed that the patient was hemizygous for a missense variant in *CD40LG*, NM_000074.3: c.761C > T (NP_000065.1: p.Thr254Met). While the variant has not been reported in gnomAD and internal control-exome datasets, it has previously been described in multiple instances as causative for *CD40LG*-related immunodeficiency.^{8,9} The variant was classified as pathogenic in accordance with the ACMG recommendations¹⁰ and confirmed by Sanger sequencing, establishing a diagnosis of XHIGM in the patient.

On his most recent examination, the 46-year-old patient displayed features of cognitive dysfunction, with a Montreal Cognitive Assessment (MoCA) score of 17

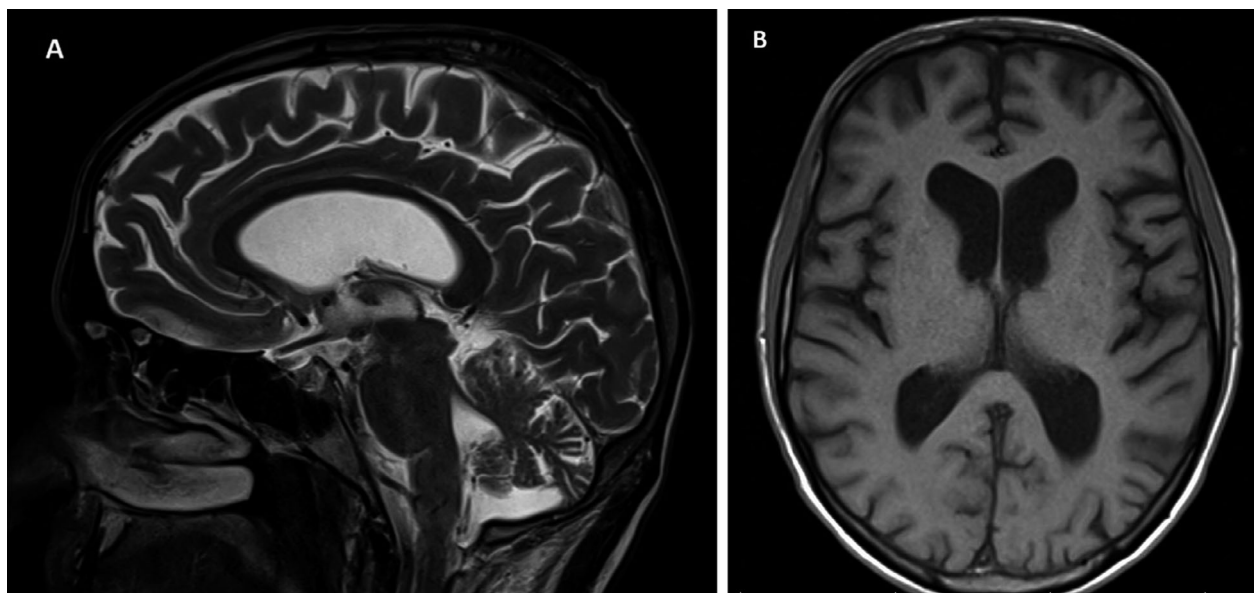


Figure 1. Brain MRI at the age of 45 years. (A) Sagittal T2 image and (B) axial T1 image showing supratentorial and infratentorial atrophy with enlarged lateral ventricles.

points (<26 points abnormal). He had cerebellar dysarthria, but his speech was fluent. Cranial nerve and oculomotor function testing revealed impaired vertical saccades with positive “Round the Houses” sign (inability to generate vertical saccades along the midline); he had perioral and mild lingual dyskinesia. His motor examination was dominated by generalized choreodystonia, with a particularly prominent choreatic component, and ataxia (both neo- and palleo-cerebellar syndrome) (see Video); he manifested limb dysmetria and dysdiadochokinesia. His gait was unsteady, slow, and wide-based, with significant risk of falls. Strength and deep-tendon reflexes were normal, as were examinations of muscle tone, pyramidal tract function, and sensation.

Discussion

CD40LG, located on chromosome Xq26.3, encodes the ligand of the immune system-related molecule CD40 (CD40 ligand, also known as CD40L, CD154, or gp39).¹¹ Preferentially expressed on activated T cells, the protein is of crucial importance for antibody class-switch recombination and the generation of high-affinity immunoglobulins. CD40 ligand deficiency has been shown to result in decreased abundance of immunoglobulin classes G, A, and E, while IgM levels are normal or elevated; various pathologies of cell-mediated immunity such as aberrant effector T-cell responses and macrophage activation deficits can also be observed.¹¹ Since the original description of *CD40LG*-related XHIGM in 1993,¹² a few hundred

individuals with pathogenic variations affecting the *CD40LG* locus have been described, including patients with deleterious missense, nonsense, frameshifting, and splice-altering alleles, as well as cases carrying intragenic deletions.¹¹ Transmitted as an X-linked trait, XHIGM is characterized by an array of immunological complications arising as a result of a combined immunodeficiency condition. Typical features, often manifesting during the first years of life comprise recurrent opportunistic infections involving the respiratory and gastrointestinal tracts, septicemia, and autoimmune manifestations.¹³ Phenotypic variability has been documented, attributed in part to variation-specific effects.¹⁴ Neurological symptoms are seen in less than 15% of affected patients.¹¹ In one of the largest XHIGM cohorts assembled to date,¹⁵ seven of 145 patients (5%) were described as having features consistent with nervous-system involvement such as cognitive impairment, speech disturbances, and ataxic/choreatic movements; a more detailed delineation of the latter association has not been provided in the corresponding publication.¹⁵ A specific relationship between XHIGM and the expression of a hyperkinetic movement disorder has been proposed in two smaller-scope studies.^{16,17} By investigating a group of nine individuals with ataxia telangiectasia-like phenotypes, Hasegawa and colleagues¹⁶ identified a pathogenic truncating *CD40LG* variant in a single patient who manifested progressive choreoathetosis in addition to an existing immunological defect syndrome with diminished IgG and elevated IgM levels. More recently, Coulter and colleagues¹⁷ described an individual with a

choreoathetoid generalized movement disorder and hyper-IgM-related immunodeficiency who was identified to have a pathogenic single-exon deletion of *CD40LG*. Brain MRI scans revealed neurodegenerative changes in both cases, with atrophy of the basal ganglia and the cerebral cortex in the first patient and global supratentorial volume loss in the second.^{16,17} Notably, the second case was also demonstrated to exhibit clinical response to pallidal deep brain-stimulation therapy, with significant reduction of abnormal movements after a 6-month follow-up¹⁷. Our patient displayed striking phenotypic overlap with these two previously published cases: he developed signs and symptoms compatible with XHIGM-related immunodeficiency in early childhood; the manifestation of an intractable hyperkinetic movement disorder affecting the trunk, craniocervical region, and all four limbs followed, although the age of onset was later than in the previously reported subjects (42 vs. 20 years¹⁶ and 13 years,¹⁷ respectively). The movement disorder showed prominent choreatic and dystonic elements, fulfilling clinical diagnostic criteria of a progressive generalized choreodystonic syndrome.^{2,18,19} Despite the convincing pathogenic nature of the *CD40LG* variant found in our patient, we cannot completely rule out a phenotype-relevant contribution of additional genetic lesions which may have gone undetected by our applied testing approaches (e.g., *C9orf72* repeat expansions were not specifically excluded). Nevertheless, the recurrence of highly similar immunodeficiency-movement disorder presentations in association to different *CD40LG* pathogenic alleles suggests the existence of a distinct entity, partially resembling more common forms of hereditary choreodystonia such as Huntington-like diseases and other conditions.²

The mechanisms through which *CD40LG* deleterious variants cause neurodegeneration are incompletely understood.^{11,17} Immunodeficiency-triggered opportunistic infections may be considered one explanation. On the other hand, accumulating evidence suggests that there is an intriguing, yet unexplored link between primary immunodeficiency disorders and encephalopathic changes in the absence of any infectious disease.⁴ For example, Ziegner and colleagues²⁰ described a series of 14 patients with various primary immunodeficiencies who were found to have profound neurodegeneration on imaging and postmortem analyses, while these complications had no apparent relation with a causative microorganism or opportunistic pathogen. Similar observations have been made in specific monogenic forms of immune function defects such as Bruton-type agammaglobulinemia caused by X-linked variants in *BTK* (OMIM#300755).²¹ Whether XHIGM-related neurodegeneration could be due to autoimmune reactions against neuronal tissue, as

discussed by some authors,¹⁷ remains to be further investigated.

Defining a diagnosis of *CD40LG*-related XHIGM in our patient was important for several reasons. First, detection of the causative variant enabled proper genetic counseling and potential future screenings for (asymptomatic) female carriers in the patient's family.¹¹ Second, significant information about the nature of disease and the associated complications was obtained, which will be useful for establishing tailored laboratory monitoring and supportive treatment strategies.¹¹ Finally, deep brain stimulation could emerge as a promising therapeutic intervention in XHIGM-related movement-disorder phenotypes.¹⁷

Conclusions

The combined manifestation of movement disorders and immunodeficiency is a rare clinical observation. Considered with two previous reports,^{16,17} our findings indicate that *CD40LG*-related XHIGM should be included in the differential diagnosis of choreo-dystonic/dyskinetic presentations occurring in association to compromised cellular and/or humoral immunity, in addition to more widely recognized conditions in this disease category such as ataxia telangiectasia⁵ and HIV-associated encephalopathy.^{22,23} Diagnoses of *CD40LG*-related choreodystonia should not be delayed or missed because of potential life-threatening immunological complications.

Acknowledgment

The authors are grateful to the patient who participated in this study. Open Access funding enabled and organized by Projekt DEAL.

Conflict of Interest

The authors declare that they have no conflict of interest.

Author Contribution

M.S. contributed to data acquisition and analysis and drafted a significant portion of the manuscript. R.J. and J.W. contributed with data acquisition and analysis and supervised the study. M.Z. contributed with design and conception of the study, data acquisition and analysis, supervised the study, and drafted a significant portion of the manuscript. All authors performed a critical review of the manuscript.

References

- Balint B, Mencacci NE, Valente EM, et al. Dystonia. *Dystonia Nat Rev Dis Primers*. 2018;4(1):25.

2. Martinez-Ramirez D, Walker RH, Rodriguez-Violante M, Gatto EM, Rare movement disorders study Group of International Parkinson's D. Review of hereditary and acquired rare Chorea. Tremor Other Hyperkinet Mov. 2020;6(10):24.
3. Shiloh Y, Rotman G. Ataxia-telangiectasia and the ATM gene: linking neurodegeneration, immunodeficiency, and cancer to cell cycle checkpoints. J Clin Immunol. 1996;16(5):254-260.
4. Yildirim M, Ayvaz DC, Konuskan B, et al. Neurologic involvement in primary immunodeficiency disorders. J Child Neurol. 2018;33(5):320-328.
5. Rothblum-Oviatt C, Wright J, Lefton-Greif MA, McGrath-Morrow SA, Crawford TO, Lederman HM. Ataxia telangiectasia: a review. Orphanet J Rare Dis. 2016;11(1):159.
6. Papapetropoulos S, Friedman J, Blackstone C, Kleiner GI, Bowen BC, Singer C. A progressive, fatal dystonia-parkinsonism syndrome in a patient with primary immunodeficiency receiving chronic IVIG therapy. Mov Disord. 2007;22(11):1664-1666.
7. Zech M, Jech R, Boesch S, et al. Monogenic variants in dystonia: an exome-wide sequencing study. Lancet Neurol. 2020;19(11):908-918.
8. Landrum MJ, Lee JM, Benson M, et al. ClinVar: public archive of interpretations of clinically relevant variants. Nucleic Acids Res. 2016;44(D1):D862-D868.
9. Stenson PD, Mort M, Ball EV, et al. The human gene mutation database: towards a comprehensive repository of inherited mutation data for medical research, genetic diagnosis and next-generation sequencing studies. Hum Genet. 2017;136(6):665-677.
10. Richards S, Aziz N, Bale S, et al. Standards and guidelines for the interpretation of sequence variants: a joint consensus recommendation of the American College of Medical Genetics and Genomics and the Association for Molecular Pathology. Genet Med. 2015;17(5):405-424.
11. Dunn CP, de la Morena MT. X-linked hyper IgM syndrome. In: Adam MP, Ardinger HH, Pagon RA, et al., editors. GeneReviews(R). University of Washington; 1993. <https://www.ncbi.nlm.nih.gov/books/NBK1402/>
12. Allen RC, Armitage RJ, Conley ME, et al. CD40 ligand gene defects responsible for X-linked hyper-IgM syndrome. Science. 1993;259(5097):990-993.
13. Du X, Tang W, Chen X, et al. Clinical, genetic and immunological characteristics of 40 Chinese patients with CD40 ligand deficiency. Scand J Immunol. 2019;90(4):e12798.
14. Franca TT, Leite LFB, Maximo TA, et al. A novel de novo mutation in the CD40 ligand gene in a patient with a mild X-linked hyper-IgM phenotype initially diagnosed as CVID: new aspects of old diseases. Front Pediatr. 2018;6:130.
15. Leven EA, Maffucci P, Ochs HD, et al. Hyper IgM syndrome: a report from the USIDNET registry. J Clin Immunol. 2016;36(5):490-501.
16. Hasegawa S, Imai K, Yoshida K, et al. Whole-exome sequence analysis of ataxia telangiectasia-like phenotype. J Neurol Sci. 2014;340(1-2):86-90.
17. Coulter IC, Yan H, Gorodetsky C, et al. Childhood choreoathetosis secondary to hyper-IgM syndrome (CD40 ligand deficiency). Neurol Neuroimmunol Neuroinflamm. 2020;7(6):e899.
18. Abdo WF, van de Warrenburg BP, Burn DJ, Quinn NP, Bloem BR. The clinical approach to movement disorders. Nat Rev Neurol. 2010;6(1):29-37.
19. Albanese A, Bhatia K, Bressman SB, et al. Phenomenology and classification of dystonia: a consensus update. Mov Disord. 2013;28(7):863-873.
20. Ziegner UH, Kobayashi RH, Cunningham-Rundles C, et al. Progressive neurodegeneration in patients with primary immunodeficiency disease on IVIG treatment. Clin Immunol. 2002;102(1):19-24.
21. Sag AT, Saka E, Ozgur TT, et al. Progressive neurodegenerative syndrome in a patient with X-linked agammaglobulinemia receiving intravenous immunoglobulin therapy. Cogn Behav Neurol. 2014;27(3):155-159.
22. Abbruzzese G, Rizzo F, Dall'Agata D, Morandi N, Favale E. Generalized dystonia with bilateral striatal computed-tomographic lucencies in a patient with human immunodeficiency virus infection. Eur Neurol. 1990;30(5):271-273.
23. Tse W, Cersosimo MG, Gracies JM, Morgello S, Olanow CW, Koller W. Movement disorders and AIDS: a review. Parkinsonism Relat Disord. 2004;10(6):323-334.

Supporting Information

Additional supporting information may be found online in the Supporting Information section at the end of the article.

Data S1. List of 241 ataxia-linked genes tested in the patient's initial panel approach.

Video S1. Our patient with pathogenic *CD40LG* variant presenting with generalized choreodystonia and ataxia.