

Case Report

Two Case Reports of Subacute Thyroiditis after Receiving Vaccine for COVID-19

Jan Adelmeyer ¹, Joachim Nils Goebel,¹ Alexander Kauka,² and Peter Herbert Kann¹

¹Philipps-University Marburg, Endocrinology Baldingerstraße, 35043 Marburg, Germany

²General Practice Grosseelheim, Grosseelheim 35274, Germany

Correspondence should be addressed to Jan Adelmeyer; adelmeyer@med.uni-marburg.de

Received 10 November 2021; Revised 6 March 2022; Accepted 25 March 2022; Published 14 April 2022

Academic Editor: J. Paul Frindik

Copyright © 2022 Jan Adelmeyer et al. This is an open access article distributed under the Creative Commons Attribution License, which permits unrestricted use, distribution, and reproduction in any medium, provided the original work is properly cited.

The ongoing COVID-19 pandemic, caused by a coronavirus named SARS-CoV-2, has struck the planet with great force. As of December 2019, the virus has made its devastating route across all continents. In January 2022, the World Health Organization (WHO) registered over 5.5 million COVID-19 related deaths. Most of these people had suffered from pneumonia and acute respiratory distress syndrome, and in some cases, extensive damage to all organ systems. To get hold of this pandemic, it was vital to find effective vaccines against it. The two vaccine candidates BNT162b2 (BioNTech/Pfizer) and ChAdOx1 (University of Oxford and AstraZeneca) offer a high level of protection against COVID-19 by providing immunity due to antibody production against the spike protein of SARS-CoV-2. In addition to general side effects, immunological side effects such as subacute thyroiditis can follow the vaccination. This transient inflammatory condition of the thyroid gland is characterized with hyperthyroxinemia, inflammation, pain, and tenderness in the thyroid region, as well as an elevation of serum thyroglobulin concentration. There are only a few reports on the occurrence of this disease after receiving a COVID-19 vaccine. We present two cases of subacute thyroiditis after vaccination with the vaccines BNT162b2 and ChAdOx1 and try to enlighten the problem of immunological phenomena after vaccination. It must be discussed whether cross-reactivity of the spike protein and tissue proteins such as thyroid peroxidase (TPO), an “autoimmune/inflammatory syndrome by adjuvants” (ASIA), or the circulating spike protein itself after vaccination are responsible for the SAT.

1. Background

SAT, is an inflammatory disease of the thyroid gland [1-30], which primarily affects women and is manifested by pain and tenderness. Furthermore, patients mention fever, general malaise, myalgia, and arthralgia [10]. These typical clinical symptoms and the presence of elevated free thyroxine (fT4) and free triiodothyronine (fT3) with suppressed thyroid-stimulating hormone (TSH) as well as increased erythrocyte sedimentation rate (ESR) lead to the diagnosis of SAT. Symptoms of thyroid hormone excess may occur in the initial phase, and hypothyroidism affects about 5–10% of patients at annual follow-up [31].

The thyroid gland appears mostly focally hypoechoic and of normal or enlarged size with no hypervascularity on ultrasound [32]. In addition, ^{99m}Tc-pertechnetate uptake is

markedly reduced, indicating an inadequate metabolic pathway during inflammation [33].

To date, there is no known definitive cause for this disease. There are some studies that show an association between SAT and HLA-B35 in several ethnic groups, as well as a family-related occurrence [34]. Previous viral infections, such as influenza, coxsackie virus, and mumps virus, have been discussed as potential causes for a long time, but so far this has not been proven with absolute certainty [35]. This theory is partly supported by observing the seasonal occurrence of the SAT from summer to early autumn in some studies [36, 37]. The search for a viral infection is often useless unless there is a therapeutic consequence for the viral disease as such.

Recently, there have been several case reports that showed the occurrence of SAT after infection with SARS-

TABLE 1: A review of previously published cases of SAT associated with vaccination against SARS-CoV-2. Only SAT cases from each manuscript are listed in this table.

Reference	Gender	Age	Vaccine	Dose	Time from vaccination until onset of symptoms	Symptoms	History of thyroid disease	ft3	ft4	TSH	ESR (mm) (RR < 15)	TgAb	TRAb	TPO-ab
Our case 1	F	36	BNT162b2 (Comirnaty®)	2 nd	1 day	Neck pain, restlessness, fatigue	None	↔	↔	↔	44	Neg	Neg	Neg
Our case 2	M	65	ChAdOx1 (Vaxzevria®)	1 st	3 days	Malaise	None	↔	↔	↓	21	Pos	Neg	Neg
Iremli et al. [11]														
Case 1	F	35	PiCoVacc (CoronaVac®)	2 nd	4 days	Left-side anterior neck pain, fever, fatigue, palpitations	None	↑	↔	↔	53	Neg	Neg	Neg
Case 2	F	34	PiCoVacc (CoronaVac®)	1 st	4 days	Anterior neck pain, fever, fatigue, palpitations	None	↑	↓	↓	19	Neg	Neg	Neg
Case 3	F	37	PiCoVacc (CoronaVac®)	2 nd	7 days	Mild anterior neck pain	None	↑	↔	↔	25	Neg	Neg	Neg
Reference	Gender	Age	Vaccine	Dose	Days until symptoms	Symptoms	History of thyroid disease	ft3	ft4	TSH	ESR (mm) (RR < 15)	TgAb	TRAb	TPO-Ab
Bornemann et al. [12]														
Case 1	F	26	ChAdOx1 (Vaxzevria®)	1 st	14 days	Fever, cervical pain radiated in both ears	None	↑	↔	↔	ND	Neg	Neg	Neg
Case 2	F	49	mRNA-1273 (Spikevax®)	1 st	14 days	Sore throat with radiation to the ear, headache	None	↔	↔	↔	ND	Neg	Neg	Neg
Patel et al. [13]														
	M	48	ND	2 nd	7 days	Right neck swelling, throat discomfort, palpitations, fever, weight loss	ND	ND	3.6 ng/dl (no RR)	0.01 mIU/L (no RR)	ND	ND	ND	ND
Reference	Gender	Age	Vaccine	Dose	Days until symptoms	Symptoms	History of thyroid disease	ft3	ft4	TSH	ESR (mm) (RR < 15)	TgAb	TRAb	TPO-ab
Saygili et al. [14]														
	F	38	PiCoVacc (CoronaVac®)	2 nd	14 days	Neck swelling, pain, fatigue, loss of appetite, sweating	None	↑	↔	↓	78	Neg	ND	Neg
	F	34	BBV152 (COVAXIN®)	1 st	5-7 days	Fever, palpitation, anterior neck pain	None	↑	↑	↓	60	ND	ND	ND
Chatzi et al. [15]														
	F	35	BNT162b2 (Comirnaty®)	1 st	12 days	Neck pain, fatigue, palpitations	ND	ND	↑	↓	75	Neg	Neg	Neg
	F	32	BNT162b2 (Comirnaty®)	2 nd	4 days	Neck pain, fatigue	ND	ND	↔	↓	40	Neg	Neg	Neg

TABLE 1: Continued.

Reference	Gender	Age	Vaccine	Dose	Time from vaccination until onset of symptoms	Symptoms	History of thyroid disease	ft3	ft4	TSH	ESR (mm) (RR < 15)	TgAb	TRAb	TPO-ab	
Kyriacou et al. 10/21 [16]	F	40	BNT162b2 (Comirnaty®)	2 nd	12 hours	Malaise, anterior neck pain,	None	ND	↑	↓	67	Pos	Neg	Neg	
Siolos et al. [17]	F	51	BNT162b2 (Comirnaty®)	1 st	4 days	Nausea, mild anterior neck pain, fever	None	↔	↑	↓	103	Neg	Neg	Neg	
Reference Jeeyavudeen et al. [18]	Gender	Age	Vaccine	Dose	Days until symptoms	Symptoms	History of thyroid disease	ft3	ft4	TSH	ESR (mm) (RR < 15)	TgAb	TRAb	TPO-ab	
Plaza-Enriquez et al. [19]	F	ND	BNT162b2 (Comirnaty®)	2 nd	14 days	Painful swelling, poor sleep, night sweats, hyperdefecation, weight loss	None	↑	↑	↓	ND	Neg	ND	Neg	
Reference Khan et al. [20]	F	42	mRNA-1273 (Spikevax®)	2 nd	5-6 days	Earache radiating down to the neck and jaw,	None	↑	↔	↓	81	ND	ND	Neg	
Sözen et al. [21]	Gender	Age	Vaccine	Dose	Days until symptoms	Symptoms	History of thyroid disease	ft3	ft4	TSH	ESR (mm) (RR < 15)	TgAb	TRAb	TPO-ab	
Reference Khan et al. [20]	F	42	BNT162b2 (Comirnaty®)	2 nd	4 days	Fever, palpitations, painful left-sided neck swelling	ND	ND	↑	↓	60	ND	Neg	Neg	
Reference Sözen et al. [21]	M	41	BNT162b2 (Comirnaty®)	2 nd	8 days	Anterior neck pain, fatigue, palpitation	None	↑	↑	↓	32	Neg	Neg	Neg	
Reference Sözen et al. [21]	F	40	BNT162b2 (Comirnaty®)	1 st	6 days	Neck pain, palpitation, sweating	None	↔	↔	↓	34	Pos	Neg	Neg	
Reference Sözen et al. [21]	M	40	BNT162b2 (Comirnaty®)	1 st	4 days	Neck pain, nervousness, fatigue	None	↔	↔	↔	15	Neg	ND	Neg	
Reference Khan et al. [20]	Gender	Age	Vaccine	Dose	Days until symptoms	Symptoms	History of thyroid disease	ft3	ft4	TSH	ESR (mm) (RR < 15)	TgAb	TRAb	TPO-Ab	
Reference Sözen et al. [21]	F	26	BNT162b2 (Comirnaty®)	2 nd	6 days	Neck pain	None	↑	↑	↓	34	Pos	Neg	Pos	

TABLE 1: Continued.

Reference	Gender	Age	Vaccine	Dose	Time from vaccination until onset of symptoms	Symptoms	History of thyroid disease	ft3	ft4	TSH	ESR (mm) (RR < 15)	TgAb	TRAb	TPO-ab
Schimmel et al. [22]	F	44	BNT162b2 (Comirnaty®)	2 nd	9 days	Neck pain, headache, palpitation, sweating, tremor	Hashimoto thyroiditis	↔	↔	↓	44	Neg	Neg	Pos
Franquemont et al. [23]	F	57	BNT162b2 (Comirnaty®)	2 nd	1 day	Anterior neck pain, swelling	None	↔	↔	↓	ND	Neg	Neg	Neg
	F	42	BNT162b2 (Comirnaty®)	1 st	5 days	Sore throat, palpitations	None	11.8 (no RR)	4.58 (no RR)	<0.01 (no RR)	62	Neg	Neg	Neg
Reference	Gender	Age	Vaccine	Dose	Days until symptoms	Symptoms	History of thyroid disease	ft3	ft4	TSH	ESR (mm) (RR < 15)	TgAb	TRAb	TPO-ab
Oyibo et al. [24]	F	55	ChAdOx1 (Vaxzevria®)	1 st	21 days	Headache, sore throat, generalized aches, palpitations	None	ND	↑	↓	51	ND	ND	Neg
Sahin Tekin et al. [25]	M	67	PiCoVacc (CoronaVac®)	2 nd	19 days	Fever, mild neck pain,	None	↑	↑	↓	67	Neg	Neg	Neg
Reference	Gender	Age	Vaccine	Dose	Days until symptoms	Symptoms	History of thyroid disease	ft3	ft4	TSH	ESR (mm) (RR < 15)	TgAb	TRAb	TPO-ab
Pla Peris et al. [26]	M	67	mRNA-1273 (Spikevax®)	1 st	10–14 days	Neck pain radiating to the ears, asthenia, mild fever, tachykardia	None	ND	↑	↓	60	Neg	Neg	Pos
	M	47	BNT162b2 (Comirnaty®)	1 st	10–14 days	Neck pain radiating to the ears, asthenia, mild fever, tachykardia	None	ND	↔	↓	70	Neg	Neg	Neg

Note: the pathological values are printed in bold. ft3: free triiodothyronine; ft4: free thyroxine; TSH: thyroid-stimulating hormone; ESR: erythrocyte sedimentation rate; TgAb: antithyroglobulin antibody; TRAb, TSH receptor antibodies; TPO-Ab: thyroid peroxidase antibody; pos: positive; neg: negative; ND: no data; RR: reference range; ↔: normal; ↑: increased; ↓: decreased.

CoV-2 [38]. However, not only could the infection itself trigger SAT, but also the new vaccines are suspected of causing this thyroidal dysfunction [11–26].

We present two additional cases of SAT following vaccination with BNT162b2 (BioNTech/Pfizer) and ChAdOx1 (University of Oxford and AstraZeneca).

2. Case Presentation I

A 36-year old woman presented to our endocrinology outpatient clinic in April 2021, four weeks after receiving her second vaccine dose against COVID-19 with BNT162b2 (BioNTech/Pfizer, Comirnaty®). She reported that she had developed neck pain one day after receiving this second dose.

Following symptom onset, she had presented to an ear, nose, and throat doctor. After a laryngoscopy, which found no pathological findings, the doctor performed an ultrasound examination of the thyroid gland, which was assessed to be abnormal. In addition, there was an increased C-reactive protein (CRP), leukocytosis, and an increased thyroglobulin in the external blood tests, so the colleague began a three-day therapy with prednisolone 60 mg/d to treat his suspected diagnosis of SAT. A few hours after starting this treatment the pain disappeared but returned shortly after prednisolone was discontinued. The symptoms worsened over the following weeks, so the woman presented herself in our endocrinology outpatient clinic for further examination and treatment advice. At that time, the patient complained about neck pain, restlessness, as well as fatigue.

She did not have any known preexisting diseases, especially no previous history or family history of thyroid disease or COVID-19. The patient was a cigarette smoker.

2.1. Investigation. At examination, she was 170 cm tall and weighed approximately 55 kilograms (body mass index, 19 kg/m²). There were no pathological findings regarding heart rate, blood pressure, and temperature. The neck pain could be induced by palpating the thyroid gland. Our initial biochemical blood tests showed a slight leukocytosis as well as moderately increased CRP and significantly increased ESR. In addition, there was a markedly elevated thyroglobulin level with normal fT₄, fT₃, and TSH indicating an euthyroid state, most likely due to the fact that the patient presented four weeks after the onset of symptoms. No thyroid peroxidase autoantibodies (TPO-Ab), TSH receptor stimulating antibodies (TRAb), or antithyroglobulin antibodies (TgAb) were detected (Table 1).

Ultrasound examination of the thyroid gland showed a hypoechoic texture with pseudonodular lesions (Figure 1). The volume was about 18 ml, and some enlarged nonsuspicious lymph nodes were seen. The appearance was typical for SAT, and the pain could be induced by pressure with the ultrasound probe right above the thyroid gland. There was no evidence of a current corona infection in the rapid antigen test.

2.2. Treatment. Based on strong evidence suggesting SAT with normal thyroidal function at presentation, we discussed the treatment options with our patient. We offered her therapy with nonsteroidal anti-inflammatory drugs (NSAIDs) or a longer course of prednisolone therapy. She decided on the former, and we advised her to begin a prednisolone therapy if there was no improvement on NSAID with a starting dose of 30 mg/d with tapering the daily dosage by 5 mg every 5–7 days.

2.3. Outcome and Follow-Up. During a telephone call two weeks later, the patient reported that the neck pain had worsened while she was taking ibuprofen and that she had developed subfebrile temperatures. Therefore, as recommended, she started prednisolone therapy, which promptly resulted in improvement. She took prednisolone in a tapering scheme over six weeks. The symptoms did not return after stopping the prednisolone, and she has been fine. An intermittent unintentional weight loss of five kilograms was also resolved. The ultrasound examination showed an almost complete recovery. Thyroglobulin decreased by about 75%, and the CRP was normal. Mild leukocytosis may have been explained by smoking. Her thyroid function tests still showed an euthyroid state.

3. Case Presentation II

A 65-year old man visited his family doctor in June 2021 because of malaise after receiving his first vaccine against COVID-19 with ChAdOx1 (University of Oxford and AstraZeneca, Vaxzevria®) three days before. Due to an increase in CRP and an increased ESR, the doctor suspected another sigmoid diverticulitis because of several episodes since 2018. The patient also complained of pain in the thyroid region and hoarseness; in secondary findings, a decreased TSH was detected. Therefore, a referral to our endocrinology outpatient clinic was arranged. At the time of the appointment, the local symptoms were decreasing and the patient was fine. There was no history of thyroid disease, neither in the patient nor in their family.

3.1. Investigation. The man was in good condition. Blood pressure was normal, and the heart rate was moderately elevated (100 bpm). Due to decreased appetite, he had lost eight kilograms. The thyroid gland was slightly enlarged and palpable without tenderness. Blood examination revealed moderately elevated CRP, normal white blood cell count, mild normochromic normocytic anemia, and elevated ESR. In addition, there was a reduced TSH with normal fT₃ and fT₄ and increased TgAb, which we assessed as unspecific (Table 1). Other antibodies related to the thyroid gland were negative (TRAb and TPO-Ab).

Ultrasound examination of the thyroid showed a hypoechoic texture and a diffusely hypoperfused parenchyma. The volume was slightly enlarged (36 ml) and there were some enlarged nonsuspicious lymph nodes (Figure 2). A COVID-19 rapid antigen test was negative.

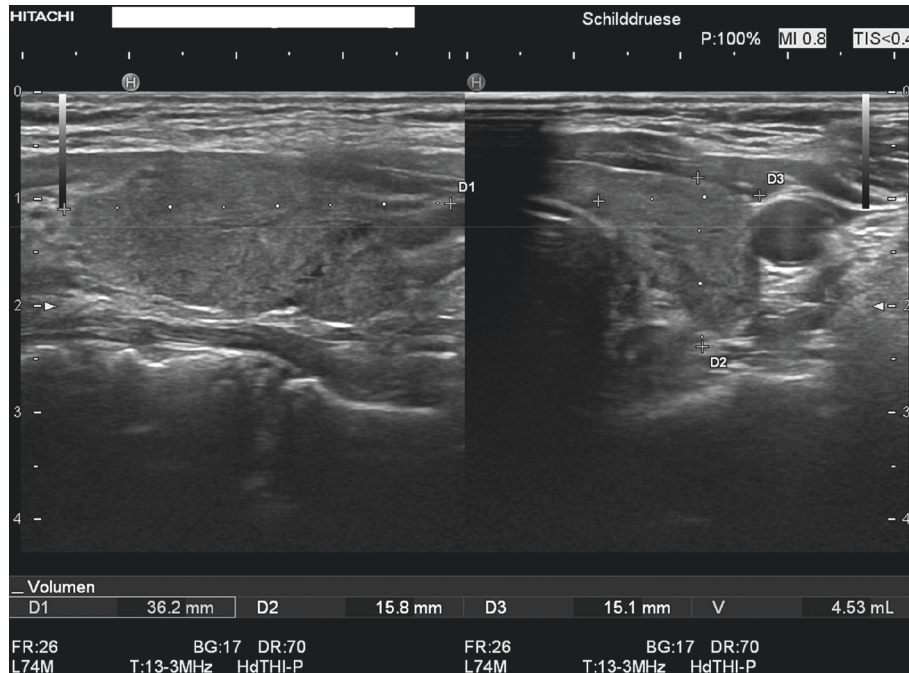


FIGURE 1: This ultrasound picture shows a hypoechoic texture with pseudonodular lesions typical for SAT.

3.2. Treatment. No special treatment was required because of the regressive symptoms.

3.3. Outcome and Follow-Up. At the recommended appointment three months later, the patient felt well. Blood tests showed mild anemia but no more signs of inflammation, and the TSH was normalized. Sonographic examination of the thyroid gland showed a reduced volume. There was no tenderness or pressure on the thyroid region.

4. Discussion

The current COVID-19 pandemic is causing various medical problems. In addition to the main infections, e.g., lung infection, the infection affects the entire body system. Initial studies by Somasundaram et al. in June 2020 suggested possible damage to the endocrine system by SARS-CoV-2 [39]. Only a few months later, the first reports underscored this suspicion [40]. The thyroid gland could be affected by several mechanisms.

First of all, the virus enters human tissues using the angiotensin-converting enzyme 2 (ACE2) as a cell receptor, which is strongly expressed in thyroid cells and can probably damage the thyroid gland by direct viral cytopathic effects [41, 42]. Early research had shown that there are some homologies between amino acid sequences of, e.g., the spike glycoprotein subunits S1 and S2 from the virus and tissue proteins such as thyroid peroxidase (TPO). This can cause autoimmunity against thyroid cells or exacerbate an existing autoimmunity [43].

In addition, uncontrolled immune responses to the virus in severe cases of COVID-19 should be discussed. This leads to an extensive inflammatory state and an enhanced Th1/

Th17 immune response, which results in the release of inflammatory cytokines that are also seen in autoimmune thyroid diseases [44].

Furthermore, the exact pathomechanism of SAT in general is unknown. It is hypothesized that autoreactive T-cells generated by molecular mimicry on thyroid cells promote an autoimmune response against the thyroid gland. Another explanation is that a virus infection results in the presentation of viral products or virus antigens by host cells. As a result, the thyroid cells are recognized as foreign and destroyed by the immune system [45].

But the infection by the virus itself is not only discussed as a cause of SAT. The occurrence of this disease has also been detected after the injection of the new vaccines [11–26]. Recent studies show that the spike protein could be detected in subjects after administration of the mRNA vaccine [30] because both vaccines lead to endogenous production of these spike proteins through different mechanisms to induce immunity against SARS-CoV-2 [6, 7].

In addition, animal experiments have shown that this protein alone can cause cell damage [29]. Since the thyroid cells, as already described, show a high level of expression of the ACE2 receptor, which serves as a cell receptor, direct damage by the protein could be an explanation. However, this theory should be explored in more detail in further studies, and of course, the idea cannot be applied to other vaccinations (e.g., influenza) and the occurrence of SAT.

Another explanation that should be mentioned is the “autoimmune/inflammatory syndrome by adjuvants” known as ASIA. Bragazzi et al. summarized 50 cases of SAT after vaccination that were attributed to this syndrome [28]. Adjuvants are substances that can increase the effectiveness of vaccines and, in some cases, can cause relevant damage by triggering immunological phenomena through activation of

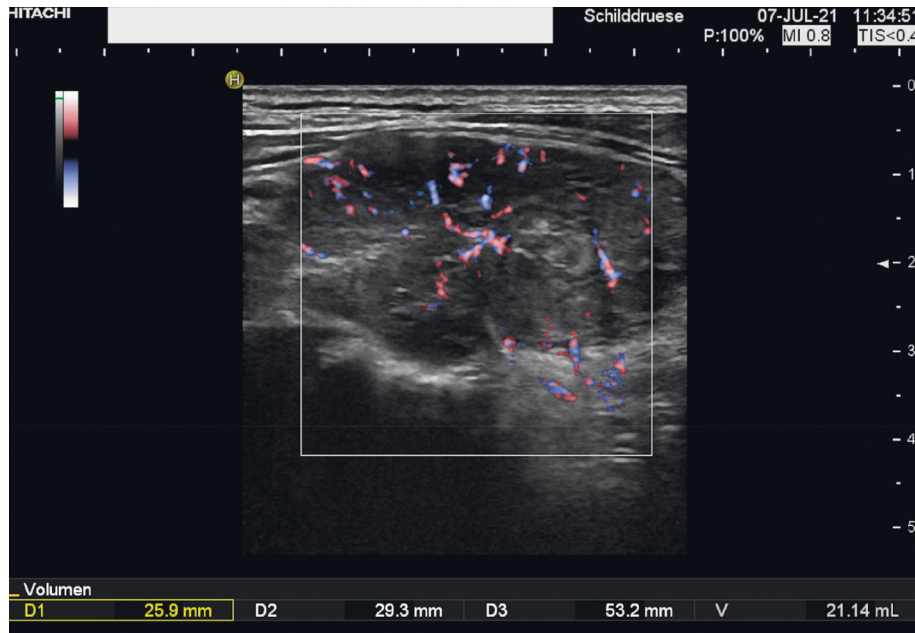


FIGURE 2: The right lobe of the thyroid gland with a hypoechoic texture and a diffusely hypoperfused parenchyma.

B lymphocytes or molecular mimicry [46]. In the case of the vaccine BNT162b2 (BioNTech/Pfizer), lipid nanoparticles (e.g., ALC-0159) have an adjuvant effect in terms of stabilizing the mRNA and transporting it to the target site [47, 48]. In contrast, the vaccine ChAdOx1 (the University of Oxford and Astra-Zeneca) does not contain any relevant adjuvant substances in the true sense [49] but processed polysorbate 80 (E 433), which is part of AS03, an adjuvant of influenza vaccines [50].

So, ASIA could also be a possible cause of the development of SAT after vaccination against COVID-19. However, ASIA cannot explain the association of SAT with the infection itself.

To our knowledge, there have been publications of 26 cases of SAT following vaccination against SARS-CoV-2 [11–26].

Our cases are in line with the published cases of SAT after COVID-19 vaccination so far (Table 1). The typical clinical presentation with neck pain and malaise, as well as the ultrasound of the thyroid gland and the time since administration (1–3 days), confirm the diagnosis of vaccination-associated SAT. In contrast to most of the cases reported in the literature, our first patient had completely normal thyroid function due to a longer history since the onset of symptoms. Among the 26 cases, there are three others who were euthyroid, and only 62% of the patients had hyperthyroidism. The positive TgAb in our second case was interpreted as unspecific. Nishihara et al. 2019 examined 40 patients in the early phase of SAT and were able to show that 52.5% had positive TgAb, which decreased over time [37]. Three of the 26 cases of vaccine-associated SAT also had positive TgAb.

We must note that although we ruled out corona infection by antigen testing, we did not arrange for further virologic testing for other pathogens. However, there was no evidence of infection.

We would like to point out that, based on the accumulation of case reports, SAT appears to be a possible but rare sequelae of SARS-CoV-2 vaccination that should be considered by practicing physicians. The course of SAT is often mild and disproportionate to the harmfulness of COVID-19 but may be important because of the substantial increase in the global vaccination rate, with more than 9.5 billion doses of vaccine administered [4].

Nevertheless, temporal findings can be no proof of a causal relationship. To date, there have been many reports of SAT following SARS-CoV-2 infection. But a study from a region in northern Italy heavily affected by SARS-CoV-2 could not document a rise in cases of SAT in their outpatient emergency clinic during the pandemic [51]. Likewise, the temporal association of the reported cases of SAT after vaccination against SARS-CoV-2 could still be a coincidence.

Because case reports can only raise suspicion of a causal relationship, studies should compare the incidence of SAT in the weeks after vaccination with an unvaccinated group or with the incidence of SAT before vaccination. In addition, when SAT is diagnosed in temporal association with vaccine use, physicians should make a report to the appropriate pharmacovigilance institution.

Data Availability

The data used to support the findings of this study are included within the article.

Additional Points

Subacute thyroiditis (SAT) is a temporary inflammatory disease of the thyroid gland that is probably triggered by multiple viral infections with a genetic predisposition to HLA-B35. In the past, the occurrence of SAT has been

described, for example, after influenza vaccination. Recently, several reports have described the appearance of SAT as being associated with the injection of the new COVID-19 vaccines. Cross-reactivity between the spike protein and tissue proteins of the thyroid gland, ASIA, or the circulating spike protein as a cause for SAT after vaccination should be discussed.

Consent

Written informed consent has been obtained from the patient (or patient's guardian) for publication of the submitted article and accompanying images.

Conflicts of Interest

The authors declare no conflicts of interest.

Authors' Contributions

The patients described were medically advised by Dr. Kauka, Goebel, and Prof. Kann, who gave full approval. The cases were presented by Dr. Adelmeyer.

References

- [1] N. Zhu, D. Zhang, W. Wang et al., "A novel coronavirus from patients with pneumonia in China, 2019," *New England Journal of Medicine*, vol. 382, no. 8, pp. 727–733, 2020.
- [2] S. K. Mishra and T. Tripathi, "One year update on the COVID-19 pandemic: where are we now?" *Acta Tropica*, vol. 214, Article ID 105778, 2021.
- [3] C. R. Triggler, D. Bansal, H. Ding et al., "A comprehensive review of viral characteristics, transmission, pathophysiology, immune response, and management of SARS-CoV-2 and COVID-19 as a basis for controlling the pandemic," *Frontiers in Immunology*, vol. 12, Article ID 631139, 2021.
- [4] W. H. Organisation, *WHO Coronavirus (COVID-19) Dashboard*, <https://covid19.who.int/22>, 2022.
- [5] P. Zhou, X.-L. Yang, X.-G. Wang et al., "A pneumonia outbreak associated with a new coronavirus of probable bat origin," *Nature*, vol. 579, no. 7798, pp. 270–273, 2020.
- [6] F. P. Polack, S. J. Thomas, N. Kitchin et al., "Safety and efficacy of the BNT162b2 mRNA covid-19 vaccine," *New England Journal of Medicine*, vol. 383, no. 27, pp. 2603–2615, 2020.
- [7] M. Voysey, S. A. C. Clemens, S. A. Madhi et al., "Safety and efficacy of the ChAdOx1 nCoV-19 vaccine (AZD1222) against SARS-CoV-2: an interim analysis of four randomised controlled trials in Brazil, South Africa, and the UK," *Lancet (London, England)*, vol. 397, no. 10269, pp. 99–111, 2021.
- [8] C. M. Girgis, R. R. Russo, and K. Benson, "Subacute thyroiditis following the H1N1 vaccine," *Journal of Endocrinological Investigation*, vol. 33, no. 7, Article ID 506, 2010.
- [9] F. A. Altay, G. Güz, and M. Altay, "Subacute thyroiditis following seasonal influenza vaccination," *Human Vaccines & Immunotherapeutics*, vol. 12, no. 4, pp. 1033–1034, 2016.
- [10] K. R. Feingold, B. Anawalt, A. Boyce, G. Chrousos, W. W. de Herder, and K. Dhatariya, *Endotext Review*, 2000.
- [11] B. G. İremli, S. N. Şendur, and U. Ünlütürk, "Three cases of subacute thyroiditis following SARS-CoV-2 vaccine: post-vaccination ASIA syndrome," *The Journal of Clinical Endocrinology and Metabolism*, vol. 106, no. 9, 2021.
- [12] C. Bornemann, K. Woyk, and C. Bouter, "Case report: two cases of subacute thyroiditis following SARS-CoV-2 vaccination," *Frontiers of Medicine*, vol. 8, Article ID 737142, 2021.
- [13] K. R. Patel, M. E. Cunnane, and D. G. Deschler, "SARS-CoV-2 vaccine-induced subacute thyroiditis," *American Journal of Otolaryngology*, vol. 43, no. 1, Article ID 103211, 2022.
- [14] E. S. Saygılı and E. Karakilic, "Subacute thyroiditis after inactive SARS-CoV-2 vaccine," *BMJ Case Reports*, vol. 14, no. 10, 2021.
- [15] S. Chatzi, A. Karampela, C. Spiliopoulou, and G. Boutzios, "Subacute thyroiditis after SARS-CoV-2 vaccination: a report of two sisters and summary of the literature," *Hormones*, vol. 21, no. 1, pp. 177–179, 2022.
- [16] A. Kyriacou, S. Ioakim, and A. A. Syed, "COVID-19 vaccination and a severe pain in the neck," *European Journal of Internal Medicine*, vol. 94, pp. 95–96, 2021.
- [17] A. Siolos, K. Gartzonika, and S. Tigas, "Thyroiditis following vaccination against COVID-19: report of two cases and review of the literature," *Metabolism Open*, vol. 12, Article ID 100136, 2021.
- [18] M. S. Jeeyavudeen, A. W. Patrick, F. W. Gibb, and A. R. Dover, "COVID-19 vaccine-associated subacute thyroiditis: an unusual suspect for de Quervain's thyroiditis," *BMJ Case Reports*, vol. 14, no. 11, 2021.
- [19] L. Plaza-Enriquez, P. Khatiwada, M. Sanchez-Valenzuela, and A. Sikha, "A case report of subacute thyroiditis following mRNA COVID-19 vaccine," *Case Rep Endocrinol*, vol. 2021, Article ID 8952048, 2021.
- [20] F. Khan and M. J. Brassill, "Subacute thyroiditis post-Pfizer-BioNTech mRNA vaccination for COVID-19," *Endocrinol Diabetes Metab Case Rep*, vol. 2021, 2021.
- [21] M. Sözen, Ö Topaloğlu, B. Çetinarslan et al., "COVID-19 mRNA vaccine may trigger subacute thyroiditis," *Human Vaccines & Immunotherapeutics*, vol. 17, no. 12, pp. 5120–5125, 2021.
- [22] J. Schimmel, E. L. Alba, A. Chen, M. Russell, and R. Srinath, "Letter to the editor: thyroiditis and thyrotoxicosis after the SARS-CoV-2 mRNA vaccine," *Thyroid*, vol. 31, no. 9, Article ID 1440, 2021.
- [23] S. Franquemont and J. Gálvez, "Subacute thyroiditis after mRNA vaccine for covid-19," *J Endocrine Society*, vol. 2021, no. 1, Article ID A956, 2021.
- [24] S. O. Oyibo, "Subacute thyroiditis after receiving the adenovirus-vectored vaccine for coronavirus disease (COVID-19)," *Cureus*, vol. 13, no. 6, Article ID e16045, 2021.
- [25] M. Şahin Tekin, S. Şaylısoy, and G. Yorulmaz, "Subacute thyroiditis following COVID-19 vaccination in a 67-year-old male patient: a case report," *Human Vaccines & Immunotherapeutics*, vol. 2021, pp. 1–3, 2021.
- [26] B. Pla Peris, A. Merchante Alfaro, F. J. Maravall Royo, P. Abellán Galiana, S. Pérez Naranjo, and M. González Boillos, "Thyrotoxicosis following SARS-COV-2 vaccination: a case series and discussion," *Journal of Endocrinological Investigation*, vol. 1-7, 2022.
- [27] S. Benvenga and F. Guarneri, "Molecular mimicry and autoimmune thyroid disease," *Reviews in Endocrine & Metabolic Disorders*, vol. 17, no. 4, pp. 485–498, 2016.
- [28] N. L. Bragazzi, A. Hejly, A. Watad, M. Adawi, H. Amital, and Y. Shoenfeld, "ASIA syndrome and endocrine autoimmune disorders," *Best Practice & Research Clinical Endocrinology & Metabolism*, vol. 34, no. 1, Article ID 101412, 2020.
- [29] Y. Lei, J. Zhang, C. R. Schiavon et al., "SARS-CoV-2 spike protein impairs endothelial function via downregulation of ACE 2," *Circulation Research*, vol. 128, no. 9, pp. 1323–1326, 2021.

- [30] A. F. Ogata, C. A. Cheng, M. Desjardins, Y. Senussi, A. C. Sherman, and M. Powell, "Circulating SARS-CoV-2 vaccine antigen detected in the plasma of mRNA-1273 vaccine recipients," *Clinical Infectious Diseases*, vol. 2021, 2021.
- [31] V. Fatourechhi, J. P. Aniszewski, G. Z. E. Fatourechhi, E. J. Atkinson, and S. J. Jacobsen, "Clinical features and outcome of subacute thyroiditis in an incidence cohort: olmsted County, Minnesota, study," *Journal of Clinical Endocrinology & Metabolism*, vol. 88, no. 5, pp. 2100–2105, 2003.
- [32] S. Y. Park, E.-K. Kim, M. J. Kim et al., "Ultrasonographic characteristics of subacute granulomatous thyroiditis," *Korean Journal of Radiology*, vol. 7, no. 4, pp. 229–234, 2006.
- [33] Y. Hiromatsu, M. Ishibashi, I. Miyake, and K. Nonaka, "Technetium-99m tetrofosmin imaging in patients with subacute thyroiditis," *European Journal of Nuclear Medicine and Molecular Imaging*, vol. 25, no. 10, pp. 1448–1452, 1998.
- [34] A. B. Kramer, C. Roozendaal, and R. P. F. Dullaart, "Familial occurrence of subacute thyroiditis associated with human leukocyte antigen-B35," *Thyroid*, vol. 14, no. 7, pp. 544–547, 2004.
- [35] R. Volpé, V. V. Row, and C. Ezrin, "Circulating viral and thyroid antibodies in subacute thyroiditis," *Journal of Clinical Endocrinology & Metabolism*, vol. 27, no. 9, pp. 1275–1284, 1967.
- [36] E. Martino, L. Buratti, L. Bartalena et al., "High prevalence of subacute thyroiditis during summer season in Italy," *Journal of Endocrinological Investigation*, vol. 10, no. 3, pp. 321–323, 1987.
- [37] E. Nishihara, H. Ohye, N. Amino et al., "Clinical characteristics of 852 patients with subacute thyroiditis before treatment," *Internal Medicine*, vol. 47, no. 8, pp. 725–729, 2008.
- [38] J. Christensen, K. O'Callaghan, H. Sinclair, K. Hawke, A. Love, and K. Hajkovicz, "Risk factors, treatment and outcomes of subacute thyroiditis secondary to COVID-19: a systematic review," *Internal Medicine Journal*, vol. 2021, 2021.
- [39] N. P. Somasundaram, I. Ranathunga, V. Ratnasamy et al., "The impact of SARS-cov-2 virus infection on the endocrine system," *Journal of the Endocrine Society*, vol. 4, no. 8, Article ID bvaa082, 2020.
- [40] N. Kothandaraman, A. Rengaraj, B. Xue et al., "COVID-19 endocrinopathy with hindsight from SARS," *American Journal of Physiology - Endocrinology And Metabolism*, vol. 320, no. 1, pp. E139–E150, 2021.
- [41] L. Scappaticcio, F. Pitoia, K. Esposito, A. Piccardo, and P. Trimboli, "Impact of COVID-19 on the thyroid gland: an update," *Reviews in Endocrine & Metabolic Disorders*, vol. 22, no. 4, 2020.
- [42] M. Rotondi, F. Coperchini, G. Ricci et al., "Detection of SARS-COV-2 receptor ACE-2 mRNA in thyroid cells: a clue for COVID-19-related subacute thyroiditis," *Journal of Endocrinological Investigation*, vol. 44, no. 5, pp. 1085–1090, 2021.
- [43] A. Vojdani, E. Vojdani, and D. Kharrazian, "Reaction of human monoclonal antibodies to SARS-CoV-2 proteins with tissue antigens: implications for autoimmune diseases," *Frontiers in Immunology*, vol. 11, Article ID 617089, 2020.
- [44] R. M. Ruggeri, A. Campenni, D. Deandreis et al., "SARS-COV-2-related immune-inflammatory thyroid disorders: facts and perspectives," *Expert Review of Clinical Immunology*, vol. 17, no. 7, pp. 737–759, 2021.
- [45] R. Domin, E. Szczepanek-Parulska, D. Dadej, and M. Ruchala, "Subacute Thyroiditis - literature overview and COVID-19," *JMS (Interent)*, vol. 89, no. 4, 2020.
- [46] A. Watad, N. L. Bragazzi, H. Amital, and Y. Shoenfeld, "Hyperstimulation of adaptive immunity as the common pathway for silicone breast implants, autoimmunity, and lymphoma of the breast," *The Israel Medical Association Journal: The Israel Medical Association Journal*, vol. 21, no. 8, pp. 517–519, 2019.
- [47] A. Khurana, P. Allawadhi, I. Khurana et al., "Role of nanotechnology behind the success of mRNA vaccines for COVID-19," *Nano Today*, vol. 38, Article ID 101142, 2021.
- [48] A. Pujol, L. A. Gómez, C. Gallegos, J. Nicolau, P. Sanchís, and M. González-Freire, "Thyroid as a target of adjuvant autoimmunity/inflammatory syndrome due to mRNA-based SARS-CoV2 vaccination: from Graves' disease to silent thyroiditis," *Journal of Endocrinological Investigation*, vol. 45, no. 4, 2021.
- [49] A. F. Hernández, D. Calina, K. Poulas, A. O. Docea, and A. M. Tsatsakis, "Safety of COVID-19 vaccines administered in the EU: should we be concerned?" *Toxicol Rep*, vol. 8, pp. 871–879, 2021.
- [50] C. Cohet, R. van der Most, V. Bauchau et al., "Safety of AS03-adjuvanted influenza vaccines: a review of the evidence," *Vaccine*, vol. 37, no. 23, pp. 3006–3021, 2019.
- [51] I. Pirola, E. Gandossi, M. Rotondi, F. Marini, A. Cristiano, and L. Chiovato, "Incidence of De Quervain's thyroiditis during the COVID-19 pandemic in an area heavily affected by Sars-CoV-2 infection," *Endocrine*, vol. 74, no. 2, 2021.