



Non-mass enhancement breast lesions: MRI findings and associations with malignancy

Gang Liu^{1#}, Ying Li^{1#}, Si-Lu Chen^{1,2}, Qiao Chen¹

¹Department of Radiology, The First Medical Center of Chinese PLA General Hospital, Beijing, China; ²Department of Radiology, The Seventh Medical Center of Chinese PLA General Hospital, Beijing, China

Contributions: (I) Conception and design: G Liu, Y Li; (II) Administrative support: G Liu; (III) Provision of study materials or patients: G Liu, Y Li; (IV) Collection and assembly of data: All authors; (V) Data analysis and interpretation: G Liu, Y Li, SL Chen; (VI) Manuscript writing: All authors; (VII) Final approval of manuscript: All authors.

[#]These authors contributed equally to this work and should be considered as co-first authors.

Correspondence to: Gang Liu. Department of Radiology, The First Medical Center of Chinese PLA General Hospital, Beijing, China.
Email: lgwzl@126.com.

Background: Magnetic resonance imaging (MRI) is a multi-sequence imaging technique. Although MRI is the most sensitive method for detecting breast cancer, it is limited in evaluating the malignant possibility of non-mass enhanced (NME) breast lesions. It is also rarely reported whether MRI can further indicate the invasion of the lesions. In this article, we explore the differentiation of MRI characteristics between benign and malignant NME lesions and determine which features are associated with invasion.

Methods: The MRI findings of 118 NME lesions were evaluated retrospectively to explore the characteristics of the benign and malignant NME lesions in different MRI sequences including dynamic contrast-enhanced (DCE) MRI and diffusion-weighted imaging (DWI). The difference of MRI findings between benign and malignant NME lesions were determined by Pearson χ^2 test or Fisher's exact test, and the diagnostic value of features for malignancy was evaluated by receiver operating characteristic (ROC) curve.

Results: This study included 118 NME lesions (62 benign and 56 malignant) in 118 patients. We found a segmental distribution, clustered-ring enhancement, wash-out dynamic curve, and lower apparent diffusion coefficient (ADC) value ($P=0.01$, <0.001 , 0.02 , 0.001) were associated with malignancy. Wash-out dynamic curves, diffusion restriction on DWI, lower ADC values were more advantageous in distinguishing invasive NME cancer from benign lesions than ductal carcinoma *in situ* (DCIS) ($P<0.001$, <0.001 , 0.027). Further analysis showed that there were statistical differences between invasive carcinoma and carcinoma *in situ* in terms of wash-out dynamic curves, diffusion restriction on DWI and lower ADC values ($P=0.001$, 0.014 , 0.024).

Conclusions: MRI is a valuable way to identify malignant NME lesions and could predict the invasion of the lesions. Compared with carcinoma *in situ*, some sequences have more advantages in distinguishing invasive carcinoma from benign lesions.

Keywords: Breast; magnetic resonance imaging (MRI); non-mass enhancement; invasion

Submitted Dec 22, 2021. Accepted for publication Mar 18, 2022.

doi: 10.21037/atm-22-503

View this article at: <https://dx.doi.org/10.21037/atm-22-503>

[^] ORCID: 0000-0003-3064-3149.

Introduction

According to the Breast Imaging-Reporting and Data System (BI-RADS), non-mass enhanced (NME) breast lesions on magnetic resonance imaging (MRI) is defined as an enhancement mode without space occupation effect, which can be distinguished from normal surrounding enhanced breast parenchyma. NME lesions include a series of entities, such as intraductal papilloma, atypical ductal hyperplasia, apocrine metaplasia, radial scar, and complex sclerosing lesions (1). While MRI is the most sensitive method to detect breast cancers, its diagnostic value is limited to NME breast lesions because of overlapping imaging findings between benign and malignant lesions, which may lead to unnecessary biopsy (2,3).

MRI is a multi-sequence imaging technique. Dynamic contrast enhanced magnetic resonance imaging (DCE-MRI) is the most important method for the detection of breast cancer, which can provide morphological and dynamic characteristics of the lesions. With the development of technology, diffusion-weighted imaging (DWI) has become a reliable auxiliary method for DCE-MR. However, compared with enhanced masses, DCE-MRI and DWI may have lower sensitivity and specificity in the diagnosis of NME lesions, which means that the diagnostic value is limited (4,5). The value of DCE-MRI and DWI in the diagnosis of invasion of NME lesions has also been rarely studied. Since post-operative carcinoma *in situ* may require reoperation if invasive elements are found, it is important to determine the invasion of the lesion. Our aim was to explore the characteristics of benign and malignant NME lesions and to determine which features are associated with invasions. We present the following article in accordance with the STARD reporting checklist (available at <https://atm.amegroups.com/article/view/10.21037/atm-22-503/rc>).

Methods

Patient selection

The study was conducted in accordance with the Declaration of Helsinki (as revised in 2013). The requirement for informed consent was waived in this retrospective study. The ethical approval was waived by the Ethics committee of the First Medical Center of Chinese PLA General Hospital. All breast lesions from March 1, 2018 to March 1, 2021 were retrospectively searched in The First Medical Center of Chinese PLA General Hospital. The inclusion criteria were as follows: (I) presence

as NME (BI-RADS 3–5) on MRI; (II) breast lesions with pathological results (Table 1); and (III) available clinical data. The exclusion criteria were as follows: (I) lesions being treated prior to examination; and (II) images that could not be accurately evaluated. Eventually, 118 patients with 118 lesions were enrolled and the NME lesions were diagnosed using excision biopsy or US-guided core needle biopsy (US-CNB). The 118 lesions included 56 malignant NME lesions (32 DCIS, 24 invasive carcinoma) and 62 benign NME lesions (14 adenosis, 8 fibroadenoma, 24 intraductal papilloma, and 16 inflammation).

MR imaging evaluation

The results were obtained with a 1.5 T Achieva (Philips, Netherland). All patients placed both breasts into a four-channel phased-array coil in the prone position using an MR protocol as follows: Axial turbo short time inversion recovery (STIR) T2-weighted Images (TR/TE, 8,000/60 ms; FOV read 350; 5 mm thickness; number of slices 20). The coronal spin-echo T1-weighted images (TR/TE, 500/10 ms; FOV read 350; thickness 2 mm; number of slices 30). The three-dimensional coronal T1-fast field echo (FFE) was used to acquire DCE-MR images after the intravenous injection of contrast agent Gd-DOTA (Gd-DTPA) at a rate of 2 mL/s followed by 20 mL of saline solution. The diffusion-weighted images (DWI) and apparent diffusion co-efficient (ADC) maps were acquired with the following parameters: TR ms/TE ms, 6,730/50; matrix 120×120; section thickness 5 mm; intersection gap 1.5 mm; Two b values of 50 and 1,000 s/mm².

MRI findings were analyzed independently by two radiologists with at least 5 years of experience, and who had no access to the clinical data. In cases where disagreement occurred, another radiologist re-evaluated the images until consensus was reached. Imaging parameters were collected by the American College of Radiology Breast Imaging Reporting and Data System MR imaging criteria.

On MRI, the following imaging parameters were observed. The type of distribution (focal, linear, segmental, regional, multiple regional, diffuse) and internal enhancement (homogeneous, heterogeneous, clumped and clustered-ring enhancement) were assessed by post-contrast axial image, maximum intensity projection (MIP) images, and radial multi-planar reconstruction (MPR). Dynamic curve modes were divided into three categories: the persistent pattern (type I), in which signal intensity increased continuously over time; the plateau pattern (type II), in which signal intensity did

Table 1 Pathologic category of NME lesions

Category	No.
Malignant	56
Ductal carcinoma <i>in situ</i>	32
Invasive ductal carcinoma	24
Benign	62
Adenosis	14
Fibroadenoma	8
Intraductal papilloma	24
Inflammation	16

NME, non-mass enhancement.

not vary with time after an initial increase in the delay phase; and the wash-out pattern (type III), in which signal intensity decreased after reaching its initial increase peak in the delay phase. The ADC threshold was $1.3 \times 10^{-3} \text{ mm}^2/\text{s}$ used as the cutoff between benign ($>1.3 \times 10^{-3} \text{ mm}^2/\text{s}$) and malignant ($\leq 1.3 \times 10^{-3} \text{ mm}^2/\text{s}$) lesions (6).

Statistical analysis

All statistical analyses were performed using SPSS, version 18.0 (SPSS, Chicago, IL, USA), and $P < 0.05$ was considered to show a significant difference. Pearson χ^2 test or Fisher's exact test were used to determine differences in MRI features between benign and malignant breast lesions, $P < 0.05$ (bilateral) is a prerequisite for Fisher's exact test. The receiver operating characteristic (ROC) curve was used to evaluate the diagnostic values of these features.

Results

We enrolled 118 patients into the study and their age ranged from 18–70 years old. Of the 118 NME breast lesions, there were 56 malignant lesions (32 DCIS, 24 invasive carcinoma) and 62 benign lesions (14 adenosis, 8 fibroadenoma, 24 intraductal papilloma, 16 inflammation).

MRI findings of the 118 breast lesions are shown in *Table 2*. Among the distribution characteristics of the NME breast lesions, segmental distribution and linear distribution were found to be statistically different between the benign and malignant lesions ($P < 0.05$). The segmental distribution was more common in malignant NME lesions (24/56, 42.9%), higher than that in the benign lesions (13/62, 21%). Of the

benign NME lesions, 12 (19.4%) showed linear distribution and only 1 (1.8%) of the malignant lesions showed linear distribution. Among the internal enhancement patterns, the frequency of cluster-ring enhancement (19/56, 33.9%) in malignancy was higher than in benign lesions, which was statistically significant ($P < 0.05$). The sensitivity and specificity of internal enhancement model for predicting malignant NME lesions were 73.2% and 51.6%. Of the dynamic curves, the persistent type (type I) and wash-out type curve (type III) were statistically significant in benign and malignant NME lesions ($P < 0.05$). The wash-out type curve (type III) was more common in malignancy (28/56, 50%), higher than that in the benign group (18/62, 29%). The incidence of type I was higher in benign lesions (18/62, 29%) than in malignant lesions (2/56, 3.6%) ($P = 0.02$). The sensitivity and specificity of the kinetic curve model for predicting malignant NME lesions were 96.4% and 29.0%. In terms of DWI, diffusion restriction was observed in 48 (85.7%) of the malignant lesions, while 48 (77.4%) of benign lesions had diffusion restriction, which was not statistically significant ($P = 0.248$). The ADC values of benign and malignant lesions were statistically different, and the ADC values of malignant NME lesions were mostly lower than those of benign lesions (*Figures 1,2*). The sensitivity and specificity of the ADC value ($\leq 1.3 \times 10^{-3} \text{ mm}^2/\text{s}$) for predicting malignant NME lesions were 83.9% and 45.2%.

MRI features of DCIS and invasive cancer were further analyzed, and the results are shown in *Table 3* and *Table 4*. Among the distribution characteristics and internal enhancement patterns, the segmental distribution and cluster-ring enhancement can help to distinguish between benign and malignant NME lesions, but there is no statistical difference between invasive carcinoma and carcinoma *in situ*. With respect to the dynamic curves, benign lesions were more likely to show type I than malignant lesions in two groups ($P = 0.003, 0.001$). The wash-out curve (type III) was more frequent in invasive cancer (18/24, 75%), higher than that in the benign lesions (18/62, 29%) ($P < 0.05$), while there was no statistical difference in type III curve between DCIS and benign lesions. All 24 (100%) of invasive cancer showed diffusion restriction and low ADC values, while 28 (45.2%) of benign lesions showed high ADC value. The difference was statistically significant ($P < 0.05$). However, there was no significant difference of diffusion restriction on DWI and ADC value between DCIS and benign lesions. Further analysis showed dynamic curves, DWI, and ADC value were statistically different between invasive cancer and DCIS

Table 2 MR imaging descriptors in NME lesions

Descriptor	Malignant (n=56) (%)	Benign (n=62) (%)	P value
Distribution			
Focal	10 (17.9)	15 (24.2)	0.400
Linear	1 (1.8)	12 (19.4)	0.002*
Segmental	24 (42.9)	13 (21.0)	0.010*
Reginal	6 (10.7)	10 (16.1)	0.391
Multiple regional	5 (8.9)	4 (6.5)	0.874
Diffuse	10 (17.9)	8 (12.9)	0.455
Internal enhancement patterns			
Heterogeneous	15 (21.8)	32 (51.6)	0.006*
Clustered-ring	19 (33.9)	3 (4.8)	<0.001*
Clumped	22 (39.3)	26 (41.9)	0.770
Homogeneous	0 (0.0)	1 (1.6)	1.000
Kinetic curve			
Persistent	2 (3.6)	18 (29.0)	<0.001*
Plateau	26 (46.4)	26 (41.9)	0.623
Washout	28 (50.0)	18 (29.0)	0.020*
ADC value			
>1.3×10 ⁻³ mm ² /s	9 (16.1)	28 (45.2)	0.001*
≤1.3×10 ⁻³ mm ² /s	47 (83.9)	34 (54.8)	
Diffusion restriction			
Present	48 (85.7)	48 (77.4)	0.248
Absent	8 (14.3)	14 (22.6)	

*, P<0.05. NME, non-mass enhancement; MRI, magnetic resonance imaging; ADC, apparent diffusion coefficient.

(P<0.05). The mean ADC value of invasive carcinoma (0.933×10⁻³ mm²/s) is lower than that of carcinoma *in situ* (1.13×10⁻³ mm²/s).

Discussion

DCE-MRI is an indispensable method to detect NME lesions, and morphologic features are the most important parameters (7). Asada *et al.* (8) found that segmental distribution was significantly associated with malignancy (P<0.05), which was similar to that seen in this study, in which the majority of malignant NME cases (24/56, 42.9%) presented as segmental distribution (P=0.01). We also found that linear distribution was more frequent in benign lesions (12/62, 19.4%), which was higher than

that in the malignant NME group (1/56, 1.8%), and the difference was statistically significant (P=0.002). As for internal enhancement model, previous study had reported that cluster-ring enhancement could effectively identify malignant NME lesions (9). In this study, the cluster-ring enhancement was demonstrated in 33.9% (19/56) of the malignant NME lesions and 4.8% (3/62) of the benign NME lesions, which was statistically significant (P<0.001). The sensitivity and specificity of internal enhancement model for predicting malignant NME lesions were 73.2% and 51.6%. Segmental distribution and cluster-ring enhancement were important predictors for NME malignancy, which was consistent with the findings of Lunkiewicz (10). The morphologic features could help to distinguish both invasive carcinoma and carcinoma *in situ*

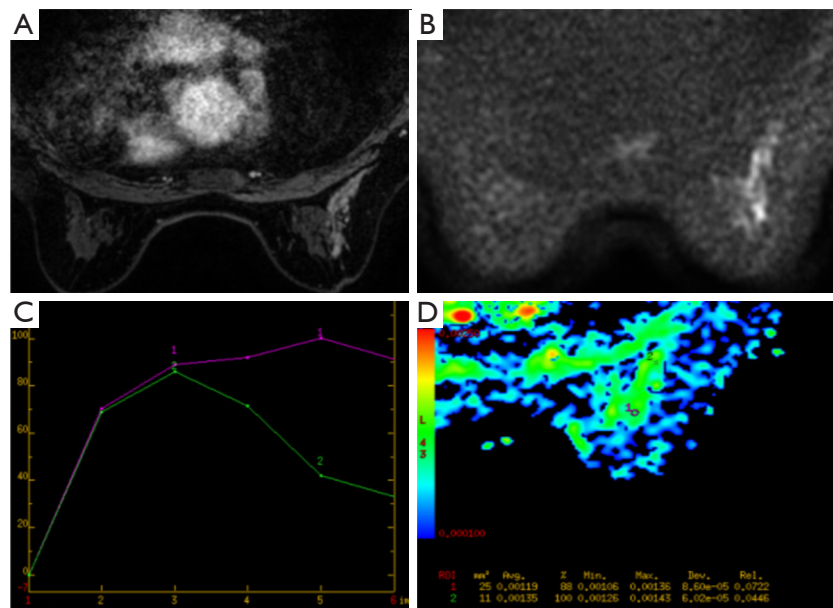


Figure 1 MRI imaging in a 45-year-old woman. (A) Contrast enhanced breast MRI showed segmental distribution and clustered-ring enhancement; (B,C) the lesion showed diffusion restriction on DWI and wash-out dynamic curve; (D) the ADC value of this malignant lesion equals to $1.19 \times 10^{-3} \text{ mm}^2/\text{s}$. Final biopsy showed invasive ductal carcinoma. MRI, magnetic resonance imaging; DWI, diffusion-weighted images; ADC, apparent diffusion coefficient.

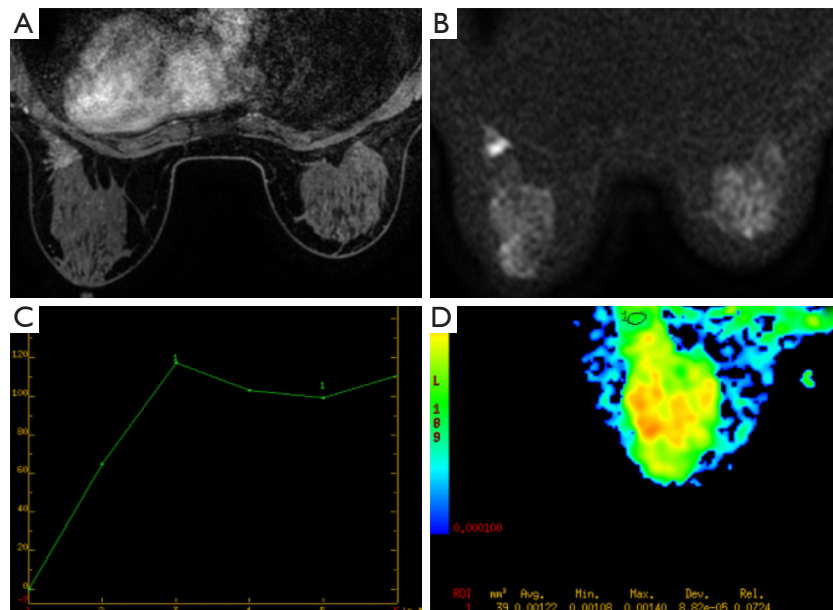


Figure 2 MRI imaging in a 35-year-old woman. (A) Contrast enhanced breast MRI showed focal distribution and heterogeneous enhancement; (B,C) the lesion showed persistent curve without diffusion restriction on DWI; (D) the ADC value of this benign lesion equals to $1.22 \times 10^{-3} \text{ mm}^2/\text{s}$. Final biopsy showed intraductal papilloma. MRI, magnetic resonance imaging; DWI, diffusion-weighted images; ADC, apparent diffusion coefficient.

Table 3 MRI descriptors of between different pathological malignant NME lesions and benign lesions

Descriptor	Invasive carcinoma (n=24) (%)	Benign (n=62) (%)	P value	DCIS (n=32) (%)	Benign (n=62) (%)	P value
Distribution						
Focal	4 (16.7)	15 (24.2)	0.450	6 (18.8)	15 (24.2)	0.548
Linear	0 (0.0)	12 (19.4)	0.048*	1 (3.1)	12 (19.4)	0.065
Segmental	11 (45.8)	13 (21.0)	0.021*	13 (40.6)	13 (21.0)	0.043*
Reginal	0 (0.0)	10 (16.1)	0.086	6 (18.8)	10 (16.1)	0.749
Multiple regional	1 (4.2)	4 (6.5)	1.000	4 (12.5)	4 (6.5)	0.545
Diffuse	8 (33.3)	8 (12.9)	0.061	2 (6.3)	8 (12.9)	0.523
Internal enhancement patterns						
Heterogeneous	7 (29.2)	32 (56.1)	0.061	8 (25.0)	32 (56.1)	0.013*
Clustered-ring	7 (29.2)	3 (4.8)	0.005*	12 (37.5)	3 (4.8)	<0.001*
Clumped	10 (41.7)	26 (41.9)	0.982	12 (37.5)	26 (41.9)	0.678
Homogeneous	0 (0.0)	1 (1.6)	1.000	0 (0.0)	1 (1.6)	1.000
Kinetic curve						
Persistent	0 (0.0)	18 (29.0)	0.003*	2 (6.3)	18 (29.0)	0.001*
Plateau	6 (25.0)	26 (41.9)	0.145	20 (62.5)	26 (41.9)	0.059
Washout	18 (75.0)	18 (29.0)	<0.001*	10 (31.3)	18 (29.0)	0.824
ADC value			<0.001*			0.109
>1.3×10 ⁻³ mm ² /s	0 (0.0)	28 (45.2)		9 (28.1)	28 (45.2)	
≤1.3×10 ⁻³ mm ² /s	24 (100.0)	34 (54.8)		23 (71.9)	34 (54.8)	
Diffusion restriction			0.027*			0.793
Absent	0 (0.0)	14 (22.6)		8 (25.0)	14 (22.6)	
Present	24 (100.0)	48 (77.4)		24 (75.0)	48 (77.4)	

*, P<0.05. NME, non-mass enhancement; MRI, magnetic resonance imaging; ADC, apparent diffusion coefficient.

from benign lesions. Whether morphological features could indicate invasion of malignant lesions was further explored. Machida *et al.* observed 76 DCIS and 55 invasive breast cancers that presented as NME and found a clustered-ring was significantly associated with invasion (11). Hahn *et al.* also reported that a clustered-ring was more commonly observed in microinvasive ductal carcinoma than in pure DCIS (12). In the present study, there was no difference in internal enhancement between invasive carcinoma and DCIS, which may be due to the small sample size. In addition, we found that diffuse distribution was associated with invasion significantly (P=0.023), which may be because the average diameter of invasive lesions was much larger than that of DCIS.

Goto *et al.* in 2007 had reported that a kinetic curve was less effective for NME lesions than mass lesions (1). In this study, malignant NME lesions often showed a wash-out type curve, and benign NME lesions often showed a persistence dynamic curve, which was statistically significant (P<0.05). The sensitivity and specificity of the kinetic curve model for predicting malignant NME lesions were 96.4% and 29.0%. Malignant NME lesions were further divided into two groups (invasive carcinoma and DCIS), and invasive breast cancer of NME mostly showed type III compared with benign lesions, which was statistically significant (P<0.001). Most DCIS (62.5%) showed a plateau dynamic type, and there was no significant difference between DCIS and benign lesions. Thus, dynamic curves

Table 4 MRI features associated with invasion in NME lesions

Descriptor	Invasive carcinoma (n=24) (%)	Ductal carcinoma <i>in situ</i> (n=32) (%)	P value
Distribution			
Focal	4 (16.7)	6 (18.8)	1.000
Linear	0 (24.2)	1 (3.1)	1.000
Segmental	11 (45.8)	13 (40.6)	0.697
Reginal	0 (0.0)	6 (18.8)	0.071
Multiple regional	1 (4.2)	4 (12.5)	0.543
Diffuse	8 (33.3)	2 (6.3)	0.023*
Internal enhancement patterns			
Heterogeneous	7 (29.2)	8 (25.0)	0.728
Clustered-ring	7 (29.2)	12 (37.5)	0.515
Clumped	10 (37.5)	12 (37.5)	0.752
Homogeneous	0 (0.0)	0 (0.0)	–
Kinetic curve			
Persistent	0 (0.0)	2 (6.3)	0.501
Plateau	6 (25.0)	20 (62.5)	0.005*
Washout	18 (75.0)	10 (31.3)	0.001*
ADC value			0.014*
>1.3×10 ⁻³ mm ² /s	0 (0.0)	9 (28.1)	
≤1.3×10 ⁻³ mm ² /s	24 (100.0)	23 (71.9)	
Diffusion restriction			0.024*
Absent	0 (0.0)	8 (25.0)	
Present	24 (100.0)	24 (75.0)	

*, P<0.05. NME, non-mass enhancement; MRI, magnetic resonance imaging; ADC, apparent diffusion coefficient.

might help to differentiate invasive NME breast cancer from benign lesions, but do not effectively distinguish DCIS from benign lesions. Greenwood *et al.* showed that MRI evaluation of DCIS mainly depended on morphological features rather than kinetics, which was consistent with our results (13). In this study, the kind of dynamic curves between invasive cancer and DCIS were further evaluated, and DCIS showed persistent or plateau curves, which were more common than invasive breast cancer (P>0.05). The wash-out dynamic type was more common in invasive carcinoma (18/24, 75%), which was higher than in the DCIS group (10/32, 31.3%) (P=0.001). Thus, a wash-out curve may help identify invasive NME lesions from DCIS.

In this study, we also found that the parameters of DWI and ADC value were important in identifying malignant

NME lesions. Malignant NME lesions mostly presented with lower ADC values (≤1.3×10⁻³ mm²/s) compared with benign lesions (P=0.001). The sensitivity and specificity of the ADC value (≤1.3×10⁻³ mm²/s) for predicting malignant NME lesions were 83.9% and 45.2%. The proportion of restricted diffusion on DWI in malignant NME lesions was higher than that in benign NME lesions, but there was no statistical difference (P=0.248). Sharma *et al.* showed malignant NME lesions had restricted diffusion on DWI at 1.5T, which was associated with increased cell density (14), while Avendano *et al.* found that the ADC value was limited in differentiating benign and malignant NME lesions, with 31% of NME lesions unable to be evaluated on DWI due to poor imaging quality (15). The differences of results might be due to the ROI measurement methods

and ADC indicators in different studies. The potential of DWI and ADC value ($b=1,000 \text{ s/mm}^2$) to distinguish invasive cancer or DCIS from benign lesions to be explored. Invasive cancer showed restricted diffusion on DWI and a lower ADC value compared to benign NME lesions and the difference was statistically significant ($P=0.027, <0.001$). DCIS also showed restricted diffusion on DWI and lower ADC values compared to benign NME lesions, but the difference was not statistically significant ($P=0.793, 0.109$), indicating it is limited in identifying DCIS from benign NME lesions by DWI and ADC values. Thus, diffusion restriction on DWI and lower ADC value could help differentiate invasive malignant lesions from benign lesions compared with DCIS ($P<0.001, 0.027$). Greenwood *et al.* found that DWI and ADC values could distinguish DCIS from invasive disease, with invasive cancer having a lower average ADC value than DCIS ($P<0.001$) ($b=1,000 \text{ s/mm}^2$) (13). Our study also showed ADC values were lower in invasive cancer than in DCIS and invasive carcinoma was more likely to show restricted diffusion on DWI ($P=0.014, 0.024$).

This study had some limitations, including its retrospective nature and small sample size, and further studies with larger sample sizes are needed to confirm the conclusions. Moreover, there may be false negative results in the pathological results of percutaneous biopsy, which might affect the accuracy of our conclusions.

In conclusion, this study demonstrated MRI was useful in distinguishing malignant NME lesions. Segmental distribution, clustered-ring enhancement, washout dynamic type, and lower ADC value were associated with malignancy. Further analysis of MRI findings of malignant NME lesions found that wash-out dynamic type, diffusion restriction on DWI and more lower ADC value could help identify invasive lesions from DCIS. MRI is a valuable way to predict the malignancy and invasion of NME lesions.

Acknowledgments

Funding: This work was supported by National Key Research and Development Program of China (Grant No. 2019YFC0118800).

Footnote

Reporting Checklist: The authors have completed the STARD reporting checklist. Available at <https://atm.amegroups.com/article/view/10.21037/atm-22-503/rc>

Data Sharing Statement: Available at <https://atm.amegroups.com/article/view/10.21037/atm-22-503/dss>

Conflicts of Interest: All authors have completed the ICMJE uniform disclosure form (available at <https://atm.amegroups.com/article/view/10.21037/atm-22-503/coif>). All authors report that this work was supported by National Key Research and Development Program of China (Grant No. 2019YFC0118800). The authors have no other conflicts of interest to declare.

Ethical Statement: The authors are accountable for all aspects of the work in ensuring that questions related to the accuracy or integrity of any part of the work are appropriately investigated and resolved. The study was conducted in accordance with the Declaration of Helsinki (as revised in 2013). The requirement for informed consent was waived in this retrospective study. The ethical approval was waived by the Ethics committee of the First Medical Center of Chinese PLA General Hospital.

Open Access Statement: This is an Open Access article distributed in accordance with the Creative Commons Attribution-NonCommercial-NoDerivs 4.0 International License (CC BY-NC-ND 4.0), which permits the non-commercial replication and distribution of the article with the strict proviso that no changes or edits are made and the original work is properly cited (including links to both the formal publication through the relevant DOI and the license). See: <https://creativecommons.org/licenses/by-nc-nd/4.0/>.

References

1. Goto M, Ito H, Akazawa K, et al. Diagnosis of breast tumors by contrast-enhanced MR imaging: comparison between the diagnostic performance of dynamic enhancement patterns and morphologic features. *J Magn Reson Imaging* 2007;25:104-12.
2. Edwards SD, Lipson JA, Ikeda DM, et al. Updates and revisions to the BI-RADS magnetic resonance imaging lexicon. *Magn Reson Imaging Clin N Am* 2013;21:483-93.
3. Kuhl CK, Schrading S, Leutner CC, et al. Mammography, breast ultrasound, and magnetic resonance imaging for surveillance of women at high familial risk for breast cancer. *J Clin Oncol* 2005;23:8469-76.
4. Gutierrez RL, DeMartini WB, Eby PR, et al. BI-RADS lesion characteristics predict likelihood of malignancy in breast MRI for masses but not for nonmasslike

- enhancement. *AJR Am J Roentgenol* 2009;193:994-1000.
5. Pinker K, Moy L, Sutton EJ, et al. Diffusion-Weighted Imaging With Apparent Diffusion Coefficient Mapping for Breast Cancer Detection as a Stand-Alone Parameter: Comparison With Dynamic Contrast-Enhanced and Multiparametric Magnetic Resonance Imaging. *Invest Radiol* 2018;53:587-95.
 6. Pinker K, Marino MA, Dr Meyer-Baese A, et al. Multiparametric and molecular imaging of breast tumors with MRI and PET/MRI. *Radiologe* 2016;56:612-21.
 7. Newell D, Nie K, Chen JH, et al. Selection of diagnostic features on breast MRI to differentiate between malignant and benign lesions using computer-aided diagnosis: differences in lesions presenting as mass and non-mass-like enhancement. *Eur Radiol* 2010;20:771-81.
 8. Asada T, Yamada T, Kanemaki Y, et al. Grading system to categorize breast MRI using BI-RADS 5th edition: a statistical study of non-mass enhancement descriptors in terms of probability of malignancy. *Jpn J Radiol* 2018;36:200-8.
 9. Aydin H. The MRI characteristics of non-mass enhancement lesions of the breast: associations with malignancy. *Br J Radiol* 2019;92:20180464.
 10. Lunkiewicz M, Forte S, Freiwald B, et al. Interobserver variability and likelihood of malignancy for fifth edition BI-RADS MRI descriptors in non-mass breast lesions. *Eur Radiol* 2020;30:77-86.
 11. Machida Y, Shimauchi A, Tozaki M, et al. Descriptors of Malignant Non-mass Enhancement of Breast MRI: Their Correlation to the Presence of Invasion. *Acad Radiol* 2016;23:687-95.
 12. Hahn SY, Han BK, Ko EY, et al. MR features to suggest microinvasive ductal carcinoma of the breast: can it be differentiated from pure DCIS? *Acta Radiol* 2013;54:742-8.
 13. Greenwood HI, Wilmes LJ, Kelil T, et al. Role of Breast MRI in the Evaluation and Detection of DCIS: Opportunities and Challenges. *J Magn Reson Imaging* 2020;52:697-709.
 14. Sharma U, Danishad KK, Seenu V, et al. Longitudinal study of the assessment by MRI and diffusion-weighted imaging of tumor response in patients with locally advanced breast cancer undergoing neoadjuvant chemotherapy. *NMR Biomed* 2009;22:104-13.
 15. Avendano D, Marino MA, Leithner D, et al. Limited role of DWI with apparent diffusion coefficient mapping in breast lesions presenting as non-mass enhancement on dynamic contrast-enhanced MRI. *Breast Cancer Res* 2019;21:136.
- (English Language Editor: B. Draper)

Cite this article as: Liu G, Li Y, Chen SL, Chen Q. Non-mass enhancement breast lesions: MRI findings and associations with malignancy. *Ann Transl Med* 2022;10(6):357. doi: 10.21037/atm-22-503