

Epidermolysis bullosa acquisita treated with ustekinumab: A case report

SAGE Open Medical Case Reports
JCMS Case Reports
Volume 10: 1–3
© The Author(s) 2022
Article reuse guidelines:
sagepub.com/journals-permissions
DOI: 10.1177/2050313X221091600
journals.sagepub.com/home/sco



Connor Prosty¹ , Justina Guirguis², May Chergui³,
Waqas Afif⁴ and Elena Netchiporouk²

Abstract

Epidermolysis bullosa acquisita is a rare autoimmune disease involving cutaneous blistering and scarring associated with collagen VII autoantibodies. Similarly, collagen VII autoantibodies are present in the majority of Crohn's disease patients and approximately a quarter of epidermolysis bullosa acquisita patients have coexisting Crohn's disease. Treatment options for epidermolysis bullosa acquisita are limited and are largely ineffective. Here, we describe a 36-year-old female with a history of Crohn's disease presenting with a 7-year history of severe blistering and scarring of acral surfaces. Diagnostic workup revealed subepidermal cleavage on skin biopsy and elevated serum collagen VII autoantibodies, indicative of epidermolysis bullosa acquisita. She was given ustekinumab for her coexisting Crohn's disease and, afterwards, her epidermolysis bullosa acquisita resolved as evidenced by a lack of new blisters or scarring. Further studies are required to evaluate the effects of ustekinumab on epidermolysis bullosa acquisita.

Keywords

Epidermolysis bullosa acquisita, ustekinumab, autoimmune blistering disease, Crohn's disease

Introduction

Epidermolysis bullosa acquisita (EBA) is a rare autoimmune disease presenting with skin fragility and mechanobullous blistering in trauma-prone sites that heals with milia cysts and scars due to collagen VII (COL7) antibody-mediated subepidermal detachment.¹ EBA has been associated with several autoimmune and inflammatory diseases including Crohn's disease (CD), reported in up to 25% of cases.^{1,2} EBA is notoriously resistant to treatment and current management consists of education, trauma prevention, wound care, and trial of immunosuppressive and immunomodulatory therapies including colchicine, dapsone, systemic corticosteroids, and rituximab.¹ Here, we present the first documented case of complete EBA control following topical corticosteroids/tacrolimus in combination with ustekinumab treatment for coexisting CD.

Case report

A 36-year-old female with a 1-year history of CD, managed with 20 mg of prednisone daily, presented to the dermatology clinic for a 7-year history of recurrent painful blisters, milia, and scarring on dorsal hands, feet, elbows, and knees. Physical examination revealed non-inflammatory tense bullae, erosions, milia, dyspigmentation, and scarring in

trauma-prone sites (Figure 1(a)). Biopsy of perilesional and lesional skin found pauci-cellular subepidermal vesicles and subepidermal cleavage on histology (Figure 1(b)) and linear immunoglobulin gamma (IgG) reactivity along the dermal-epidermal junction on direct immunofluorescence. Laboratory investigations including 24-h urine porphyrins and workup for systemic lupus were normal, except for elevated serum COL7 autoantibodies. She was diagnosed with EBA, counselled on trauma prevention/gentle skin hygiene, and managed with topical clobetasol propionate alternating with tacrolimus. One month following her diagnosis with EBA, ustekinumab was initiated by her gastroenterologist because of poorly controlled CD on prednisone. Induction

¹Faculty of Medicine, McGill University, Montreal, QC, Canada

²Division of Dermatology, McGill University Health Centre, Montreal General Hospital, Montreal, QC, Canada

³Department of Pathology, McGill University Health Centre, Montreal General Hospital, Montreal, QC, Canada

⁴Division of Gastroenterology and Hepatology, McGill University Health Centre, Montreal General Hospital, Montreal, QC, Canada

Corresponding Author:

Elena Netchiporouk, Division of Dermatology, McGill University Health Centre, Montreal General Hospital, 1650 Avenue Cedar, Montreal, QC H3G 1A4, Canada.

Email: elena.netchiporouk@mcgill.ca



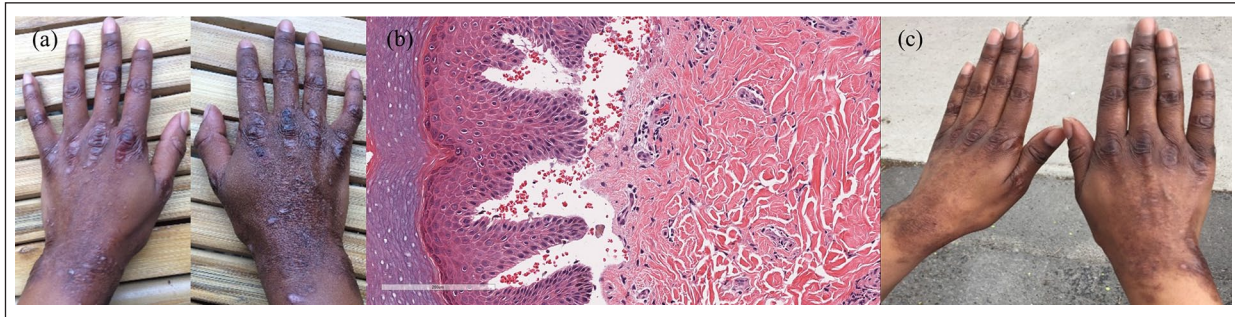


Figure 1. (a) Atrophic scarring, milia cysts, and dyspigmentation on dorsal hands in trauma-prone areas before the patient was started on ustekinumab. Evidence of active blistering with resolving tense blister on the left index finger and multifocal crusted papules from recent bullae. (b) Lesional biopsy stained with hematoxylin and eosin showing subepidermal cell poor blistering. (c) Complete control of EBA 9 months after starting ustekinumab, complete resolution of blistering and pain. Isolated milia cysts and dyspigmentation remain.

dosing was a 6-mg/kg intravenous infusion followed by 45 mg administered subcutaneously every 8 weeks. Dermatologic assessment 2 months after starting ustekinumab revealed marked improvement of the patient's EBA, with few new lesions. One month later, dosing of ustekinumab was increased to 90 mg, due to recalcitrant CD. Injection frequency was increased to every 4 weeks, 3 months later. At reassessment 8 months after ustekinumab initiation, the patient reported complete control of EBA evidenced by the absence of newly developing bullae and erosions. Clinically only sequelae of prior disease, milia, dyspigmentation, and scars were observed (Figure 1(c)). Importantly, EBA response did not correlate with CD response to ustekinumab.

Discussion

To our knowledge, no studies exist reporting the effective treatment of EBA with ustekinumab, a humanized monoclonal antibody for the treatment of CD.³ By inhibiting interleukin (IL)-12 and IL-23 via their shared p40 subunit, ustekinumab suppresses the Th1 and Th17 pathways, respectively, thereby diminishing the pathologic inflammation underlying CD.³ Interestingly, polarization of the immune response towards Th1 has been noted in EBA, potentially driving the production of COL7 IgG autoantibodies and explaining EBA's association with CD and response to ustekinumab.¹ Although the role of the aforementioned interleukins has not been clearly elucidated in EBA's pathogenesis,¹ other links could potentially explain the interplay between the two diseases and their response to ustekinumab. Indeed, tumor necrosis factor (TNF)- α has been implicated in the pathogenesis of both conditions, and one case report has documented the remission of EBA and concomitant CD in response to TNF- α inhibition by infliximab.^{1,4}

EBA is an exceedingly rare cutaneous association of CD.⁵ Autoantibodies against COL7 have been detected in up to 68% of CD patients; however, only a small subset of these patients develop EBA.^{2,6} The mechanism for the antibody formation and subsequent EBA development in select CD

patients is unknown.^{2,6} Interestingly, the IgG isotypes implicated in EBA (IgG1 and IgG3) differ from those detected in CD (IgG4).^{2,5} In addition, COL7 epitopes existing in the skin vary compared to those found in the gut.² Further studies are necessary to clarify the common role of COL7 autoantibodies in CD and EBA, which may explain their common response to ustekinumab.

Despite limitations imposed by the observational nature of this case report, ustekinumab may be an effective therapy for EBA. Moreover, the successful treatment of the described patient's EBA by ustekinumab further highlights the interplay between CD and EBA.

Declaration of conflicting interests

The author(s) declared the following potential conflicts of interest with respect to the research, authorship, and/or publication of this article: WA received consultancy fees from Abbvie, Amgen, Arena Pharmaceuticals, Dynacare, Fresenius Kabi, Janssen, Merck, Novartis, Pfizer, Sandoz, and Takeda. EN received consultancy and/or research funding and/or speaker honorarium from Bausch Health, Novartis, Eli Lilly, Sanofi Genzyme, AbbVie, Galderma, Sun Pharma, Janssen, Sandoz, Mallinckrodt, Medexus, Leo Pharma, Beiersdorf. The other authors declare no conflicts of interest.

Funding

The author(s) received no financial support for the research, authorship, and/or publication of this article.

Informed consent

Written consent was obtained from the patient for publication of all information and photos herein.

ORCID iD

Connor Prosty  <https://orcid.org/0000-0001-6790-220X>

References

1. Koga H, Prost-Squarcioni C, Iwata H, et al. Epidermolysis bullosa acquisita: the 2019 update. *Front Med* 2019; 5: 362.

2. Chen M, O'Toole EA, Sanghavi J, et al. The epidermolysis bullosa acquisita antigen (Type VII Collagen) is present in human colon and patients with Crohn's disease have autoantibodies to type VII collagen. *J Invest Dermatol* 2002; 118(6): 1059–1064.
3. Benson JM, Sachs CW, Treacy G, et al. Therapeutic targeting of the IL-12/23 pathways: generation and characterization of ustekinumab. *Nat Biotechnol* 2011; 29(7): 615–624.
4. Vicente EF, Hernández-Núñez A, Aspa J, et al. Crohn's disease, relapsing polychondritis and epidermolysis bullosa acquisita: an immune-mediated inflammatory syndrome. *Rheumatology* 2008; 47(3): 380–381.
5. Reddy H, Shipman AR and Wojnarowska F. Epidermolysis bullosa acquisita and inflammatory bowel disease: a review of the literature. *Clin Exp Dermatol* 2013; 38(3): 225–229; quiz 229.
6. Hundorfean G, Neurath MF and Sitaru C. Autoimmunity against type VII collagen in inflammatory bowel disease. *J Cell Mol Med* 2010; 14(10): 2393–2403.