


# Clinical Evaluation of Pediatric Posterior Zirconia and Stainless Steel Crowns: A Comparative Study

Gayathri Murali<sup>1</sup>, Jayanthi Mungara<sup>2</sup>, Poornima Vijayakumar<sup>3</sup>, Keerthi T<sup>4</sup>, Sai Sarath Kumar Kothimbakkam<sup>5</sup>, Santhosh Priya AKR<sup>6</sup> 

## ABSTRACT

**Objective:** To clinically evaluate and compare the performance of posterior pediatric zirconia crowns with stainless steel crowns.

**Materials and methods:** Twenty nine children [3–9 years] were selected and given 70 preformed crowns [35: preformed zirconia crowns, Kinderkrown; 35: stainless steel crowns, KIDZ CROWN]. Crowns were evaluated for retention, marginal integrity, opposing tooth wear, plaque accumulation, gingival inflammation, and proximal contact at 3, 6, 9, and 12th month.

**Results:** At the end of follow-up period overall success rate with zirconia crown was 93.5% and that of stainless steel crown was 96.7%. Statistical analysis showed no difference between the groups.

**Conclusion:** Posterior preformed zirconia and stainless steel crowns showed good clinical performance. Preformed zirconia crowns can be an option for posterior full coronal restoration when esthetics is of prime concern for the parent and child.

**Keyword:** Clinical performance, Esthetics, Esthetic crowns, Pediatric crowns, Pediatric stainless steel crowns, Preformed pediatric crowns, Stainless steel crowns, Zirconia crowns.

*International Journal of Clinical Pediatric Dentistry* (2022): 10.5005/jp-journals-10005-2125

## INTRODUCTION

Early childhood caries is a global epidemic problem affecting majority of preschool children, if left untreated leads to degenerating condition in primary dentition even at very young age.<sup>1</sup> The mutilated teeth can be restored with full coronal restoration in order to preserve the integrity of primary dentition until their natural exfoliation. Till date, various preformed crowns have been tried as full coronal restorations for both therapeutic and preventive treatment.<sup>2</sup>

Stainless steel crowns were the choice of full coronal restoration, as they were easily available as preformed, pretrimmed and precontoured crowns with wide range of sizes and with proven clinical efficiency.<sup>5</sup> Stainless steel crowns, introduced by “Rocky Mountain” company were later improved by various manufacturers. The only disadvantage of SSC was its unesthetic appearance.<sup>6,7</sup>

A survey of pediatric dentists reported that 87% of the parents are concerned about the esthetics of even posterior restorations. In addition, studies suggest that even children are more concerned about esthetics as it influences their psychological well-being and physical appearance.<sup>8,9</sup>

The need to meet the demand for esthetic restorations led to the introduction of open faced stainless steel crowns, veneered crowns, polycarboxylate crowns, and strip crowns. Each of these full coronal restorations has their own advantage and disadvantage. Initially veneered stainless steel crowns showed short term success rate but long term follow-up studies have reported frequent fracture of these crowns as a whole or a part of it.<sup>10,12</sup>

The technological advances in material science led to the evolution of preformed zirconia crowns for primary teeth, so as to fulfill the esthetic demands, at the same time promise good durability. Zirconia crowns are known as “Ceramic Steel” as it provides strength close to available metal crowns as well as color similar to that of natural teeth. Pediatric zirconia crowns were

<sup>1</sup>Department of Pedodontics and Preventive Dentistry, SRM Kattankulathur Dental College and Hospital, Chennai, Tamil Nadu, India

<sup>2,3</sup>Pedodontics, Ragas Dental College and Hospital Chennai, Tamil Nadu, India

<sup>4</sup>Chennai, Tamil Nadu, India

<sup>5,6</sup>Pediatric and Preventive Dentistry, Sathyabama Dental College and Hospital, Chennai, Tamil Nadu, India

**Corresponding Author:** Gayathri Murali, Department of Pedodontics and Preventive Dentistry, SRM Kattankulathur Dental College and Hospital, Chennai, Tamil Nadu, India, Phone: +91 9360866038, e-mail: drgayathrimurali1992@gmail.com

**How to cite this article:** Murali G, Mungara J, Vijayakumar P, et al. Clinical Evaluation of Pediatric Posterior Zirconia and Stainless Steel Crowns: A Comparative Study. *Int J Clin Pediatr Dent* 2022;15(1):9–14.

**Source of support:** Nil

**Conflict of interest:** None

introduced by EZ-pedo and became commercially available in 2008. Later preformed zirconia crowns were popularized by companies like Nusmile, Kinderkrowns, Cheng crowns, Signature crowns, and many more. These preformed crowns differed with respect to size, shape, shade, and pattern of retention component.<sup>13</sup> Advantages of preformed zirconia crowns are its esthetics, no component of the crown that might debond and potentially less technique sensitive when compared to other esthetic alternatives. The potential disadvantages include need for more tooth reduction,<sup>14</sup> inability to crimp or contour the crown and they are also expensive.

Many of the studies with preformed zirconia crowns have been confined only to the anterior teeth.<sup>4,15</sup> Very limited literature is available with regard to its efficiency and clinical performance. Thus this study was carried out to assess and compare the efficiency

of zirconia crowns with stainless steel crowns used in posterior primary teeth.

## MATERIALS AND METHODOLOGY

The study is a prospective clinical trial done to evaluate and compare the efficacy of preformed posterior zirconia crowns and stainless steel crowns. The study was approved by the Institutional review board [IRB no- 201,61220] of RAGAS DENTAL COLLEGE AND HOSPITAL [affiliated to Tamil Nadu Dr M.G.R. Medical University, Chennai].

### Sample Size Determination

Based on the findings of pilot study conducted with 10 teeth [five in each group] taking alpha error of 0.05 and 90% power, a sample size of 28 in each group was determined. Accounting for 20% loss to follow up the total number of crowns to be evaluated per group was decided to be 35 [28 +20% of 28]. Overall 70 crowns [35 stainless steel and 35 zirconia crowns were decided to be placed]. The study was started with 70 pulp treated [pulpectomy, pulpotomy] primary molars of 29 children aged between 3 and 9 years and restored with preformed pediatric crowns of which 35 were zirconia crowns and 35 were stainless steel crowns. The clinical performance of these crowns was assessed for a period of 1 year at 3 months interval.

### Clinical Procedure

#### Tooth Preparation for Stainless Steel Crowns

Tooth preparation was done with No.330 or tapered diamond bur to reduce occlusal surface by 1 to 1.5 mm. Care was taken to produce uniform occlusal reduction. Inter proximal reduction was done mesially and distally with No.169 L tapered diamond bur in such a way that straight probe passes freely through the contact area. Rounding of line angles done and a knife-edge finish margin of the proximal surface was obtained. Care was taken to avoid any ledge formation.

An appropriate size crown was chosen according to mesiodistal width of the prepared tooth and trial fit was carried out before cementation. The crown was crimped using No.800–417 crown–crimping plier. Finally the crown was luted with type 1 GIC, the flash was removed with an explorer and final occlusion was checked<sup>16</sup> (Fig. 1).

#### Tooth Preparation for Preformed Zirconia Crowns

The tooth preparation was done following the manufacturer's guidelines.<sup>17</sup> The occlusal surface was reduced to a thickness

of 1.5 to 2 mm with WR-13I diamond bur. Interproximal contacts was broken using CD-59F tapered fissure bur. The tooth was trimmed down circumferentially by around 20 to 30%, or 0.5 to 1.25 mm with the help of TC-21 tapered diamond or carbide burs (Fig. 2).

About 1 to 2 mm subgingival preparation was done to achieve feather-edge finish line. Care was taken to not to create any undercuts. A slim, narrowed diamond bur was utilized to prevent the breaking up of tissue during the execution of such subgingival tooth modifications.

Selected preformed crown was placed on the prepared tooth. Prepared tooth was made free from any blood or saliva. Passive fit of the crown and occlusion was checked and the crown was luted with dual cure resin cement [relyx-300]. (Fig. 3) Consistent firm finger pressure was applied during cementation. Care was taken to stabilize the crown in position till the cement has completely hardened. The access cavity of the pulp treated tooth was finally

### Evaluation Criteria

#### Clinical evaluation

- Crown retention
  - Intact
  - Chipped
  - Complete loss
- Marginal integrity
  - Closed
  - Open
- Opposing tooth wear
  - Wear
  - No wear
- Gingival inflammation
  - Mild
  - Moderate
  - Severe
- Proximal contact
  - Intact
  - Lost
- Plaque accumulation
  - No plaque
  - Mild plaque not visible to naked eye
  - Plaque visible to naked eye

### Inclusion Criteria

- Full coverage restoration following pulpectomy or pulpotomy.
- Healthy children, free of any systemic disease.
- Children for whom consent was obtained from parents/guardians.

### Exclusion Criteria

- Teeth with pathological root resorption
- Infection involving the furcation.
- Children with para functional habits.
- Teeth with inadequate crown structure.

sealed using Glass ionomer cement, so as to obtain better bond between the luting cement and access cavity cement.

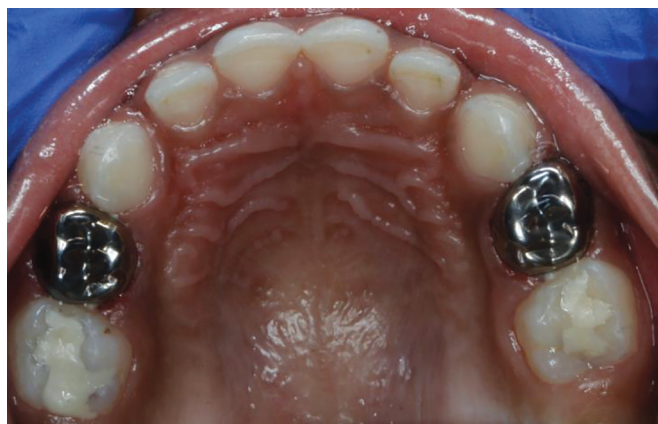

Fig. 1: Stainless steel crown in maxillary molars

**RESULTS**

The data was entered in the Microsoft Excel spread sheet and analyzed with WILCOXON SIGNED RANK TEST for within group comparison and MANN-WHITNEY U TEST for intergroup comparison. The level of significance was set at 0.05. The review for 12th month showed 29 (93.5%) of zirconia crowns were intact and 31 (100%) of stainless steel crowns were found to be intact. All the evaluated crowns from both the groups showed 100% good marginal adaptation. Both the crowns maintained 100% (31/31: stainless steel, 30/30: zirconia) good proximal contact and reported no opposing tooth wear. Good gingival health and plaque score was maintained with both the groups. Zirconia crowns showed 93.5% overall success rate whereas stainless steel crowns showed 96.7% success rate, with no significant difference between the groups.

**DISCUSSION**

Full coronal restorations have become the prevalent part of rehabilitation of the children affected with early childhood caries.

Multiple options have been tried with each one showing varied clinical performance. Change in life style, more opportunities to socialize and role of media plays a role in exposing the children to a concept of ideal beauty at very young age. This has showed impact on their concerns about esthetics which is similar to that of adults.<sup>8</sup> The same principle applies in terms of restorations to be placed on their teeth.<sup>9</sup>

In this study, a total of 70 crowns [35 zirconia and 35 stainless steel] were placed in 29 patients following pulp therapy. Of which 61 crowns were available for 12 months review [31 SSC and 30 Zirconia crowns]. The clinical evaluation criteria was based on the plaque accumulation, gingival health, proximal contact, marginal integrity, crown retention, and opposing tooth wear.

In this study, preformed Kinder Krowns were used due to the availability of varied sizes, better retentive features, and a polished surface to reduce opposing tooth wear. According to the manufacturer’s guidelines, resin modified glass ionomer [3M ESPE Rely X] was used to lute the crowns. Preformed stainless steel crown were luted with type 1 GIC [GC Type 1 GIC] as it is the most commonly recommended cement for luting stainless steel crowns.<sup>18</sup>

The present study showed 96.7% [30/31] retention with stainless steel crowns. Loss of stainless steel crown 3.2% (1) during 9th month follow up could be attributed to loss of cement. Micro structural porosity or the voids in the set cement can progressively cause crack propagation due to occlusal forces finally leading to cement loss over a period of time.<sup>19</sup> This could be the attributing factor for crown dislodgement at the end of 9th month review 93.77% [29/31] of zirconia showed complete retention of crowns 3.2% (1) of zirconia crowns showed chipping of the crown and 3.2% (1) showed complete loss of crown at 3rd month follow up. The chipping of the crown could be attributed to the occlusal forces delivered while seating the crown or due to mild occlusal disharmony as a result of inability to trim the cuspal patterns of these crowns. The complete loss of crown in zirconia group could be as a result of inadequate tooth structure to achieve subgingival preparation, functional cusp of opposing tooth, due to inadequate moisture control while cementing, or due to loss of cement. The crown which showed complete loss was recorded as restoration failure and it was replaced by custom made zirconia crown and not assessed for other parameters. These results are contrary to the findings of Abdulhadi et al. who showed 100% retention of zirconia crowns. The cements used in the present study to lute the crowns were different and that might have influenced the bond strength which in turn could have influenced the retention of the crowns<sup>4,7</sup>(Table 1).

The crowns other than those which showed retention failure had good marginal integrity in both the groups 100% [31/31]

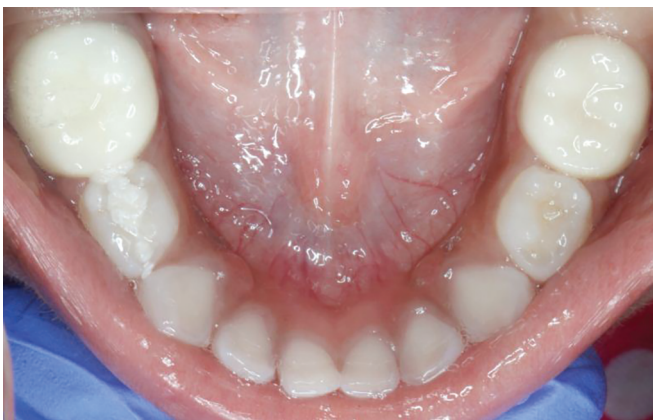

Fig. 2: Preformed zirconia crowns in mandibular second molars

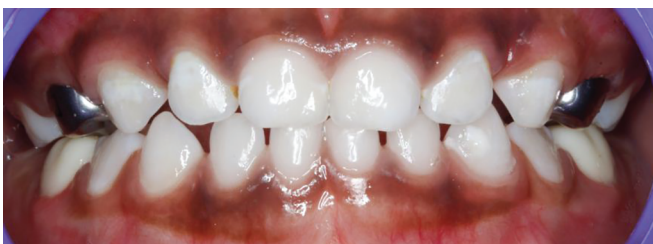

Fig. 3: In occlusion

**Table 1:** Retention of stainless steel and zirconia crown at 3,6,9, and 12th month follow-up visit

Category	Stainless steel crown				Zirconia crowns			
	3 M (31)	6M (31)	9M (31)	12M (31)	3M (32)	6M (31)	9M (31)	12M (31)
1. Crown retention								
a) Intact	31/31 100%	31/31 100%	30/31 96.77%	31/31 100%	30/31 96.77%	29/31 93.5%	29/30 96.6%	29/30 96.6%
b) Chipped	-	-	-	-	1/31(3.2%)	1/31(3.2%)	1/30(3.3%)	1/30(3.3%)
c) Complete loss	-	-	1/31 3.2%	-	-	1/31(3.2%)	-	-
NOT ASSESSED	-	-	-	-	-	-	1/31(3.2%)	1/31(3.2%)

with SSC and 96.6% [29/30] with zirconia crowns. Holsinger et al. showed 86% closed margins with Nusmile zirconia crowns.<sup>15</sup> This could be attributed to the morphological qualities of Kinder Krowns. The fine feather margins could have contributed in good adaptation of crown to the tooth structure irrespective of excessive tooth preparation. Stainless steel crowns are easy to contour and crimp, making them adapt well to the prepared tooth structure (Table 2).

The 100% success rate with respect to proximal contact in both the groups was made possible because of the availability of varied sizes and morphological features as close as possible to that of natural teeth making them easier to establish proximal contact. The adjacent teeth were also intact till the end of study

period without any pathology. Similar to findings observed in other studies<sup>7</sup>(Table 4).

All the stainless steel crowns evaluated for gingival inflammation and plaque accumulation showed healthy gingiva without any inflammation, whereas two children showed visible plaque accumulation and mild gingival inflammation in the zirconia group which was resolved during 9th month review. Gingival inflammation can be attributed to the generalized plaque accumulation and lack of motivation which was improved with oral prophylaxis and oral health education and motivation (Tables 5 and 6).

Both the groups showed no opposing tooth wear, but few of studies showed opposing tooth wear with zirconia crown.<sup>4</sup> Donovan

**Table 2:** Marginal integrity of stainless steel and zirconia crown at 3,6,9, and 12th month follow-up visit

Category	Stainless steel crowns				Zirconia crowns			
	3 M (31)	6M (31)	9M (31)	12M (31)	3M (32)	6M (31)	9M (31)	12M (31)
2. Marginal integrity								
a) Closed	31/31 100%	31/31 100%	30/30 100%	31/31 100%	30/31(96.7%)	30/30 (100%)	30/30 (100%)	30/30 (100%)
b) Open	-	-	-	-	1/31(3.2%)	-	-	-
<b>NOT ASSESSED</b>	-	-	1/31 3.2%	-	-	1/31(3.2%)	1/31(3.2%)	1/31(3.2%)

**Table 3:** Opposing tooth wear caused by stainless steel and zirconia crowns at 3, 6, 9, and 12th month follow-up visit

Category	Stainless steel crowns				Zirconia crowns			
	3 M (31)	6M (31)	9M (31)	12M (31)	3M (32)	6M (31)	9M (31)	12M (31)
3. Opposing tooth wear								
a) Wear	-	-	-	-	-	-	-	-
b) No wear	31/31(100%)	31/ 31,100%	31/ 31,100%	31/ 31,100%	31/31(100%)	31/31(100%)	31/31(100%)	31/31(100%)
<b>NOT ASSESSED</b>	-	-	-	-	-	-	-	-

**Table 4:** Proximal contact with stainless steel and zirconia crowns at 3, 6, 9, and 12th month follow-up visit

Category	Stainless steel crowns				Zirconia crowns			
	3 M (31)	6M (31)	9M (31)	12M (31)	3M (32)	6M (31)	9M (31)	12M (31)
4. Proximal contact								
a) Intact	31/31(100%)	31/31(100%)	30/31(96.7%)	31/31(100%)	31/31(100%)	30/30(100%)	30/30(100%)	30/30(100%)
b) Lost	-	-	1/31(3.2%)	-	-	-	-	-
<b>NOT ASSESSED</b>	-	-	-	-	-	-	-	-

**Table 5:** Plaque accumulation with stainless steel and zirconia crown at 3, 6, 9, and 12th month follow-up visit

Category	Stainless steel crowns				Zirconia crowns			
	3 M (31)	6M (31)	9M (31)	12M (31)	3M (32)	6M (31)	9M (31)	12M (31)
5. Plaque index								
a) No plaque	31/31(100%)	31/31(100%)	31/31(100%)	31/31(100%)	30/31(96.7%)	28/30(93.3%)	30/30(100%)	30/30(100%)
b) Plaque not seen by naked eye	-	-	-	-	-	-	-	-
c) Plaque seen by naked eye	-	-	-	-	1/31(3.2%)	2/30(6.6%)	-	-
<b>NOT ASSESSED</b>	-	-	-	-	-	1/31(3.2%)	1/31(3.2%)	1/31(3.2%)



**Table 6:** Gingival inflammation with stainless steel and zirconia crowns at 3,6,9, and 12th month follow-up visit

Category	Stainless Steel Crowns				Zirconia Crowns			
	3 M (31)	6M (31)	9M (31)	12M (31)	3M (32)	6M (31)	9M (31)	12M (31)
6. Gingival Inflammation								
a) No Inflammation	31/31(100%)	31/31(100%)	31/31(100%)	31/31(100%)	30/31(96.7%)	28/30(93.3%)	30/30(100%)	30/30(100%)
b) Mild	–	–	–	–	1/31(3.2%)	2/30(6.6%)	–	–
c) Moderate	–	–	–	–	–	–	–	–
d) Severe	–	–	–	–	–	–	–	–
NOT ASSESSED	–	–	–	–	–	1/31(3.2%)	1/31(3.2%)	1/31(3.2%)

et al. suggested opposing tooth wear occurs if the crown surface is improperly glazed.<sup>20</sup> The adaptable property of stainless steel crown and polished occlusal surface of zirconia crowns could be the reason for prevention of opposing tooth wear (Table 3).

The results of this study suggests that both pediatric posterior zirconia crowns and stainless steel crowns maintained good proximal contact, marginal integrity with no opposing tooth wear. The results highlight the role of oral hygiene maintenance and health education on the gingival health with respect to crowns. The results also indicate the necessity of acquiring skills in preparing and placing the crowns to achieve best performance of the crowns.

Further studies are recommended following a split mouth design, testing different brands of commercially available zirconia crowns with varied level of polish, gloss, and morphological variations for a longer duration to get more valuable information on the clinical performance of preformed zirconia crowns. Further studies are recommended to test the crowns efficiency in varied clinical scenarios, such as crowded dentition, dentition with occlusal variation, and placement of multiple crowns.

Both stainless steel crowns and zirconia crowns are an excellent choice for posterior primary teeth as their clinical performance. But zirconia crowns can be the choice of postendodontic restoration when esthetics is of prime concern (Fig. 3).

## CONCLUSION

The following conclusions were drawn from the present study:

- Pediatric zirconia [93.5%] and stainless steel crowns [96.7%] showed good clinical success rate with no significant difference between the two groups [ $p = 0.317$ ].
- Crown retention, marginal integrity, accumulation of plaque, and gingival health were better with stainless steel crown compared to zirconia crowns but not to the significant level [ $p = 1.000$ ].
- Both stainless steel crowns and zirconia crowns showed no opposing tooth wear and established good proximal contact throughout the study period.

Clinical performance of zirconia and stainless steel crowns was good. The choice of the crowns during treatment plan can be made specific to each child based on the demands of the parents and the clinical scenario.

## ORCID

Santhosh Priya  <https://orcid.org/0000-0003-0887-8507>

## REFERENCES

1. O'Sullivan DM, Tinanoff N. The association of early dental caries patterns with caries incidence in preschool children. *J of Public Health Dent* 1996;56(2):81–83. DOI: 10.1111/j.1752-7325.1996.tb02401.x
2. Mendes FM, De Benedetto MS, Zardetto CG, et al. Resin composite restoration in primary anterior teeth using short-post technique and strip crowns: a case report. *Quintessence int* 2004;35(9):689–692. PMID 15470991.
3. Usha M, Deepak V, Venkat S, et al. Treatment of severely mutilated incisors: a challenge to the pedodontist. *J Indian Soc Pedod Prev Dent* 2007;25 Suppl:S34–S36. PMID 17921639.
4. Walia T, Salami AA, Bashiri R, et al. A randomised controlled trial of three aesthetic full-coronal restorations in primary maxillary teeth. *Eur J Paediatr Dent* 2014;15(2):113–118. PMID 25102458.
5. Messer LB, Levering NJ. The durability of primary molar restorations: II. Observations and predictions of success of stainless steel crowns. *Pediatr Dent* 1988;10(2):81–85. PMID 3269527.
6. Clinical AC. American Academy of Pediatric Dentistry. Guideline on pediatric restorative dentistry. *Pediatr Dent* 2012;34(5):173. PMID 23211906.
7. Abdulhadi BS, Abdullah MM, Alaki SM, et al. Clinical evaluation between zirconia crowns and stainless steel crowns in primary molars teeth. *J Pediatr Dent* 2017;5(1):21. DOI: 10.4103/jpd.jpd\_21\_17
8. Pani SC, Saffan AA, AlHobail S, et al. Esthetic concerns and acceptability of treatment modalities in primary teeth: a comparison between children and their parents. *Int J Dent* 2016 DOI:10.1155/2016/3163904
9. Fishman R, Guelmann M, Bimstein E. Children's selection of posterior restorative materials. *J Clin Pediatr Dent* 2007;31(1):1–4. DOI: 10.17796/jcpd.31.1.ng7122836mp04vj5
10. Fuks AB, Ram D, Eidelman E. Clinical performance of esthetic posterior crowns in primary molars: a pilot study. *Pediatr dent* 1999;21(7):445–448. PMID 10633519.
11. Ram D, Fuks AB, Eidelman E. Long-term clinical performance of esthetic primary molar crowns. *Pediatr Dent* 2003;25(6). PMID 14733474
12. Roberts C, Lee JY, Wright JT. Clinical evaluation of and parental satisfaction with resin-faced stainless steel crowns. *Pediatr Dent* 2001;23(1):28–31. PMID 11242727.
13. Tote J, Gadhane A, Das G, et al. Posterior esthetic crowns in pediatric dentistry. *Int J Dent Med Res* 2015;1(6):197.
14. Clark L, Wells MH, Harris EF, et al. Comparison of amount of primary tooth reduction required for anterior and posterior zirconia and stainless steel crowns. *Pediatr dent* 2016;38(1):42–46. PMID 26892214.
15. Holsinger DM, Wells MH, Scarbecz M, et al. Clinical evaluation and parental satisfaction with pediatric zirconia anterior crowns. *Pediatr dent* 2016;38(3):192–197. PMID 27306242.
16. Mathewson RJ, Primosch RE, Robertson D. Fundamentals of pediatric dentistry. *Quintessence*; 1995. <https://www.kinderkrowns.com/>.
17. Croll TP, Nicholson JW. Glass ionomer cements in pediatric dentistry: review of the literature. *Pediatr Dent* 2002;24(5):423–429.

18. Yilmaz Y, Dalmis A, Gurbuz T, et al. Retentive force and microleakage of stainless steel crowns cemented with three different luting agents. *Dent Mater J* 2004;23(4):577–584. DOI: 10.4012/dmj.23.577
19. Ashima G, Sarabjot KB, Gauba K, et al. Zirconia crowns for rehabilitation of decayed primary incisors: an esthetic alternative. *J Clin Pediatr Dent* 2014;39(1):18–22. DOI: 10.17796/jcpd.39.1.t6725r5566u4330g
20. Donovan TE. Factors essential for successful all-ceramic restorations. *J Amer Dental Assoc* 2008;139:S14–S18. DOI: 10.14219/jada.archive.2008.0360