

# Topical *Mentha piperita* Effects on Cutaneous Wound Healing: A Study on TGF- $\beta$ Expression and Clinical Outcomes

Mohammad Hosein Amirzade-Iranaq<sup>1</sup>, Maryam Tajik<sup>2,3</sup>, Alireza Takzaree<sup>4</sup>,  
Mina Amirmohammadi<sup>2</sup>, Farzane Rezaei Yazdi<sup>2</sup>, Nasrin Takzaree<sup>5\*</sup>

1. Universal Network of Interdisciplinary Research in Oral and Maxillofacial Surgery (UNIROMS), Universal Scientific Education and Research Network (USERN), Tehran, Iran
2. School of Medicine, Tehran University of Medical Sciences, Tehran, Iran
3. Students' Scientific Research Center, Tehran University of Medical Sciences, Tehran, Iran
4. Children's Medical Center, School of Medicine, Tehran University of Medical Sciences, Tehran, Iran
5. Department of Anatomy, School of Medicine, Tehran University of Medical Sciences, Tehran, Iran

## \*Corresponding Author:

Nasrin Takzaree

Department of Anatomy, School of Medicine, Tehran University of Medical Sciences, Tehran, Iran

Tel.: +098 912 213 7132

Email: [takzaree@gmail.com](mailto:takzaree@gmail.com)

Received: 6 Mar 2020

Accepted: 19 Nov 2021

## ABSTRACT

### BACKGROUND

Wound healing is a critical clinical concept. We aimed to evaluate the effects of topical *Mentha piperita* essence on cutaneous wound healing.

### METHODS

This randomized controlled trial was conducted in Tehran University of Medical Sciences, Tehran, Iran in 2019. Square-shaped 1.5×1.5 cm wounds were made on the neck of 60 male Wistar rats in a sterile condition. Samples were randomly divided into a control group and three experimental groups. Group A treated with *M. piperita* essence and Vaseline. The second group received the *M. piperita* essence, and the third group received Vaseline. Histological specimens were obtained in 4<sup>th</sup>, 7<sup>th</sup>, and 14<sup>th</sup> days and were explored for fibroblasts, epithelial cells, inflammatory cells, and vessels. RT-PCR was performed for molecular and gene expression evaluation of TGF- $\beta$ .

### RESULTS

The *M. piperita* essence increases TGF- $\beta$  gene expression as an important factor in wound healing. After 14 d, group A, who received *M. piperita* and Vaseline, had 99.73% of wound healing with the mean wound size of 0.006 cm<sup>2</sup> while wound healing in the control group was only 52%. Samples treated with *M. piperita* have 74.58% wound healing following by group treated with Vaseline, which was 67.02% ( $P < 0.05$ ), respectively.

### CONCLUSION

The application of the *M. piperita* essence for wound healing accelerates the process and improves outcomes.

### KEYWORDS

*Mentha piperita*; Peppermint; Wound healing; Herbal medicine; TGF- $\beta$

### Please cite this paper as:

Amirzade-Iranaq MH., Tajik M., Takzaree A., Amirmohammadi M., Rezaei Yazdi F., Takzaree N., Topical *Mentha piperita* Effects on Cutaneous Wound Healing: A Study on TGF- $\beta$  Expression and Clinical Outcomes. *World J Plast Surg.* 2022;11(1):86-96.

doi: 10.52547/wjps.11.1.86

## INTRODUCTION

One of the most important issues in medical science is tissue repair after devastations due to trauma. Physicians have been searching for an effective way of wound healing in the shortest possible time with the least complications<sup>1,2</sup>.

Synthetic drugs are shown to have more adverse effects and limitations. Hence, researchers are looking for a natural combination to accelerate wound healing<sup>3, 4</sup>. In the past, natural ingredients, especially medicinal plants, were the basic and even the only treatment in some conditions. Their raw materials were used in the pharmaceutical industry<sup>5</sup>. Mankind has been using honey, mint, garlic, aloe vera, fish oil, and similar materials as medication in wound healing for many years<sup>3</sup>. A new tendency to use medicinal plants is spreading around the world<sup>3, 6, 7</sup>.

Various growth factors, such as transforming growth factor- $\beta$  (TGF- $\beta$ ), affect the healing process. TGF- $\beta$ , the most powerful factor in tissue repair, is released after degranulation of platelets in the wound area<sup>8</sup>. This factor is also a crucial fibrogenic moderator of connective tissue<sup>9</sup>.

*Mentha piperita* (peppermint) belongs to the Lamiaceae family and is one of the most widely used herbal medicine. This perennial herbaceous has quadrangular stems and light purple flowers in the form of compound clusters. Peppermint contains a considerable amount of menthol (40.7%). Dried mint has 0.3%-0.4% menthol. Moreover, the oil contains menthone (23.4%), menthyl esters, especially menthyl acetate, limonin, pulegone, caryophyllene, and pinene. There are also different flavonoids in this plant, such as Eriocitrin, hesperidin, and kaempferol<sup>9</sup>.

Peppermint leaves are useful for intestinal inflammation, buccal mucosa inflammation, coryza, and respiratory problems, due to their antispasmodic features. The topical use of peppermint oil helps reduce neuromuscular pains. This oil is also known for fungicidal, antimicrobial, antiseptic, antipyretic, and anti-aging properties<sup>9</sup>.

This study aimed to evaluate the effects of topical *M. piperita* essence on wound healing considering critical variables such as clinical outcome, amount of fibroblast, epithelial cells, inflammatory cells and vessels, and TGF- $\beta$  gene expression.

## **MATERIALS AND METHODS**

### **Essence Preparation**

Fresh *M. piperita* leaves were collected from gardens of the medicinal plants of Kashan (Iran) in June 2019. They were washed, dried, and powdered at room temperature after the pharmacognosy approval. The

amount of 100 gr of the powder was mixed in the Clevenger balloon (Hei-VAP Platinum 3 Rotary Evaporator, Heidolph, Germany) with 400 milliliters of water. The essence was prepared by the Clevenger after 5 hours. We kept this essence in the dark glass container in the refrigerator after dehydration with sodium anhydride sulfate (Merck, Germany). The main constituents of this essence were menthol (39.8%), menthone (19.5%), neomenthol (8.83%), and acetyl menthol (8.64%).

### **Surgical method**

The ethics committee of Tehran University of Medical Sciences, School of Medicine confirmed the method of this study with the ethics code: IR.TUMS.MEDICINE.REC.1397.322.

Sixty adult healthy male Wistar rats were included in this study. The samples were kept in cages individually with 12 h of light each day. Proper food and water were available for each sample.

On the surgery day (day 0), rats were anesthetized with 5 mg/100 g Ketamine Hydrochloride (Ketalar, Gedeonrichter, Germany) as the primary anesthetic and 0.04 mg/100 g Pentazocine (Pentazocine, Toliddaru, Iran) as the pre-anesthetic drug. Diazepam (Valium, Chemidarou, Iran) with a dose of 0.45 mg/100 g was added to relax the muscles<sup>6, 10</sup>. Samples received all these drugs by intramuscular injection.

Neck hair shaved and surgery sites sterilized with Povidone Iodine (Betadine, Chemidarou, Iran). We used a 1.5×1.5 cm square-shaped stencil to make wounds on the back of their necks. The wound was made in a sterile condition and contained the full thickness of the skin. After that, wounds were washed with normal saline and determined treatment started.

The rats were randomly divided into one control group and three experimental groups. The first experimental group (group A) was treated with 5mg of *M. piperita* essence and Vaseline once a day. Group B received 5mg of *M. piperita* essence each day, and group C received Vaseline. Samples in the control group did not receive any treatment.

### **Wound healing assay**

Wound sizes and healing percentage were measured on 1<sup>st</sup>, 4<sup>th</sup>, 7<sup>th</sup>, 10<sup>th</sup>, and 14<sup>th</sup> d after starting the treatment. For this purpose, a photograph was obtained from the wounds with a ruler beside it.

Then the exact wound size was measured with Image J software (Digital Image Processing for Medical Applications Image J 1.46 r, Java 1.6.0-20 Cambridge University). At the end of each course, the rats were sacrificed by inhaling carbon dioxide (CO<sub>2</sub>). Wound healing percentage calculated with the following formula:

#### Recovery Percentage

$$\frac{\text{wound surface on the first day} - \text{wound surface on the day } x}{\text{wound surface on the first day}} \times 100$$

#### Histological study

On the 4<sup>th</sup>, 7<sup>th</sup> and 14<sup>th</sup> d after starting the treatment, histological specimens were obtained under general anesthesia. Specimens were divided into two parts, one soaked in 10% formalin for tissue processing, and the other part was used to evaluate gene expression using reverse transcription-polymerase chain reaction (RT-PCR) technique. For tissue processing, specimens were stained with specific Masson's trichrome to assess the density of the collagen fibers and Hematoxylin and Eosin (H&E) staining to assess other cells. Using a light microscope (CX31-OLYMPUS, Japan) and a magnification field of 40×, specimens were investigated to explore 10 areas of each wound surface. ImageJ software version 1.45 (imagej.nih.gov/ij/UK) was used to count fibroblasts, neutrophils, macrophages, and vessels.

#### Quantitative Reverse transcription PCR (RT-PCR)

RT-PCR was performed for molecular and gene expression evaluations in each group. First, the primer was designed (Table 1), and the RNA was extracted from the tissue using RNX™ (PLUS) kit (CinnaGen, Iran)<sup>11</sup>. Electrophoresis of agarose gel and ultraviolet spectrophotometry was performed to check the quality and the quantity of the extracted RNA. The RNA was converted to cDNA and proliferated with the PCR technique and was evaluated for TGF-β gene expression. Reverse transcription of the extracted RNA was performed using the AccuPower® RocketScript™ RT PreMix kit (Bioneer Company). The produced cDNAs were used as transcription patterns for performing PCR.

#### RT-PCR product electrophoresis on agarose gel

Electrophoresis was done on the PCR product on agarose gel 1% after performing PCR. The electrophoresis was done on the samples with a voltage of 150 volts for 25 minutes. After performing electrophoresis, the produced bands were observed and interpreted by projecting ultraviolet rays using a UV transilluminator device.

#### Data Analysis

The data of this study analyzed using SPSS software version 20 (IBM corporation, New York, US), and all the graphs were prepared with Prism software version 6 (GraphPad Inc., California, US).

A modified histologic scoring system (Abramov's scoring system) was introduced for wound healing<sup>12</sup>. Quantitative data were reported by mean ± standard deviation (SD). We used the Shapiro-Wilk test of normality to check if the distribution is normal. Mann-Whitney U test was performed to compare data between groups. All the tests were 2-tailed. The Significance level was considered  $P < 0.05$ .

#### RESULTS

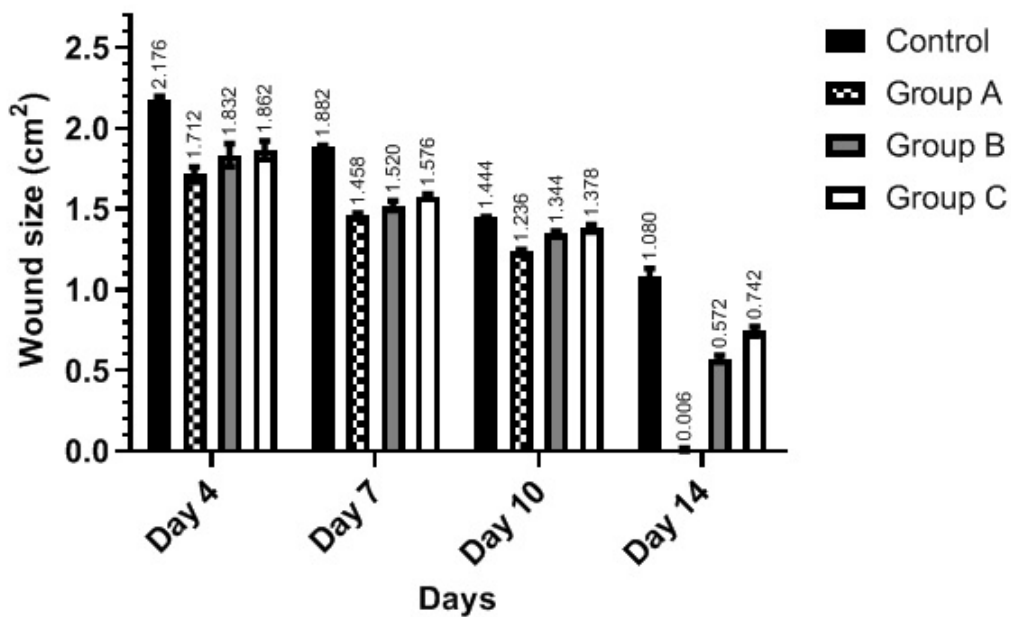
Sixty healthy adult male Wistar rats were used in this study. The first experimental group (group A) treated with 5 mg of *M. piperita* essence and Vaseline once a day. Group B received 5mg of *M. piperita* essence each day, and group C received Vaseline. Samples in the control group did not receive any treatment. The wound healing process was investigated based on both microscopic and macroscopic findings.

#### Macroscopic Findings

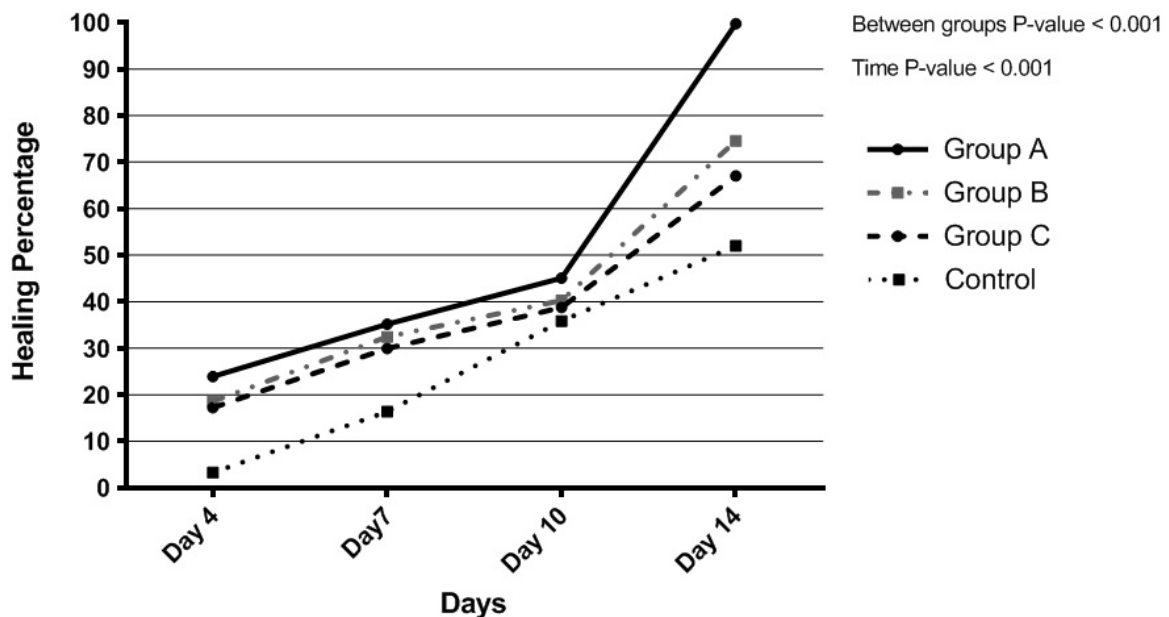
Figure 1 reveals the mean of wound size in each group on different days. At the beginning of the study, all rats had the same 2.25 cm<sup>2</sup> wound at the back of their neck. On 4<sup>th</sup> day, the wound size of group A (1.71±0.037 cm<sup>2</sup>) was significantly smaller than the control group (2.17±0.017 cm<sup>2</sup>) ( $P=0.009$ ). Groups B and C did not show a significant difference with each other ( $P=0.394$ ). However, both had significantly smaller wound sizes compared to the control group ( $P < 0.001$  for both).

**Table 1:** TGF-β gene-specific primers designed to evaluate the TGF-β gene expression

	Template strand	Length	Start	Stop	Tm	GC%
Forward primer	AGGAGACGGAATACAGGGCT	20 (plus strand)	775	794	60.03	55.00
Reverse primer	GGATCCACTTCCAACCCAGG	20 (minus strand)	1079	1060	60.03	60.00



**Fig. 1:** Wound size of each group in 4, 7, 10, and 14 days after starting the treatment. Group A: *Mentha piperita* and Vaseline, Group B: *Mentha piperita*, and Group C: Vaseline



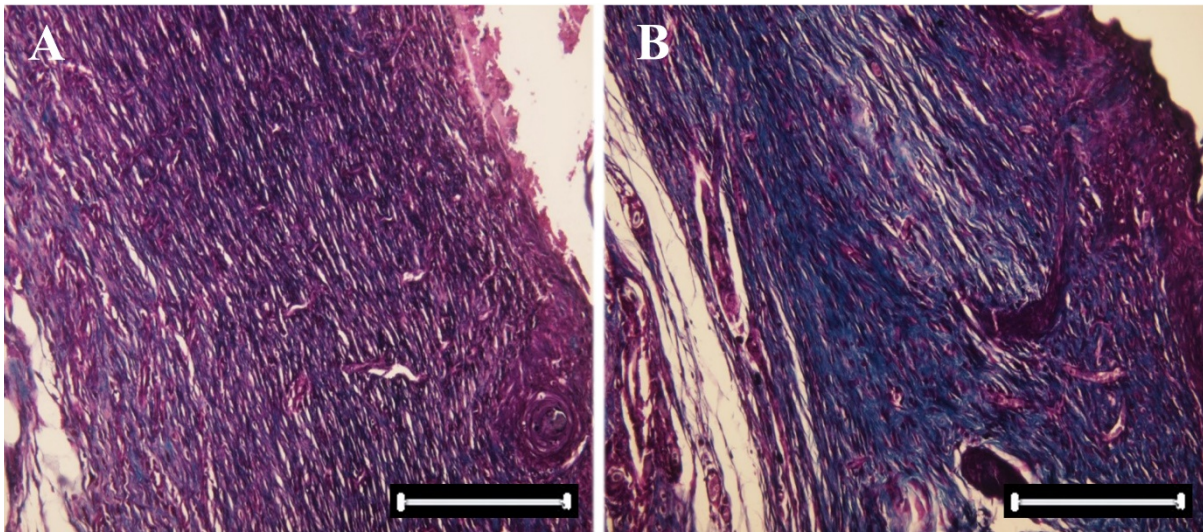
**Fig. 2:** Healing percentage of each group during the study. Group A: *Mentha piperita* and Vaseline, Group B: *Mentha piperita*, and Group C: Vaseline

Wound healing progressed until day 14, and the wound size decreased significantly from the beginning until day 14 in all groups ( $P < 0.001$ ).

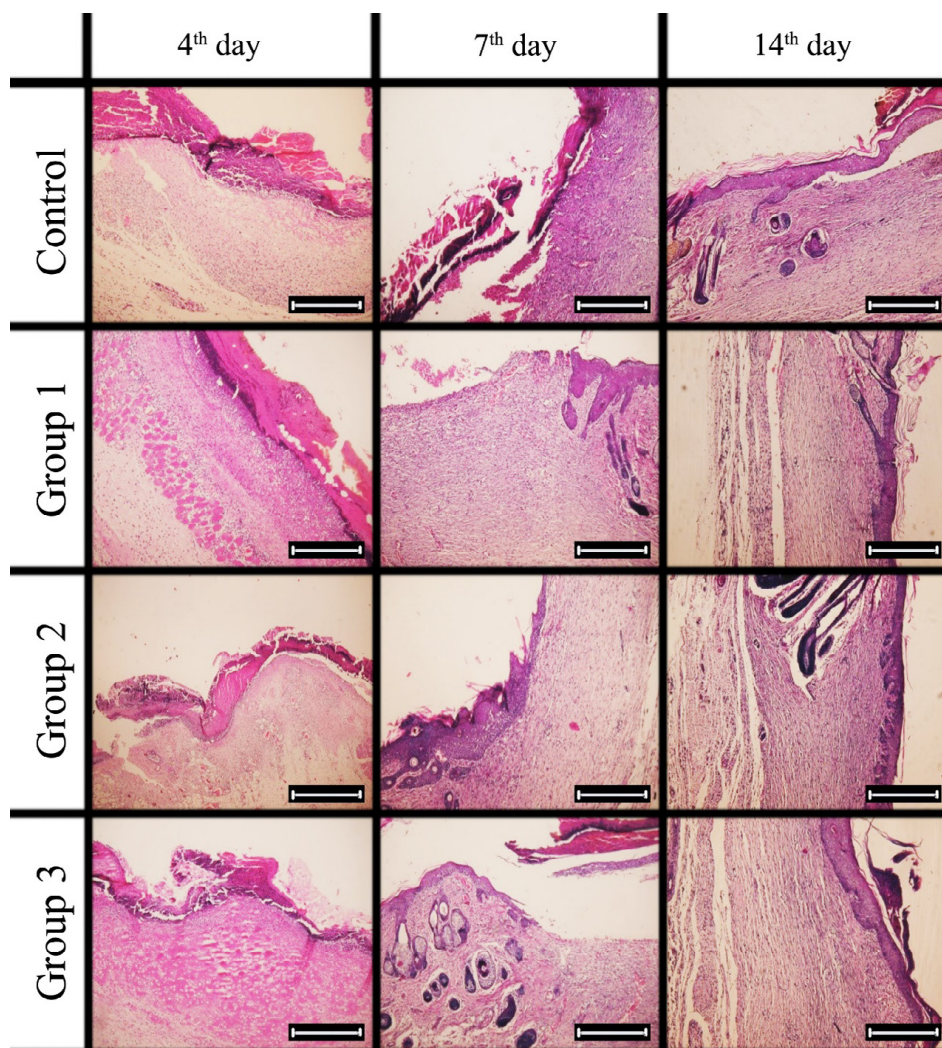
At the end of the study (day 14), the mean wound size of group A ( $0.006 \pm 0.008 \text{ cm}^2$ ) was significantly smaller than the control group ( $1.08 \pm 0.41 \text{ cm}^2$ ), group B ( $0.572 \pm 0.16 \text{ cm}^2$ ) and group C ( $0.742 \pm 0.023$

$\text{cm}^2$ ) ( $P < 0.001$ ). Moreover, the wound size was smaller in group B in comparison with group C and the control group, and the difference was significant ( $P < 0.001$ ).

We measured the wound healing percentage by using the mentioned formula in the 4<sup>th</sup>, 7<sup>th</sup>, 10<sup>th</sup>, and 14<sup>th</sup> days. As Figure 2 demonstrates, the healing



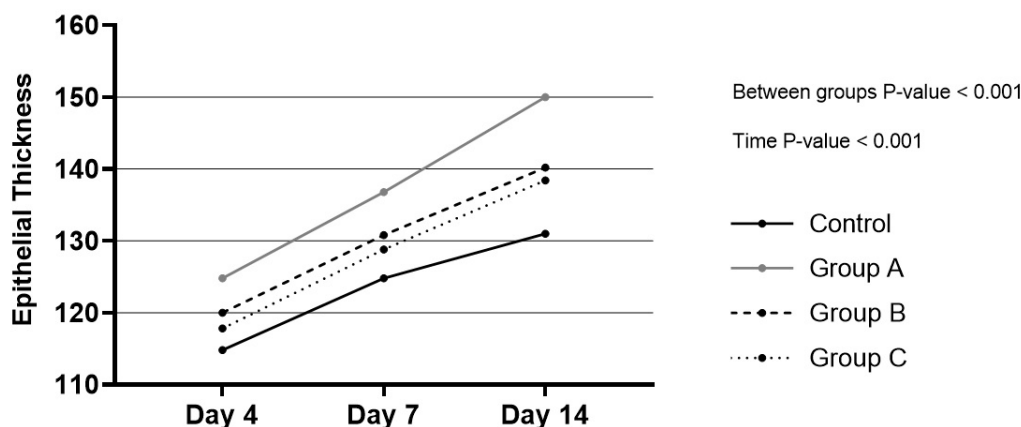
**Fig. 3:** Photomicrographs of histopathological sections representing skin wounds of rat groups following treatment for 14 days. (Staining, H&E  $\times 10$ )



**Fig. 4:** Microscopic view of open cutaneous wounds: (a) control group: collagen fibers are lesser than the experimental group in this photomicrograph. (b) The experimental group (*Mentha piperita*), collagen fibers are more than the control group in this photomicrograph (specific staining, Masson's trichrome  $\times 10$ )

**Table 2:** Mean ± SD of the fibroblasts, vessels, neutrophils, and macrophages of the wounds bed in 4th, 7th, and 14th day of the experiment. The highest number of each cell group highlighted

Groups	Parameters	Days			P-value
		Day 4	Day 7	Day 14	
Control	Fibroblasts	54.6 ± 0.548	83.20 ± 0.83	81.00 ± 0.70	<0.001
	Vessels	4 ± 0.70	9.4 ± 0.54	6.8 ± 0.83	<0.001
	Inflammatory cells	22 ± 2	17.4 ± 0.54	7.2 ± 0.44	<0.001
Group-A	Fibroblasts	68.2 ± 0.83	114.4 ± 3.05	111.80 ± 1.48	<0.001
	Vessels	8 ± 1	15.4 ± 0.89	11.6 ± 1.89	<0.001
	Inflammatory cells	13.4 ± 0.54	10.40 ± 0.54	1.40 ± 0.54	<0.001
Group-B	Fibroblasts	65 ± 1.22	102.6 ± 2.40	100.8 ± 0.83	<0.001
	Vessels	6.6 ± 0.54	12.6 ± 1.14	9.6 ± 1.14	<0.001
	Inflammatory cells	15.2 ± 0.83	11.4 ± 1.34	2.40 ± 0.54	<0.001
Group-C	Fibroblasts	64 ± 1.22	101.8 ± 2.16	97.2 ± 1.78	<0.001
	Vessels	5.8 ± 0.83	11.8 ± 0.83	7.80 ± 1.09	<0.001
	Inflammatory cells	16.4 ± 0.89	13.8 ± 0.83	3.40 ± 0.54	<0.001



**Fig. 5:** Epithelial width of each group during the study. Group A: *Mentha piperita* and Vaseline, Group B: *Mentha piperita*, and Group C: Vaseline.

percentage was the highest in group A (the one with received both treatments), followed by group B (the one who received *M. piperita*). The control group had the lowest healing percentage. As explained, the application of both Vaseline and *M. piperita* essence provided almost 100% (99.734%) healing, whereas without receiving any treatment, the healing percentage reduces to almost half (51.998%).

**Microscopic Findings**

Microscopic specimens were obtained after sacrificing samples from each group on the 4<sup>th</sup>, 7<sup>th</sup>, and 14<sup>th</sup> d of the experiment. Specimens were stained with Hematoxylin and Eosin (H&E) to investigate the fibroblasts, neutrophils, macrophages, and vessels. Specific Masson’s Trichrome staining to assess the density of collagen fibers (Figure 3 & 4).

The number of neutrophils, macrophages, fibroblasts, and wound thickness of group A that received mint essence and Vaseline is significantly different from the control group ( $P < 0.009$ ).

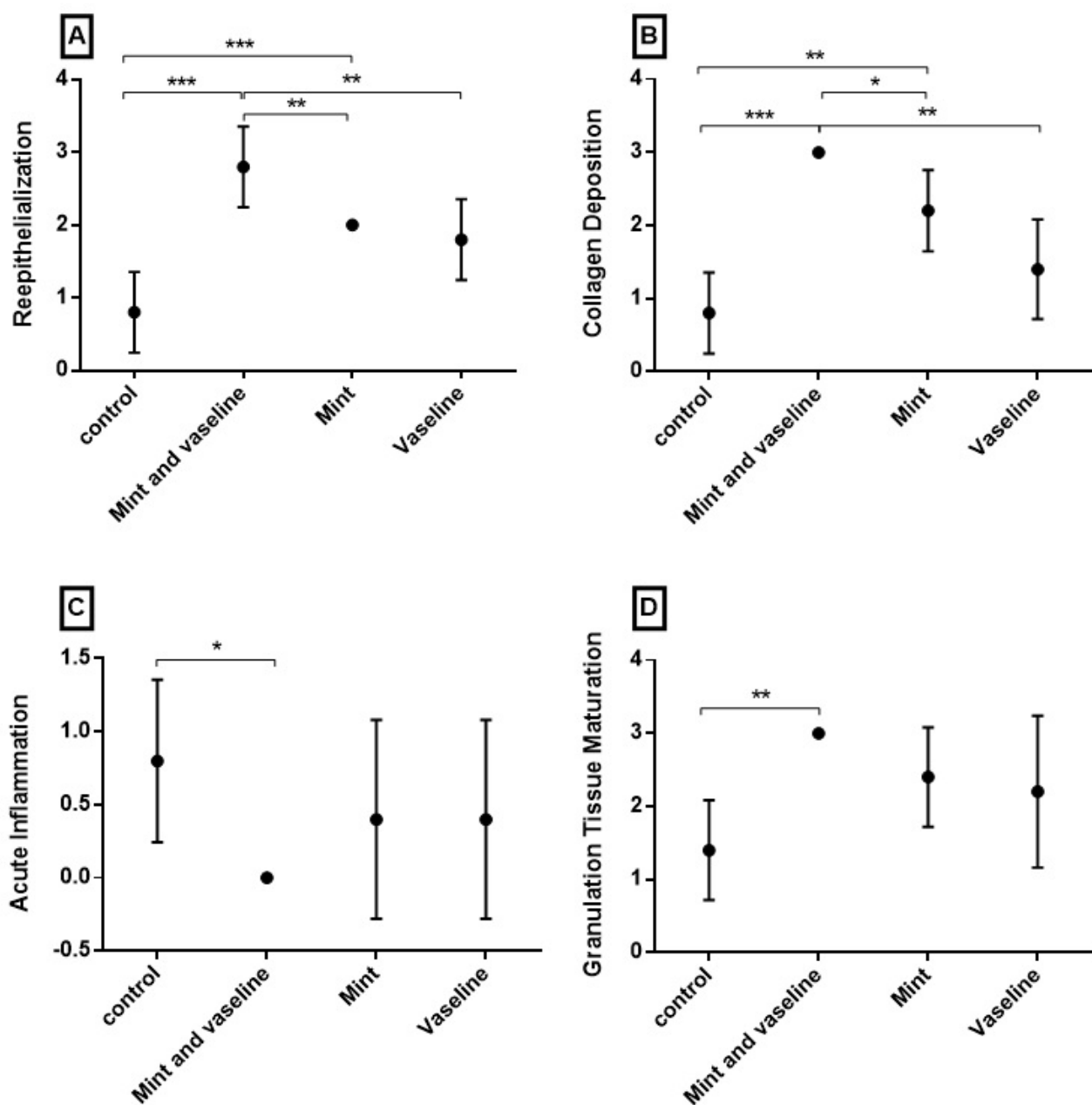
As shown, the highest level of fibroblasts and vessels was found on day 4, which is the proliferative phase of wound healing. The number of vessels and fibroblasts was always the highest in group A and the lowest in the control group. The number of inflammatory cells had a downward trend in all groups, but the lowest level always belonged to group A. Meanwhile, the control group had the highest number of these cells during the whole period (Table 2).

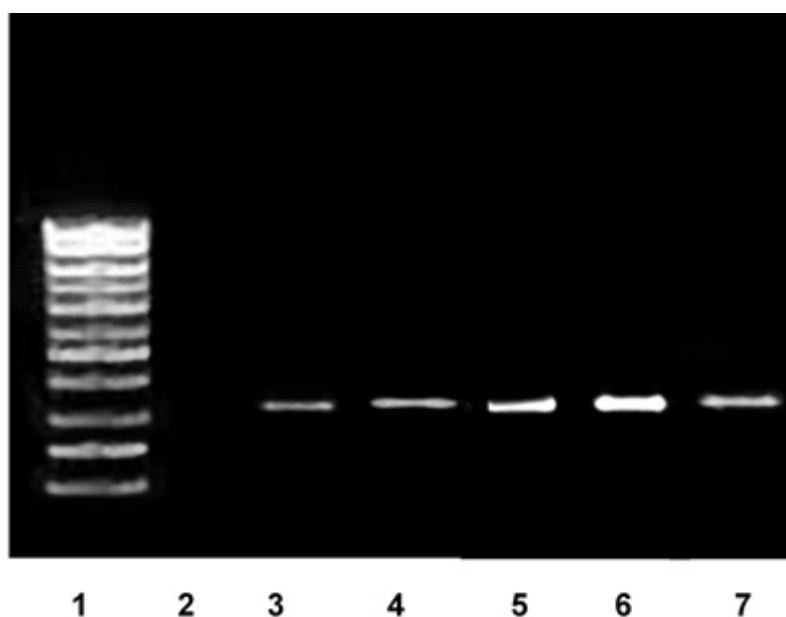
Figure 5 illustrates the epithelial width of each study group in days 4, 7, and 14, which reveals an ascending trend in all the groups, but group A

**Table 3:** Abramov's histological scoring system for wound repair

Parameter	Score			
	0	1	2	3
Acute inflammation	None	Scant	Moderate	Abundant
Chronic inflammation	None	Scant	Moderate	Abundant
Amount of granulation tissue	None	Scant	Moderate	Abundant
Granulation tissue maturation	Immature	Mild maturation	Moderate maturation	Fully matured
Collagen deposition	None	Scant	Moderate	Abundant
Re-epithelialization	None	Partial	Complete but immature or thin	Complete and mature
Neovascularization	None	Up to five vessels per	6 to 10 vessels per HPF	More than 10 vessels per HPF

HPF= High Power Field

**Fig. 6:** Mean  $\pm$  95% confidence interval of Scoring of wound healing in different groups at the end of the study based on Abramov's scoring system. (\*= P-Value <0.05; \*\*= P-Value <0.01; \*\*\* = P-Value <0.001)



**Fig. 7:** Evaluation of TGF- $\beta$  gene expression (PCR size: 305 bp) in the wound bed at 7th days after injury by RT-PCR technique in the treatment groups. 1: Ladder 100 bp, 2: Negative control (H<sub>2</sub>O) of PCR, 3: Negative control of TGF- $\beta$ , 4: Control, 5: *Mentha piperita*, 6: *Mentha piperita* & Vaseline, 7: Vaseline.

always had the most values.

A modified histologic scoring system (Abramov's scoring system) was introduced for wound healing. Several factors are included in this system. Each parameter receives a score from zero to three independently. We compared re-epithelialization, collagen deposition, acute inflammation, and granulation tissue maturation between our groups using this scoring system (Table 3).

Figure 6 illustrates Abramov's score of different study groups on the last day of the experiment. Group-A that received *M. piperita* essence and Vaseline had a significant difference in re-epithelialization ( $P < 0.001$ ), collagen deposition ( $P < 0.001$ ), acute inflammation ( $P = 0.016$ ) and granulation tissue maturation ( $P = 0.02$ ) compared to control group. However, there was no significant difference between group-A and other experimental groups in acute inflammation and granulation tissue maturation.

#### **RT-PCR product electrophoresis on agarose gel**

After performing PCR, we ran electrophoresis on agarose gel 1% with a voltage of 150 volts for 25 minutes. Then, ultraviolet ray was projected to the gel using a UV transilluminator device and produced bands were observed and interpreted (Figure 7).

## **DISCUSSION**

Wound healing is a complicated and organized process divided into three phases, including inflammation, proliferation, and remodeling (reconstructing). Therefore, improving each of these stages can result in the acceleration of wound healing and a decrease in complications.

The *M. piperita* (Peppermint) essence improves the healing process by preventing infections and microorganisms' growth. The *M. piperita* essence had more bactericidal effects on gram-positive bacteria than gram-negative ones<sup>13,14</sup>. Antimicrobial property of *M. piperita* essence was studied in food system models; and documented that this feature is a result of *M. piperita* components including menthol and ketones such as pulegone, iso menthone, piperitone, carvone, and dehydrocarvone. Thymol has a high inhibitory effect on pathogen fungi like *Aspergillus* and *Candida albicans*<sup>15</sup>. Methanol of the peppermint essence has a great antifungal activity on *Candida albicans*, *Sacromices servizieh*, and *Penicillium nutanum*<sup>16</sup>.

The *M. piperita* essence helps with wound healing acceleration in several ways. *M. piperita* essence increases expression of the Transforming growth



factor- $\beta$  (TGF- $\beta$ ) gene as an important factor in wound healing. Platelets release TGF- $\beta$ 1. This isoform attracts neutrophils, macrophages, and other cells that increase the TGF- $\beta$ 1 level<sup>17, 18</sup>. In the inflammatory phase, the number of neutrophils is maximized. In the next phase, macrophages are dominant cells. Lactate and other mediators released from macrophages cause fibroblasts proliferation and angiogenesis. According to the present study, the topical use of the *M. piperita* essence shortens the inflammatory period, reduces the inflammatory cells such as neutrophils, and increases the macrophages. These changes cause an increase in angiogenesis and fasten wound healing in experimental groups in comparison to the control group ( $P < 0.05$ ).

The proliferation phase starts after the inflammation. Fibroblasts activate in this phase and produce collagen and glycosaminoglycan. In other words, fibroblasts are builders of new tissue. In large skin injuries, a severe reduction in the number of fibroblasts is the cause of delay or failure of repair. Platelets and macrophages secrete chemotactic materials that induce sprouting of new vessels from the venue. Therefore, angiogenesis can be induced by adding chemotactic materials to the tissue. Mint essence can help with the induction of angiogenesis and epithelialization.

In an open wound, capillaries increase along with the cells' proliferation. A dense population of macrophages, fibroblasts, and vessels penetrate the collagen and hyaluronic acid matrix. These events create granulated tissue. Every factor that augments vascularization accelerates wound healing.

Peppermint essence speeds up angiogenesis and helps to build granulated tissue. In this research also, the number of vessels was significantly higher in the experimental groups ( $P < 0.009$ ).

Histopathological studies 7 d after creating the wound reveal the beginning of the second step in healing, which is cell proliferation with fibroblast migration and epithelialization (Figure 5). The results of our study indicated that topical use of *M. piperita* essence increases the migration of fibroblasts to wound area, epithelialization, and acceleration of wound healing in the second phase of repairing in comparison to control group (Figure 1).

The number of fibroblasts increases due to applying peppermint essence in the wound, and this causes growing granulated tissue with higher speed (Table 2). Proliferated fibroblasts secrete collagen and

proteoglycans. These results to wound closure. The essence also reduces the inflammation and speeds up fibroblasts transformation<sup>19</sup>.

The amount of wound closure is a pragmatic scale to evaluate wound healing. Wound closure is related to fibroblasts and myofibroblasts activity in granulation tissue. The percentage and speed of wound healing were significantly higher in the experimental group that received the *M. piperita* essence (Figures 1 & 2). In the present study, day 14 is considered the wound healing process reconstruction phase. On this day, excess of fibroblasts numbers and collagen fibers in the experimental group compared to the control group reveals the healing process continues until the 14<sup>th</sup> day. Epithelialization and differentiation of the epidermis continue at maximum level as long as the wound area is kept wet. In the experimental group, wound thickness has decreased in a shorter time because of the *M. piperita* essence. In addition, healing power and wound closure are developed faster than previous groups. TGF- $\beta$  causes an increase in mitosis power in the skin fibroblasts<sup>19</sup>. This factor is recognized as a key mediator in the stimulation of fibroblasts and extracellular matrix accumulation<sup>20, 21</sup>. In this study, a further expression of TGF- $\beta$  causes an increase in cellular activity, especially fibroblasts (Figure 7).

In addition, the *M. piperita* essence increases collagen synthesis (Figure 6); therefore, the healing accelerates.

As our macroscopic and microscopic findings demonstrate, the average wound healing seems to be the highest while using both Vaseline and *M. piperita* essence as the treatment. Application of peppermint as a single treatment ranks as the second effective method, followed by using Vaseline only.

Various studies have studied the *M. piperita* plant topical use in different areas: cutaneous wound healing acceleration, antimicrobial activity, and analgesic effects. In India, the effectiveness of *M. piperita* on wound healing acceleration was studied in streptozotocin-induced diabetic rats<sup>22</sup>. Literature indicates the *M. piperita* antibacterial potential effect<sup>23</sup>. Analgesic effects of *M. piperita* were also studied by literature, and the *M. piperita* essence was proved to have strong analgesic effects in the experiment<sup>24</sup>.

A parallel study evaluated the topical application of *M. piperita* essential oil's effects on wound healing in the infected mice model. The migration rate of

fibroblasts, collagen production and secretion, and regeneration of epithelial tissue was increased in the groups treated with *M. piperita*<sup>19</sup>.

Comprehensively, according to the results of the present study and other researchers, the use of *M. piperita* essence has led to an increase in expression of TGF- $\beta$  gene in the wound area and has provided wound healing essentials by stimulation of growth factors release and providing a suitable environment in the wound area. The essence has antibacterial effects because of having thymol, menthol, phenol and flavonoid combinations, and oxidants like terpenes. In addition, due to the antioxidant effects of the mentioned chemicals, it has been able to increase angiogenesis, fibroblast proliferation, epithelialization as well as controlling skin infection and acceleration of wound healing.

## CONCLUSION

According to histologic measures, gene expression amount wound diameter and healing percentage topical use of *M. piperita* essence is effective in rats' cutaneous open wound healing. It shortens the inflammatory phase, deepens the granulated tissue, helps with angiogenesis, causes the proliferative phase to start sooner, and finally accelerates wound healing.

## FINANCIAL SOURCE

We received no financial support for this study.

## CONFLICT OF INTEREST

The authors declare that there is no conflict of interest.

## REFERENCES

1. Han G, Ceilley R. Chronic wound healing: a review of current management and treatments. *Adv Ther* 2017;**34**(3):599-610.
2. Marshall CD, Hu MS, Leavitt T, Barnes LA, Lorenz HP, Longaker MT. Cutaneous scarring: Basic science, current treatments, and future directions. *Adv Wound Care* 2018;**7**(2):29-45.
3. Delfan B, Bahmani M, Eftekhari Z, Jelodari M, Saki K, Mohammadi T. Effective herbs on the wound and skin disorders: a ethnobotanical study in Lorestan province, west of Iran. *Asian Pacific Journal of Tropical Disease* 2014;**4**:S938-S42.
4. Takzaree N, Hadjiakhondi A, Hassanzadeh G, Rouini MR, Manayi A. Synergistic Effect of Honey and Propolis on Cutaneous Wound Healing in Rats. *Acta Med Iran* 2016 Apr;**54**(4):233-9.
5. Mir M, Ali MN, Barakullah A, et al. Synthetic polymeric biomaterials for wound healing: a review. *Progress in Biomaterials* 2018;**7**(1):1-21.
6. Lindley LE, Stojadinovic O, Pastar I, Tomic-Canic M. Biology and biomarkers for wound healing. *Plast Reconstr Surg* 2016;**138**(3):18S.
7. Shah A, Amini-Nik S. The role of phytochemicals in the inflammatory phase of wound healing. *Int J Molecul Sci* 2017;**18**(5):1068.
8. Chicharro-Alcántara D, Rubio-Zaragoza M, Damiá-Giménez E, et al. Platelet rich plasma: new insights for cutaneous wound healing management. *Journal of Functional Biomaterials* 2018;**9**(1):10.
9. Mahendran G, Rahman LU. Ethnomedicinal, phytochemical and pharmacological updates on Peppermint (*Mentha piperita* L.)—A review. *Phytother Res* 2020.
10. Lynch SE, Colvin RB, Antoniades HN. Growth factors in wound healing. Single and synergistic effects on partial thickness porcine skin wounds. *The Journal of Clinical Investigation* 1989;**84**(2):640-6.
11. Takzaree N, Hadjiakhondi A, Hassanzadeh G, Rouini MR, Manayi A, Zolbin MM. Transforming growth factor-beta (TGF-beta) activation in cutaneous wounds after topical application of aloe vera gel. *Can J Physiol Pharmacol* 2016 Dec;**94**(12):1285-90.
12. Abramov Y, Golden B, Sullivan M, et al. Histologic characterization of vaginal vs. abdominal surgical wound healing in a rabbit model. *Wound Repair Regen* 2007 Jan-Feb;**15**(1):80-6.
13. İşcan G, Kırimer N, Kürkcüoğlu Mn, Başer HC, DEMİrci F. Antimicrobial screening of *Mentha piperita* essential oils. *J Agric Food Chem* 2002;**50**(14):3943-6.
14. Sivropoulou A, Papanikolaou E, Nikolaou C, Kokkini S, Lanaras T, Arsenakis M. Antimicrobial and cytotoxic activities of *Origanum* essential oils. *J Agric Food Chem* 1996;**44**(5):1202-5.
15. Giordani R, Regli P, Kaloustian J, Mikail C, Abou L, Portugal H. Antifungal effect of various essential oils against *Candida albicans*. Potentiation of antifungal action of amphotericin B by essential oil from *Thymus vulgaris*. *Phytother Res* 2004;**18**(12):990-5.
16. Mathur A, Purohit R, Mathur D, Prasad G, Dua V. Pharmacological investigation of methanol extract of *Mentha piperita* L. roots on the basis of antimicrobial, antioxidant and anti-inflammatory properties. *Der Pharmacia Sinica* 2011;**2**(1):208-16.
17. Chang Z, Kishimoto Y, Hasan A, Welham NV. TGF- $\beta$ 3 modulates the inflammatory environment

- and reduces scar formation following vocal fold mucosal injury in rats. *Dis Model Mech* 2014;7(1):83-91.
18. Sun T, Adra S, Smallwood R, Holcombe M, MacNeil S. Exploring hypotheses of the actions of TGF- $\beta$ 1 in epidermal wound healing using a 3D computational multiscale model of the human epidermis. *PLoS One* 2009;4(12):e8515.
  19. Modarresi M, Farahpour M-R, Baradaran B. Topical application of Mentha piperita essential oil accelerates wound healing in infected mice model. *Inflammopharmacology* 2019;27(3):531-7.
  20. Crider BJ, Risinger Jr GM, Haaksma CJ, Howard EW, Tomasek JJ. Myocardin-related transcription factors A and B are key regulators of TGF- $\beta$ 1-induced fibroblast to myofibroblast differentiation. *J Invest Dermatol* 2011;131(12):2378-85.
  21. Mott GA, Costales JA, Burleigh BA. A soluble factor from Trypanosoma cruzi inhibits transforming growth factor- $\beta$ -induced MAP kinase activation and gene expression in dermal fibroblasts. *PLoS One* 2011;6(9):e23482.
  22. Umasankar K, Nambikkairaj B, Backyavathi M. Wound healing activity of topical Mentha piperita and Cymbopogon citratus essential oil on streptozotocin induced rats. *Asian J Pharm Clin Res* 2013;6:180-3.
  23. Sujana P, Sridhar TM, Josthna P, Naidu CV. Antibacterial activity and phytochemical analysis of Mentha piperita L.(peppermint)—an important multipurpose medicinal plant. *Am J Plant Sci* 2013;4(01):77.
  24. Taher YA. Antinociceptive activity of Mentha piperita leaf aqueous extract in mice. *Libyan J Med* 2012;7(1):16205.