



Since January 2020 Elsevier has created a COVID-19 resource centre with free information in English and Mandarin on the novel coronavirus COVID-19. The COVID-19 resource centre is hosted on Elsevier Connect, the company's public news and information website.

Elsevier hereby grants permission to make all its COVID-19-related research that is available on the COVID-19 resource centre - including this research content - immediately available in PubMed Central and other publicly funded repositories, such as the WHO COVID database with rights for unrestricted research re-use and analyses in any form or by any means with acknowledgement of the original source. These permissions are granted for free by Elsevier for as long as the COVID-19 resource centre remains active.



Coronavirus Disease 2019 Positivity Immediately After Lung Transplantation: A Case Report

Yuhei Yokoyama^a, Yuriko Terada^a, Ruben G. Nava^a, Varun Puri^a, Daniel Kreisel^a, G. Alexander Patterson^a, Ramsey R. Hachem^b, and Tsuyoshi Takahashi^{a*}

^aDivision of Cardiothoracic Surgery, Department of Surgery, Washington University School of Medicine, St. Louis, MO, USA; and ^bDivision of Pulmonary and Critical Care, Department of Medicine, Washington University School of Medicine, St. Louis, MO, USA

ABSTRACT

Management of COVID-19 in lung transplant recipients is challenging. We report a case of a 71-year-old male who underwent bilateral lung transplantation with an unexpected case of COVID-19. The patient had been fully vaccinated. The patient and donor tested negative for pretransplant COVID-19. On routine bronchoscopy on day 1 after transplant, the COVID-19 test was positive. Mycophenolic mofetil and the second dose of basiliximab were skipped, but tacrolimus and prednisone were continued. He was treated with casirivimab/imdevimab and remdesivir. He was discharged on day 14 and has had no episodes of acute rejection during the 3 months.

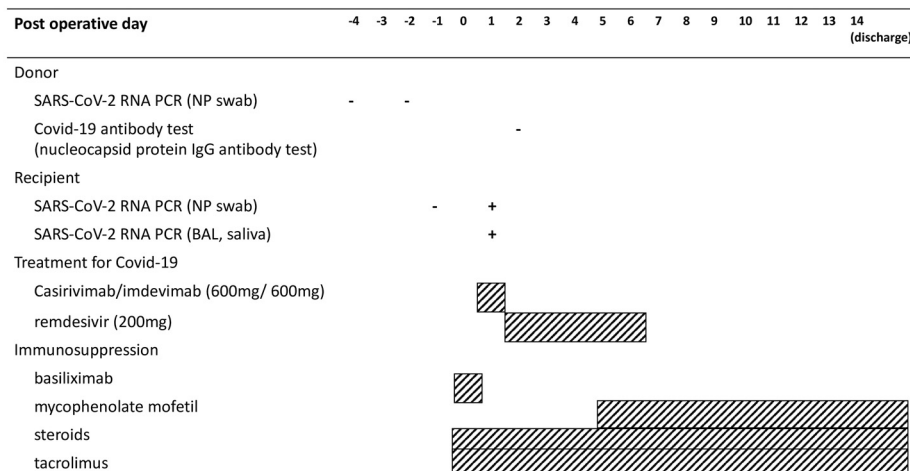
IN December 2019, a novel coronavirus, designated as coronavirus disease 2019 (COVID-19), began to spread rapidly, resulting in a global pandemic [1]. A concern about the susceptibility of immunocompromised patients to the worldwide pandemic of COVID-19 was raised. Optimal management of immunosuppression and antiviral treatment is challenging in solid organ transplant recipients with COVID-19 infection. Lung transplant recipients are highly susceptible to serious disease because of their immunosuppression and COVID-19 [2]. Throughout the pandemic, there have been concerns about patients and donors becoming infected with COVID-19 at the time of transplantation. Here, we present a rare case of a lung transplant recipient found to be COVID-19 positive the day after transplantation.

CASE REPORT

A 71-year-old man with chronic hypersensitivity pneumonitis was referred to our center for evaluation 2 years prior to lung transplantation. His past medical history was notable for colon cancer 7 years ago without recurrence. A chest computed tomography scan showed interstitial fibrosis with ground-glass opacities bilaterally consistent with chronic hypersensitivity pneumonitis. Pulmonary function testing at the time when he was listed showed forced vital capacity = 2.12 L (47% of predicted), forced expiratory volume in 1 second = 1.91 L (56% of predicted), total lung capacity = 3.76 L (51% of predicted), and diffusing capacity for carbon monoxide = 9.6 mL/mm Hg/min (35% of predicted). Two months after listing, a suitable donor

became available, and the patient was admitted to undergo transplantation. The patient had received 2 doses of the COVID-19 vaccine followed by a booster dose 23 days before transplantation. On admission, he had dyspnea, cough, and fatigue, but these symptoms were attributed to his underlying lung disease. He did not have fever or other symptoms suggestive of COVID-19 infection. His pretransplant nasopharyngeal (NP) swab polymerase chain reaction (PCR) for COVID-19 was negative, and the donor NP swab and bronchoalveolar lavage (BAL) PCR, 4 and 2 days before lung transplantation, respectively were also negative for COVID-19. He underwent bilateral lung transplantation with intra-operative extracorporeal membrane oxygenation support. On postoperative day (POD) 1, he underwent PCR test from NP, BAL, and saliva for COVID-19, which was found to be positive (Fig 1). We suspected that the donor PCR may have been falsely negative. We performed antinucleocapsid antibody testing on donor blood because the donor had not been vaccinated, and this was negative. In retrospect, the recipient's wife endorsed respiratory symptoms suggestive of COVID-19, and she was advised to undergo testing; this was positive on POD 2. This suggested that the recipient and his wife were infected with COVID-19 before transplantation. The recipient had received the first dose

*Address correspondence to Tsuyoshi Takahashi MD, PhD, Division of Cardiothoracic Surgery, Department of Surgery, Washington University School of Medicine, 660 S Euclid Ave Campus Box 8234, St. Louis, MO 63110. Tel.: (+1) 314-273-2526; Fax: (+1) 314-367-8459. E-mail: tsuyoshi.takahashi@wustl.edu



SARS-CoV-2: severe acute respiratory syndrome coronavirus2, PCR: polymerase chain reaction, NP: nasopharyngeal, Covid-19: coronavirus disease 2019, BAL: bronchoalveolar lavage,

Fig 1. Donor and recipient laboratory findings, treatment for COVID-19, and immunosuppression of this case. BAL, bronchoalveolar lavage; Ig, immunoglobulin; NP, nasopharyngeal; PCR, polymerase chain reaction; SARS-CoV-2, severe acute respiratory syndrome coronavirus 2.

of basiliximab on POD 0, but the second dose was held and mycophenolate mofetil was discontinued. He was maintained on tacrolimus and prednisone according to our program’s immunosuppression protocol. He was treated with monoclonal antibody (casirivimab/imdevimab 600mg/600mg) on POD 1 and remdesivir 200 mg for 5 days from POD 2. His postoperative course was uncomplicated and mycophenolate mofetil was restarted on POD 5. His chest radiograph did not show any abnormalities (Fig 2) when he was discharged on POD 14. The explanted lung pathology showed advanced interstitial fibrosis with honeycombing consistent with chronic hypersensitivity pneumonitis. Follow-up COVID-19 PCRs became negative 2 months after transplantation, and the recipient continues to do well without any episodes of acute rejection.

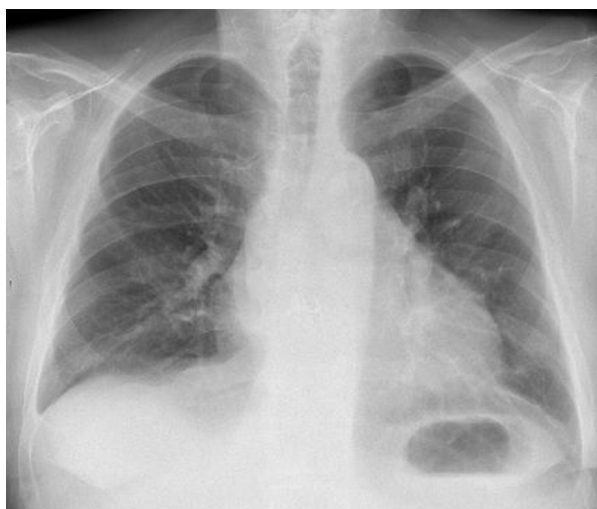

Fig 2. Postoperative chest radiograph showed clear lungs.

DISCUSSION

We report a rare case of a recipient diagnosed with COVID-19 the day after bilateral lung transplantation. In this case, COVID-19 PCR tests of both donor and recipient 48 hours before transplantation were negative, but, on POD 1, the recipient’s PCR test from BAL was found to be positive. We subsequently discovered that the recipient’s wife was also COVID-19 positive, suggesting that both were infected preoperatively. Although a previous case of donor-transmitted COVID-19 infection has been reported despite a negative donor NP swab PCR [3], our case is different in that the recipient was infected pre-transplant.

Balancing treatment of COVID-19 and management of immunosuppression in the immediate period following transplantation is challenging because, although de-escalating immunosuppression can promote viral clearance, this may increase the risk of rejection. There are no current established guidelines or optimal treatment strategies for solid organ transplant recipients who develop COVID-19, but administering monoclonal antibodies early after viral exposure may enhance passive immunity and prevent progression to severe disease [4]. In addition, vaccination and booster dosing preoperatively likely contributed to the prevention of severe disease in our patient. In this case, the second dose of basiliximab on POD 4 was held and mycophenolate mofetil was discontinued. Decreasing immunosuppression, particularly withholding antimetabolites, has shown benefits in ameliorating viral infection in solid organ transplant recipients [5]. One report in liver transplant patients suggests that mycophenolic mofetil dose reduction or withdrawal may prevent severe COVID-19 disease [6].

CONCLUSIONS

We described a challenging case of a lung transplant recipient found to be infected with COVID-19 the day after transplantation. Although COVID-19 infection in lung transplant recipients can be

fatal, aggressive treatment with monoclonal antibodies, remdesivir, and by deescalating immunosuppression was effective in our patient. In addition, pretransplant vaccination and booster dosing likely mitigated the severity of the infection.

REFERENCES

- [1] Guan WJ, Ni ZY, Hu Y, Liang WH, Ou CQ, He JX, et al. Clinical characteristics of coronavirus disease 2019 in China. *N Engl J Med* 2020;382:1708–20.
- [2] Messika J, Eloy P, Roux A, Hirschi S, Nieves A, Le Pavec J, et al. COVID-19 in lung transplant recipients. *Transplantation* 2020;105:177–86.
- [3] Kaul DR, Valesano AL, Petrie JG, Sagana R, Lyu D, Lin J, et al. Donor to recipient transmission of SARS-CoV-2 by lung transplantation despite negative donor upper respiratory tract testing. *Am J Transplant* 2021;21:2885–9.
- [4] Marovich M, Mascola JR, Cohen MS. Monoclonal antibodies for prevention and treatment of COVID-19. *JAMA* 2020;324:131–2.
- [5] Weikert BC, Blumberg EA. Viral infection after renal transplantation: surveillance and management. *Clin J Am Soc Nephrol* 2008;3 (Suppl2):S76–86.
- [6] Colmenero J, Rodríguez-Perálvarez M, Salcedo M, Arias-Milla A, Muñoz-Serrano A, Graus J, et al. Epidemiological pattern, incidence, and outcomes of COVID-19 in liver transplant patients. *J Hepatol* 2021;74:148–55.