

Cerebral topography of vesicular cholinergic transporter changes in neurologically intact adults: A [¹⁸F]FEOBV PET study

Prabesh Kanel^{a,b,*}, Sygrid van der Zee^c, Carlos A. Sanchez-Catasus^{d,e}, Robert A. Koeppe^a, Peter J.H. Scott^a, Teus van Laar^c, Roger L. Albin^{b,f,g}, Nicolaas I. Bohnen^{a,b,f,g}

^a Department of Radiology, University of Michigan, Ann Arbor, MI, USA

^b University of Michigan Morris K. Udall Center of Excellence for Parkinson's Disease Research, Ann Arbor, MI, USA

^c Department of Neurology, University Medical Center Groningen, Groningen, the Netherlands

^d Department of Neurology, Clinica Universidad de Navarra, 31008 Pamplona, Spain

^e Department of Nuclear Medicine and Molecular Imaging, University Medical Center Groningen, the Netherlands

^f Department of Neurology, University of Michigan, Ann Arbor, MI, USA

^g Neurology Service and GRECC, VAAHS, Ann Arbor, MI, USA

ARTICLE INFO

Article history:

Received 14 December 2021

Revised 14 March 2022

Accepted 16 March 2022

Available online 28 March 2022

Keywords:

Acetylcholine transporter

Aging

Normal persons

VACHT PET

ABSTRACT

Acetylcholine plays a major role in brain cognitive and motor functions with regional cholinergic terminal loss common in several neurodegenerative disorders. We describe age-related declines of regional cholinergic neuron terminal density *in vivo* using the positron emission tomography (PET) ligand [¹⁸F](-)-5-Fluoroethoxybenzovesamicol ([¹⁸F]FEOBV), a vesamicol analogue selectively binding to the vesicular acetylcholine transporter (VACHT). A total of 42 subjects without clinical evidence of neurologic disease (mean 50.55 [range 20–80] years, 24 Male/18 Female) underwent [¹⁸F]FEOBV brain PET imaging. We used SPM based voxel-wise statistical analysis to perform whole brain voxel-based parametric analysis (family-wise error corrected, FWE) and to also extract the most significant clusters of regions correlating with aging with gender as nuisance variable. Age-related VACHT binding reductions were found in primary sensorimotor cortex, visual cortex, caudate nucleus, anterior to mid-cingulum, bilateral insula, *para*-hippocampus, hippocampus, anterior temporal lobes/amygdala, dorsomedial thalamus, metathalamus, and cerebellum (gender and FWE-corrected, $P < 0.05$). These findings show a specific topographic pattern of regional vulnerability of cholinergic nerve terminals across multiple cholinergic systems accompanying aging.

© 2022 The Author(s). Published by Elsevier Inc. This is an open access article under the CC BY-NC-ND license (<http://creativecommons.org/licenses/by-nc-nd/4.0/>).

Abbreviations: AChE, Acetylcholinesterase; BFCC, Basal Forebrain Cholinergic Corticopetal complex; COTC, Cingulo-Opercular Task Control; FEOBV, Fluoroethoxybenzovesamicol; IBVM, Iodobenzovesamicol; MVC, Medial Vestibular Complex; PPN/LDTC, pedunculo-pontine nucleus/lateral dorsal tegmental complex; PET, Positron Emission Tomography; SChs, Striatal Cholinergic Interneurons; SPECT, Single Photon Emission Computed Tomography; VACHT, vesicular acetylcholine transporter.

* Corresponding author at: Functional Neuroimaging, Cognitive and Mobility Laboratory, Departments of Radiology and Neurology, University of Michigan, 24 Frank Lloyd Wright Drive, Box 362, Ann Arbor, MI 48105-9755, USA.

E-mail address: prabeshk@umich.edu (P. Kanel).

Introduction

Normal aging is associated with cholinergic system losses in the brain (see [1–3] for review). Most data relevant to age-related declines of cholinergic systems derives from older post-mortem studies of the basal forebrain cholinergic corticopetal complex (BFCC) evaluating markers of cholinergic terminal and perikaryal integrity [3].

<https://doi.org/10.1016/j.nbas.2022.100039>

2589-9589/© 2022 The Author(s). Published by Elsevier Inc.

This is an open access article under the CC BY-NC-ND license (<http://creativecommons.org/licenses/by-nc-nd/4.0/>).

Other important brain cholinergic systems were largely ignored in these studies.

Important cholinergic projection systems include the BFCC, notably the nucleus basalis of Meynert (nbM), which provides the principal cholinergic input of the entire cortical mantle and amygdala [4]. The medial septal and vertical limb of the diagonal band nuclei of the BFCC innervate the hippocampal formation. The pedunculopontine nucleus/lateral dorsal tegmental complex (PPN/LDTC) provides cholinergic inputs to the basal ganglia, thalamus, cerebellum, several brainstem nuclei, and the spinal cord [5]. The medial vestibular nucleus (MVN) is a major source of cholinergic input to the cerebellum [6]. The striatum exhibits the highest density of cholinergic terminal markers in the brain. Cholinergic nerve terminals in the striatum may derive from striatal cholinergic interneurons (SCHs) or from extrinsic projections from the PPN/LDTC, with available evidence indicating that the great majority of striatal cholinergic terminals emanate from SCHs [7,8]. There is a paucity of information about the relationship between normal aging and changes in brain cholinergic systems other than the BFCC. Our recent positron emission tomography (PET) study using the vesicular acetylcholine transporter (VACHT) ligand [¹⁸F](–)5-fluoroethoxybenzovesamicol ([¹⁸F]FEOBV) found significant age-associated decreases in [¹⁸F]FEOBV binding in striatum (approximately 4% binding loss per decade) and approximately 2.5% per decade FEOBV binding losses in primary sensorimotor cortex, anterior cingulum, and thalamus of neurologically intact adults [9]. VACHT expression is unique to cholinergic terminals and [¹⁸F]FEOBV PET is thought to be a specific and robust measure of regional cholinergic terminal density [10]. Assessment of aging effects in this study was based on limited volume-of-interest analysis using *a priori* selection of relatively high binding regions. This approach lacks sensitivity to assess cholinergic aging effects in regions with lower tracer binding and also in characterizing changes within larger preselected volumes-of-interest, such as the striatum. A more systematic analysis requires a spatially unbiased approach.

The goal of this paper is to perform a whole brain voxel-based analysis to investigate the topography of age-related cholinergic terminal changes using [¹⁸F]FEOBV PET in normal adults and across a wide age range and complemented by a cluster peak analysis. Identification of the topographic vulnerability of cholinergic systems during aging is relevant to understand the contributions of normal aging to age-related neurodegenerative disorders exhibiting cholinergic systems degenerations, such as Parkinson's or Alzheimer's disease. Identifying the topography of normal age-related changes in cholinergic systems may also be relevant to understand potential sensitivity to the use of commonly prescribed anticholinergic drugs in older adults.

Subjects and methods

Subjects

This cross-sectional study involved 42 neurologically intact normal control subjects (24 males, 18 females),

mean age 50.55 ± 19.35 , age range 20–80 years. Data from 29 subjects was used in a previous study describing the normal biodistribution of VACHT binding with limited (volume-of-interest method only) aging effects analyses [9]. Ten subjects (5/5 M/F) out of 42 were part of the Dutch Parkinson Cohort (DUPARC) study [11]. No subjects had histories of the neurologic or psychiatric disease, none took medications that might affect cholinergic neurotransmission (either cholinergic or anticholinergic drugs) and all had a normal neurological examination at the time of this study. The study was approved by and study procedures were followed in accordance with the ethical standards of the Institutional Review Board of the University of Michigan and medical ethical committee of the University of Groningen. Written informed consent was obtained from all subjects.

Imaging techniques All subjects underwent brain MRI and VACHT [¹⁸F]FEOBV PET imaging. MRI was performed on a 3 Tesla Philips Achieva system (Philips, Best, The Netherlands) at the University of Michigan and a 3 Tesla Philips Intera system (Philips, The Netherlands) at the University Medical Center Groningen (UMCG). PET imaging was performed in 3D imaging mode with an ECAT Exact HR + tomograph (Siemens Molecular Imaging, Inc., Knoxville, TN) as previously reported [12] or Biograph 6 TruPoint PET/CT scanner (Siemens Molecular Imaging, Inc., Knoxville, TN) as previously described [13] at the University of Michigan and Biograph 40-mCT or 64-mCT TruPoint PET/CT scanner (Siemens Molecular Imaging, Inc., Knoxville, TN) at the UMCG as previously described [11]. [¹⁸F]FEOBV were prepared as described previously [14]. Inter-camera data harmonization was performed as described [15]. We constructed TruePoint images with 3 mm filters to match the resolution and to account for differences between the scanners. To reduce the scanner variability, the acquisition parameters used at the University of Michigan were followed at the UMCG. We reconstructed all [¹⁸F]FEOBV PET images obtained at the UMCG using software, methodology and reconstruction parameters identical to those used at the University of Michigan.

Image analysis

Spatial preprocessing

We constructed parametric images to reflect Distribution Volume Ratios (DVR) of [¹⁸F] FEOBV in the brain by using the supratentorial white matter as a reference region as previously reported [16–18]. All structural MRI images were segmented into native and 'Dartel-imported' gray matter, white matter and cerebrospinal fluid using the Statistical Parametric mapping 12 (SPM12) software package (<https://www.fil.ion.ucl.ac.uk/spm/>). Using this segmentation, a Muller-Gartner partial-volume correction method was used to remove the partial volume effect (PVE) on our PET images [19]. Each subject's structural MRI along with registered PVE corrected PET image is then normalized to the study specific template in Montreal Neurological Institute (MNI) space using high-dimensional DARTEL registration. To remove random noise, normalized PVE corrected PET images were spatially smoothed to 8 mm full

width at half maximum (FWHM). We performed the images preprocessing steps from both the centers at the University of Michigan. Before including the Groningen subjects in our analysis and to account for any biases present in the images due to scanning at two sites, we applied an inter-scanner normalization method as listed above [15] between age and gender-matched subjects between the center and found no significant difference between any of the images. The mask of the basal forebrain in MNI space was drawn from a multilevel atlas framework based on the Julich Brain atlas (https://www.fz-juelich.de/inm/inm-1/EN/Forschung/JulichBrain/JulichBrain_Webtools/JulichBrain_Webtools_node.html) using the previously described method [20–22].

Statistical analysis

To evaluate the effect of neurologically intact adults on [^{18}F] FE0BV DVR in the brain, a voxel-based correlation analysis of the parametric images in MNI space was performed using SPM12, with age as the variance of interest and gender as the nuisance covariate. Both positive and negative correlations were evaluated. A cluster-based analysis was also performed and statistical parametric mapping results were thresholded at voxel level $p < 0.001$ and corrected for whole-brain comparisons using cluster-level family-wise error rate ($p < 0.05$). Clusters that survived the cluster-level family-wise error rate were interpreted as significant.

Results

Age-related reductions of VAcHT binding were found in primary sensorimotor cortex, visual cortex, caudate nucleus, anterior to mid cingulum, bilateral insulae, parahippocampus, hippocampus, anterior temporal lobes/amygdala, metathalamus (lateral and medial geniculate nuclei), dorsomedial thalamus, and cerebellum (gender and FWE-corrected, $P < 0.05$; Fig. 1).

Scatter plots of distribution volume ratio of parahippocampal gyrus and caudate nucleus show age-associated reductions of VAcHT binding (Fig. 2). Similarly, a voxel-based morphometric analysis of the basal forebrain detects age-related reduction of volume in basal forebrain in neurologically intact adults, gender and FWE-corrected, $P < 0.05$ (Fig. 3).

Table 1 lists the major clusters with cluster size 50 voxels or more, FWE-corrected p -values, the coordinates (X, Y, Z) of the local maxima within that cluster in MNI space, peak voxel z and t -score at the local maxima, and brain regions associated with the clusters.

Discussion

Post-mortem studies show that neurologically intact control persons exhibit age-related declines of BFCC perikaryal density, and within the cortex, in biochemical and histochemical markers of cholinergic terminal density. Other cholinergic systems are less studied. Molecular imaging methods allow *in vivo* evaluation of cholinergic

systems integrity but there is only scarce *in vivo* molecular imaging data on the relationships between normal aging and cholinergic systems integrity. A prior VAcHT ligand [^{123}I]iodobenzovesamicol (IBVM) single photon emission computed tomography (SPECT) imaging study in neurologically intact controls found cortical IBVM binding declined 3.7% per decade between the ages of 21 and 91 [23]. The limited resolution of SPECT precluded more detailed analysis and results in subcortical structures were not reported. A $\alpha_4\beta_2$ [^{123}I]IA-85380 SPECT study of nicotinic cholinergic receptors found an inverse correlation between age and receptor binding availability in neurologically intact adults aged 18–85 years [24]. Declines ranged from 32% (thalamus) to 18% (occipital cortex) over the adult lifespan, or up to 5% per decade, but these results may partly reflect post-synaptic changes. Our more recent VAcHT [^{18}F]FE0BV PET study, with a subset of the normal participants ($n = 29$) used for this analysis, found significant age-associated decreases in [^{18}F]FE0BV binding of the striatum (approximately 4% binding loss per decade) with approximately 2.5% per decade binding losses in the primary sensorimotor cortex, the anterior cingulum, and the thalamus. Other regions did not show significant age-related reductions [9].

Our current analysis, performed with a larger study sample and using a whole-brain voxel-based analysis method, as opposed to the volumes-of-interest analyses of prior studies, confirms our prior results and depicts a more granular topography of age-related cholinergic terminal declines. Novel findings include preferential vulnerability of the caudate nucleus cholinergic terminals relative to those of the putamen, and similar relative vulnerability of the metathalamus cholinergic terminals compared to those of the thalamus. Other novel findings include age-related declines of [^{18}F]FE0BV binding in hippocampal and parahippocampal regions, the calcarine cortex, and parts of the cerebellar cortex. The striatal and cerebellar results show the potential strengths of this voxel-by-voxel analysis. The striatal cluster of significant voxels suggests preferential involvement of caudate SchTs. The prior volume-of-interest analysis did not detect any changes in the cerebellum, even in regions of high [^{18}F]FE0BV binding such as nodulus and flocculus.

A FE0BV PET study of aging rodents [25] found aging associated with hippocampal and parietotemporal cortical cholinergic losses. Our study in neurologically intact adults found evidence of more widespread age-related losses extending beyond these regions. This may either reflect a critical difference between rodents and the human brain versus more detailed neuroimaging analysis techniques applied to the anatomically larger human brain.

Our present results indicate age-related changes in all major brain cholinergic systems, including declines of BFCC terminals, PPN-LDTC cholinergic terminals, MVN cholinergic terminals, and likely SchT terminals. Our findings suggest that the BFCC afferents to limbic and paralimbic cortices appear more vulnerable than BFCC afferents to most of the neocortex with the exception of primary sensorimotor and calcarine cortices. These results suggest preferential age-related effects on medial septal/vertical limb of the diagonal band nucleus and nBM subpopula-

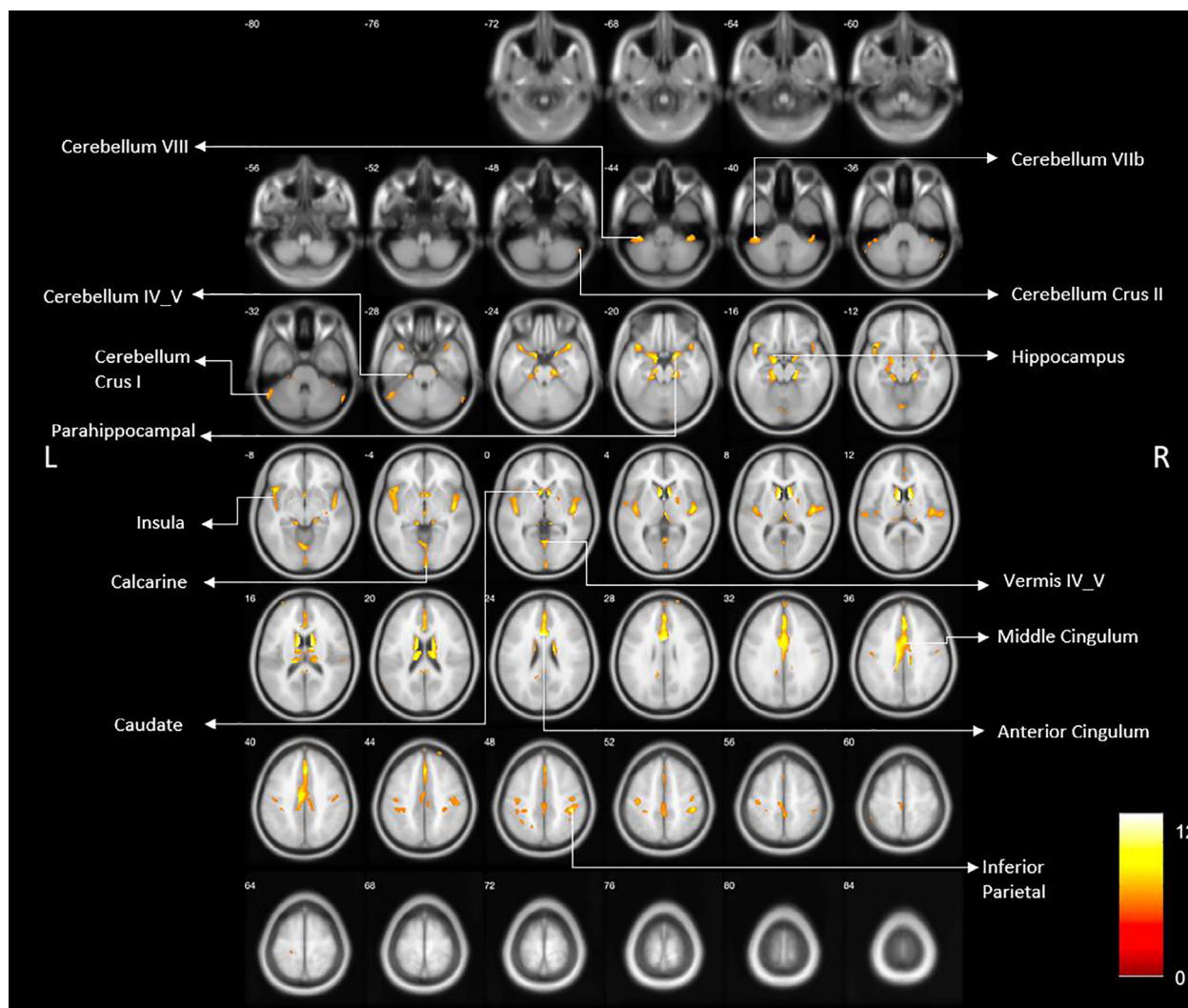


Fig. 1. Age-related reduced VAcHT binding reductions are shown in primary sensorimotor cortex, visual cortex, caudate nucleus, anterior to mid cingulum, bilateral insula, *para*-hippocampus, hippocampus, anterior temporal lobes/amygdala, epithalamus, and cerebellum (gender and FWE-corrected, $P < 0.05$).

tions. Recent studies indicate that the BFCC is not a diffuse projections system but rather composed clusters of cholinergic projection neurons with terminals in limited numbers of cortical fields [26,27]. What factors might account for BFCC subpopulation specific cholinergic terminal losses is unclear. In the case of calcarine cortex, it is plausible that this may be a “dying back” phenomenon. Cholinergic efferents from the nBM traverse 2 major pathways, one projecting initially anterior and coursing around the corpus callosum and one traveling through the external capsule [2,26]. Some BFCC afferents to calcarine cortex might travel through the anterior projection with their extended length making them particularly vulnerable to metabolic impairments.

Similarly, our results in regions innervated by other cholinergic systems – metathalamus/thalamus (PPN/LTDC), cerebellum (MVN), and striatum (SCHs) – suggest preferential involvement of subpopulations of cholinergic neurons.

We recently reported that cholinergic terminals in components of the cingulo-opercular task control (COTC) network in patients with PD correlated with the degree of cognitive impairment [28]. The identification of age-related cholinergic terminal deficits within the anterior cingulum, thalamus, metathalamus, insula, and caudate nucleus point to greater vulnerability of COTC hubs [29]. The COTC network plays important roles in the maintenance of tonic alertness and task performance [30]. Maintenance of alertness is a critical function subserving multiple higher cognitive domain functions, such as executive functions and memory. Age-associated cholinergic terminal deficits within COTC nodes may provide a partial explanation of why normal aging is associated with declines in cognitive abilities such as processing speed and certain memory, language, visuospatial, and executive functions [31]. Our finding that cholinergic terminals within COTC nodes may be vulnerable to aging effects expands the growing literature that normal aging is associ-

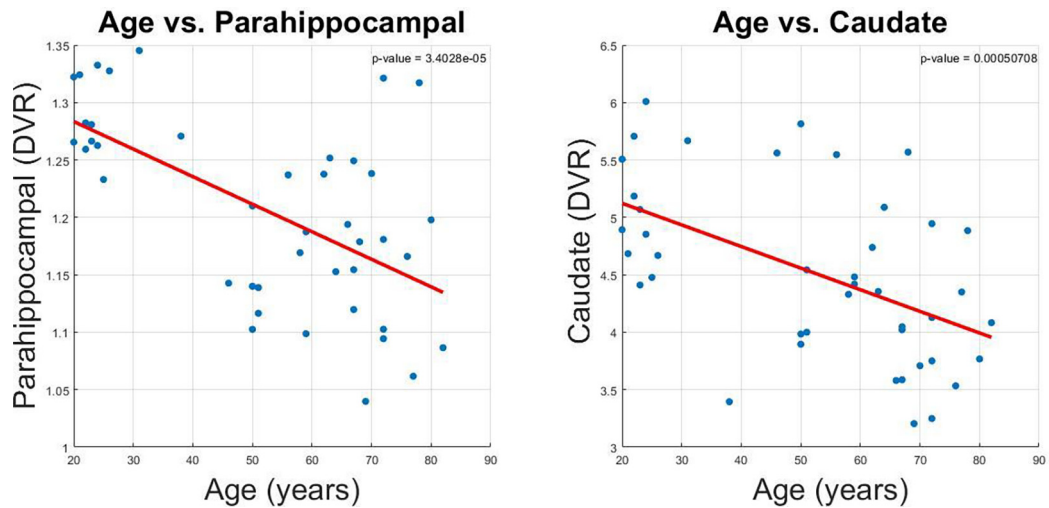


Fig. 2. Scatter plot of the DVR of parahippocampal gyrus and caudate nucleus with age.

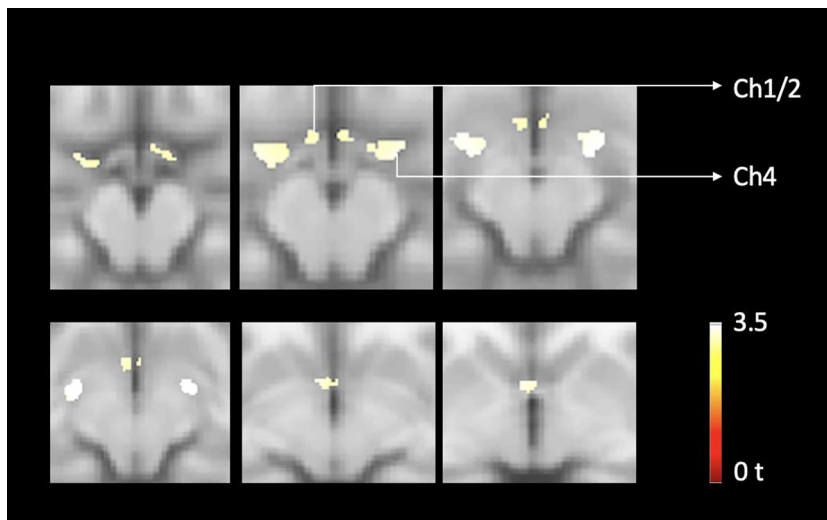


Fig. 3. Voxel-based analysis of basal forebrain loss over time in neurologically intact elderly. Findings show evidence of significant age-associated cholinergic forebrain volume losses in neurologically intact adults, FWE-corrected $P < 0.05$.

ated with loss of large-scale neural network functions [32] and may increase vulnerability to age-associated neurodegenerations, such as Alzheimer’s disease (AD). FEOBV PET has also potential to be used as a diagnostic test for AD or other types of dementia. For example, a recent VACHT [^{18}F]FEOBV PET study found that cholinergic denervation in AD was more accurate and sensitive in differentiating AD from normal controls compared to [^{11}C]-PIB amyloid PET and [^{18}F]-Fluorodeoxyglucose (FDG) tracers [33]. Similarly, our voxel-based metabolic covariance group analysis between AD and DLB using VACHT [^{18}F]FEOBV PET reveals a specific covarying pattern of cholinergic losses in DLB supporting the use of VACHT [^{18}F]FEOBV PET to distinguish DLB from AD [34].

Our results also implicate age-related brain cholinergic deficits in other common age-related clinical phenomena.

Given the involvement of the metathalamus and caudate nucleus cholinergic deficits in postural imbalance and falls in PD, cholinergic deficits of these regions in normal aging may increase risk of falling in normal older adults, particularly those taking anti-cholinergic drugs [35]. Our findings emphasize the importance of avoiding anti-cholinergic drugs in the elderly.

Our current findings underscore the notion that brain cholinergic deficits found neurodegenerative disorders such as PD reflect both disease-specific and normal aging-related degenerative processes. Similar mixed effects of disease and normal aging were shown for nigrostriatal dopaminergic losses in PD [36,37].

There are several limitations of this study. First, gender distribution was not equally distributed across the older (relatively more males) vs. the younger (relatively more

Table 1

Table 1 lists of significant age-associated FEOBV PET clusters with a minimum of 50 voxels with the location of the peak voxel, peak voxel z and t-score, and the regions associated with the clusters.

Clusters (voxels)	P	Peak MNI coordinates [x,y,z]	Z	T	Regions
1146	<0.001	-6 8 10	7.8	12.28	Left and Right Caudate Left and Right Thalamus Left and right lateral geniculate nuclei Left and right medial geniculate nuclei Left and Right Olfactory
2289	<0.001	-2 8 26	7.58	11.57	Left and Right Mid Cingulum Left and Right Ant Cingulum Left and Right Precuneus Left and Right Supp Motor Area Left and Right Frontal sup medial Left and Right paracentral lobule Left post cingulum
244	<0.001	18 -24 -18	6.74	9.37	Right Parahippocampal Right Lingual Right Cerebellum lobules 3, 4 & 5 Right Hippocampus Right Fusiform gyrus
967	<0.001	44 -12 2	6.72	9.33	Right Insula Right Temporal sup Right Heschl gyrus Right temporal superior pole Right parahippocampal gyrus Right Rolandic operculum Right Amygdala Right Hippocampus
1386	<0.001	-14 -8 -16	6.52	8.86	Right frontal inferior orbitofrontal lobe Left Hippocampus Left Superior temporal pole Left Insula Left Parahippocampal gyrus Left Frontal inferior orbitofrontal lobe Left Heschl gyrus Left Amygdala Left Cerebellum lobules 3, 4 & 5 Left Olfactory cortex Left Rolandic operculum Left fusiform gyrus Left lingual gyrus
362	<0.001	42 -34 50	6.49	8.79	Left inferior frontal gyrus triangular part Right postcentral cortex Right precentral cortex Right inferior parietal lobe
36	<0.001	2 -38 18	6.13	8.02	Left and Right posterior cingulate cortex
267	<0.001	0 -60 2	6.12	7.99	Vermis sections of lobules 4, 5 & 6 Left and right lingual gyrus Left Cerebellum lobules 4, 5 & 6 Left and Right Calcarine cortex
308	<0.001	-40 -38 -42	5.72	7.33	Left Cerebellum Crus 1 & 2 Left Cerebellum lobules 7b & 8 Left Inferior Temporal lobe
102	<0.001	40 -40 -42	5.84	7.44	Right Cerebellum Crus 1 & 2 Right Cerebellum lobules 7b & 8
157	<0.001	-40 -20 52	5.69	7.16	Left Postcentral cortex Left Precentral cortex
110	<0.001	4-98 -4	5.68	7.15	Left Calcarine cortex
129	0.007	-30 -34 50	5.08	6.10	Left Postcentral cortex Left Inferior parietal cortex
50	0.002	58 -66 -32	5.35	6.55	Right Cerebellum Crus1
51	0.004	-56 -22 12	5.24	6.36	Left superior temporal lobe Left postcentral cortex Left supramarginal gyrus
53	0.004	20 2 4	5.21	6.32	Right Putamen Right Pallidum

females) age groups in the study participants. Our analysis, however, was adjusted for the effects of gender. Furthermore, despite the smaller number of women in the older age group, *post hoc* analysis showed similar regional topographic effects of aging in women in uncorrected analyses. Second, we did not assess the presence of asymptomatic or prodromal biomarkers of Alzheimer and Lewy body disorders, which might have resulted in possible inclusion of otherwise neurologically intact adults in our study.

We conclude that all major cholinergic cell groups and projections, including the BFCC, PPN-LDTC, MVN and SchIs, are vulnerable to effects of normal aging. Our results suggest that subpopulations of these cholinergic systems are particularly vulnerable. Our findings may have clinical implications and may help to explain the deleterious effects of anti-cholinergic drugs in the otherwise neurologically intact elderly without the history of neurological disease.

Funding

This work was supported by the National Institutes of Health [P01 NS015655, RO1 NS070856, P50 NS091856, P50 NS123067], Department of Veterans Affairs grant [I01 RX001631], the Michael J. Fox Foundation, the Parkinson's Foundation, W. Garfield Weston Foundations' Weston Brain Institute. None of the funding agencies had a role in the design and conduct of the study, in the collection, management, analysis and interpretation of the data, in the preparation, review or approval of the manuscript, nor in the decision to submit the manuscript for publication.

Declaration of Competing Interest

Dr. Koeppe has received grant support from the National Institute of Health, the Farmer Family Foundation Parkinson's Research Initiative and National Institute of Aging.

Dr. Scott has received grant from U.S. Department of Energy, the National Institute of Biomedical Imaging and Bioengineering, the Farmer Family Foundation Parkinson's Research Initiative and the Alzheimer's Association, AbbVie and Bristol-Myers Squibb.

Dr. Frey has research support from the National Institutes of Health, National Institute of Neurological Disorders and Stroke, National Cancer Institute, GE Healthcare and AVID Radiopharmaceuticals (Eli Lilly subsidiary). Dr. Frey also serves as a consultant to AVID Radiopharmaceuticals, MIMVista, Inc, Bayer-Schering and GE healthcare. He also holds equity (common stock) in GE, Bristol-Myers, Merck and Novo-Nordisk.

Dr. van Laar has received research support from the Weston Brain Institute, speaker fees from Britannia and is on the advisory boards of Britannia and AbbVie, Medtronic and is on the advisory boards of LTI and Neuroderm.

Dr. Albin has research support from the National Institute of Neurologic Disease and Stroke, the Parkinson's Foundation, the National Institute on Aging, and the Farmer Family Foundation Parkinson's Research Initiative.

Dr. Bohnen has research support from the National Institute of Health, Department of Veteran Affairs, the Parkinson's Foundation, and the Farmer Family Foundation Parkinson's Research Initiative.

The remaining authors declare that they have no known competing financial interests or personal relationships that could have appeared to influence the work reported in this paper.

Acknowledgements

The authors thank Christine Minderovic, Cyrus Sarosh, the PET technologists, cyclotron operators, and radiochemists, for their assistance. We are indebted to the subjects who participated in this study.

References

- [1] Gasiorowska A, Wydrych M, Drapich P, et al. The Biology and Pathobiology of Glutamatergic, Cholinergic, and Dopaminergic Signaling in the Aging Brain. *Front Aging Neurosci* 2021; 13: 654932021/07/310.3389/fnagi.2021.654931.
- [2] Schmitz TW, Zaborszky L. Chapter 10 - Spatial topography of the basal forebrain cholinergic projections: Organization and vulnerability to degeneration. In: Swaab DF, Kreier F, Lucassen PJ, editors. *Handbook of Clinical Neurology*. Elsevier; 2021. p. 159-73.
- [3] Candy JM, Perry EK, Perry RH, et al. The current status of the cortical cholinergic system in Alzheimer's disease and Parkinson's disease. *Prog Brain Res* 1986; 70: 105-132. 1986/01/01. 10.1016/s0079-6123(08)64300-9.
- [4] Mesulam MM, Geula C. Nucleus basalis (Ch4) and cortical cholinergic innervation in the human brain: observations based on the distribution of acetylcholinesterase and choline acetyltransferase. *J Comparative Neurol* 1988; 275: 216-240. 1988/09/08. 10.1002/cne.902750205.
- [5] Heckers S, Geula C, Mesulam M. Cholinergic innervation of the human thalamus: dual origin and differential nuclear distribution. *J Comp Neurol* 1992;325:68-82.
- [6] Zhang C, Zhou P, Yuan T. The cholinergic system in the cerebellum: from structure to function. *Rev Neurosci* 2016; 27: 769-772016/08/210.1515/revneuro-2016-0008.
- [7] Dautan D, Hacıoglu Bay H, Bolam JP, et al. Extrinsic sources of cholinergic innervation of the striatal complex: a whole-brain mapping analysis. *Front Neuroanat* 2016; 10: 1. 2016/02/03. 10.3389/fnana.2016.00001.
- [8] Janickova H, Rosborough K, Al-Onaizi M, et al. Deletion of the vesicular acetylcholine transporter from pedunculopontine/laterodorsal tegmental neurons modifies gait. *J Neurochem* 2017; 140: 787-792016/11/210.1111/jnc.13910.
- [9] Albin RL, Bohnen NI, Muller M, et al. Regional vesicular acetylcholine transporter distribution in human brain: A [(18)F] fluoroethoxybenzovesamicol positron emission tomography study. *J Comp Neurol* 2018. doi: <https://doi.org/10.1002/cne.24541>.
- [10] Petrou M, Frey KA, Kilbourn MR, et al. In vivo imaging of human cholinergic nerve terminals with (-)-5-¹⁸F-fluoroethoxybenzovesamicol: biodistribution, dosimetry, and tracer kinetic analyses. *J Nucl Med* 2014;55:396-404. doi: <https://doi.org/10.2967/jnumed.113.124792>.
- [11] Boertien JM, van der Zee S, Chrysoy A, et al. Study protocol of the Dutch Parkinson Cohort (DUPARC): a prospective, observational study of de novo Parkinson's disease patients for the identification and validation of biomarkers for Parkinson's disease subtypes, progression and pathophysiology. *BMC Neurol* 2020; 20: 245. 2020/06/15. 10.1186/s12883-020-01811-3.
- [12] Bohnen NI, Muller ML, Kotagal V, et al. Heterogeneity of cholinergic denervation in Parkinson's disease without dementia. *J Cereb Blood Flow Metab* 2012; 32: 1609-17. 2012/05/10. 10.1038/jcbfm.2012.60.
- [13] Bohnen NI, Kanel P, Koeppe RA, et al. Regional cerebral cholinergic nerve terminal integrity and cardinal motor features in Parkinson's disease. *Brain Commun* 2021; 3: fcab109. <https://doi.org/10.1093/braincomms/fcab109>.
- [14] Shao X, Hoareau R, Hockley BG, et al. Highlighting the Versatility of the Tracerlab Synthesis Modules. Part 1: Fully Automated Production of [F]Labelled Radiopharmaceuticals using a Tracerlab

- FX(FN). *J Label Compounds Radiopharmaceuticals* 2011; 54: 292-307. 2011/07/20. 10.1002/jlcr.1865.
- [15] Thiele F, Young S, Buchert R, et al. Voxel-based classification of FDG PET in dementia using inter-scanner normalization. *NeuroImage* 2013; 77: 62-9. 2013/04/02. 10.1016/j.neuroimage.2013.03.031.
- [16] Kanel P, Müller M, van der Zee S, et al. Topography of cholinergic changes in dementia with Lewy bodies and key neural network hubs. *J Neuropsychiatry Clin Neurosci* 2020; 32: 370-5. 2020/06/06. 10.1176/appi.neuropsych.19070165.
- [17] Nejad-Davarani S, Koeppe RA, Albin RL, et al. Quantification of brain cholinergic denervation in dementia with Lewy bodies using PET imaging with [(18)F]-FEOBV. *Mol Psychiatry* 2019; 24: 322-327. 2018/08/08. 10.1038/s41380-018-0130-5.
- [18] Albin RL, Minderovic C, Koeppe RA. Normal striatal vesicular acetylcholine transporter expression in Tourette syndrome. *eNeuro* 2017; 4 2017/08/10. 10.1523/ENEURO.0178-17.2017.
- [19] Muller-Gartner HW, Links JM, Prince JL, et al. Measurement of radiotracer concentration in brain gray matter using positron emission tomography: MRI-based correction for partial volume effects. *J Cereb Blood Flow Metab* 1992; 12: 571-583. 1992/07/01. 10.1038/jcbfm.1992.81.
- [20] Amunts K, Mohlberg H, Bludau S, et al. Julich-Brain: a 3D probabilistic atlas of the human brain's cytoarchitecture. *Science* 2020;369(988-992):20200730. doi: <https://doi.org/10.1126/science.abb4588>.
- [21] Zilles K, Amunts K. Centenary of Brodmann's map—conception and fate. *Nat Rev Neurosci* 2010;11(139-145):20100104. doi: <https://doi.org/10.1038/nrn2776>.
- [22] Zilles K, Schleicher A, Palomero-Gallagher N, et al. 21 - Quantitative Analysis of Cyto- and Receptor Architecture of the Human Brain. In: Toga AW, Mazziotta JC, editors. *Brain Mapping: The Methods*. San Diego: Academic Press; 2002. p. 573-602.
- [23] Kuhl DE, Koeppe RA, Minoshima S, et al. In vivo mapping of cerebral acetylcholinesterase activity in aging and Alzheimer's disease. *Neurology* 1999; 52: 691-9. 1999/03/17. DOI: 10.1212/wnl.52.4.691.
- [24] Mitsis EM, Cosgrove KP, Staley JK, et al. Age-related decline in nicotinic receptor availability with [(123)I]5-IA-85380 SPECT. *Neurobiol Aging* 2009; 30: 1490-7. 2008/02/05. 10.1016/j.neurobiolaging.2007.12.008.
- [25] Parent M, Bedard MA, Aliaga A, et al. PET imaging of cholinergic deficits in rats using [18F]fluoroethoxybenzovesamicol [(18F) FEOBV]. *NeuroImage* 2012;62(555-561):20120425. doi: <https://doi.org/10.1016/j.neuroimage.2012.04.032>.
- [26] Zaborszky L, Csordas A, Mosca K, et al. Neurons in the basal forebrain project to the cortex in a complex topographic organization that reflects corticocortical connectivity patterns: an experimental study based on retrograde tracing and 3D reconstruction. *Cereb Cortex (New York, NY : 1991)* 2015; 25: 118-137. 2013/08/22. 10.1093/cercor/bht210.
- [27] Gielow MR and Zaborszky L. The input-output relationship of the cholinergic basal forebrain. *Cell Rep* 2017; 18: 1817-30. 2017/02/16. 10.1016/j.celrep.2017.01.060.
- [28] van der Zee S, Müller MLTM, Kanel P, et al. Cholinergic denervation patterns across cognitive domains in Parkinson's disease. *Movement Disord* 2021; 36: 642-50. 2020/11/03. DOI: 10.1002/mds.28360.
- [29] Power JD, Cohen AL, Nelson SM, et al. Functional network organization of the human brain. *Neuron* 2011; 72: 665-78. 2011/11/22. 10.1016/j.neuron.2011.09.006.
- [30] Sadaghiani S and D'Esposito M. Functional characterization of the Cingulo-opercular network in the maintenance of tonic alertness. *Cereb cortex (New York, NY : 1991)* 2015; 25: 2763-73. 2014/04/29. 10.1093/cercor/bhu072.
- [31] Harada CN, Natelson Love MC and Triebel KL. Normal cognitive aging. *Clin Geriatr Med* 2013; 29: 737-52. 2013/10/08. 10.1016/j.cger.2013.07.002.
- [32] Zhang HY, Chen WX, Jiao Y, et al. Selective vulnerability related to aging in large-scale resting brain networks. *PLoS One* 2014; 9: e108807. 2014/10/02. 10.1371/journal.pone.0108807.
- [33] Aghourian M, Legault-Denis C, Soucy JP, et al. Quantification of brain cholinergic denervation in Alzheimer's disease using PET imaging with [(18)F]-FEOBV. *Mol Psychiatry* 2017; 22: 1531-1538. 2017/09/13. 10.1038/mp.2017.183.
- [34] Kanel P, Bedard M-A, Aghourian M, et al. Molecular imaging of the cholinergic system in alzheimer and lewy body dementias: expanding views. *Curr Neurol Neurosci Rep* 2021;21:52. doi: <https://doi.org/10.1007/s11910-021-01140-z>.
- [35] Bohnen NI, Kanel P, Koeppe RA, et al. Regional cerebral cholinergic nerve terminal integrity and cardinal motor features in Parkinson's disease. *Brain Commun* 2021; 3. ARTN fcab1091093/braincomms/fcab10910.1093/braincomms/fcab109.
- [36] de la Fuente-Fernandez R, Schulzer M, Kuramoto L, et al. Age-specific progression of nigrostriatal dysfunction in Parkinson's disease. *Ann Neurol* 2011; 69: 803-10. 2011/01/20. 10.1002/ana.22284.
- [37] Rodriguez M, Rodriguez-Sabate C, Morales I, et al. Parkinson's disease as a result of aging. *Aging Cell* 2015; 14: 293-308. 2015/02/14. 10.1111/acel.12312.