

The diagnosis remains probable despite the strong temporal relationship because after literature review with the keywords 'SARS-CoV-2', 'Vaccine', 'COVID-19', 'Angiomatosis', 'Haemangiomas', 'Cherry' and/or 'Angiomas', no other articles describe true eruptive angiomas after any SARS-CoV-2 vaccine.

The pathogenesis of this skin disorder remains unclear. Among the various possibilities, we proposed an HHV-8 reactivation elicited by the vaccination,^{1,5} but a real-time PCR requested to search for herpesvirus DNA on cutaneous samples resulted negative.

Cells exposing angiotensin-converting enzyme 2 (ACE2) could be altered by circulating spike proteins, probably affecting the ACE2 pathway.⁶ Inflammation or increased angiotensin II levels could stimulate the proliferation of predisposed endothelial cells of the skin, causing angiomas; the latter mechanism is also proposed in infantile haemangiomas.⁷ Still, experimental studies have not shown significant alterations in the angiotensin II pathway in patients with COVID-19.⁸

We believe in a dysregulation of the neuropilin-1 (NRP-1) proteins cascade⁹ as a plausible mechanism. Spike protein portions could bind to the NRP-1 and interfere with the VEGF-R, which has been already described to cause cherry angiomas proliferation when dysregulated. This interaction could recall the side effects produced by ramucirumab and other VEGF-R inhibitors.¹⁰

In conclusion, in this case report, we aimed to raise awareness of the increasing variety and complexity of viral, paraviral and vaccine skin reactions induced by the immune response to the genetic material related to the SARS-CoV-2. By sharing this case, we hope that physicians can be aware of the increasing spectrum of AEDs related to these vaccines skin manifestations, however harmless and self-limiting.

Acknowledgements



The patients in this manuscript have given written informed consent to the publication of their case details.

Conflict of interest

The authors have no conflict of interest to declare.

Data Availability Statement

Data available on request from the authors.

C. Zengarini,^{1,2}  C. Misciali,^{1,2,*} T. Lazzarotto,³ E. Dika^{1,2} 

¹Dermatology Unit, IRCCS Azienda Ospedaliero-Universitaria di Bologna, Bologna, Italy, ²Dermatology, Department of Experimental, Diagnostic and Specialty Medicine (DIMES), University of Bologna, Bologna, Italy,

³Microbiology Unit, IRCCS Azienda Ospedaliero-Universitaria di Bologna, Bologna, Italy

*Correspondence: C. Misciali. E-mail: cosimo.misciali@unibo.it

References

- 1 Qadeer HA, Singal A, Patel BC. Cherry Hemangioma. In: StatPearls [Internet]. StatPearls Publishing, Treasure Island, FL; 2021. URL <http://www.ncbi.nlm.nih.gov/books/NBK563207/> (last accessed: 9 July 2021).
- 2 Corazza M, Dika E, Maietti E, Musmeci D, Patrizi A, Borghi A. Eruptive cherry angiomas and skin melanoma: a fortuitous association? *Melanoma Res* 2019; **29**: 313–317.
- 3 Eruptive Cherry Hemangiomas Associated With Multicentric Castleman Disease: A Case Report and Diagnostic Clue | Allergy and Clinical Immunology | JAMA Dermatology | JAMA Network [Internet]. URL <https://jamanetwork.com/journals/jamadermatology/fullarticle/1654890> (last accessed: 5 July 2021).
- 4 Adverse Drug Reaction Probability Scale (Naranjo) in drug induced liver injury. In: LiverTox: Clinical and Research Information on Drug-Induced Liver Injury [Internet]. National Institute of Diabetes and Digestive and Kidney Diseases, Bethesda, MD; 2012. URL <http://www.ncbi.nlm.nih.gov/books/NBK548069/> (last accessed: 24 May 2020).
- 5 Borghi A, Minghetti S, Battaglia Y, Corazza M. Predisposing factors for eruptive cherry angiomas: new insights from an observational study. *Int J Dermatol* 2016; **55**: e598–e600.
- 6 Angeli F, Spanevello A, Reboldi G, Visca D, Verdecchia P. SARS-CoV-2 vaccines: lights and shadows. *Eur J Intern Med* 2021; **88**: 1–8.
- 7 Itinteang T, Marsh R, Davis PF, Tan ST. Angiotensin II causes cellular proliferation in infantile haemangioma via angiotensin II receptor 2 activation. *J Clin Pathol* 2015; **68**: 346–350.
- 8 Rieder M, Wirth L, Pollmeier L *et al.* Serum ACE2, angiotensin II, and aldosterone levels are unchanged in patients with COVID-19. *Am J Hypertens* 2021; **34**: 278–281.
- 9 Mayi BS, Leibowitz JA, Woods AT, Ammon KA, Liu AE, Raja A. The role of Neuropilin-1 in COVID-19. *PLoS Pathog* 2021; **17**: e1009153.
- 10 Kosumi H, Nishie W, Sugai T *et al.* Ramucirumab-induced multiple haemangiomas of the skin: two case reports. *Acta Derm Venereol* 2018; **98**: 454–455.

DOI: 10.1111/jdv.17723

Recurrence of cutaneous T-cell lymphoma post viral vector COVID-19 vaccination

Dear Editor,

We are living an ongoing global COVID-19 pandemic which is associated with a considerable number of fatal cases worldwide.¹ Vaccines are the promising solution to minimize the problem amongst cancer patients; however, there are limitations to be considered such as the efficacy of COVID-19 vaccines for immunocompromised individuals and possible interactions between the vaccine and cancer.^{2–4}

On the latest issue of JEADV, Damiani *et al.*⁵ reported exacerbation of immunobullous diseases post COVID-19 vaccination.

We present two CTCL cases which were in remission for many years and the immunization with viral vector COVID-19 vaccine (Vaxzevria, Oxford/AstraZeneca, Cambridge, England) induced them to reappear.

The first case is a 60-year-old male diagnosed with folliculotropic mucosis fungoides (MF) tumour, stage T1a/IA.

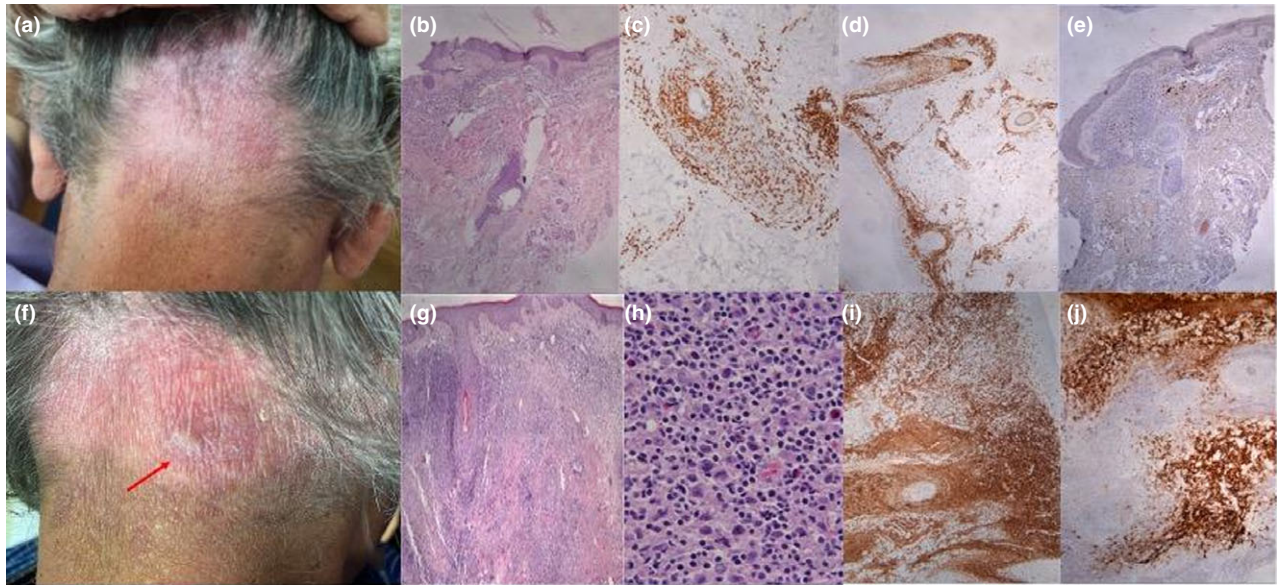


Figure 1 Clinical presentation and histology before (a–e) and after (f–j) the vaccine. (a) Purple patch on the occipital area, (b) H&E $\times 20$: Lymphoid infiltration of the dermis with prominent folliculotropism, (c) CD3 $\times 40$: CD3 expression, (d) CD4 $\times 20$: CD4 expression, (e) CD30 $\times 20$: Sparse CD30 positivity, (f) Lichenoid induration and small nodules on the periphery of the patch, (g) H&E $\times 20$: dense, diffuse, full thickness lymphoid infiltration of the dermis, (h) H&E $\times 400$: increased numbers of large neoplastic T lymphocytes among the lymphocytic population, (i) CD3 $\times 20$: CD3 expression, (j) CD30 $\times 40$: extensive CD30 positivity mainly in the large anaplastic T lymphocytes (transformation to peripheral CD30+ T-cell lymphoma).

Clinically, he presented with areas of alopecia areata such as rash (i.e. patches with hair loss on the face, arms and pubic area with no epidermal involvement) and minor patches in the same anatomic locations. The last 2 years, the disease was stage T1aN0M0 with only one stable patch on the occipital area (Fig. 1a–e); 4 weeks after the first dose of the vaccine, a minor lichenoid induration on the periphery of the patch was observed. A week after the second dose, small nodules were detected on the same location (Fig. 1f). An incisional biopsy was performed and the diagnosis of CD30⁺ large cell transformation (LCT) tumour stage MF (Fig. 1g–j) was set by immunohistochemistry and PCR analysis.

The second case is a 73-year-old female, with a 10-year history of early-stage MF (stage T1a/IA) and lymphomatoid papulosis type A (LyP). Both diagnoses were immunocytochemically and molecularly confirmed. She was treated successfully with PUVA and she was in remission the last 7 years. Ten days after the first dose of the vaccine, she developed a rash on areas where LyP was previously evident (Fig. 2a). The histology confirmed the diagnosis of LyP type-A (Fig. 2c–h).

The question which is raised in these cases is whether and via which pathway the vaccine has caused the MF CD30⁺ LCT and the reappearance of primary cutaneous CD30+ lymphoproliferative disorder.

According to the literature, the education of CD4⁺ T, CD8⁺ T and B cells against SARS-CoV-2 S protein appears to be the most feasible way for COVID-19 vaccine production. Both cancers and coronavirus provide a persistent and chronic antigenic load, amongst which PD-1, resulting in T-cell exhaustion. Therefore, it is important to assure the vaccination would not cause a further T-cell exhaustion state which may have already been induced by tumour cells.^{6–8}

CD30 is expressed on a small subset of activated T and B lymphocytes and a variety of lymphoid neoplasms. Studies showed that CD30 expression on lymphocytes could be induced by in vitro antigenic stimulation by mitogens or viruses such as HSV. CD30 expression appears higher in CD4⁺ and CD8⁺ cells producing a Th2-type cytokine response.⁶ Recently, Brumfiel *et al.*,⁷ reported a case of recurrence of cutaneous CD30 positive lymphoma following mRNA vaccine (Pfizer-BioNTech COVID-19 vaccine, New York, NY, USA). In our case, it was given a viral vector vaccine which does not include live viruses, however, contains a part of the coronavirus stuck to adenovirus, which triggers an immune response. We speculate that the recurrence of the disease in our patients as well as Brumfiel's case was possibly caused by the activation of CD30 via the above pathway i.e. overproduction and exhaustion of CD4⁺ and CD8⁺ cells which expressed CD30 after being triggered by the adenovirus. However, this could also be a coincidental finding, unrelated to the

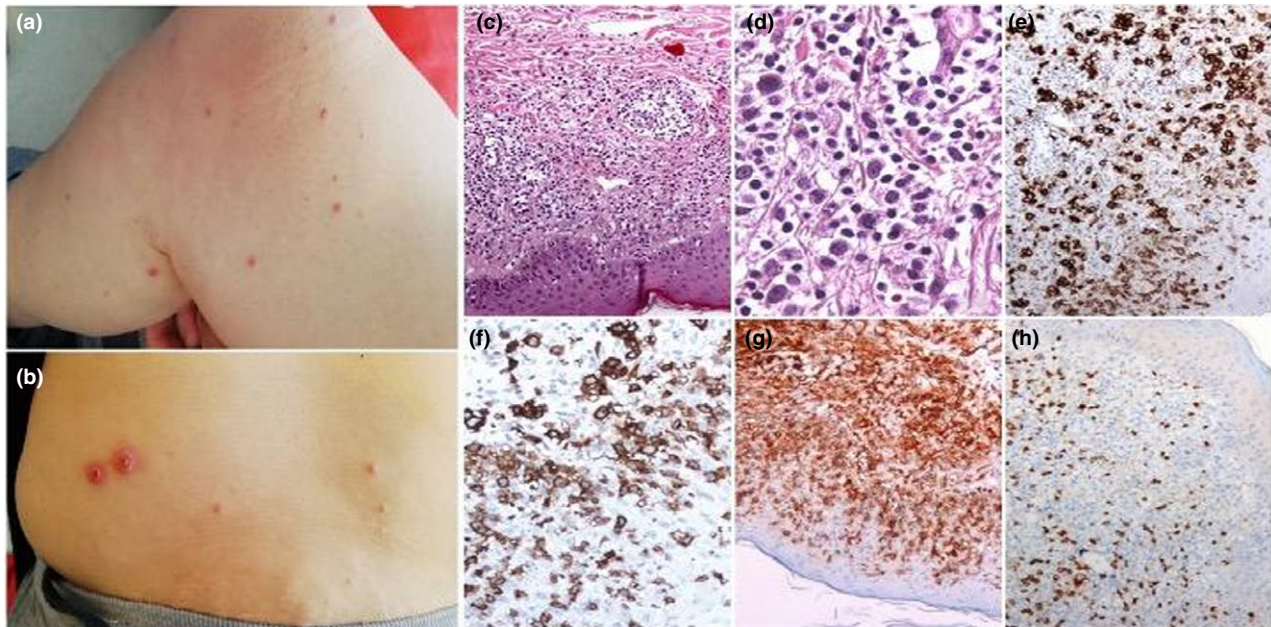


Figure 2 Clinical presentation and histology after the vaccine. (a) Erythematous papules on the dorsal aspect of the thigh, (b) erythematous papules and scaly plaques on the abdominal area, (c) H&E $\times 100$, (d) diffuse H&E $\times 200$: polymorphic infiltration of the reticular dermis by lymphocytes of various sizes (small to large anaplastic), (e) CD30 $\times 100$, (f) CD30 $\times 200$: CD30 expression by the majority of the lymphocytic population, (g) CD4 $\times 100$: Predominantly CD4 expression, (h) CD8 $\times 100$: CD8 expression.

vaccine since MF and especially the LyP are known for a waxing and waning course of the disease.

To our knowledge, reappearance of a pre-existing neoplastic condition or lymphoproliferative disease post COVID-19 vaccination is extremely uncommon. Currently, there is limited evidence in regard to the safety and efficacy of vaccines in patients with altered immunity. Further studies are needed for this target group of patients.

Acknowledgement

The patients in this manuscript have given written informed consent to the publication of their case details.

Conflict of interest

The authors have no conflict of interest.

Funding source

None declared.

E. Panou,^{1,*} V. Nikolaou,¹ L. Marinou,²
S. Kallambou,¹ P. Sidiropoulou,¹ M. Gerochristou,¹
A. Stratigos¹

¹1st Dermatology Department, Andreas Syggros Hospital for Skin Diseases, National & Kapodestrian University of Athens Medical School, Athens, Greece, ²Department of Hemopathology, Evangelismos Hospital, Athens, Greece

*Correspondence: E. Panou. E-mail: ev_panou@yahoo.gr

References

- McPeake J, Pattison N. COVID-19: Moving beyond the pandemic. *J Adv Nurs* 2020; **76**: 2447–2449.
- Liang W, Guan W, Chen R *et al*. Cancer patients in SARS-CoV-2 infection: a nationwide analysis in China. *Lancet Oncol* 2020; **21**: 335–337. <https://doi.org/10.1111/jdv.17472>
- Moris D, Tsilimigras DI, Schizas D. Cancer and COVID-19. *Lancet* 2020; **396**: 1066.
- Han HJ, Nwagwu C, Anyim O, Ekweremadu C, Kime S. COVID-19 and cancer: From basic mechanisms to vaccine development using nanotechnology. *Int Immunopharmacol* 2021; **90**: 107247.
- Damiani G, Pacifico A, Pelloni F, Iorizzo M. The first dose of COVID-19 vaccine may trigger pemphigus and bullous pemphigoid flares: is the second dose therefore contraindicated? *J Eur Acad Dermatol Venereol* 2021; **35**: e645–e647.
- van der Weyden CA, Pileri SA, Feldman AL, Whisstock J, Prince HM. Understanding CD30 biology and therapeutic targeting: a historical perspective providing insight into future directions. *Blood Cancer J* 2017; **7**: e603.
- Brumfiel CM, Patel MH, Puri P *et al*. Recurrence of primary cutaneous CD30 positive lymphoproliferative disorder following COVID-19 vaccination. *Leuk Lymphoma* 2021. <https://doi.org/10.1080/10428194.2021.1924371>
- Soleimanpour S, Yaghoubi A. COVID-19 vaccine: where are we now and where should we go? *Expert Rev Vaccines* 2021; **20**: 23–44.

DOI: 10.1111/jdv.17736