

SHORT REPORT

Lateralized *ante mortem* and *post mortem* pathology in a case of Lewy body disease with corticobasal syndrome

David G. Coughlin¹  | H. Branch Coslett² | Claire Peterson² | Jeffrey S. Phillips² | Corey McMillan² | Edward B. Lee³ | John Q. Trojanowski^{3,*} | Murray Grossman² | David J. Irwin² 

¹Department of Neurosciences, University of California San Diego, La Jolla, California, USA

²Department of Neurology, University of Pennsylvania, Philadelphia, Pennsylvania, USA

³Department of Pathology and Laboratory Medicine, University of Pennsylvania, Philadelphia, Pennsylvania, USA

Correspondence

David Irwin MD MTR, Department of Neurology, 3400 Spruce St, 3W Gates Building, Philadelphia, PA 19104, USA.

E-mail: dirwin@penmedicine.upenn.edu

* Posthumous

Funding information

AAN, Grant/Award Number: CRTS 2059; National Institutes of Health, Grant/Award Numbers: P30AG072979, AG043503, AG062429, AG062418, NS053488, NS109260

Abstract

Introduction: Lewy body diseases are pathologically characterized by α -synuclein pathology. Alzheimer's disease (AD) co-pathology can influence phenotypes. In vivo AD biomarkers can suggest the presence of this co-pathology in unusual cases, but pathological validation remains essential.

Methods: This patient originally presented with corticobasal syndrome and later developed visual hallucinations and parkinsonism consistent with a synucleinopathy. The patient underwent CSF sampling, 18F-flortaucipir PET scanning, and brain donation with bilateral regions available for digital histological analysis.

Results: CSF A β 42 and t-tau were in the AD range. 18F-flortaucipir scanning showed right-lateralized retention in all lobes ($t = 4.3$ - 10.0 , $P < .006$). Neocortical stage Lewy body pathology and high levels of AD neuropathological changes were present at autopsy. There was right lateralization of α -synuclein and tau pathology (T value = 3.1, P value = .007 and T value = 3.3, P value = .004 respectively).

Discussion: This case with overlapping tauopathy and synucleinopathy clinical features had in-depth biomarker characterization and rare bilateral post-mortem sampling showing lateralized tau and α -synuclein pathology suggesting possible synergistic relationships.

KEYWORDS

alpha-synuclein, Alzheimer's disease, cerebrospinal fluid, corticobasal syndrome, flortaucipir, Lewy body dementia, neuropathology

1 | INTRODUCTION

Lewy body disorders (LBD) are a spectrum of heterogeneous neurodegenerative diseases (i.e., Parkinson's disease [PD]; PD with dementia [PDD]; dementia with Lewy bodies [DLB]) characterized by the *post mortem* findings of α -synuclein (aSyn) pathology in Lewy bodies

and Lewy neurites. However, Alzheimer's disease (AD) co-pathology is common in LBD and is associated with greater degrees of neocortical aSyn pathology, faster time to dementia, and decreased survival.¹ Tau co-pathology in particular appears to correlate with the neocortical distribution of aSyn pathology and with specific cognitive features including episodic memory and language functioning.^{2,3}

This is an open access article under the terms of the [Creative Commons Attribution-NonCommercial-NoDerivs](https://creativecommons.org/licenses/by-nc-nd/4.0/) License, which permits use and distribution in any medium, provided the original work is properly cited, the use is non-commercial and no modifications or adaptations are made.

© 2022 The Authors. *Alzheimer's & Dementia: Diagnosis, Assessment & Disease Monitoring* published by Wiley Periodicals, LLC on behalf of Alzheimer's Association

RESEARCH IN CONTEXT

- 1. Systematic Review:** The authors reviewed the literature using traditional sources (e.g., PubMed). While pathological lateralization is well described in frontotemporal lobar degeneration, less is known about lateralization of alpha-synuclein in Lewy body disease and tau in Alzheimer's disease (AD). Tau positron emission tomography (PET) tracers can offer in vivo information about tau lateralization but detailed *post mortem* bi-hemispheric analyses are rare and are needed to confirm and expand these observations.
- 2. Interpretation:** This case had multimodal *ante mortem* biomarker assessments including cerebrospinal fluid sampling and 18F-flortaucipir PET scanning that suggested right lateralized AD tau pathology. Bilateral brain samples were available for *post mortem* digital immunohistochemical analysis and showed right lateralized tau and alpha-synuclein pathology, suggesting a synergistic relationship worthy of further study.
- 3. Future Directions:** In-depth pathological sampling with digital histological analyses provide fine-grained assessments of pathological severity and can suggest unique patterns of disease spread and suggest mechanisms of pathophysiology. The case adds to the growing understanding of the interaction between alpha-synuclein and tau pathology.

Emerging biofluid biomarkers and molecular imaging tracers appear to be able to detect this pathology in vivo, with studies similarly suggesting a strong clinical influence of AD tau pathology in LBD.^{4,5} The LBD clinical syndromes (PD, PDD, DLB) are fairly specific for underlying synucleinopathy; however, neocortical aSyn pathology can be found in asymptomatic individuals, in patients with clinical AD,⁶ and has also been occasionally reported in association with focal lateralized cortical presentations in the frontotemporal dementia spectrum, including primary progressive aphasia⁷ and corticobasal syndrome (CBS).⁸ *Post mortem* analysis of these focal cortical syndromes can provide a unique insight into the distribution of pathology across hemispheres and suggest pathophysiological mechanisms of disease spread,^{9,10} but detailed bilateral *post mortem* immunohistochemical assessment in LBD with lateralized clinical features is lacking. We are unaware of a previous assessment of combined lateralization of mixed pathology in CBS. Here, we present a novel interhemispheric assessment of pathology in an unusual case with highly lateralized clinical symptoms with overlapping features of a synucleinopathy and a tauopathy who had both *ante mortem* positron emission tomography (PET) imaging and rare bilateral *post mortem* histopathological assessments.¹¹

HIGHLIGHTS

- This case had features of corticobasal syndrome and Lewy body dementia.
- Cerebrospinal fluid and 18F-flortaucipir scanning suggested right-lateralized Alzheimer's disease (AD) tau pathology.
- Right-lateralized tau and alpha-synuclein pathology was present at autopsy.
- In vivo biomarkers can help identify AD pathology in unusual presentations.
- Lateralization of tau and alpha-synuclein suggests a synergistic relationship.

2 | CASE PRESENTATION

The patient initially presented with left-sided neglect, left-sided myoclonus, and significant visuospatial and executive impairments at age 64, consistent with a diagnosis of possible CBS.¹² The patient had several minor motor vehicle accidents and eventually was unaware of the left side of his visual field, evidenced by the history of him often leaving the left side of his plate uneaten, requiring his family to turn the plate for him to finish a meal. The minor car accidents did not result in closed head injury or loss of consciousness and did not require medical care or hospitalization. Four years later at age 68 he developed well-formed visual hallucinations, excessive daytime sleepiness despite a full night sleep, cognitive fluctuations, along with motor Parkinsonism with left sided cogwheel rigidity and bradykinesia, fulfilling clinical criteria for DLB.¹³ Alien-limb phenomenon was also noted at that time. Tremor was not present nor was hyperreflexia or orthostatic hypotension. There was not cortical blindness on exam. The patient was enrolled into biomarker and brain donation research programs and informed consent for each study and for subsequent publication was obtained. The study was performed in accordance with the ethical standards as laid down in the 1964 Declaration of Helsinki and its later amendments with protocols being approved locally by the University of Pennsylvania's Institutional Review Board. AD cerebrospinal fluid (CSF) biomarker analysis using the Lumindex platform and AlzBio3 immunoassay reagents (AlzBio3[®], Innogenetics NV) and 18F-flortaucipir PET were obtained (5 years after symptom onset and 8 months prior to death) and analyzed using previously published protocols.⁴ PET images were parcellated into 116 cortical brain regions and grouped into major areas for analysis (frontal, temporal, parietal, occipital, limbic, and subcortical regions including caudate nucleus and putamen, etc.). Asymmetry indices ($[(\text{Right}-\text{Left})/(\text{Right}+\text{Left})]*100$) for regional standardized uptake value ratio (SUVr) were calculated ($n = 58$) and compared to a hypothesized mean of 0 (i.e., symmetric disease) using one-sided *t*-tests.⁹ A subset of data from this case was previously included in a series of multimodal tau biomarkers in LBD.¹¹ Bilateral sections were available from 17 neocortical and two

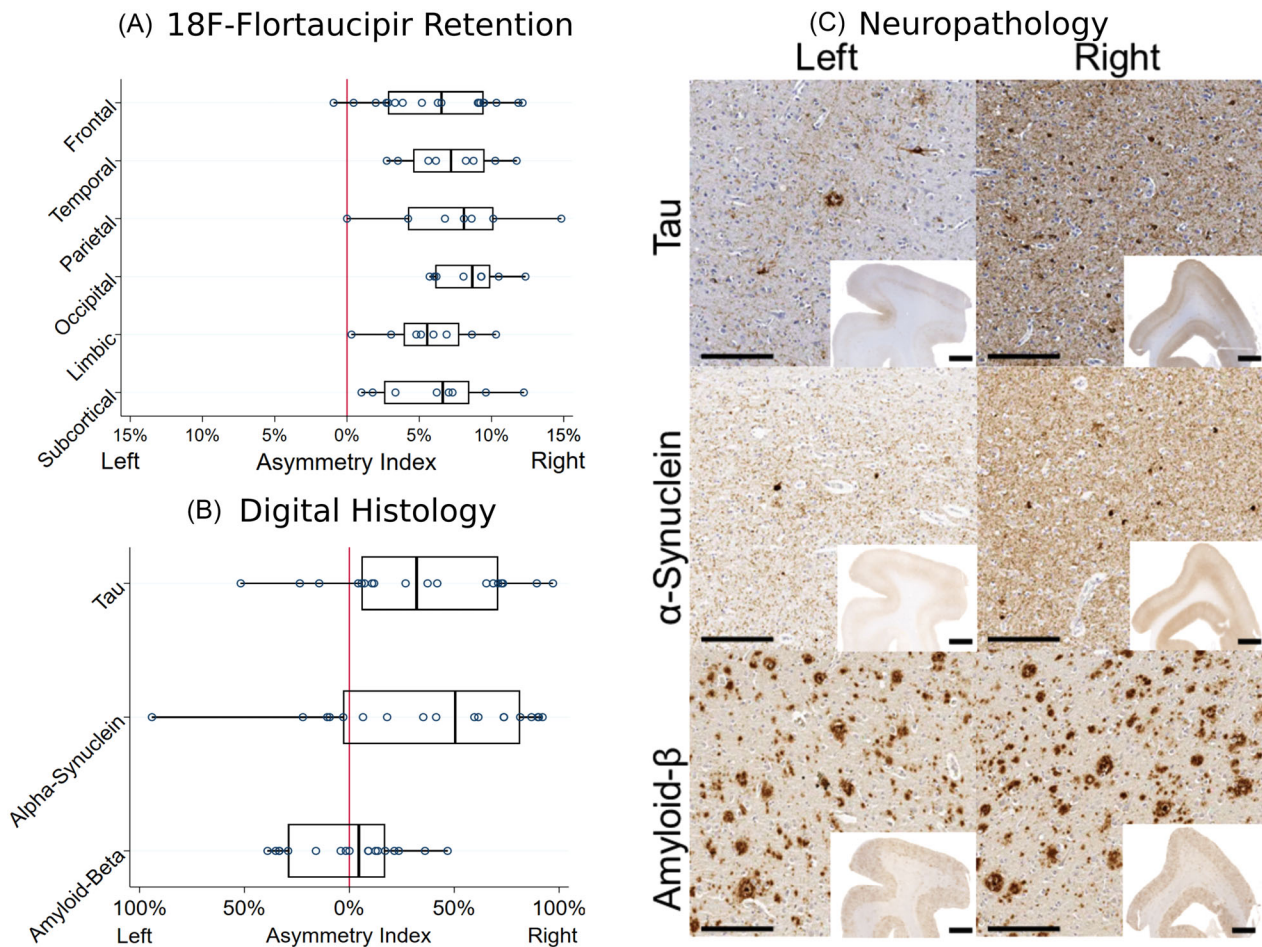


FIGURE 1 A, Asymmetry indices calculated from regional 18F-flortaucipir positron emission tomography (PET) image standardized uptake value ratio. B, Asymmetry indices calculated from digital histological measurements of % area occupied by pathological inclusions of tau, α -synuclein, and amyloid beta ($A\beta$). Right lateralization was observed for all PET region groups and for tau and α -synuclein pathology while $A\beta$ pathology was symmetric. C, Representative images from the bilateral sections of the dorsolateral prefrontal cortex immunostained for tau, alpha synuclein, and $A\beta$. High-magnification images were taken at 10x with scale bar of 200 μ m. Low-magnification inset images were taken at 0.5x with a scale bar of 2 mm. Higher density tau and α synuclein pathology is noted in the right hemispheric sections whereas $A\beta$ pathology is equally distributed

subcortical regions (see [supporting information](#)), which were immunostained stained for phosphor-tau (AT8, ThermoFisher 1:1000, no antigen retrieval), amyloid beta ($A\beta$; NAB228, CNDR 1:40,000, formic acid antigen retrieval), and aSyn (MJF-R13 Abcam1:15,000, proteinase K antigen retrieval). Whole-slide images were obtained using a digital slide scanner (Aperio AT2, Leica Biosystems) at 20x magnification, and gray matter regions were analyzed to calculate %area occupied (%AO) of reactivity for tau, $A\beta$, and aSyn pathology using QuPath software (version 0.2.0-m2) as previously published.^{3,14} Asymmetry indices were similarly calculated as above.

CSF $A\beta_{42}$ was 105 pg/mL, total-tau was 80 pg/mL, and phosphorylated tau₁₈₁ was 19 pg/mL, all of which are consistent with AD co-pathology using our previously published autopsy-validated cutpoints in LBD.⁴ Average cortical flortaucipir SUVR was 1.48 (left hemisphere SUVR = 1.40 ± 0.27 standard deviation [SD]; right hemisphere SUVR = 1.61 ± 0.36 SD) in the range consistent with AD-related tau pathology.¹¹ Comparison of intrahemispheric tracer uptake showed right lateralization overall and in each major area

(overall: T value = 14.4, P value < .001; regions: T value = 4.3–10.0, all P values < .006; Figure 1A). *Post mortem*, the brain weighed 1366 grams and neuropathological examination showed neocortical stage LBD and high-level AD neuropathologic change by criteria (Thal phase 4: A3, Braak stage V: B3, CERAD C3).¹⁵ Tufted astrocytes, coiled bodies, astrocytic plaques, and argyrophilic grains were not identified. There was significant right lateralization of tau and aSyn pathology in regions with bilateral sampling (Tau: right %AO = $43.3\% \pm 20.9$ SD, left %AO = $28.3\% \pm 24.04$ SD T value = 3.3, P value = .004; aSyn: right %AO = $32.0\% \pm 25.5$ SD, left %AO = $18.3\% \pm 24.4$ SD, T value = 3.1, P value = .007). $A\beta$ pathology was not lateralized (P value = .98) (Figure 1B,C).

3 | DISCUSSION AND CONCLUSION

This is a case report of a patient with an unusual presentation originally most consistent with CBS who later developed LBD features;

this patient had in-depth biomarker analyses that suggested lateralized AD-related tau pathology that fit with clinical symptoms of left-sided neglect and myoclonus. This patient also participated in brain donation and rare bilateral sampling was available for modern digital histological analysis to assess pathology laterality. This analysis adds to previous work showing that AD tau pathology is influential in symptoms of CBS and LBD.^{2,3,16} The features of apraxia and neglect experienced by this patient are associated with right parietal lobe dysfunction, which can be associated with both posterior cortical atrophy and CBS and AD pathology is well described to result in both phenotypes.^{12,17} In this case, tau pathology was detectable during life using biofluid and imaging biomarkers and anatomically consistent with clinical symptoms and *post mortem* distribution of pathology. We and others previously reported an association of tau pathology in LBD with cortical atrophy on magnetic resonance imaging in the medial and lateral temporal lobe, and here we extend these findings to this atypical clinical presentation whose features correlate more closely to frontal and parietal regions.¹⁸ Interestingly aSyn pathology but not A β plaque was also strongly lateralized to the right hemisphere potentially suggesting a synergistic interaction between tau and aSyn. Indeed, this hypothesis aligns well with prior *in vitro* and *in vivo* studies that have shown that certain strains of aSyn pathology are capable of cross seeding tau pathology.¹⁹ It is also possible that there was early lateralization of A β pathology that had plateaued later in the disease course. While AD pathology is well described to result in a CBS phenotype, in the absence of current *in vivo* methods to detect spatial distribution of aSyn pathology, it is not possible to determine the molecular progression of proteinopathy in relationship to clinical symptoms, and thus, one cannot rule out a contribution from aSyn to the initial clinical features of this patient.

We are unaware of a previous assessment of lateralization of mixed pathology in CBS. The neuropathological substrates associated with clinical CBS include corticobasal degeneration pathology, progressive supranuclear palsy pathology, lateralized atypical AD pathology, and even rare presentations of other proteinopathies including LBD.⁸ In a case series, 11/523 subjects with a clinical diagnosis of CBS had a primarily LBD pathology noted at autopsy and four had co-occurring severe AD pathology, but this study did not include assessments of laterality of pathology across hemispheres.⁸ Lateralization of frontotemporal dementia syndromes using quantitative measures have been published as have qualitative studies of laterality of pathology in AD and LBD, but the assessment of this case is a unique study of quantitative lateralization of mixed pathology in CBS.^{9,10}

A limitation of the current study was that brainstem regions were not available for comparison of laterality of pathology, which would further elucidate when some of these interactions between tau and aSyn may be occurring; however, we were able to assess the rostral end of the nigrostriatal pathway in the caudate and putamen, where tau and aSyn was lateralized similarly to the cortical regions analyzed (Tau: right %AO: 49.2% \pm 6.44 SD, left %AO: 1.84% \pm 1.67 SD; aSyn: right %AO: 59.0% \pm 19.8 SD, left 6.74% \pm 6.14 SD).

Future work combining longitudinal biomarker collection with gene expression data and detailed anatomic study may uncover insights into

regional and interhemispheric neuronal vulnerabilities to neurodegeneration, which could be potentially targeted for therapeutic development in AD and LBD. Finally, the reasons for focal lateralized clinical presentations of neurodegenerative diseases are unclear but may relate in part to developmental, genetic, and environmental factors that could influence the onset and spread of pathology.²⁰

This case also highlights the utility of using current biomarkers in patients with unusual clinical presentation. In this case lateralized AD-related tau pathology was suggested on PET imaging, which was confirmed along with lateralized aSyn pathology at autopsy. Future application of aSyn aggregation assays will likely aid in the detection of the presence of aSyn seeds, which can be coupled with AD-specific biomarkers in such patients with co-pathology.

Last, typical neuropathological assessments incorporate immunohistochemistry from a single hemisphere. While laterality is well described in CBS, posterior cortical atrophy, and frontotemporal dementia syndromes, less is known about laterality in LBD.^{7,17} Bilateral sampling and the use of digital histology methods can aid in improving understanding of unique patterns and suggest mechanisms of disease spread.

ACKNOWLEDGMENTS

Avid Radiopharmaceuticals provided ¹⁸F-flortaucipir tracer used in this study and were involved in the decision to publish the paper. They were not involved in study design, collection, analysis or interpretation of data, or the writing of this report. This work was funded by the AAN (CRTS 2059), the National Institutes of Health (P30AG072979, AG043503, AG062429, AG062418, NS053488, NS109260).

CONFLICTS OF INTEREST

The authors have no competing interests or conflicts of interest to declare that are relevant to the content of this article.

AUTHOR CONTRIBUTIONS

David G. Coughlin and David J. Irwin: conception, organization and execution of the project, writing the first draft and revisions. Claire Peterson, H. Branch Coslett, Jeffrey S. Phillips, Corey McMillan, Edward B. Lee, John Q. Trojanowski, Murray Grossman: execution of the project and review of the manuscript.

AUTHOR INFORMATION

The work was completed while David Coughlin was affiliated at the University of Pennsylvania and now at the University of California San Diego.

ORCID

David G. Coughlin  <https://orcid.org/0000-0003-4111-0102>

David J. Irwin  <https://orcid.org/0000-0002-5599-5098>

REFERENCES

1. Coughlin DG, Hurtig HI, Irwin DJ. Pathological influences on clinical heterogeneity in lewy body diseases. *Mov Disord* 2019. <https://doi.org/10.1002/mds.27867>.

2. Peavy GM, Edland SD, Toole BM, et al. Phenotypic differences based on staging of Alzheimer's neuropathology in autopsy-confirmed dementia with Lewy bodies. *Parkinsonism Relat Disord* 2016;31:72-78. <https://doi.org/10.1016/j.parkreldis.2016.07.008>.
3. Coughlin D, Xie SX, Liang M, et al. Cognitive and pathological influences of tau pathology in lewy body disorders. *Ann Neurol* 2019;85:259-271. <https://doi.org/10.1002/ana.25392>.
4. Irwin DJ, Xie SX, Coughlin D, et al. CSF tau and amyloid-beta predict cerebral synucleinopathy in autopsied Lewy body disorders. *Neurology* 2018. <https://doi.org/10.1212/wnl.0000000000005166>.
5. Kantarci K, Lowe VJ, Boeve BF, et al. AV-1451 tau and β -amyloid positron emission tomography imaging in dementia with Lewy bodies. *Ann Neurol* 2017;81:58-67.
6. Parkkinen L, Pirttila T, Alafuzoff I. Applicability of current staging/categorization of alpha-synuclein pathology and their clinical relevance. *Acta Neuropathol* 2008;115:399-407. <https://doi.org/10.1007/s00401-008-0346-6>.
7. Dickson DW, Kouri N, Murray ME, Josephs KA. Neuropathology of Frontotemporal Lobar Degeneration-Tau (FTLD-Tau). *J Mol Neurosci* 2011;45:384-389. <https://doi.org/10.1007/s12031-011-9589-0>.
8. Kasanuki K, Josephs KA, Ferman TJ, et al. Diffuse Lewy body disease manifesting as corticobasal syndrome A rare form of Lewy body disease. *Neurology* 2018;91:E268-79. <https://doi.org/10.1212/WNL.0000000000005828>.
9. Giannini LAA, Xie SX, McMillan CT, et al. Divergent patterns of TDP-43 and tau pathologies in primary progressive aphasia. *Ann Neurol* 2019;85:630-643.
10. Stefanits H, Budka H, Kovacs GG. Asymmetry of neurodegenerative disease-related pathologies: a cautionary note. *Acta Neuropathol* 2012;123:449-52. <https://doi.org/10.1007/S00401-011-0936-6>.
11. Coughlin DG, Phillips JS, Roll E, et al. Multimodal in vivo and post-mortem assessments of tau in lewy body disorders. *Neurobiol Aging* 2020.
12. Armstrong MJ, Litvan I, Lang AE, et al. Criteria for the diagnosis of corticobasal degeneration. *Neurology* 2013;80:496-503. <https://doi.org/10.1212/WNL.0b013e31827f0fd1>.
13. McKeith IG, Boeve BF, Dickson DW, et al. Diagnosis and management of dementia with Lewy bodies: fourth consensus report of the DLB Consortium. *Neurology* 2017;89:88-100.
14. Bankhead P, Loughrey MB, Fernández JA, et al. QuPath: Open source software for digital pathology image analysis. *Sci Rep* 2017;7:16878.
15. Montine TJ, Phelps CH, Beach TG, et al. National Institute on Aging-Alzheimer's Association guidelines for the neuropathologic assessment of Alzheimer's disease: a practical approach. *Acta Neuropathol* 2012;123:1-11. <https://doi.org/10.1007/s00401-011-0910-3>.
16. Irwin DJ, Grossman M, Weintraub D, et al. Neuropathological and genetic correlates of survival and dementia onset in synucleinopathies: a retrospective analysis. *Lancet Neurol* 2017;16:55-65. [https://doi.org/10.1016/s1474-4422\(16\)30291-30295](https://doi.org/10.1016/s1474-4422(16)30291-30295).
17. Renner JA, Burns JM, Hou CE, McKeel DW, Storandt M, Morris JC. Progressive posterior cortical dysfunction: a clinicopathologic series. *Neurology* 2004;63:1175-80. <https://doi.org/10.1212/01.WNL.0000140290.80962.BF>.
18. Spoto N, Coughlin DG, Olm CA, et al. Tau pathology associates with in vivo cortical thinning in Lewy body disorders. *Ann Clin Transl Neurol* 2020.
19. Basil F, Meymand ES, Brown HJ, et al. α -Synuclein modulates tau spreading in mouse brains. *J Exp Med* 2021;218. <https://doi.org/10.1084/jem.20192193>.
20. Rogalski E, Weintraub S, Mesulam MM. Are there susceptibility factors for primary progressive aphasia? *Brain Lang* 2013;127:135-8. <https://doi.org/10.1016/j.bandl.2013.02.004>.

SUPPORTING INFORMATION

Additional supporting information may be found in the online version of the article at the publisher's website.

How to cite this article: Coughlin DG, Coslett HB, Peterson C, et al. Lateralized *ante mortem* and *post mortem* pathology in a case of Lewy body disease with corticobasal syndrome. *Alzheimer's Dement*. 2022;8:e12294. <https://doi.org/10.1002/trc2.12294>