

Cone-beam Computed Tomographic Analysis of Deciduous Root Canals after Instrumentation with Different Filing Systems: An *In Vitro* Study

Priyanka Singh¹, Sonali Saha², Abhay Mani Tripathi³, Gunjan Yadav⁴, Kavita Dhinsa⁵

ABSTRACT

Aim and objective: To evaluate root canal transportation, centering ability ratio (CAR), remaining dentine thickness, dentinal cracks, and instrumentation time after instrumentation with different filing systems in root canals of primary teeth by cone beam computed tomography (CBCT) analysis.

Materials and methods: Sixty prepared canals of primary teeth divided into 4 groups with 15 canals in each were prepared with NiTi K files, Proaper Next (PTN) files, OneShape (OS), and WaveOne (WO) files, respectively. Using CBCT scan, the pre- and postinstrumentation scan was done to obtain images at three levels (apical, middle, and cervical). The results obtained were statistically analyzed using SPSS 21 statistical software version.

Result: Significant statistical difference was found between different filing systems.

Conclusion: ProTaper Next files showed least canal transportation and the best centering ability was shown by OS file system. The NiTi K hand files preserved maximum remaining dentin thickness (RDT) and produced minimum dentin cracks. WO file system took least instrumentation time when compared to the other three filing systems.

Clinical significance: The use of rotary instruments in the pulpectomy of primary teeth represents a promising technique being advantageous for the pediatric patients by maintaining the original canal curvatures, showing greater ability to maintain dentin thickness, causing lesser dentin cracks, and reducing chair time thus favoring preparation of more conical root canals and better obturation.

Keywords: Cone beam computed tomography, Nickel–titanium, Primary teeth, ProTaper, WaveOne.

International Journal of Clinical Pediatric Dentistry (2022): 10.5005/jp-journals-10005-2126

INTRODUCTION

Hand instrumentation remains to be the conventional endodontic treatment technique for primary teeth.¹ Earlier use of stainless steel hand files was the primary means for cleaning and preparing root canals in pulpectomy and root canal therapy.² An ideal root canal preparation should be a tapered preparation maintaining a continued taper from crown to the apex and restricting the size of apical foramen to minimal.² Stainless steel hand files failed to fulfil these objectives of ideal root canal preparation leading to the advent of rotary nickel–titanium (NiTi) instruments in endodontics. It was a significant move toward achievement of optimal root canal shaping in root canal treatment.² The turquoise and curved canals in primary teeth are always very challenging to clean and prepare often leading to complications such as ledge formation, perforation, etc.³ As a result, even the rotary instruments needed modifications to overcome these drawbacks.

Rotary NiTi files produce a continuous tapered preparations without causing any canal transposition and lead to lesser errors.⁴ Such root canal preparations make final obturation with pastes more easier and uniform.⁴ Almost all NiTi instrument systems follow the most common symmetrical cross-sectional design, but the new generation special NiTi rotary systems such as PTN by Dentsply, Maillefer of Switzerland has a special offset design. ProTaperNextPTN, which is made by the M-Wire, is considered a multiadvantage instrument system.⁵ Its offset design not only provides the instrument good debris-collection ability but also creates larger envelope movements as compared to a conventional rotary NiTi instrument of the same size.⁵

¹⁻⁵Department of Pedodontics and Preventive Dentistry, Sardar Patel Post Graduate Institute of Dental Sciences, Lucknow, Uttar Pradesh, India

Corresponding Author: Priyanka Singh, Department of Pedodontics and Preventive Dentistry, Sardar Patel Post Graduate Institute of Dental Sciences, Lucknow, Uttar Pradesh, India, Phone: +91 8527770821, e-mail: priyankasingh909@gmail.com

How to cite this article: Singh P. Cone-beam Computed Tomographic Analysis of Deciduous Root Canals after Instrumentation with Different Filing Systems: An *In Vitro* Study. *Int J Clin Pediatr Dent.* 2022;15(S-1):S22–S29.

Source of support: Nil

Conflict of interest: None

Now a days, single-file systems are in practice but their use in endodontics is still questionable because of lesser research and studies pertaining to their efficacy and applicability.⁴ Recently One Shape files from Micromega, France have come into practice; its NiTi single-file system that works in continuous rotation motion. Its main advantage is the noncutting safe tip that leads to smooth progression of the file into the canal without causing instrument breakage.⁶

Nickel–titanium rotary instruments working in rotational motion often cause procedural errors like file breakage due to fatigue and torsional shear stresses.⁶ Therefore in spite of their excellent cleaning efficacy and uniformity in canal preparation, chances of file separation cannot be prevented. Lately NiTi rotary

instruments working in reciprocating motion have shown lesser cyclic fatigue as compared to rotary files moving in continuous rotation motion.⁶ Hence the single file shaping systems with new mode of reciprocation rotation was developed to decrease the complexity of instrumentation.⁵ The WO files from Dentsply, Switzerland was one of the first reciprocating single file system.⁵ The manufacturer of WO claims that it has more flexibility and strength as compared to that of conventional NiTi instruments.⁵ With reciprocating rotation mode, which turns the instrument in unequal bidirectional movements with less than a circle active movement, the WO instrument generates less stress than does a continuous rotary instrument and therefore has a longer fatigue life.⁷

Along with the developments made in the field of rotary instrumentation, various analyzing systems have been introduced and are being incorporated in the endodontic practice to study effect of various rotary instruments on root canal morphology.⁷ To overcome the shortcomings of conventional radiographs, advanced digital imaging modalities were introduced in dentistry, one of which is CBCT.⁸ This system is less time consuming with added advantages of clear and sharp image formation and lesser patient discomfort.⁸

As there are scanty studies and very few literature evaluating the cleaning and shaping potential of hand- and engine-driven instrumentation in deciduous teeth; hence, the aim of our study was to assess and compare canal transportation, centering ability, remaining dentin thickness, dentinal cracks, and instrumentation time using WO, OS, PTN file systems, and hand NiTi K files in primary teeth using CBCT analysis.

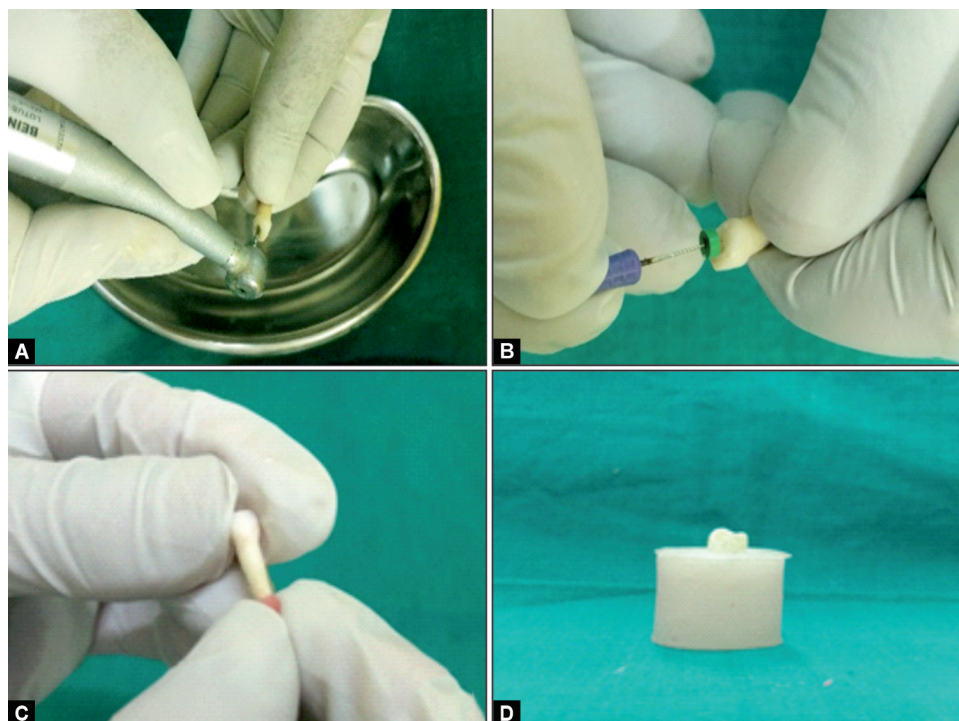
MATERIALS AND METHODS

The study was conducted in the Department of Pedodontics and Preventive Dentistry at Sardar Patel Post Graduate Institute of Dental and Medical Sciences, Lucknow collaborating with Raydent i-CAT

Dental and Maxillofacial Imaging Center, Lucknow. The approval of Institutional Ethical Committee was obtained before beginning of the research.

Forty-four primary teeth were taken for the study which were stored in 10% formalin solution. These 44 extracted teeth were divided into 60 study samples according to availability of intact root canals for endodontic preparations. The samples collected were extracted due to various reasons, e.g., root resorption of one of the roots, with greater bone loss or infection beneath the roots or over retained primary teeth altering the path of eruption of underlying permanent teeth, etc. The samples collected had at least two third of root length present. Teeth having undergone endodontic treatment or involving severe root resorption were excluded from the studies. The access cavity preparation was done using a Endo z bur (Fig. 1A). The samples were rinsed with normal saline and length of root canals was determined visually by placing 10 number file till the file reached the apex of tooth. Considering that primary teeth show apical resorption, working length was set 1 mm less than the actual length (Fig. 1B).

All samples were immersed in acrylic mold for preinstrumentation CBCT scan. The apex of the tooth was filled with wax to avoid the entry of resin in the tooth (Fig. 1C). The samples were embedded in the acrylic mold in such a way that the long axis of the tooth and mold are parallel to each other for accurate measurements during CBCT scan (Fig. 1D). This method of mounting the study samples was done in studies conducted by Prabhakar et al.⁴ and Elnagar et al.⁹ Cone beam computed tomography images of all teeth were captured for the first time (I-Cat Viewer, GENDEX GXCB-500™, Gendex Dental Systems, USA) before instrumentation (Fig. 2). Exposure parameters were same for pre- and postinstrumentation: as 20 seconds with voltage of 84 kVp, and 5 mA of current (Fig. 3). The CBCT images were analyzed using *in vivo* 5 software (Egg Viewer, Gendex Dental Systems, USA) and the Dell Precision M6400 Workstation (Dell, Round Rock, TX, USA). Data were acquired



Figs 1A to D: For sample preparation

as volume acquisition and reconstructed in multiple planes. The slices in panoramic window were chosen in such a way that very clear images of the root canals could be acquired. Three sections were created at three levels apical, middle, and cervical level.

Post-CBCT scan of all samples were subdivided into 4 groups of 15 samples each depending on the filing systems to be used.

Group I (NiTi K files): In this group manual instrumentation with NiTi K files of Dentsply using step back technique was done till size 30.

Group II (PTN files): In this group, PTN files by Dentsply were used in a crown down technique. It has three different files used in the following sequence—firstly Sx file was used to enlarge the coronal portion followed by X1 till working length and lastly X2 to finish canal preparation.

Group III (OS files): Root canals were enlarged with Endoflare to 3 mm distance to get coronal portion enlarged followed by OS main file till working length at speed of 400 rpm and torque of 2 Ncm.

Group IV (WO Files): In this group WO small file (6% taper) was used in the Crown-Down technique.

The time required for complete instrumentation was recorded using a stopwatch. After the instrumentation post-CBCT scan was taken keeping in mind the position of pre-CBCT scan. Both the CBCT scans carried out before and after instrumentation were overlapped and various factors such as the thickness of remaining dentin, ratio of centering ability, and canal transportation were




Fig. 2: Study samples arranged for preinstrumentation CBCT scan

measured using Gambill et al.¹⁰ Whereas dentin cracks were studied and compared based on method given by Priya et al.¹¹

All the parameters were evaluated as follows:

- **Canal transportation (CT)**

Canal transportation (CT) was calculated from the equation: $(M1 - M2) - (D1 - D2)$ where

M1—distance from external surface of mesial portion of root to mesial wall of non instrumented canal

M2— distance from external root surface of mesial portion of root to mesial wall of canal after instrumentation.

D1—distance from external surface of distal portion of root to distal wall of non instrumented canal

D2—distance from external surface of distal portion of root to distal surface of canal after instrumentation.

Regarding transportation direction following inferences was noted:

- CT = 0, no transportation
- CT = a negative value, transportation in distal direction
- CT = a positive value, transportation in mesial direction.

- **Centering ability ratio (CAR)**

Centering ability ratio was calculated using the equation: $(M1 - M2)/(D1 - D2)$

M1, *M2*, *D1*, and *D2* were obtained during measurement of CT

- CAR = 1 indicates perfect centralization.
- CAR = close to zero means instrument is not able to stay along central axis.

- **Remaining dentin thickness (RDT)**

It was recorded from the external root surface to inner surface of pulp space at three different levels.

- **Dentinal cracks**


They were either preset or absent

- **Instrumentation time calculation**

Instrumentation time was measured in minutes by stopwatch. Total time was from the beginning of instrumentation till the end, including the time spend on the irrigation also.

RESULTS

The data were statistically analyzed using SPSS version 21 software. Inferential statistics was performed using one-way analysis of variance (ANOVA) and chi-square test.



Figs 3A and B: Scanned samples: (A) Transverse section; (B) Longitudinal section

Canal Transportation

At cervical level the mean canal transportation score of PTN files was statistically less than NiTi K files followed by OS and WO files, respectively. At apical and middle level, no statistically difference was seen in all four filing groups (Table 1).

Centering Ability Ratio

At cervical level, CAR showed difference in all four filing groups. OneShape files showed optimum centering ability followed by PTN files, NiTi K files, and WO files, respectively. At apical and middle level, no difference was seen in all the four filing groups (Table 2).

Remaining Dentin Thickness

At cervical level, RDT among NiTi K files was statistically significantly more than PTN followed by OS and WO, respectively. At middle level RDT did not show any statistically difference in all filing groups. At apical level, RDT in NiTi K files was statistically significantly more than the OS followed by WO and PTN, respectively (Table 3).

Dentin Cracks

The mean number of cracks at all levels in NiTi K files was statistically significantly less as compared to WO followed by PTN and OS, respectively (Table 4).

Instrumentation Time

The mean instrumentation time taken by WO was statistically significantly least as compared to OS followed by, PTN and NiTi K files, respectively (Table 5).

DISCUSSION

In today's era, endodontic treatment seems to be of utmost importance to retain the primary teeth until the permanent successor erupts. Hence endodontic treatment seems to be the best option for treatment of these teeth affected with pulpitis and pulp necrosis to maintain its integrity.¹² The chair time should also be considered in endodontic therapy, especially in pediatric dentistry for which several devices and several have been introduced developed to make the treatment easier, faster, and more effective.¹³ With the beginning concepts of root canal therapy, hand files made of stainless steel were used for preparing the root canals which had tendency to create irregularities. This is due to the stiffness encountered on stainless steel together with the design of the instrument and shape of the canal.¹³

As stated by Hatton et al.¹⁴ instruments made of stainless steel clean canals very superficially thereby not removing much of the pulp tissues. To overcome drawbacks of hand instrumented canal preparation (i.e., ledge formation, apical blockage, etc.), with rotary instruments made of NiTi has been stressed upon.¹⁵ Preparing canals of primary teeth mechanically using rotary files made of NiTi was first proposed by Barr et al.¹⁶ According to them using NiTi rotary files for primary teeth has proved to be faster, more economical, and more uniform. This could be attributed to the superelasticity of these files. These rotary files produce less forces laterally against the canal wall and can be used specifically in canals which are severely curved. Reducing the propensity of creating the canal irregularities together with continuing to maintain the original shape of the canal.¹⁷

Kuhn and David¹⁸ stated that this is the design of the instrument, type of alloy, and technique of instrumentation that govern the centricity of preparation of the canal. Hence numerous rotary file systems made of NiTi have been originated with various tip designs, e.g., ProTaper universal filing system by Dentsply. The files of this system are convex and triangular in cross-section, cutting edges which are sharp, safety tip which is non cutting, absence of radial lands, and flexibility.¹⁸

ProTaper Next instrument system which is rectangular in cross-section is an improved and modified category of the universal ProTaper system which is made from a specialized M wire, heat treated NiTi alloy. When compared to ProTaper Universal system, the PTN has improved flexibility, torsional resistance, and less cyclic fatigue.¹⁹ Pansheriya et al.²⁰ stated that PTN provides greater space cross-sectionally for a more superior cutting thereby allowing these files to cut in a larger area of motion due to their swaggering effects.

Recently, in contrast to multiple file system of PTN new OS single files has been introduced for preparation of root canals when compared to the multiple file systems.²¹ These files have the advantage of using a single file during the complete shaping of the root canal in continuous rotary motion. They have a tip size of 25 and its taper is 0.06. Its made up of austenite 55 NiTi alloy. It has an innovative instrument design with various cross-sectional zones across the full length of file.⁵ There are three specific cutting edges in the tip of the instrument while in the middle the cross-section represents two cutting edges.⁶ There are two cutting edges in the shank region having an S-shaped cross-section. This pattern is alleged to abolish the binding and threading during continuous rotation.⁶

Table 1: Intergroup comparison of canal transportation in apical, middle, and cervical levels of the study samples

Canal transportation	N	Mean	Std. deviation	95% Confidence interval for mean		P value	Post hoc pairwise comparison
				Lower bound	Upper bound		
Apical	Group I (NiTi K files)	15	0.0667	0.10574	0.0081	.1252	0.093, NA
	Group II (ProTaper next files)	15	0.0573	0.04317	0.0334	0.0812	NS
	Group III (One Shape files)	15	0.0807	0.05509	0.0502	0.1112	
	Group IV (Wave One file)	15	0.1393	0.14190	0.0608	0.2179	
Middle	Group I (NiTi K files)	15	0.0813	0.08193	0.0360	0.1267	0.208, NA
	Group II (ProTaper next files)	15	0.0933	0.09263	0.0420	0.1446	NS
	Group III (One Shape files)	15	0.1533	0.13584	0.0781	0.2286	
	Group IV (Wave One file)	15	0.1467	0.13292	0.0731	0.2203	
Cervical	Group I (NiTi K files)	15	0.0747	0.06621	0.0380	0.1113	0.016, Group I, group II < group III
	Group II (ProTaper next files)	15	0.0647	0.05502	0.0342	0.0951	S
	Group III (One Shape files)	15	0.1907	0.20717	0.0759	0.3054	
	Group IV (Wave One file)	15	0.0913	0.06198	0.0570	0.1257	

Table 2: Intergroup comparison of centering ability ratio in apical, middle, and cervical parts of study samples

Centric ability ratio	N	Mean	Std. deviation	95% Confidence interval for mean		P value	Post hoc pairwise comparison
				Lower bound	Upper bound		
Apical	Group I (NiTi K files)	15	2.3874	2.26087	1.1354	3.6394	0.221, NA
	Group II (ProTaper next files)	15	0.8104	0.57142	0.4939	1.1268	NS
	Group III (One Shape files)	15	2.6841	5.12395	-0.1534	5.5217	
	Group IV (Wave One file)	15	3.3159	3.65016	1.2945	5.3373	
Middle	Group I (NiTi K files)	15	1.0246	1.23,056	0.3431	1.7061	0.895, NA
	Group II (ProTaper next files)	15	1.0858	0.46,877	0.8262	1.3454	NS
	Group III (One Shape files)	15	1.4176	2.40,764	0.0843	2.7509	
	Group IV (Wave One file)	15	1.2882	1.50,299	0.4559	2.1205	
Cervical	Group I (NiTi K files)	15	0.7128	2.17,168	-0.4898	1.9154	0.04, S
	Group II (ProTaper next files)	15	0.7839	0.31,988	0.6067	0.9610	Group I, group II < group III < group IV
	Group III (One Shape files)	15	1.0429	0.96,142	0.5104	1.5753	
	Group IV (Wave One file)	15	2.7134	3.50,781	0.7709	4.6560	

Table 3: Intergroup comparison of remaining dentine thickness in apical, middle, and cervical parts of the study samples

Remaining dentine thickness	N	Mean	Std. deviation	95% Confidence interval for mean		P value	Post hoc pairwise comparison
				Lower bound	Upper bound		
Apical	Group I (Ni-Ti K files)	15	0.4827	0.16520	0.3912	0.5742	<0.0001, S
	Group II (ProTaper Next files)	15	0.2087	0.05475	0.1783	0.2390	Group II < group III, group IV < group I
	Group III (One Shape file)	15	0.3553	0.13352	0.2814	0.4293	
	Group IV (Wave One file)	15	0.3007	0.08405	0.2541	0.3472	
Middle	Group I (NiTi K files)	15	0.6333	0.19190	0.5271	0.7396	0.517,
	Group II (ProTaper Next files)	15	2.0133	6.63607	-1.6616	5.6883	NS
	Group III (One Shape file)	15	0.4987	0.18696	0.3951	0.6022	
	Group IV (Wave One file)	15	0.4273	0.12050	0.3606	0.4941	
Cervical	Group I (NiTi K files)	15	0.7987	0.25017	0.6601	0.9372	<0.0001, S
	Group II (ProTaper Next files)	15	0.3880	0.06213	0.3536	0.4224	Group II, group III, group IV, <group I
	Group III (One Shape file)	15	0.6233	0.22398	0.4993	0.7474	
	Group IV (Wave One file)	15	0.5533	0.12344	0.4850	0.6217	

In spite of many superior features the NiTi rotary instruments seem to undergo high high risk of separation. These instruments often lead to improper cleaning of the ribbon-shaped canals of primary teeth because of fatigue and shear stresses.²² To combat this, in the past years, endodontic files having reciprocating motion have been introduced in the dentistry which have lesser cyclic fatigue created due to continuous rotary motion in one direction.⁴ As the clockwise angle was lesser than the counter-clockwise angle, it was asserted that the instrument progressively moved toward the apex of the root canal.⁴

The WO was one of the first NiTi endodontic file system with reciprocating motion being manufactured with M-Wire NiTi alloy. Currently the Wave One single-file system consists of three files of varying lengths 21, 25, and 31 mm.²³ The WO small file (taper 6% tip size 21) is used predominantly in fine canals. The WO primary file (taper 8%, tip size 25) is used in maximum canals while the WO large file (taper 8%, tip size 40) is mainly used in canals which are larger in size.⁸ With reciprocating rotation mode, which turns the instrument in unequal bidirectional movements with less than a circle active movement, the WO instrument generates less stress than does a continuous rotary instrument and therefore has a

longer lifespan, longer fatigue life, and satisfactory shaping and cleaning efficiency.⁵

There are numerous reports in literature advocating the use of WO file systems for permanent teeth but these systems still need to be investigated for their use in the deciduous dentition. Hence the current research have been taken up.

There are several methods like optical microscopy and serial sectional technique evaluating the final outline of root canal preparation. But since there is need to sacrifice the tooth structure even prior to the evaluation and postoperatively; therefore, these methods are not in use very often.²⁴ On the contrary, radiographic evaluation seems to be nondestructive in nature but the evaluation is only two dimensional.²⁴

Recently, CBCT has been employed in dentistry and has been related to medical tomography leading to an increase in accuracy and resolution thereby reducing the time required for image acquisition together with exposure to lesser radiation.²⁴ It allows for safer accurate and consistent assessment of external and internal anatomy of the tooth. Due to its varied advantages, the current study aimed to assess the consistency of radicular preparation by different filing systems by CBCT analysis.²⁴

Table 4: Intergroup comparison of number of cracks in apical, middle, and cervical parts of the study samples

Cracks	N	Mean	Std deviation	95% Confidence interval for mean		P value	Post hoc pairwise Comparison
				Lower bound	Upper bound		
Apical	Group I (Ni-Ti K files)	15	0.33	0.488	0.06	0.60	<0.0001 Group I < group III < group II Group IV < group II
	Group II (ProTaper Next files)	15	2.67	0.724	2.27	3.07	
	Group III (One Shape file)	15	1.13	0.990	0.58	1.68	
	Group IV (Wave One file)	15	0.60	0.632	0.25	0.95	
Middle	Group I (NiTi K files)	15	0.27	0.458	0.01	0.52	<0.0001 Group I, group IV < group II
	Group II (ProTaper Next files)	15	1.27	0.594	0.94	1.60	
	Group III (One Shape file)	15	0.80	0.676	0.43	1.17	
	Group IV (Wave One file)	15	0.33	0.488	0.06	0.60	
Cervical	Group I (NiTi K files)	15	0.07	0.258	-0.08	0.21	<0.0001 Group I, group IV < group II, group III
	Group II (ProTaper Next files)	15	0.93	0.258	0.79	1.08	
	Group III (One Shape file)	15	1.07	0.961	0.53	1.60	
	Group IV (Wave One file)	15	0.13	0.352	-0.06	0.33	

Table 5: Intergroup comparison of instrumentation time (minutes)

Instrumentation time	N	Mean	Std. deviation	95% Confidence interval for mean		
				Lower bound	Upper bound	
Time in minutes	Group I (Ni-Ti K files)	15	9.4107	0.85045	8.9397	9.8816
	Group II (ProTaper Next files)	15	5.8313	1.04413	5.2531	6.4096
	Group III (One Shape file)	15	3.4473	0.58773	3.1219	3.7728
	Group IV (Wave One file)	15	1.8313	0.42487	1.5960	2.0666
P ^a value		<0.0001, S				
Post hoc pairwise comparison		Group I < group II < group III < group IV				

^a One way ANOVA, ^bTukey's test.

The results of the present study when comparing CT in three levels (cervical, middle, and apical), revealed that PTN file system showed least CT followed in ascending order by NiTi K files, WO file system, and OS file system, respectively. In accordance to our study, Cui et al.²⁵ also suggested that the PTN file system caused less transportation than the WO file system in narrow and dilacerated curved root canals while Dhingra et al.⁸ concluded that PTN exhibited more centered preparation with negligible transportation. Zhao et al. (2014)²⁶ attributed the reason of less canal transportation by PTN file system to its taper of 0.04 that helps in the initial enlargement of the apical portion of the canal, reducing the bending and stress on the main file. Elnaghy and Elsaka²⁷ and Jain et al.²⁸ emphasized on the longer diameter of these files predisposing it to resist deformation forces. The lowest value of CT was seen in apical level attributing to the fact that more calcified dentine was present in permanent teeth which gives more resistance while shaping the canal. However, primary teeth are always in a dynamic stage of resorption which in turn results in softer dentin at apex; therefore, achieving equal shaping of canal leading to less transportation.²⁹

The results of the present study when comparing CAR (ability to stay centered in canal) revealed that OS file system showed best CAR followed in descending order by PTN files, NiTi K files, and WO file system, respectively. Similar to results of our study, Ba-Hattab and Pahncke³⁰ observed that OS file systems were better centered compared to WO systems. They attributed this

result to the instrument design and alloy from which the WO files are manufactured. Since OS instruments have lesser cross-section and lesser taper than WO files they showed better centering ability as minimal amount of the residual core improved instrument flexibility.³⁰ Rashid and Saleh³¹ in a study stated that OS file system resulted in minimum changes in the original curvature of the canals, attributing this result to the instrument taper being the predominant factor affecting the shaping capability of the files. OS files have taper of 0.06, whereas WO have 0.08 taper along the initial 3 mm from the tip of the files, which reduces their flexibility in comparison to various files having similar tip size.³¹ Results of the present study also showed better Centering Ability by PTN files in comparison to NiTi K files and WO file system in the cervical level of study samples. This result is in accordance to Dhingra et al.⁸ who also found PTN files showing better CAR. Authors attributed this result to PTN files' modified tip design and its brushing motion away from concavities which facilitate flute unloading and apical file progression ultimately leading to more centered root canal preparations.

On comparing RDT in three levels (cervical, middle, and apical), results of the present study revealed that NiTi K files showed greater RDT followed in descending order by OS, WO, and PTN files, respectively. NiTi K files preserving greater dentin than other file systems could be attributed to the super-elastic nature of NiTi K files along with their shape memory minimizing the straightening effect and preserving more dentin. In accordance to our study Nagaraja and Murthy³² concluded that progressive taper in the design and

rectangular cross-section of the PTN files could have led to more dentin cutting than NiTi K files. Ahquist et al. (2001).³³ inferred superior efficacy of NiTi K files in preserving RDT along the entire root canal length in root canals of permanent teeth.

Results of the present study revealed minimum cracks with hand NiTi K files followed by WO file system, PTN files, and OS file system in ascending order, respectively. This is in accordance to Langaliya et al.³⁴ who similarly concluded that hand NiTi files showed no cracks followed by WO and PTN files. According to them hand instruments did not result in inadvertent removal or radicular dentin due to its controlled movements inside the canal as compared to engine-operated files. Authors also deduced that, WO files created lesser cracks as it works with single file system compared to multiple rotary file system. Additionally, WO files are manufactured with M-wire which happens to be more flexible variant of the NiTi alloy and works in reciprocation which is based on the fundamentals of balanced force technique.³⁵ Result of our study also revealed that PTN files showed greater cracks formation in comparison to NiTi K files and WO file system. This might be attributed to the high number of rotations associated with more number of files, progressively increasing taper, smaller pitch, and cross-section design all of which removes relatively more dentin compared to other systems.

The comparison of instrumentation time of all four filing systems revealed that mean instrumentation time taken by WO files was least followed in ascending order by OS, PTN, and NiTi K file systems, respectively. Decreased instrumentation time with WO files could be attributed to the fact that reciprocal files are able to avoid overcutting of the dentin and are able to prepare the canals up to the working length faster as compared to the conventional rotary files same was theorized by Prabhakar et al.⁴ Katge et al.¹ too concluded that WO files resulted in lesser time for root canal preparation as compared to ProTaper and K-files. Rao et al.³⁵ concluded lesser instrumentation time with PTN files as these rotary files are engine driven with higher cutting efficiency compared to manual K files. In accordance with result of the current study Azar et al.³⁶ also concluded that rotary files resulted in shorter instrumentation time as compared to K files in deciduous teeth and suggested it could be attributed to the reduced root length of primary teeth, lower resistance of dentin toward the cutting instruments, and use of fewer files.

Results of the present study showed that CBCT scanning is an efficient tool to evaluate the accuracy of root canal instrumentation techniques. Assessment of CT, centering ability, RDT and dentin cracks have been studied with several methodologies, but CBCT remains the most commonly employed method at the present time since it does not involve any damage to the specimen and is standardized. It allows the operator to capture multiple images throughout the process of biomechanical preparation, thereby providing accurate information of the root canal at various stages. Pediatric dentists often face challenges during pulpectomy procedures because of the complex morphology of the primary root canals. Thereby our study was conducted to establish a simplified procedure for preparing primary root canals by reducing the time of instrumentation and number of files to be used.

CONCLUSION

Considering the limitations of this study, it can be concluded that PTN files resulted in least canal transportation the best centering

ability and was shown by OneShape file system. The NiTi K hand files preserved maximum RDT and produced minimum dentin cracks making samples more resistant to vertical fracture. Additionally, WO file system took least instrumentation time when compared to the other three filing systems.

There is a lack of literature regarding the efficiency of any given type of the files for preparation of root canals of the primary teeth hence further research is warranted to evaluate the advantages of various rotary and reciprocating filing systems in deciduous teeth *in vivo*.

CLINICAL SIGNIFICANCE

Instrumentation of root canals during pulpectomy procedures in primary teeth using rotary instruments proves to be a promising technique being advantageous for the pediatric patients by maintaining the original canal curvatures, showing greater ability to maintain dentin thickness, causing lesser dentin cracks, and reducing chair time thus favoring preparation of more conical root canals and better obturation.

REFERENCES

1. Katge F, Patil D, Poojari M, et al. Comparison of instrumentation time and cleaning efficacy of manual instrumentation, rotary systems and reciprocating systems in primary teeth: an in vitro study. *J Indian Soc Pedod Prev Dent* 2014;32(4):311–315. DOI: 10.4103/0970-4388.140957
2. Tambe VH, Nagmode PS, Abraham S, et al. Comparison of canal transportation and centering ability of rotary protaper, one shape system and wave one system using cone beam computed tomography: An in vitro study. *J Conserv Dent* 2014;17(2):561–565. DOI: 10.4103/0972-0707.144605
3. Schafer E. Shaping ability of Hero 642 rotary nickel-titanium instruments and stainless steel hand K-Flexofiles in stimulated root canals. *Oral Surg. Oral Med. Oral Pathol. Oral Radiol Endod* 2001;92:215–220. DOI: 10.1067/moe.2001.114622
4. Prabhakar AR, Yavagal C, Dixit K, et al. Reciprocating vs rotary instrumentation in pediatric endodontics: cone beam computed tomographic analysis of deciduous root canals using two single-file systems. *Int J Clin Pediatr Dent* 2016;9(1):45–49. DOI: 10.5005/jp-journals-10005-1332
5. Pham KV, Phan TN. Evaluation of root canal preparation using two nickel–titanium instrument systems via cone-beam computed tomography. *Saudi Endod J* 2019;9:210–215. DOI: 10.4103/sej.sej_147_18
6. Dagna A, Poggio C, Beltrami R, et al. Cyclic fatigue resistance of one shape, reciproc, and wave one: an in vitro comparative study. *J Conserv Dent* 2014;17(2):250–254. DOI: 10.4103/0972-0707.131788
7. Freire LG, Gavini G, Branco-Barletta F, et al. Microscopic computerized tomographic evaluation of root canal transportation prepared with twisted or ground nickel-titanium rotary instruments. *Oral Surg Oral Med Oral Pathol Oral Radiol Endod* 2011;112(6):e143–e148. DOI: 10.1016/j.tripleo.2011.06.029
8. Dhingra A, Kochar R, Banerjee S, et al. Comparative evaluation of the canal curvature modifications after instrumentation with One Shape rotary and Wave One reciprocating files. *J Conserv Dent* 2014;17(2):138–141. DOI: 10.4103/0972-0707.128049
9. Elnagar MH, Ghoname NA, Ghoneim WM. Cleaning efficacy of rotary versus manual system for root canal preparation in primary teeth. *Tanta Dent J* 2018;15(1):14–19. DOI: 10.4103/tj.tj_43_17
10. Gambill JM, Alder M, Rio CE. Comparison of nickel-titanium and stainless steel hand-file instrumentation using computed tomography. *J Endodent* 1996;22(7):369–375. DOI: 10.1016/S0099-2399(96)80221-4375.

11. Priya TN, Chandrasekhar V, Anita S, et al. "Dentinal microcracks after root canal preparation" a comparative evaluation with hand, rotary and reciprocating instrumentation. *J Clin Diag Res* 2014;8(12):ZC70–ZC77. DOI: 10.7860/JCDR/2014/11437.5349
12. Pinheiro SL, Araujo G, Bincelli I, et al. Evaluation of cleaning capacity and instrumentation time of manual, Hybrid and rotary instrumentation techniques in primary molars. *Int Endod J* 2012;45(4):379–385. DOI: 10.1111/j.1365-2591.2011.01987.x
13. Nagaratna PJ, Shashikiran ND, Subbareddy VV. In vitro comparison of NiTi rotary instruments and stainless steel hand instruments in root canal preparations of primary and permanent molar. *J Indian Soc Pedod Prev Dent* 2006;24(4):186–191. DOI:10.4103/0970-4388.28075
14. Musani I, Goyal V, Singh A, et al. Evaluation and comparison of biological cleaning efficacy of two endofiles and irrigants as judged by microbial quantification in primary teeth - an in vivo study. *Int J Clin Pediatr Dent*, September-December 2009;2(3):15-22. DOI: 10.5005/jp-journals-10005-1013
15. Walton RE. Histologic evaluation of different methods of enlarging the pulp canal space. *J Endod* 1976;2(10):304–311. DOI: 10.1016/S0099-2399(76)80045-3
16. Barr ES, Kleier DJ, Barr NV. Use of nickel-titanium rotary files for root canal preparation in primary teeth. *Pediatr Dent* 2000;22(1):77–78.
17. Berutti E, Paolino DS, Chiandussi G, et al. Root canal anatomy preservation of WaveOne reciprocating files with or without glide path. *J Endod* 2012;38(1):101–104. DOI: 10.1016/j.joen.2011.09.030
18. KuhnWG, David L. Effect of tip design of Ni-Ti and stainless files on root canal preparation. *J Endod* 1997;23(5):735–738. DOI: 10.1016/S0099-2399(97)80345-7
19. Brasil SC, Marilia F, Alves M, et al. Canal transportation, unprepared areas, and dentin removal after preparation with BT-RaCe and ProTaper next systems. *J Endod* 2017;43(10):1–8. DOI: 10.1016/j.joen.2017.04.012
20. Pansheriya E, Goel M, Gupta KD, et al. Comparative evaluation of apical transportation and canal centric ability in apical region of newer nickel-titanium file systems using cone-beam computed tomography on extracted molars: an in vitro study. *Contem Clin Dent* 2018;9:215–220. DOI: 10.4103/ccd.ccd_17_18
21. Celikten B, Uzuntas CF, Kursun S, et al. Comparative evaluation of shaping ability of two nickel-titanium rotary systems using cone beam computed tomography. *BMC Oral Health* 2015;15(5):32–39. DOI 10.1186/s12903-015-0019-5
22. Drukteinis S, Balciuniene I. A scanning electron microscopic study of debris and smear layer remaining following use of AET instruments and K-flexofiles. *Stomatologija* 2006;8:70–75.
23. Sharma P, Goel M, Verma S, et al. Entering a new era in endodontics with revolutionary single file systems: a comprehensive review. *EC Dent Sci* 2016;5(3):1100–1122. DOI: <http://dx.doi.org/10.15562/jdmfs.v3i3.746>
24. Simon S, Lumley P, Tomson P, et al. Protaper – hybrid technique. *Dent Update* 2008;35:110–116. DOI: 10.12968/denu.2008.35.2.110
25. Cui Z, Wei Z, Du M, Yan P, et al. Shaping ability of pro taper next compared with wave one in late-model three-dimensional printed teeth. *BMC Oral Health* 2018;18(4):115–120. DOI: 10.1186/s12903-018-0573-8
26. Zhao D, Shen Y, Peng B, et al. Micro-computed tomography evaluation of the preparation of mesiobuccal root canals in maxillary first molars with Hyflex CM, Twisted Files, and K3 instruments. *J Endod* 2013;39(3):385–358. DOI: 10.1016/j.joen.2012.11.030
27. Elnaghy A, Elsaka S. Cyclic fatigue resistance of XP-endo Shaper compared with different nickel-titanium alloy instruments. *Clin Oral Invest* 2018;22(3):1433–1437. DOI: 10.1007/s00784-017-2245-5
28. Jain A, Asrani H, Singhal AC, et al. Comparative evaluation of canal transportation, centering ability, and remaining dentin thickness between Wave One and ProTaper rotary by using cone beam computed tomography: an in vitro study. *J Conserv Dent* 2016;19(1):440–444. DOI: 10.4103/0972-0707.190024
29. Shaikh SM, Goswami M. Evaluation of the effect of different root canal preparation techniques in primary teeth using CBCT. *J Clin Pediatr Dent* 2018;42(4):250–255. DOI: 10.17796/1053-4628-42.4.2
30. Ba-Hattab RA, Pahncke D. Shaping ability of superelastic and controlled memory nickel-titanium file systems: an in vitro study. *Int J Dent* 2018;2018: 1–5. DOI: 10.1155/2018/6050234
31. Rashid A, Saleh AR. Shaping ability of different endodontic single-file systems using simulated resin blocks. *Indian J Multidiscip Dent* 2016;6(2):61–65. DOI:10.4103/2229-6360.197745
32. Nagaraja S, Murthy BVS. CT evaluation of canal preparation using rotary and hand Ni-Ti instruments: an in vitro study. *J Conserv Dent* 2010; 13(1): 16-22. DOI: 10.4103/0972-0707.62636
33. Ahlquist M, Henningsson O, Hultemby K, et al. The effectiveness of manual and rotary techniques in the cleaning of root canals: a scanning electron microscopy study. *Int Endod J* 2001; 34:533–537. DOI: 10.1046/j.1365-2591.2001.00429.x
34. Langaliya AK, Kothari AK, Surti NR, et al. In vitro comparative evaluation of dentinal microcracks formation during root canal preparation by different nickel-titanium file systems. *Saudi Endod J* 2018;8(3):183–188. DOI: 10.4103/sej.sej_23_17
35. Rao A, Pandya D, Roy S, et al. Comparison of Instrumentation time and cleaning efficacy of manual k-file, rotary protaper universal and rotary protaper next in primary anterior teeth: an in vitro study. *Int J Sci Res* 2018;7(1): 27–30. DOI: 10.36106/IJSR
36. Azar MR, Safi L, Nikaiein A. Comparison of the cleaning capacity of Mtwo and ProTaper rotary systems and manual instruments in primary teeth. *Dent Res J* 2012;9(2):146–151. DOI: 10.4103/1735-3327.95227