

Topical tretinoin for treating photoaging: A systematic review of randomized controlled trials

Irma Bernadette S. Sitohang, MD, PhD^{a,*}, Wresti Indriatmi Makes, MD, PhD^a, Normalina Sandora, MD, PhD^b, Jose Suryanegara, MD^c

ABSTRACT

Background: Aging, an inevitable and continuous process in one's lifetime, has all along been a focus of interest, especially for women, yet photoaging treatment to slow the process remains challenging. Recent studies have demonstrated the potency of topical tretinoin in the treatment of photoaging. Tretinoin, a metabolite of retinoids, shows prominent efficacy to regulate proliferation and differentiation of epidermal cells and induce new collagen formation.

Objective: This review aims to study the current evidence on topical tretinoin for photoaging treatment.

Methods: A systematic search of the literature was performed from Medline, Cochrane Central, Embase, and PubMed databases for published articles in the past 20 years. Only randomized controlled trials investigating tretinoin for photoaging treatment were included in our review.

Results: A total of 180 studies were initially examined, of which 7 randomized controlled trials were included in this review. Four studies included only women as their participants, while the rest demonstrated women as their majority subjects. All studies that indicated topical tretinoin were safe and well tolerated in all patients. Topical tretinoin dosage varied from 0.025% to 5% while duration of treatment ranged from 3 months up to 24 months. With regard to efficacy, all studies consistently reported that topical tretinoin was efficacious in improving clinical appearance of photoaging in terms of wrinkling, mottled hyperpigmentation, sallowness, and lentigines as early as 1 month and lasted after 24 months.

Limitations: Different tretinoin formulas used, different outcome parameters, and limited recent studies on topical tretinoin cause lack of uniformity in the evidences.

Conclusion: Topical tretinoin is a safe and effective therapeutic modality for long-term treatment of photoaging. Further research is required to compare dose-ranging topical tretinoin to other agents to provide the best treatment strategy for photoaged skin.

Keywords: Photoaging, treatment, tretinoin

Introduction

Aging is a major concern in today's society, and studies about the prevention of aging have received special attention for many years. As the largest organ in the human body, skin shows prominent and visible signs of aging. Therefore, a younger-looking skin is always desirable and positively influences social behavior and psychological state, especially among women.^{1,2} Both intrinsic and extrinsic factors induce skin aging. Intrinsic aging is an inevitable process due to internal factors such as genetics. Environmental factors generate extrinsic aging, most notably exposure to solar ultraviolet (UV), referred to as photoaging.²⁻⁴

Photoaging indicates the effect of prolonged exposure to UV, which results in premature aging of the skin. Both UV A and UV B have been implicated in photoaging process. UV B causes DNA damage and photocarcinogenesis, sunburn, and immunosuppression. On the other hand, UV A radiation is responsible for damage to the dermal extracellular matrix and blood vessels as it can penetrate into deeper layer of the skin compared with UV B.⁵ UV A induces transcription factor activator protein 1 that upregulates matrix metalloproteinase (MMP), degrades dermal collagen, and decreases procollagen gene expression of the dermis. UV A also induces nuclear factor kappa-light-chain-enhancer of activated B cell expression that triggers collagen breakdown and inhibits its synthesis.⁶ After repeated UV exposure, collagen degradation and attenuation of its formation accumulate and result in clinical features of photoaging.^{5,7} The typical clinical features of skin aging are dyspigmentation, laxity, wrinkles, leathery appearance, and cutaneous malignancies.⁸ Regarding gender differences, women exhibit a greater risk of wrinkle than men, while pigmentary changes are more prominent in men.⁹

Retinoids have been widely used as dermatological agents for treatment of acne and photoaging. Tretinoin, a metabolite of retinoids, has proved to be beneficial for photoaging in a large number of clinical studies for more than 10 years.^{10,11} Tretinoin has shown the ability to regulate proliferation and differentiation of epidermal cells, induce formation of new collagen, prevent collagen loss, and block induction of MMP. Furthermore, tretinoin may reduce the epidermal melanin and pigmentation by upregulating keratinocyte turnover and reducing tyrosinase activity.¹² The use of tretinoin in photoaging was first conducted by Kligman et al.¹³ with the application of tretinoin 0.05% on photoaged face and forearm for 3–12 months. This study found deposition of reticulin fibers, uniform dispersion of melanin, and new dermal collagen

^a Department of Dermatology and Venereology, Faculty of Medicine, Universitas Indonesia, Dr. Cipto Mangunkusumo Hospital, Jakarta, Indonesia

^b Human Reproduction, Infertility and Family Planning, Indonesia Medical Education and Research Institute, Jakarta, Indonesia

^c Faculty of Medicine, Universitas Indonesia, Dr. Cipto Mangunkusumo Hospital, Jakarta, Indonesia

*Corresponding author. E-mail address: irma_bernadette@yahoo.com (I.B.S. Sitohang).

Copyright © 2022 The Authors. Published by Wolters Kluwer Health, Inc. on behalf of Women's Dermatologic Society. This is an open access article distributed under the Creative Commons Attribution-NoDerivatives License 4.0, which allows for redistribution, commercial and non-commercial, as long as it is passed along unchanged and in whole, with credit to the author.

International Journal of Women's Dermatology (2022) 8:e003

Received: 10 June 2021; Accepted 12 October 2021

Published online 25 March 2022

DOI: 10.1097/JW9.000000000000003

What is known about this subject in regard to women and their families?

- Photoaging refers to the effect of prolonged exposure to ultraviolet, resulting in premature skin aging, which is a common concern among women.
- Tretinoin has been widely used as a dermatological agent for treatment of acne and photoaging.
- Tretinoin, a derivative of vitamin A, shows prominent efficacy in regulating the proliferation and differentiation of epidermal cells and inducing new collagen formation.

What is new from this article as messages for women and their families?

- All clinical signs of photodamage, except for tactile roughness, showed dramatic improvement after topical tretinoin treatment.
- The improvement was significant after 4 months and continued over a 24-month period. Treatment with tretinoin was associated with an acceptable safety profile even at high-dose concentrations.
- Almost all of the study subjects were women, suggesting that topical tretinoin is effective and suitable for treating photoaging in women.

and blood vessel formation. Since then, many studies have investigated the efficacy of topical tretinoin for treating photoaging.¹² Thus, this systematic review aims to synthesize the current evidence on topical tretinoin for treating photoaging.

Methods

Our methodology and reporting process followed the recommendations from the Preferred Reporting Items for Systematic Reviews and Meta-Analyses. A comprehensive search of articles was performed on November 5, 2020, from Medline, Cochrane Central, Embase, and PubMed databases for published articles during the past 20 years, from January 1, 2000, to November 5, 2020. The MeSH search headings included (“Tretinoin” OR “all trans retinoic acid” OR “ATRA”) AND (“Photoaging” or “photoaging” or “Aging” or “photoaged skin” OR “photodamage”). Only studies written in English were included in this systematic review. A manual review of citations from these articles was also performed to identify any potential missed studies.

Initially, selected articles from 4 databases were screened for duplicates and screened according to the titles and abstracts. The inclusion criteria are: (1) full-text and English-based articles; (2) tretinoin used in various dosages, vehicles, and application methods as the determining variable for photoaging treatment, (3) randomized controlled trials; (4) participants 20 years old or older regardless of gender and ethnic group, with a minimum of moderate photodamaged skin, and without additional photoaging medication except sunscreen. Disagreements among reviewers were discussed to reach a consensus.

Data from selected articles were extracted and analyzed by 2 reviewers (I.B.S.S., J.S.) (Table 1) and were double-checked by 2 independent reviewers (W.I.M., N.S.). The extracted data were publication details, study design, participants, the intervention, and the results. The collected data for the primary outcomes were clinical and histological improvements according to clinicians' observations and patients' responses. The safety and adverse events associated with the intervention were also collected as secondary data. Bias was assessed by evaluating the blinding procedure, exclusion criteria, and withdrawal of the participants.

Results

The flow chart in Figure 1 demonstrates the selection method used in this study. A literature search from 4 databases

resulted in 178 articles, and 2 references were added from the citation list. Sixty articles were excluded due to duplicate, and through screening of titles and abstracts, we excluded 99 ineligible articles. Fourteen articles were further excluded because they did not meet the inclusion criteria. Finally, 7 articles were chosen to be critically appraised by the reviewers (I.B.S.S., W.I.M., N.S.).

Protocol

Among the 7 randomized controlled trials, 3 were multicenter studies,^{10,15,17} and the rest were single-center studies.^{14,16,18,19} Most studies used a double-blinded evaluation by blinding patients and assessors. Sample sizes varied with a total of 739 subjects and 113 dropouts. Four studies included only women subjects. The other 3 studies included both genders, although majority were women, being up to 80%. Regarding treatment protocol, the concentration of tretinoin varied from 0.025% to 0.1%. Only 1 study used tretinoin 5% as a peeling agent.¹⁶ The vehicle used in 6 studies was cream or emollient cream, and only 1 study used microsphere gel.¹⁴ Duration of treatment ranged from 3 months up to 24 months, while the period for follow-up after treatment varied from 84 days to 24 months. Two studies investigated tretinoin in comparison to placebo,^{14,15} 1 study compared the effects of different dosages of tretinoin,¹⁶ and 4 studies compared tretinoin to other topical agents, such as tazarotene, adapalene, and retinol.^{10,17-19} Methodological data are summarized in Table 1.

Measurement of efficacy

Data from most studies presented clinicians' assessment of photodamage severity, wrinkle, dyspigmentation, tactile roughness, and lentigines. All subjective outcomes were scored as an absolute quantification using scales, which were the 10-point scale,¹⁴ Griffiths scale,¹⁰ and Guimaraes scale.¹⁶ Data of the subject's self-assessment were collected in various parameters and any adverse events related to the interventions were noted.

Efficacy

All studies indicated positive effects of topical tretinoin to reduce photoaging damages. Application of tretinoin 0.1% microsphere gel significantly improved overall photodamage severity after 6 months, compared with placebo.¹⁴ All clinical signs of photodamage improved remarkably, except for tactile roughness.¹⁴ Further observation after 24 months showed significant reduction in wrinkle and mottled hyperpigmentation; however, tactile roughness persisted. These changes were identified after 4 months of treatment and persisted until 24 months of intervention.¹⁵ Another study comparing tretinoin 0.05% cream versus tretinoin 5% peel indicated that the mean photoaging score had reduced by 20%, showing no difference according to the Guimaraes scale. Histologically, application of tretinoin 0.05% showed a reduction in corneal thickness while tretinoin 5% resulted in an increased corneal thickness.¹⁶ Another study reported that tazarotene 0.1% exceeded tretinoin 0.05% in fine wrinkles and mottled hyperpigmentation, with treatment success up to 50% of global improvement.¹⁷ Draelos¹⁸ also indicated that applying 4% hydroquinone/0.3% retinol cream after 16 weeks reduced dyspigmentation, fine wrinkles, and tactile roughness better than tretinoin 0.05% cream. Meanwhile, adapalene 0.3% gel had no difference compared to tretinoin 0.05% in global cutaneous photoaging, periorbital wrinkles, melanosin, forehead wrinkles, and actinic keratosis.¹⁰ This result is in line with the trial by Bouloc et al.¹⁹ that compared the efficacy of retinol/LR2412 with tretinoin 0.025%.

Table 1.
Summary of articles

No	Author	Year	Study design	Patients	Dropouts	Intervention	Comparison	Duration of treatment	Follow-up	Evaluation of the treatment	AEs
1	Weiss et al. ¹⁴	2006	Single-center, double-blind, RCT	45	5	TMG 0.1% once daily	Placebo	6 mo	At baseline and 1, 2, 4, 6, 9, and 12 mo	TMG 0.1% was more effective than placebo in improving photodamaged skin	Most signs and symptoms of cutaneous irritation were rated mild in intensity. Tretinoin group was statistically significant only for peeling and dryness. Cutaneous irritation was greater in tretinoin group.
2	Kang et al. ¹⁵	2005	Multicenter, double-blind, RCT	205	45	Tretinoin emollient cream 0.05%	Placebo (vehicle emollient cream)	24 mo	At 1, 2, 4, 6, 9, 12, 15, 18, 21, and 24 mo	Long-term treatment with tretinoin emollient cream 0.05% was effective in subjects with moderate to severe facial photodamage	Most common AEs: erythema, peeling, itching, burning, and dryness. Good tolerability for both regimens. Pruritus and erythema were reported by the subjects but neither led to treatment discontinuation.
3	Sumita et al. ¹⁶	2018	Single-center, evaluator-blind, RCT	24	1	0.05% tretinoin cream 3 alternate nights a week for 24 wk	5% tretinoin 8 sequential applications as peeling, every 2 wk	24 wk	At baseline, 1 and 6 mo	Tretinoin as a cream 0.05% or peeling (5%) was effective for treatment of moderate photoaging and forearm field cancerization	No significant difference in AEs between groups. Most common: burning sensation, erythema, peeling, pruritus, and dryness. Both products were comparable in terms of cosmetic acceptability and tolerability. Tazarotene was associated with a higher incidence of a burning sensation.
4	Bagatin et al. ¹⁰	2018	Multicenter, investigator-blind, RCT	128	14	Adapalene 0.3% gel once daily	Tretinoin 0.05% cream once daily	24 wk	At 1, 4, 8, 12, 16, 20, and 24 wk	Adapalene 0.3% gel showed noninferior efficacy to tretinoin 0.05% cream as treatment for photoaged skin	Both products were comparable in terms of cosmetic acceptability and tolerability. Tazarotene was associated with a higher incidence of a burning sensation.
5	Lowe et al. ¹⁷	2004	Multicenter, double-blind, RCT	173	16	Tazarotene 0.1% cream once daily	Tretinoin 0.05% emollient cream once daily	24 wk	At 2, 4, 8, 12, 16, 20, and 24 wk	Tazarotene 0.1% cream offered superior efficacy over tretinoin 0.05% emollient cream in the treatment of facial photodamage, particularly with respect to the speed of improvement	Erythema and dryness/scaling were more significant in tretinoin group.
6	Draeos ¹⁸	2005	Single-center, double-blind, RCT	44	12	4% hydroquinone and retinol 0.3% cream	Tretinoin 0.05% emollient cream once daily	16 wk	At baseline, 4, 8, 12, and 16 wk	The hydroquinone/tretinoin treatment was superior in terms of tactile roughness, fine lines, and hyperpigmentation compared with tretinoin treatment	Adverse effects were mostly graded mild. Retinol 0.2%/LR2412 2% cream was better tolerated than tretinoin 0.025% cream.
7	Bouloc et al. ¹⁹	2015	Single-center, double-blind, RCT	120	20	Retinol 0.2%/LR2412 2% cream	Tretinoin 0.025% cream	3 mo	At 0, 28, 56, and 84 d	The outcome of retinol 0.2%/LR2412 2% cream does not differ from tretinoin 0.025% cream	

AE, adverse event; d, days; mo, months; RCT, randomized controlled trial; TMG, tretinoin microsphere gel; wk, weeks.

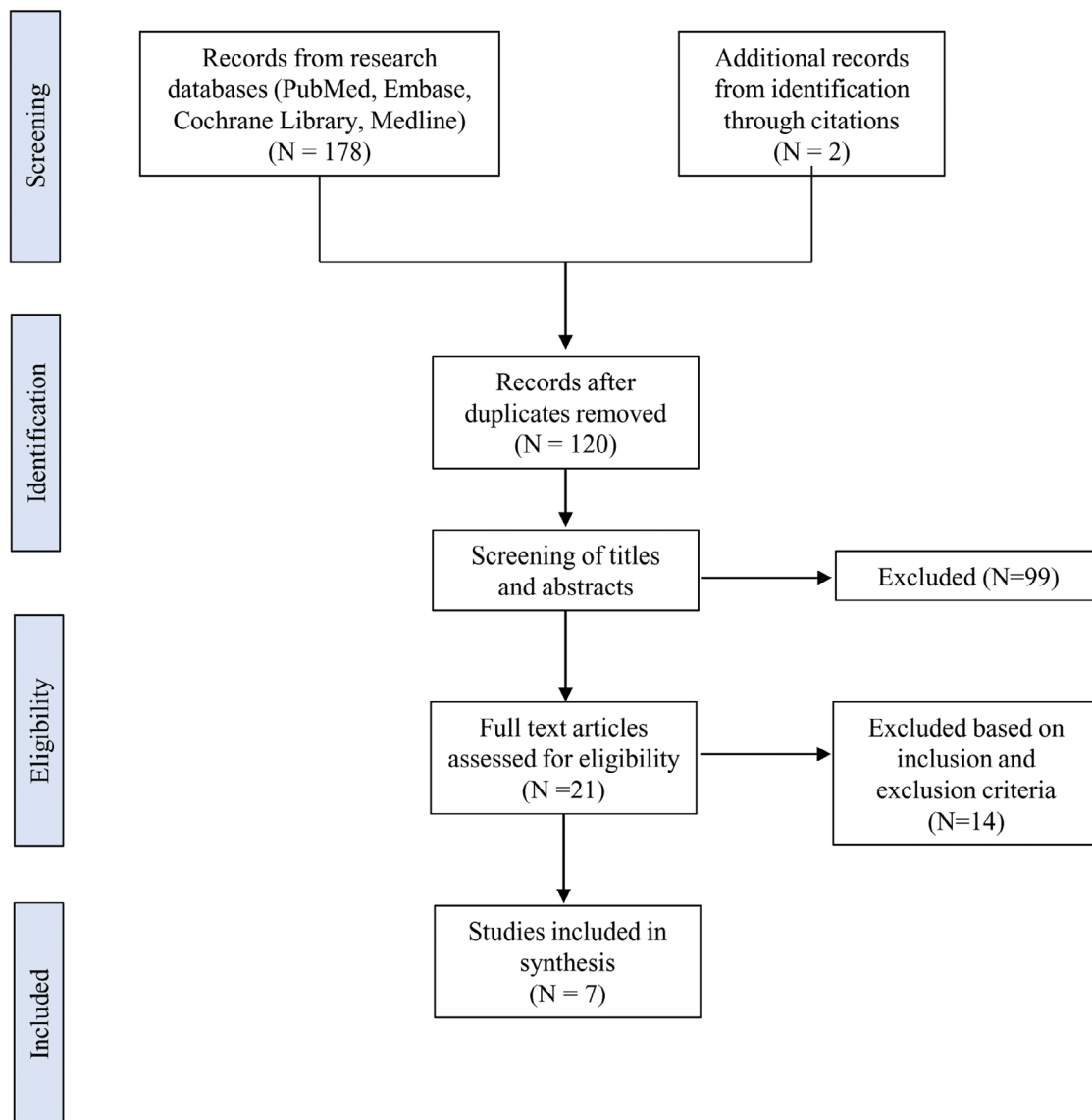


Fig. 1. Flow chart of data extraction.

Patient satisfaction

Tretinoin resulted in better patient satisfaction as compared to placebo, in terms of overall appearance and feels of the skin,¹⁴ and fine wrinkles.¹⁵ Nonetheless, tretinoin showed no difference as compared to adapalene 0.3% or tazarotene 0.1% in causing significant improvements.^{10,17} Only retinol/LR2412 was superior to tretinoin, as patients reported smooth and supple sensation of the skin, and reduced skin dyspigmentation and pores.¹⁹

Adverse events

The most commonly reported adverse events after tretinoin intervention were erythema, peeling, itching, burning/stinging, and dryness. However, the proportion of subjects who withdrew from the studies due to side effects was relatively small even after 24 months of intervention.¹⁵ Comparing adapalene 0.3% with tretinoin, the incidence of adverse events was similar between both groups.¹⁰ Moreover, the incidence of burning was greater in tazarotene group compared with tretinoin 0.5%.¹⁷ In contrast, retinol 0.2%/LR2412 and 4% hydroquinone/0.3% were better tolerated compared with topical tretinoin.¹⁹

Discussion

Skin photoaging due to repeated exposure to UV light manifests as fine and coarse wrinkles, skin roughness, mottled hyperpigmentation, lentigines, and sallowness.²⁰⁻²³ At an advanced stage, it may progress into actinic keratosis and skin cancer.⁷ Various ingredients are currently available to address each of the clinical signs; however, formulation challenges still exist. This systematic review evaluated the use of tretinoin, which has been used for many years and is approved for the treatment of acne and photodamaged skin.^{11,12,24,25}

All included studies showed positive effects of tretinoin in improving the clinical appearance of photoaging. Most studies found monotherapy of topical tretinoin could significantly improve wrinkling, mottled hyperpigmentation, sallowness, and lentigines,^{10,14,15,17-19} while 2 studies indicated no improvement of tactile roughness compared with placebo.^{14,15} Many publications have described the mechanism of tretinoin in improving fine and coarse wrinkles.²⁶⁻²⁸ Tretinoin counteracts the destruction of collagen and elastic fibers by inhibiting the regulation of MMPs. It also induces MRC2 and prolydase to increase collagen-1 recycling.²⁹ In the study by Kang et al.,¹⁵ subjects treated with topical tretinoin showed a significant increase in immunohistologic

indicators of procollagen synthesis. As a result, this leads to restoration of dermal matrix, improved wrinkling, and skin laxity.²⁶ Moreover, majority of the articles found a vital role of tretinoin in improving UV-induced dyspigmentation.^{10,14,15,17-19} A study by Bagatin et al.¹⁰ on 128 subjects demonstrated that 71.9% of subjects showed improvement of melanosis after 24-week application of tretinoin 0.05% cream. Tretinoin has been shown to improve dyspigmentation by inhibiting tyrosinase, reducing melanosome transfer, and increasing the shedding of melanin-containing keratinocytes.²⁶ However, in terms of hyperpigmentation, the study by Draeos¹⁸ found that 4% hydroquinone/retinol 0.3% cream was superior to tretinoin emollient in overall Melasma Area and Severity Index score and clinical evaluation of mottled hyperpigmentation. The potential ability of hydroquinone to reduce melanocyte pigmentation production may give advantage to this combination, while tretinoin primarily decreases melanosome transfer.¹⁸ In addition, the application of tretinoin can also facilitate improved penetration of hydroquinone.¹²

In our reviewed articles, the dosage of topical tretinoin varied from 0.025% to 0.1%. The application of tretinoin with these dosages has demonstrated significant improvements in clinical signs of photoaging. A previous study has mentioned that topical tretinoin produces dose-dependent improvement in the epidermis, including stratum corneum compaction, increased epidermal thickness, and decreased melanin content.³⁰ A clinical study by Darlenski et al.²⁶ found that tretinoin 0.02% cream effectively treated photoaging with fewer side effects compared with higher strength. In contrast, tretinoin 0.01% showed no improvement in photoaging. The beneficial clinical effects after tretinoin application are often seen over a long period of time. To address this drawback, many studies evaluated application of high-strength topical tretinoin.³¹⁻³⁵ In one of the articles, tretinoin 0.05% was compared with tretinoin 5% as a peeling agent. The tretinoin 0.05% was superior in improving aging parameters, while tretinoin 5% was effective in stabilizing field cancerization. However, treatments were applied on the forearms, and the frequency of application was different for each treatment.¹⁶ Kligman et al.³³ investigated the potency of high-strength tretinoin (0.25% tretinoin). After only 4–6 weeks of therapy, there were improvements in mottled hyperpigmentation, fine wrinkles, elasticity, hydration, and collagen deposition. These results were comparable to those observed after 6–12 months of tretinoin 0.05% therapy. Interestingly, all patients could tolerate high-strength tretinoin treatment.³³ However, this study was conducted with a small sample size, and comparison with other tretinoin dosages was not investigated.

The duration of treatment for photoaging using topical tretinoin has always been challenging. Kang et al.¹⁵ found that improvement could be observed as early as 1 month for coarse wrinkles. Shukuwa et al.³⁶ also showed that compaction of stratum corneum and disappearance of atypia and dysplasia occurred after only 1-month application of tretinoin. A histological study carried out by Cuce et al.³¹ using high-strength tretinoin found compaction of stratum corneum and increased epidermal thickness after just 15 days of treatment. However, it was found that skin condition continued to improve over time even after cessation of treatment. Many studies on the longer duration of tretinoin treatment were conducted.¹¹ Three articles studied 6-month treatment periods.^{10,17,18} One of our included studies investigated a 24-month observation of long-term efficacy of tretinoin 0.05% therapy. Kang et al.¹⁵ found significant clinical improvement in clinical signs of photoaging and the investigator's global assessment compared with baseline. Histological study revealed increased levels of procollagen formation following long-term treatment with tretinoin cream.¹⁵ Moreover, a long-term tretinoin study by Bhawan et al.³⁰ found that after 6 months of treatment, there were improvements in the epidermis of photoaged skin, including increased epidermal thickness, increased granular layer thickness, decreased melanin content, and stratum corneum compaction. Interestingly, after 12 months, all of these changes returned to baseline levels,

despite continuous clinical benefits of skin roughness and fine wrinkles. After 48 weeks of treatment, a decrease in epidermal melanin content was noted, which may explain the improvement in dyspigmentation.³⁰

Based on our literature findings, tretinoin was investigated in many different settings. Compared with adapalene 0.3% and retinol/LR2412, topical tretinoin showed comparable results in terms of treatment outcomes.^{10,19} On the other hand, a study comparing tazarotene 0.1% versus tretinoin 0.05% suggested that tazarotene offers a superior speed of improvement. All clinical observation endpoints, such as wrinkling and mottled hyperpigmentation, favored tazarotene.¹⁷ A previous study by Kang et al.³⁷ comparing tretinoin 0.05% and tazarotene 0.1% also demonstrated similar findings with the superiority of tazarotene. However, different results might be observed as the potential efficacy of tazarotene is dose-dependent. This was supported by a 24-week treatment study demonstrating a 52% improvement with tazarotene 0.05% and 55% with tretinoin 0.05% based on global responses (>50% improvement compared with baseline).³⁷ Furthermore, after 16 weeks of treatment, 4% hydroquinone/0.3% retinol cream was more effective than tretinoin 0.05% in reducing dyspigmentation, fine wrinkles, and tactile roughness. Although retinol has a lower potency than tretinoin, this combined formulation showed greater efficacy for dyspigmentation due to the presence of hydroquinone, as mentioned previously. Moreover, better improvement in tactile roughness and fine lines were most likely due to the enhanced moisturization properties used in this study.¹⁸

All studies indicated topical tretinoin to be safe and well tolerated in all patients, even with high-dose tretinoin 5% as a peeling agent.¹⁶ The commonly observed side effects included dryness, burning sensation, erythema, and scaling. These adverse events depend on the concentration, frequency, and mode of application.³⁸⁻⁴⁰ Weiss et al.¹⁴ used microsphere gel as tretinoin 1% formulation that is equally efficacious but less irritating and showed that cutaneous irritation was mild in most subjects. With regard to long-term safety of topical tretinoin application, Kang et al.¹⁵ demonstrated no untoward histological effect on keratinocytes and melanocytes following 2-year treatment, and most adverse events were in agreement with the previous safety profile of tretinoin. Compared with tazarotene 0.1%, tretinoin 0.05% was found to cause fewer adverse effects.¹⁷ On the other hand, treatment with retinol/LR2412 demonstrated a better safety profile than topical tretinoin. Tretinoin may rapidly destroy the skin barrier on the application; therefore, less irritating ornithine transcarbamylase retinoid form such as retinol is sometimes preferable. Inflammatory characteristic of LR2412 in inhibiting mediators such as interleukin-8 and prostaglandin E2 was suggested to decrease inflammation and irritation.⁴¹ This finding was in agreement with the study by Draeos¹⁸ that found a combination of hydroquinone/retinol showed less irritation than topical tretinoin.

With regard to gender differences, studies in Asian population exhibited women to have higher risk for developing wrinkles than men, most probably due to a decrease in collagen following hypoestrogenism after menopause.⁹ Meanwhile, skin pigmentation, thickness, and sebum production are more prominent in men than in women.⁴² Nevertheless, the effects of tretinoin on skin photoaging based on these gender differences are currently unknown. However, as women generally showed more concern with their appearance, the available evidence about skin photoaging commonly included women as their participants. This is in accordance to what we found in our included studies where almost all participants were women. Therefore, this review might be representative of the significant women population that pose concern towards skin photoaging.

This study is not without limitation. The lack of uniformity in the evidence may in part be due to different tretinoin formulas used, different outcome parameters, and limited recent studies on topical tretinoin. Owing to the heterogeneity of the

studies, a meta-analysis could not be performed. Further investigation is needed to compare dose-ranging topical tretinoin to other agents with a larger sample size and long-term follow-up.

Conclusion

Topical tretinoin is a safe and effective therapeutic modality for long-term treatment of photoaging. Further research is required to compare dose-ranging topical tretinoin to other agents to provide the best treatment strategy for photoaged skin.

Author contributions

All authors listed have significantly contributed to the development and the writing of this article.

Conflicts of interest

None.

Funding

This work was financially supported by the Ministry of Research and Technology of the Republic of Indonesia (award number: B/202/E3/RA.00/2020).

Study approval

N/A.

References

- Buranasirin P, Pongpirul K, Meephanan J. Development of a Global Subjective Skin Aging Assessment score from the perspective of dermatologists. *BMC Res Notes* 2019;12:364.
- Zhang S, Duan E. Fighting against skin aging: the way from bench to bedside. *Cell Transplant* 2018;27(5):729–38.
- Ganceviciene R, Liakou AI, Theodoridis A, Makrantonaki E, Zouboulis CC. Skin anti-aging strategies. *Dermatoendocrinol* 2012;4(3):308–19.
- Tobin DJ. Introduction to skin aging. *J Tissue Viability* 2017;26:37–46.
- Han A, Chien AL, Kang S. Photoaging. *Dermatol Clin* 2014;32(3):291–9, vii.
- Fisher GJ, Kang S, Varani J, et al. Mechanisms of photoaging and chronological skin aging. *Arch Dermatol* 2002;138(11):1462–70.
- Poon F, Kang S, Chien AL. Mechanisms and treatments of photoaging. *Photodermatol Photoimmunol Photomed* 2015;31(2):65–74.
- Rabe JH, Mamelak AJ, McElgunn PJ, Morison WL, Sauder DN. Photoaging: mechanisms and repair. *J Am Acad Dermatol* 2006;55:1–19.
- Chung JH, Lee SH, Youn CS, et al. Cutaneous photodamage in Koreans: influence of sex, sun exposure, smoking, and skin color. *Arch Dermatol* 2001;137(8):1043–51.
- Bagatin E, Gonçalves HS, Sato M, Almeida LMC, Miot HA. Comparable efficacy of adapalene 0.3% gel and tretinoin 0.05% cream as treatment for cutaneous photoaging. *Eur J Dermatol* 2018;28(3):343–50.
- Mukherjee S, Date A, Patravale V, Korting HC, Roeder A, Weindl G. Retinoids in the treatment of skin aging: an overview of clinical efficacy and safety. *Clin Interv Aging* 2006;1(4):327–48.
- Baldwin HE, Nighland M, Kendall C, Mays DA, Grossman R, Newburger J. 40 years of topical tretinoin use in review. *J Drugs Dermatol* 2013;12(6):638–42.
- Kligman AM, Grove GL, Hirose R, Leyden JJ. Topical tretinoin for photoaged skin. *J Am Acad Dermatol* 1986;15(4 Pt 2):836–59.
- Weiss JS, Shavin JS, Nighland M, Grossman R. Tretinoin microsphere gel 0.1% for photodamaged facial skin: a placebo-controlled trial. *Cutis* 2006;78(6):426–32.
- Kang S, Bergfeld W, Gottlieb AB, et al. Long-term efficacy and safety of tretinoin emollient cream 0.05% in the treatment of photodamaged facial skin: a two-year, randomized, placebo-controlled trial. *Am J Clin Dermatol* 2005;6(4):245–53.
- Sumita JM, Miot HA, Soares JLM, et al. Tretinoin (0.05% cream vs. 5% peel) for photoaging and field cancerization of the forearms: randomized, evaluator-blinded, clinical trial. *J Eur Acad Dermatol Venereol* 2018;32(10):1819–26.
- Lowe N, Gifford M, Tanghetti E, et al. Tazarotene 0.1% cream versus tretinoin 0.05% emollient cream in the treatment of photodamaged facial skin: a multicenter, double-blind, randomized, parallel-group study. *J Cosmet Laser Ther* 2004;6(2):79–85.
- Draelos ZD. Novel approach to the treatment of hyperpigmented photodamaged skin: 4% hydroquinone/0.3% retinol versus tretinoin 0.05% emollient cream. *Dermatol Surg* 2005;31(7 Pt 2):799–804.
- Bouloc A, Vergnanini AL, Issa MC. A double-blind randomized study comparing the association of Retinol and LR2412 with tretinoin 0.025% in photoaged skin. *J Cosmet Dermatol* 2015;14:40–6.
- Bernstein EF, Chen YQ, Kopp JB, et al. Long-term sun exposure alters the collagen of the papillary dermis. Comparison of sun-protected and photoaged skin by northern analysis, immunohistochemical staining, and confocal laser scanning microscopy. *J Am Acad Dermatol* 1996;34(2 Pt 1):209–18.
- Chen VL, Fleischmajer R, Schwartz E, Palaia M, Timpl R. Immunohistochemistry of elastotic material in sun-damaged skin. *J Invest Dermatol* 1986;87(3):334–7.
- Mera SL, Lovell CR, Jones RR, Davies JD. Elastic fibres in normal and sun-damaged skin: an immunohistochemical study. *Br J Dermatol* 1987;117:21–7.
- Schwartz E, Cruickshank FA, Christensen CC, Perlish JS, Lebwohl M. Collagen alterations in chronically sun-damaged human skin. *Photochem Photobiol* 1993;58(6):841–4.
- Mera SL, Ribeiro H, Marques HC, Oliveira H, Santos C, Simões S. Is tretinoin still a key agent for photoaging management? *Mini Rev Med Chem* 2014;14(8):629–41.
- Nyirady J, Bergfeld W, Ellis C, et al. Tretinoin cream 0.02% for the treatment of photodamaged facial skin: a review of 2 double-blind clinical studies. *Cutis* 2001;68(2):135–42.
- Darlenki R, Surber C, Fluhr JW. Topical retinoids in the management of photodamaged skin: from theory to evidence-based practical approach. *Br J Dermatol* 2010;163(6):1157–65.
- Fisher GJ, Wang ZQ, Datta SC, Varani J, Kang S, Voorhees JJ. Pathophysiology of premature skin aging induced by ultraviolet light. *N Engl J Med* 1997;337(20):1419–28.
- Riahi RR, Bush AE, Cohen PR. Topical retinoids: therapeutic mechanisms in the treatment of photodamaged skin. *Am J Clin Dermatol* 2016;17(3):265–76.
- Shim JH, Shin DW, Noh MS, Lee TR. Reduced collagen internalization via down-regulation of MRC2 expression by UVA irradiation and its recovery by all-trans retinoic acid. *J Dermatol Sci* 2014;73(2):163–6.
- Bhawan J, Gonzalez-Serva A, Nehal K, et al. Effects of tretinoin on photodamaged skin. A histologic study. *Arch Dermatol* 1991;127(5):666–72.
- Cucé LC, Bertino MC, Scattone L, Birkenhauer MC. Tretinoin peeling. *Dermatol Surg* 2001;27:12–4.
- Geng A, Weinstock MA, Hall R, Eilers D, Naylor M, Kalivas J; VATTC Trial Group. Tolerability of high-dose topical tretinoin: the Veterans Affairs Topical Tretinoin Chemoprevention Trial. *Br J Dermatol* 2009;161(4):918–24.
- Kligman DE, Sadiq I, Pagnoni A, Stoudemayer T, Kligman AM. High-strength tretinoin: a method for rapid retinization of facial skin. *J Am Acad Dermatol* 1998;39(2 Pt 3):S93–7.
- Kligman DE, Draelos ZD. High-strength tretinoin for rapid retinization of photoaged facial skin. *Dermatol Surg* 2004;30(6):864–6.
- Weinstock MA, Bingham SF, Lew RA, et al; Veterans Affairs Topical Tretinoin Chemoprevention (VATTC) Trial Group. Topical tretinoin therapy and all-cause mortality. *Arch Dermatol* 2009;145:18–24.
- Shukuwa T, Kligman A, Stoudemayer T. The effect of short-term (one-month) topical tretinoin on photodamaged forearm skin. *J Dermatolog Treat* 1993;4:139–43.
- Kang S, Leyden JJ, Lowe NJ, et al. Tazarotene cream for the treatment of facial photodamage: a multicenter, investigator-masked, randomized, vehicle-controlled, parallel comparison of 0.01%, 0.025%, 0.05%, and 0.1% tazarotene creams with 0.05% tretinoin emollient cream applied once daily for 24 weeks. *Arch Dermatol* 2001;137(12):1597–604.
- Leyden JJ, Grossman R, Nighland M. Cumulative irritation potential of topical retinoid formulations. *J Drugs Dermatol* 2008;7(Suppl. 8):s14–8.
- Skov MJ, Quigley JW, Bucks DA. Topical delivery system for tretinoin: research and clinical implications. *J Pharm Sci* 1997;86(10):1138–43.
- Thielitz A, Gollnick H. Topical retinoids in acne vulgaris: update on efficacy and safety. *Am J Clin Dermatol* 2008;9(6):369–81.
- Tran C, Michelet JF, Simonetti L, et al. In vitro and in vivo studies with tetra-hydro-jasmonic acid (LR2412) reveal its potential to correct signs of skin ageing. *J Eur Acad Dermatol Venereol* 2014;28(4):415–23.
- Rahrovan S, Fanian F, Mehryan P, Humbert P, Firooz A. Male versus female skin: what dermatologists and cosmeticians should know. *Int J Womens Dermatol* 2018;4(3):122–30.