



Acute Respiratory Distress Syndrome Associated with Multisystem Inflammatory Syndrome in a Child with Covid-19 and Diabetic Ketoacidosis: A Case Report

Sy Duong-Quy · Duc Huynh-Truong-Anh · Nhung Le-Thi-Hong ·
Tap Le-Van · Sa Le-Thi-Kim · Tien Nguyen-Quang · Thanh Nguyen-Thi-Kim ·
Ngan Nguyen-Phuong · Thanh Nguyen-Chi · Tinh Nguyen-Van ·
Van Duong-Thi-Thanh · Dung Nguyen-Tien · Carine Ngo ·
Timothy Craig

Received: April 21, 2022 / Accepted: May 12, 2022 / Published online: May 24, 2022
© The Author(s) 2022

ABSTRACT

Severe acute respiratory syndrome coronavirus 2 (SARS-CoV-2) or coronavirus disease 2019 (Covid-19), has uncontrollable effects on many organs. A great number of previously published scientific reports have revealed that patients with diabetes mellitus face a more severe form of Covid-19 with a higher death rate. Here we present the case of a 13-year-old unvaccinated boy who was admitted to an intensive care unit (ICU) with a history of fever, cough, dyspnea, throat pain, nausea, and confusion that progressed to lethargy after 24 h. On clinical

examination, he was in a coma with Kussmaul's breathing, and was anuric. His blood biochemical analysis demonstrated hyperglycemia, severe metabolic acidosis, kidney failure, electrolyte disturbances, and inflammation. Chest x-ray showed pneumonia and a pleural effusion. The results of the SARS-CoV-2 real-time polymerase chain reaction were positive. The patient was diagnosed with Covid-19-induced acute respiratory distress syndrome associated with multisystem inflammatory syndrome in children secondary to his acute respiratory failure, acute kidney injury, and new-onset type 1 diabetes mellitus with diabetic ketoacidosis. He was intubated for invasive

S. Duong-Quy (✉)
Biomedical Research Center, Lam Dong Medical
College, Da Lat, Vietnam
e-mail: sduongquy.jfvp@gmail.com

S. Duong-Quy · D. Huynh-Truong-Anh ·
N. Le-Thi-Hong · T. Le-Van · S. Le-Thi-Kim ·
T. Nguyen-Quang · T. Nguyen-Thi-Kim ·
N. Nguyen-Phuong · T. Nguyen-Chi ·
T. Nguyen-Van
Covid-19 Unit of Phu Chanh, Binh Duong General
Hospital, Binh Duong, Vietnam

S. Duong-Quy · T. Craig
Division of Pulmonary, Allergy and Critical Care
Medicine, Penn State College of Medicine, Hershey,
PA, USA

V. Duong-Thi-Thanh
Department of Internal Medicine, Can Tho
University of Medicine and Pharmacy, Can Tho,
Vietnam

D. Nguyen-Tien
Department of Pediatric Intensive Care Unit, Bach
Mai Hospital, Hanoi, Vietnam

C. Ngo
Department of Pathology, Institute Gustave Roussy,
Villejuif, France

mechanical ventilation and received a normal saline infusion and continuous insulin infusion (0.1 IU/kg/h) for the treatment of his diabetic ketoacidosis. He was also treated with methylprednisolone, aspirin, and heparin, and underwent continuous renal replacement therapy for acute renal failure for 9 days. The patient was discharged from ICU on day 16 and was followed up regularly as an outpatient with daily treatment, including subcutaneous insulin injection (30 IU/day) and a calcium channel blocker for hypertension (nifedipine 20 mg/day).

Keywords: Acute respiratory distress syndrome; ARDS; SARS-CoV-2; Covid-19; Continuous renal replacement therapy; Ketoacidosis; Diabetes mellitus

Key Summary Points

Evidence-based diagnosis and treatment of acute respiratory distress syndrome (ARDS) associated with multiple systemic inflammatory syndrome in children (MIS-C) related to Covid-19 is still limited.

Ketoacidosis coma might be at the onset of Covid-19-induced diabetes in children associated with ARDS.

Early diagnosis of ARDS and ketoacidosis in children with Covid-19 is very important for starting the appropriate treatment.

Invasive mechanical ventilation combined with conventional treatment for MIS-C is crucial for patient recovery.

INTRODUCTION

The coronavirus disease 2019 (Covid-19) pandemic, caused by the severe acute respiratory syndrome coronavirus 2 (SARS-CoV-2), has triggered an unprecedented global emergency.

Covid-19 has uncontrollable effects on many organs. Since the start of this pandemic, a great number of published scientific reports have revealed that patients with diabetes mellitus face a more severe form of Covid-19 with a higher death rate [1]. Interestingly, “new-onset” hyperglycemia and “new-onset” diabetes mellitus are now identified as possible consequences of Covid-19, particularly among hospitalized children and adults [2, 3]. Moreover, clinical manifestations of Covid-19 are significantly different between age groups [4]. Adults develop respiratory symptoms, which can proceed to the most severe form of acute respiratory distress syndrome (ARDS), while children are largely immune to respiratory illness, but can develop multisystem inflammatory syndrome-in-children (MIS-C) [5, 6] that may rapidly progress to multiorgan failure and be life-threatening [7]. Children with MIS-C often present with persistent fever (100%), gastrointestinal symptoms (84%), cardiac abnormalities (75%), neurological symptoms (26–56%), respiratory symptoms (12–34%), and acute kidney injury (18.2%) [8]. Most reported cases illustrate that patients with MIS-C were admitted to the hospital with cardiac and gastrointestinal problems [8]. In this case report, we describe the clinical course and follow-up of a 13-year-old child with severe MIS-C secondary to Covid-19 with acute kidney injury, confusion, pneumonia, diabetic ketoacidosis (DKA), and new-onset type 1 diabetes mellitus.

CASE REPORT

Here we present the case of a 13-year-old male who was admitted to an intensive care unit (ICU), referred to as Covid-19 Unit of Phu Chanh, Binh Duong General Hospital, Binh Duong Province, Vietnam, at the end of October 2021, with a 2-day medical history of fever, cough, dyspnea, throat pain, nausea, and confusion that progressed to lethargy after 24 h. He had no medical history of chronic diseases during his childhood. Before being ill, he did not have any medical history of diabetes or neurological disorders. He had not received the Covid-19 vaccine yet. There was no family

history of diabetes; however, his father had been diagnosed with Covid-19 previously. In the ICU, the patient's initial vital signs were a temperature of 38.5 °C, heart rate of 140 beats per minute, blood pressure of 90/40 mmHg, respiratory rate of 50 breaths per minute, and oxygen saturation of 99% via nasal cannula at 6 L/min. On clinical examination, he was in a coma, unresponsive to pain and stimulation, with Glasgow score of 7, positive pupillary reaction, Kussmaul's breathing, and was anuric. He did not have any skin infection nor other source of infection. His weight was 50 kg, height 154 cm, and body mass index (BMI) 21.1 kg/m² (50% percentile for age).

His blood biochemical analysis demonstrated hyperglycemia, severe metabolic acidosis, kidney failure, electrolyte disturbances, and inflammation (Table 1). Chest x-ray showed a mild pneumonia (Fig. 1). Abdominal ultrasound revealed free fluid in the abdomen and scrotum. Echocardiogram demonstrated normal cardiac muscle, valves, ejection fraction, and wall motion. Brain computed tomography (CT) scan was also normal. An electrocardiogram showed sinus tachycardia, with a rate of 150 beats per minute. The result of a SARS-CoV-2 real-time polymerase chain reaction (RT-PCR) was positive.

The patient was diagnosed with Covid-19-induced acute respiratory distress syndrome associated with MIS-C secondary to his acute respiratory failure, acute kidney injury (AKI), suspected brain injury, and new-onset type 1 diabetes mellitus with DKA secondary to β -cell injury. He was intubated for invasive mechanical ventilation to assure respiratory function with the following parameters: ventilatory mode, pressure control; FiO₂, 55%; positive end expiratory pressure (PEEP) 14 cm H₂O; respiratory rate, 20 times per minute. Midazolam and rocuronium were prescribed for preventing mechanical ventilatory desynchrony. The patient received a normal saline infusion (3000 mL/24 h) combined with potassium chloride 10% (40 mL/24 h) for 2 days and continuous insulin infusion (0.1 IU/kg/h) for the treatment of DKA. He was also treated with pulse doses of methylprednisolone therapy for 3 days, and then changed to

methylprednisolone 2 mg/kg/day for 5 days as recommended locally for treating Covid-19. In addition, he received aspirin for his MIS-C, heparin for preventing coagulation, and an antibiotic for preventing ventilator-associated pneumonia. He also underwent continuous renal replacement therapy (CRRT) for acute renal failure for 9 days. On day 6, the patient was woken and extubated from invasive mechanical ventilation, transferred to high-flow nasal cannula, followed by conventional oxygen therapy over the following days. His urine increased from 50 ml per day from day 8 to over 2000 ml per day on day 12. By day 10, his vital signs normalized with a Glasgow score of 14, body temperature of 37 °C, SpO₂ of 97% on room air; his hemodynamic parameters stabilized; and his biochemical blood testing was nearly normal, except for his renal functional parameters (Table 1 and Fig. 2). The patient was discharged from the ICU on day 16 and was followed up regularly as an outpatient with daily treatment, including subcutaneous insulin injection (30 IU/day) and a calcium channel blocker for hypertension (nifedipine 20 mg/day). Currently, the patient has been in a good health status and seen regularly in Outpatients Department of Binh Duong General Hospital every month for his new onset of type 1 diabetes during post-Covid-19 period. Written informed consent was obtained from the patient's parents for the publication of clinical details.

DISCUSSION

The Covid-19 pandemic poses a significant risk to both adults and children. Although children were initially considered less likely to be affected by SARS-CoV-2, MIS-C is a recently recognized manifestation in children associated with coronavirus SARS-CoV-2 infection with a proven higher mortality rate [9]. The US Centers for Disease Control and Prevention (CDC) has provided a case definition of MIS-C, which includes patients under 21 years of age with fever (> 38.0 °C for \geq 24 h, or report of subjective fever lasting \geq 24 h), laboratory evidence of inflammation (with one or more of the

Table 1 Laboratory data of patient before and after treatment MIS-C

Variables	Reference range	Patient's value Before treating MIS-C	Patient's value After treating MIS-C	Difference (%)
White blood cells ($10^9/L$)	4–11	23.7	8.7	92.59 ↓
Neutrophil (%)	45–75	75.3	65.7	13.62 ↓
Lymphocyte (%)	20–45	20.7	19.56	5.66 ↓
Red blood cell ($10^{12}/L$)	3.8–6.3	3.49	3.84	9.55 ↑
Hemoglobin (g/dL)	12–18	10.2	15.3	40.00 ↑
Hematocrit (%)	37–52	31.6	44.6	34.12 ↑
Platelet ($10^9/L$)	140–500	197	289	37.86 ↑
CRP (mg/dL)	< 1	3.01	1.37	74.89 ↓
Pro-calcitonin (ng/ml)	< 0.05	2.99	0.095	187.68 ↓
Ferritin (ng/ml)	23.9–336.2	523.8	246.1	72.14 ↓
Albumin (g/L)	35–52	25.1	28.9	14.07 ↑
Lactate (mmol/L)	0.5–22	0.4	1.28	104.76 ↑
LDH (U/L, 37 °C)	< 247	299.71	225.3	28.35 ↓
Urea (mmol/L)	2.8–7.2	11.13	18.8	51.25 ↑
Creatinine ($\mu\text{mol}/L$)	72–127	187.91	275.06	37.65 ↑
eGFR ($\text{mL}/\text{min}/1.73 \text{ m}^2$)	> 60	46.29	73.21	45.05 ↑
Glucose (mg/dL)	70–110	296	142	70.32 ↓
HbA1c (%Hb)	< 5.7	13.0	9.7	29.07 ↓
pH	7.35–7.45	6.82	7.44	8.70 ↑
PaCO ₂ (mmHg)	35–45	24	33	31.58 ↑
PaO ₂ (mmHg)	80–100	169	90	61.00 ↓
		(with FiO ₂ of 30%)	(with FiO ₂ of 21%)	
HCO ₃ ⁻ (mmol/L)	18–23	3.9	22.4	140.68 ↑
BE ⁻ (mmol/L)	-2 to +3	-29.8	-1.1	185.76 ↑
Serum ketone (mg/dL)	Negative	40	0	200 ↓
D-dimer ($\mu\text{g}/\text{mL}$)	< 0.5	6.42	3.91	48.60 ↓
Fibrinogen (g/L)	1.5–4	5.9	2.14	93.53 ↓
PT (%)	> 70	74	96	25.88 ↑
APTT (s)	10–16	33.5	28.6	15.78 ↓
Sodium (mmol/L)	135–145	134	137	2.21 ↑

Table 1 continued

Variables	Reference range	Patient's value Before treating MIS-C	Patient's value After treating MIS-C	Difference (%)
Potassium (mmol/L)	3.5–5	2.9	4.5	43.24 ↑
Calcium (mmol/L)	1.1–1.6	1.17	1.05	10.81 ↓
Magnesium (mmol/L)	0.77–1.33	0.82	0.84	2.41 ↑
AST (U/L, 37 °C)	0–50	38.18	23.14	49.05 ↓
ALT (U/L, 37 °C)	0–50	15.8	12.78	21.13 ↓
FT3 (pg/mL)	2.30–3.90	2.24	–	–
FT4 (ng/mL)	0.61–1.12	0.63	–	–
TSH (μIU/mL)	0.32–5.33	0.28	–	–

Data presented as number and %

APTT activated partial thromboplastin time; *AST* aspartate aminotransferase; *ALT* alanine aminotransferase; *CRP* C-reactive protein; *eGFR* estimated glomerular filtration rate; *FiO₂* fraction of inspired oxygen; *FT3* free triiodothyronine; *FT4* free thyroxine; *HbA1c* hemoglobin A1c; *LDH* lactate dehydrogenase; *MIS-C* multisystem inflammatory syndrome in children; *PT* prothrombin time; *TSH* thyroid stimulating hormone

*With *FiO₂*

following: elevated C-reactive protein (CRP), erythrocyte sedimentation rate (ESR), fibrinogen, procalcitonin, D-dimer, ferritin, lactic acid dehydrogenase (LDH), or interleukin 6 (IL-6), elevated neutrophils, reduced lymphocytes, and low albumin), severe illness needing hospitalization, and involvement of two or more organ systems (cardiac, renal, respiratory, hematologic, gastrointestinal, dermatologic, or neurological), with a positive test for SARS-CoV-2 indicating current or recent infection or Covid-19 exposure; and no other alternative plausible diagnoses [10]. Our patient had a 24 h fever and multisystem illness (lung, kidney, suspected brain injury, and injured β-cells-induced diabetes), as well as elevated inflammatory markers such as increased neutrophils and CRP, and decreased albumin, consistent with the US CDC case definition of MIS-C. In addition, RT-PCR testing to detect SARS-CoV-2 infection was positive.

Published data have illustrated that children with Covid-19 can develop a life-threatening multisystem inflammatory syndrome, but rarely

exhibit severe respiratory symptoms, and that most reported patients were admitted to the hospital for symptoms including diarrhea, vomiting, abdominal pain, ventricular dysfunction, or coronary artery dilation [8, 11]. However, in our case, the patient was admitted to the hospital with coma, DKA, and clinical signs of acute kidney failure, including anuria, and severe edema of the legs, hands, eyes, abdomen, and a pleural effusion. Previous studies demonstrated that most patients developed AKI on the first day of hospitalization and the pathophysiology of Covid-19-induced AKI might be related to local and systemic inflammatory and immune responses, endothelial injury, activation of coagulation pathway, and the renin–angiotensin system, or alternatively direct viral infection of kidney tissue [12, 13]. Furthermore, severe disease, acute lung injury, obesity, lower median left ventricular ejection fraction, systolic dysfunction, inflammation, and exposure to nephrotoxins also contribute to Covid-19-related AKI [14]. In our patient with acute Covid-19 and MIS-C, AKI appeared to be

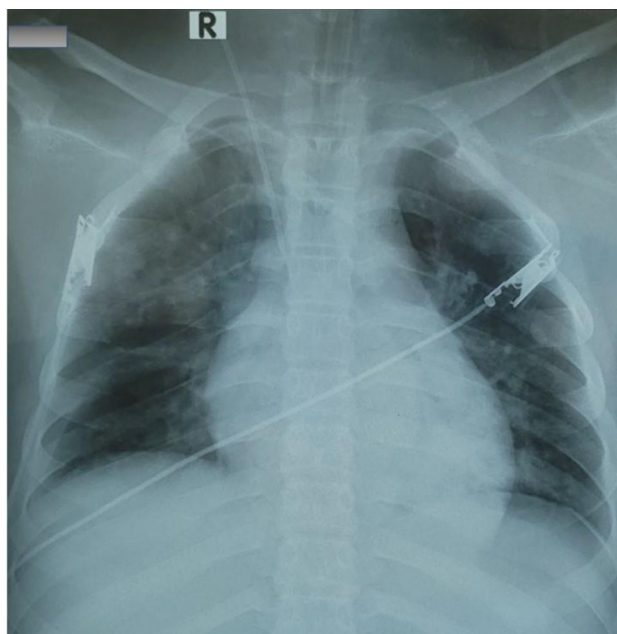


Fig. 1 Chest x-ray imaging with pneumonia at admission. The presence of diffused and bilateral infiltration in lung parenchyma of reported patient with acute respiratory distress syndrome

related to inflammation, as evidenced by a high neutrophil/lymphocyte rate, and increased inflammatory biomarker levels (Table 1).

Obviously, DKA is a serious complication of diabetes that can be life-threatening, and unfortunately we suspect delays in the diagnosis and care of DKA has not been uncommon during the Covid-19 pandemic. In our report, the patient was diagnosed with DKA on the basis of the typical clinical symptoms, such as Kussmaul's breathing, loss of consciousness, biochemical features [blood glucose higher than ≥ 200 mg/dL, arterial pH of < 7.3 and bicarbonate (HCO_3) level < 15 mmol/L] and ketonemia (Table 1). DKA is serious complication due to a lack of total or partial insulin deficiency that is most commonly encountered in patients with type 1 diabetes mellitus [13]. Type 1 diabetes may develop secondary to autoimmune destruction of insulin-producing β -cells in the pancreas [15, 16]. In his medical history, our patient did not have any health problems before being infected by Covid-19. We attributed his new-onset DKA and type 1 diabetes to Covid-19-induced autoimmune pancreatitis, leading to the destruction of β -cells.

Although genetic predisposition is important in the development of type 1 diabetes mellitus, infections are also important in the pathogenesis of autoimmune type 1 diabetes mellitus. It is speculated that antibodies against SARS-CoV-2 may trigger an inflammatory process that impacts β -cell function and potentially leads to hastened β -cell death and the onset of diabetes [17].

In our case report, the patient was in a comatose state that appears to be secondary to DKA-induced cerebral edema, rather than brain injury from the virus. Because of his mental status, he required invasive mechanical ventilation for airway protection. Although the possibility of SARS-CoV-2 infecting the central nervous system directly is still disputed, owing to the very low level of angiotensin-converting enzyme 2 (ACE-2) expression in the brain, human brain gene expression and immunohistochemistry have revealed that SARS-CoV-2 could infiltrate into the hypothalamus [18]. Interestingly, neuroimaging in children with neurologic manifestations has demonstrated only a low prevalence of acute encephalitis in MIS-C associated with Covid-19 [19, 20]. Our

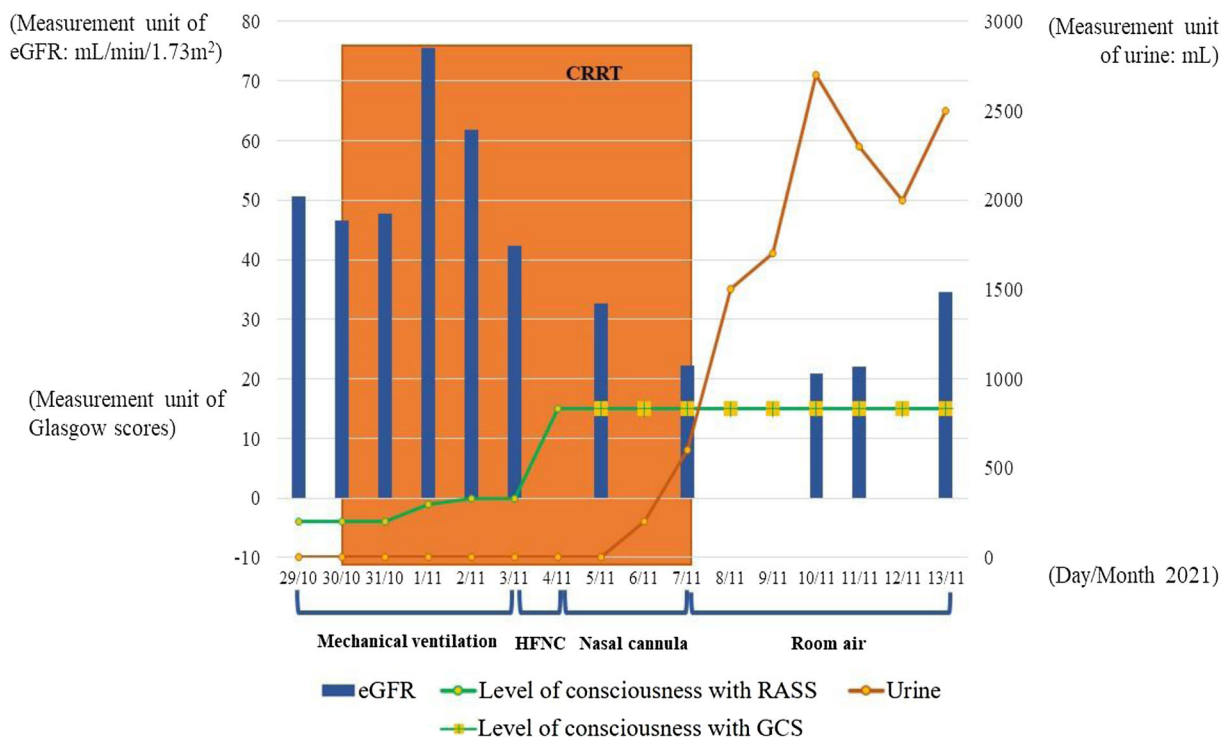


Fig. 2 Laboratory, clinical findings, and treatment trends during hospitalization. Modification of urine volume, glomerular filtration, conscious status, and treatment of acute respiratory distress syndrome during patients’

hospitalization. *eGFR* estimated glomerular filtration rate; *RASS* Richmond agitation sedation scale; *GCS* Glasgow coma scale; *CRRT* continuous renal replacement therapy; *HFNC* high-flow nasal cannula

patient had a normal brain CT scan, and a total recovery from his coma without any neurologic sequela, suggesting his mental status changes were from DKA. Furthermore, low levels of serum albumin, calcium, and potassium were also found in our patient with Covid-19-induced MIS-C. It has been suggested that increased capillary permeability, secondary to SARS-CoV-2-induced MIS-C, might be responsible for the reduction of serum albumin, and thus calcium [14]. In addition, the consequence of Covid-19’s protein S binding to ACE-2 receptor might reduce angiotensin-2 degradation, leading to an increase of aldosterone, causing renal potassium loss, and finally leading to hypokalemia [17].

Although the first cases of multisystem inflammatory syndrome in children (MIS-C) and adults (MIS-A) have been reported previously [21, 22], the prevalence of MIS-C and MIS-A related to Covid-19 has not been well

established [23]. These reports showed that there was a diversity of clinical manifestation of MIS across age groups: MIS-C with mucocutaneous lesions was more frequent in young children and myocarditis and gastrointestinal symptoms were more common in older children, while MIS-A usually had gastrointestinal complications [21, 22]. Until now, ARDS due to Covid-19 associated with MIS-C or MIS-A and diabetes has still been rare.

The treatment of MIS-C is often difficult and has required combination therapies. In our case report, the patient underwent continuous renal replacement therapy, owing to ARI with anuria, metabolic acidosis, and uremia. In addition, the patient was given a pulse dose of methylprednisolone in association with aspirin for his MIS-C. Although intravenous immune globulin has been recommended in some studies, we did not use it in our patient since the beneficial effect of intravenous immune globulin in Covid-19-

induced MIS-C has not been clearly demonstrated [24]. In our case report, the treatment of DKA with fluid resuscitation using 0.9% saline, 0.45% saline, infused insulin, and correction of the electrolyte disturbances was performed as per recommendations [25]. As noted above, Covid-19-induced MIS-C with ARI, DKA, and new onset of type 1 diabetes has rarely been reported in children; however, making the diagnosis and instituting aggressive and individualized therapy can prevent loss of life.

The patient was discharged from hospital after 16 days in the ICU fully conscious and clinically stable, with full recovery from his respiratory failure, and with improved inflammatory biomarkers. His renal function has not fully recovered, but improved, and he has continued to require treatment of his new-onset diabetes with insulin, and also treatment of his hypertension with a calcium channel blocker. Six months after his discharge, the patient has returned to normal life and been followed in the long-Covid-19 clinic for his diabetes and hypertension.

Finally, the main limitation of this case report is related to a lack of clarity to effectively estimate a lag following initial Covid-19 infection with the presumably autoimmune MIS-C syndrome as demonstrated previously [26]. Although the diagnosis of MIS-C in our case report was based significantly on clinical manifestations and inflammatory biomarkers, the alternative diagnosis in favor of acute Covid-19 is still debatable.

CONCLUSION

MIS-C related to Covid-19 with ARDS remains an uncommon clinical manifestation, especially when it is complicated with COVID-19 new-onset type 1 diabetes. Our case report is the first case in Vietnam with the constellation of Covid-19-induced multisystemic inflammatory syndrome, respiratory failure, acute kidney injury, and new-onset diabetes in an unvaccinated child, despite more than 1.8 million people (0.8% children) having contracted Covid-19 in Vietnam. Fortunately, the accurate diagnosis and aggressive treatment saved the

life of our patient. Finally, in addition to lung damage from Covid-19, the mechanism by which SARS-CoV-2 (Covid-19) can damage the kidney and pancreatic β -cells causing the long-term consequence of renal failure and diabetes needs to be further explored.

ACKNOWLEDGEMENTS

Funding. No funding or sponsorship was received for this study or publication of this article.

Authors Contributions. Sy Duong-Quy, Duc Huynh-Truong-Anh, Nhung Le-Thi-Hong, Tap Le-Van, Sa Le-Thi-Kim, Tien Nguyen-Quang, Thanh Nguyen-Thi-Kim, Ngan Nguyen-Phuong, Thanh Nguyen-Chi, Tinh Nguyen-Van: data collection. Sy Duong-Quy, Van Duong-Thi-Thanh, Dung Nguyen-Tien, Carine Ngo, Timothy Craig: manuscript drafting. Sy Duong-Quy, Duc Huynh-Truong-Anh, Carine Ngo, and Timothy Craig: manuscript approving.

Disclosures. Sy Duong-Quy, Duc Huynh-Truong-Anh, Nhung Le-Thi-Hong, Tap Le-Van, Sa Le-Thi-Kim, Tien Nguyen-Quang, Thanh Nguyen-Thi-Kim, Ngan Nguyen-Phuong, Thanh Nguyen-Chi, Tinh Nguyen-Van, Van Duong-Thi-Thanh, Dung Nguyen-Tien, Carine Ngo, and Timothy Craig have nothing to disclose.

Compliance with Ethics Guidelines. Written informed consent was obtained from the patient's parents for the publication of clinical details.

Data Availability. Patient data and the clinical course were retrieved from the hospital medical records. They are available from the corresponding author upon reasonable request.

Open Access. This article is licensed under a Creative Commons Attribution-NonCommercial 4.0 International License, which permits any non-commercial use, sharing,

adaptation, distribution and reproduction in any medium or format, as long as you give appropriate credit to the original author(s) and the source, provide a link to the Creative Commons licence, and indicate if changes were made. The images or other third party material in this article are included in the article's Creative Commons licence, unless indicated otherwise in a credit line to the material. If material is not included in the article's Creative Commons licence and your intended use is not permitted by statutory regulation or exceeds the permitted use, you will need to obtain permission directly from the copyright holder. To view a copy of this licence, visit <http://creativecommons.org/licenses/by-nc/4.0/>.

REFERENCES

- Caballero AE, Ceriello A, Misra A, et al. COVID-19 in people living with diabetes: an international consensus. *J Diabetes Complications*. 2020;34(9):107671. <https://doi.org/10.1016/j.jdiacomp.2020.107671>.
- Khunti K, Prato SD, Mathieu C, et al. COVID-19, hyperglycemia, and new-onset diabetes. *Diabetes Care*. 2021;44(12):2645–55. <https://doi.org/10.2337/dc21-1318>.
- Rubino F, Amiel SA, Zimmet P, et al. New-onset diabetes in covid-19. *N Engl J Med*. 2020;383(8):789–90. <https://doi.org/10.1056/NEJMc2018688>.
- Wu Z, McGoogan JM. Characteristics of and important lessons from the coronavirus disease 2019 (COVID-19) outbreak in China: summary of a report of 72 314 cases from the Chinese Center for Disease control and prevention. *JAMA*. 2020;323(13):1239–42. <https://doi.org/10.1001/jama.2020.2648>.
- Cheung EW, Zachariah P, Gorelik M, et al. Multisystem inflammatory syndrome related to COVID-19 in previously healthy children and adolescents in New York City. *JAMA*. 2020;324(3):294–6. <https://doi.org/10.1001/jama.2020.10374>.
- Feldstein LR, Rose EB, Horwitz SM, et al. Multisystem inflammatory syndrome in U.S. children and adolescents. *N Engl J Med*. 2020;383:334–46. <https://doi.org/10.1056/NEJMoa2021680>.
- Weisberg SP, Connors TJ, Zhu Y, et al. Distinct antibody responses to SARS-CoV-2 in children and adults across the COVID-19 clinical spectrum. *Nat Immunol*. 2021;22:25–31. <https://doi.org/10.1038/s41590-020-00826-9>.
- Tang Y, Li W, Baskota M, et al. Multisystem inflammatory syndrome in children during the coronavirus disease 2019 (COVID-19) pandemic: a systematic review of published case studies. *Transl Pediatr*. 2021;10(1):121–35. <https://doi.org/10.21037/tp-20-188>.
- Acevedo L, Piñeres-Olave BE, Niño-Serna LF, et al. Mortality and clinical characteristics of multisystem inflammatory syndrome in children (MIS-C) associated with covid-19 in critically ill patients: an observational multicenter study (MISCO study). *BMC Pediatr*. 2021;21:1–12. <https://doi.org/10.1186/s12887-021-02974-9>.
- Centers for Disease Control and Prevention. MIS-A case definition (2021). <https://www.cdc.gov/mis/mis-a/hcp.html>. [Accessed 6 Dec 2021]
- Wu EY, Campbell MJ. Cardiac manifestations of multisystem inflammatory syndrome in children (MIS-C) following COVID-19. *Curr Cardiol Rep*. 2021;23(11):168. <https://doi.org/10.1007/s11886-021-01602-3>.
- Ahmadian E, Khatibi SMH, Soofiyan SR, et al. COVID-19 and kidney injury: pathophysiology and molecular mechanisms. *Rev Med Virol*. 2020;31(3):e2176. <https://doi.org/10.1002/rmv.2176>.
- Lipton M, Mahajan R, Kavanagh C, et al. AKI in COVID-19-associated multisystem inflammatory syndrome in children (MIS-C). *Kidney*. 2021;2(4):611–8. <https://doi.org/10.34067/KID.0005372020>.
- Basalely A, Gurusinge S, Schneider J, et al. Acute kidney injury in pediatric patients hospitalized with acute COVID-19 and multisystem inflammatory syndrome in children associated with COVID-19. *Kidney Int*. 2021;100(1):138–45. <https://doi.org/10.1016/j.kint.2021.02.026>.
- Lizzo JM, Goyal A, Gupta V. Adult diabetic ketoacidosis. <https://www.ncbi.nlm.nih.gov/books/NBK560723/>. [Accessed 30 Dec 2021]
- Yang J-K, Lin S-S, Ji X-J, et al. Binding of SARS coronavirus to its receptor damages islets and causes acute diabetes. *Acta Diabetol*. 2010;47(3):193–9. <https://doi.org/10.1007/s00592-009-0109-4>.
- Unsworth R, Wallace S, Oliver NS, et al. New-onset type 1 diabetes in children during COVID-19: multicenter regional findings in the U.K. *Diabetes Care*. 2020;43(11):170–1. <https://doi.org/10.2337/dc20-1551>.

18. Nampoothiri S, Sauve F, Sauve F, et al. The hypothalamus as a hub for SARS-CoV-2 brain infection and pathogenesis. *BioRxiv*. 2021. <https://doi.org/10.1101/2020.06.08.139329>.
19. Olivotto S, Basso L, Lavatelli R, et al. Acute encephalitis in pediatric multisystem inflammatory syndrome associated with COVID-19. *Eur J Paediatr Neurol*. 2021;34:84–90. <https://doi.org/10.1016/j.ejpn.2021.07.010>.
20. Orman G, Desai NK, Kralik SF, et al. Neuroimaging offers low yield in children positive for SARS-CoV-2. *Am J Neuroradiol*. 2021;42(5):951–4. <https://doi.org/10.3174/ajnr.A7022>.
21. Dufort EM, Koumans EH, Chow EJ, New York State and Centers for Disease Control and Prevention Multisystem Inflammatory Syndrome in Children Investigation Team, et al. Multisystem inflammatory syndrome in children in New York State. *N Engl J Med*. 2020;383(4):347–58. <https://doi.org/10.1056/NEJMoa2021756>.
22. Davogusto GE, Clark DE, Hardison E, et al. Characteristics associated with multisystem inflammatory syndrome among adults with SARS-CoV-2 infection. *JAMA Netw Open*. 2021;4(5):e2110323. <https://doi.org/10.1001/jamanetworkopen.2021.10323>.
23. Patel P, DeCuir J, Abrams J, Campbell AP, Godfred-Cato S, Belay ED. Clinical characteristics of multisystem inflammatory syndrome in adults: a systematic review. *JAMA Netw Open*. 2021;4(9):e2126456. <https://doi.org/10.1001/jamanetworkopen.2021.26456>.
24. Licciardi F, Baldini L, Dellepiane M, et al. MIS-C treatment: is IVIG always necessary? *Front Pediatr*. 2021;9: 753123. <https://doi.org/10.3389/fped.2021.753123>.
25. Lawrence SE. Diagnosis and treatment of diabetic ketoacidosis in children and adolescents. *Paediatr Child Health*. 2005;10(1):21–4.
26. Kundu A, Maji S, Kumar S, Bhattacharya S, Chakraborty P, Sarkar J. Clinical aspects and presumed etiology of multisystem inflammatory syndrome in children (MIS-C): a review. *Clin Epidemiol Glob Health*. 2022;14: 100966. <https://doi.org/10.1016/j.cegh.2022.100966>.