



# Foreign body granulomas caused by caterpillar setae

Wen Chen ,<sup>1</sup> Ting Gong,<sup>1</sup> Dirk Elston,<sup>2</sup> Chao Ji <sup>1</sup>

<sup>1</sup>Dermatology, the First Affiliated Hospital of Fujian Medical University, Fuzhou, Fujian, China

<sup>2</sup>Department of Dermatology and Dermatologic Surgery, Medical University of South Carolina, Charleston, South Carolina, USA

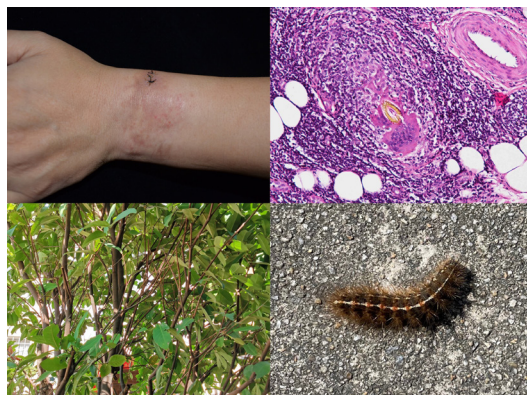## Correspondence to

Dr Chao Ji;  
jichaofy@fjmu.edu.cn

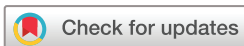Accepted 18 May 2022

## DESCRIPTION

A man in his 50s complained of repeated redness and sharp pain on his left wrist for about 5 months. In this time period, he visited local clinics and was diagnosed with eczema. Treatment with topical steroid cream and oral antihistamines drugs did not improve his symptoms. He was then transferred to our department and received a biopsy of the affected area. Physical examination revealed scattered erythematous papules and nodules on his left wrist. Surprisingly, histopathological results exhibited many unique structures in dermis and subcutaneous fat tissue, which had sharply defined refractory golden walls, short retrograde barbules and hollow interior with variable eosinophilic staining. These special structures were surrounded by a large number of lymphocytes, histocytes and several multinucleated giant cells. On reviewing this patient's medical history, we found that he climbed a wax apple tree (*Syzygium samarangense*) and was bitten by the unknown insect 5 months ago. By searching the literature,<sup>1,2</sup> we believe that the unique structures were the setae of a caterpillar. Subsequently, this patient confirmed our conjecture. He admitted that there were many gypsy moth caterpillars (*Lymantria dispar*) on the wax apple tree at that time (figure 1). Based on these findings, a diagnosis of foreign body granulomas caused by caterpillar setae was made. We applied 0.5 mL of compound betamethasone, which was composed of 2 mg betamethasone sodium phosphate and 5 mg betamethasone dipropionate in 1 mL, to the lesion by intralesional injection once a month and conducted a total treatment of 5 months. The patient's lesions disappeared after treatment with intralesional injection of glucocorticoid.



**Figure 1** Top left: the clinical appearance of the affected area after biopsy; bottom left: the wax apple tree in the patient's yard; top right: histopathological image of the caterpillar setae; bottom right: the caterpillar found in the patient's yard.



© BMJ Publishing Group Limited 2022. No commercial re-use. See rights and permissions. Published by BMJ.

**To cite:** Chen W, Gong T, Elston D, et al. *BMJ Case Rep* 2022;**15**:e248653. doi:10.1136/bcr-2021-248653

## Patient's perspective

I had redness and sharp pain on my left wrist and was diagnosed with eczema 5 months ago. These symptoms did not improve after treatment with oral antihistamines drugs and topical glucocorticoids. I was then transferred to Dr Ji and had a pathological examination. The histopathology result suggested that the lesion was caused by the caterpillar. This reminded me of the exposure to the insect 5 month ago. I recovered from it soon after intralesional steroid injection.

## Learning points

- ▶ For patients with allergic contact dermatitis, a detailed medical history should be obtained, including occupational history and environmental exposure history.
- ▶ The unique histopathological characteristics of the setae of a caterpillar is difficult to collect and provide highly relevant information for practising dermatologists.

**Contributors** CJ was the first visited doctor for this patient. WC was responsible for collecting the results of laboratory tests and writing this manuscript. TG provided photos of the lesion, tree and caterpillar. DE reviewed the first manuscript and provided key advice for the revision of the manuscript.

**Funding** The authors have not declared a specific grant for this research from any funding agency in the public, commercial or not-for-profit sectors.

**Competing interests** None declared.

**Patient consent for publication** Consent obtained directly from patient(s).

**Provenance and peer review** Not commissioned; externally peer reviewed.

Case reports provide a valuable learning resource for the scientific community and can indicate areas of interest for future research. They should not be used in isolation to guide treatment choices or public health policy.

## ORCID iDs

Wen Chen <http://orcid.org/0000-0001-8530-4641>

Chao Ji <http://orcid.org/0000-0002-2282-3505>

## REFERENCES

- 1 Todhunter KH, Cawdell-Smith AJ, Bryden WL, et al. Processionary caterpillar setae and equine fetal loss: 1. histopathology of experimentally exposed pregnant mares. *Vet Pathol* 2014;**51**:1117–30.
- 2 Hossler EW. Caterpillars and moths: Part 1. dermatologic manifestations of encounters with Lepidoptera. *J Am Acad Dermatol* 2010;**62**:1–10.

Copyright 2022 BMJ Publishing Group. All rights reserved. For permission to reuse any of this content visit <https://www.bmj.com/company/products-services/rights-and-licensing/permissions/>  
BMJ Case Report Fellows may re-use this article for personal use and teaching without any further permission.

Become a Fellow of BMJ Case Reports today and you can:

- ▶ Submit as many cases as you like
- ▶ Enjoy fast sympathetic peer review and rapid publication of accepted articles
- ▶ Access all the published articles
- ▶ Re-use any of the published material for personal use and teaching without further permission

**Customer Service**

If you have any further queries about your subscription, please contact our customer services team on +44 (0) 207111 1105 or via email at [support@bmj.com](mailto:support@bmj.com).

Visit [casereports.bmj.com](http://casereports.bmj.com) for more articles like this and to become a Fellow